

Sudden depression of R-wave amplitude in a patient who underwent subcutaneous implantable cardioverter-defibrillator implantation



Masaki Takahashi, MD, Hidekazu Kondo, MD, PhD, Tetsuji Shinohara, MD, PhD, Naohiko Takahashi, MD, PhD

From the Department of Cardiology and Clinical Examination, Faculty of Medicine, Oita University, Yufu, Japan.

Introduction

Implantable cardioverter-defibrillators (ICDs) are commonly used for prevention of sudden cardiac death (SCD) in patients with idiopathic ventricular fibrillation (IVF). The subcutaneous ICD (S-ICD) is a novel therapeutic modality to prevent SCD that does not require transvenous lead implantation.¹ Patients with IVF are usually young and active, do not require pacing, and do not have ventricular tachycardias that would benefit from antitachycardia pacing. They are therefore likely to benefit from this system. However, S-ICD treatment is susceptible to T-wave oversensing (TWOS), resulting in inappropriate shocks with the therapy. Therefore, it is necessary to strictly screen patients for the suitability of S-ICD using a template electrocardiogram. A new high-pass filter (SMART Pass; Boston Scientific Corporation, Natick, MA) for cardiac sensing, created in order to reduce inappropriate shocks, is commonly used with the S-ICD system. Theuns and colleagues² reported that using SMART Pass resulted in significant reduction of inappropriate shocks in an S-ICD system without negative effects on appropriate shock therapies. SMART Pass becomes invalid when recorded R-wave amplitude is depressed to less than 0.5 mV. Most recently, the remote monitoring system for the S-ICD updated the alert function, which can inform medical practitioners of the invalidity of the SMART Pass sensing filter. We herein report a case of preventing a potential inappropriate therapy through the detection of invalid SMART Pass via remote monitoring.

Case report

A 48-year-old man who survived cardiac arrest owing to IVF was implanted with an S-ICD (A209 EMBLEMTM) for

KEYWORDS Depression of R-wave amplitude; Inappropriate shock; Postural change; Remote monitoring; S-ICD; SMART Pass (Heart Rhythm Case Reports 2021;7:449–452)

Conflict of interest for all authors: None. Sources of funding: None. **Address reprint requests and correspondence:** Dr Hidekazu Kondo, Department of Cardiology and Clinical Examination, Faculty of Medicine, Oita University, 1-1 Idaigaoka, Hasama, Yufu, Oita 879-5593, Japan. E-mail address: hkondo@oita-u.ac.jp.

KEY TEACHING POINTS

- Sudden depression of R-wave amplitude caused the invalidation of SMART Pass. It could be one of the causes for inappropriate shock in patients implanted with S-ICD. An alert of invalidation of SMART Pass through remote monitoring was useful to prevent the possible inappropriate therapy in the present S-ICD-implanted case.
- The most probable cause for this problem would be the postural change-induced minor displacement of the S-ICD generator, which was demonstrated by the fact that changing the sensing vector from primary to alternate solved this problem, because an alternate sensing vector is considered less affected by the position of the S-ICD generator.
- Preoperative screening including postural change in the decubitus position might be recommended as one of the solutions for preventing this problem. If the alteration of R wave is observed in a primary sensing vector by postural change screening, the eligibilities of other sensing vectors should be checked, and the use of these vectors should be considered.

secondary prevention. He weighed 59.7 kg. His body mass index was 19.9 kg/m². He had no family history of SCD or past history of syncope. During 36 months of follow-up using remote monitoring, he has had no episodes of ventricular fibrillation (VF).

Most recently (3 months before the event), the remote monitoring system of the S-ICD was updated to be able to inform an alert regarding invalidation of the SMART Pass sensing filter, which revealed the drastic R-wave amplitude depression in this patient (Figure 1A). Undersensing was observed in some initial beats, but automatic gain control

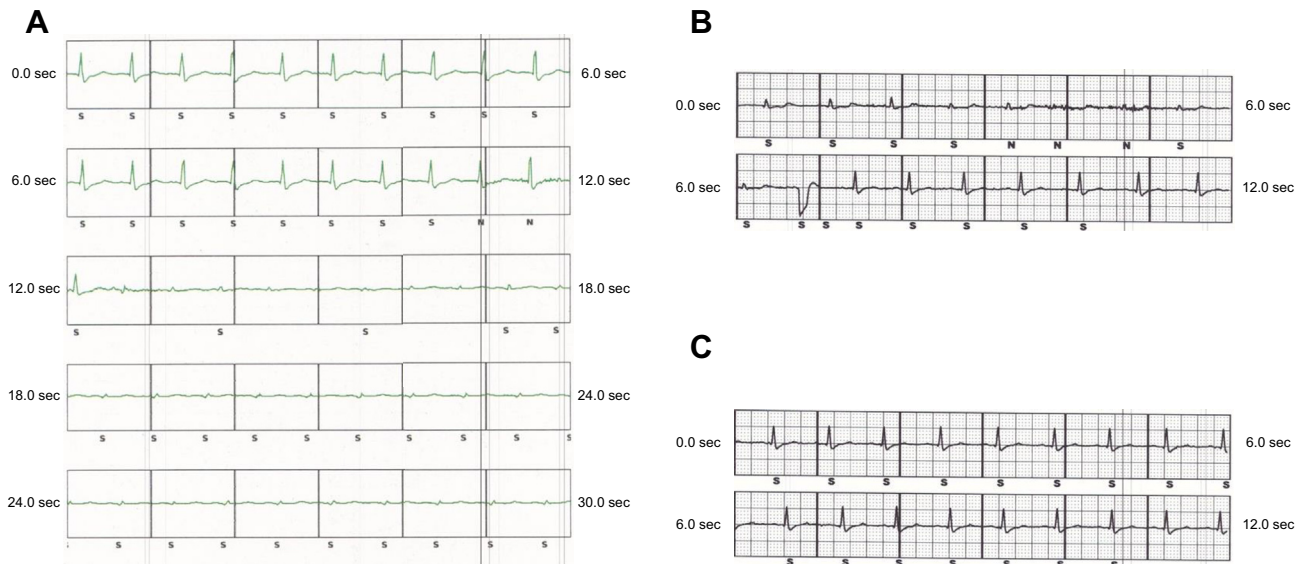


Figure 1 A: Surface electrocardiogram of subcutaneous implantable cardioverter-defibrillator (S-ICD) system showed sudden R-wave amplitude depression, making this system undersense some beats of the patient temporarily. B: Surface electrocardiogram in the S-ICD system using primary sensing vector while changing the patient's body position from supine to right lateral decubitus position and subsequently returning from right lateral decubitus position to supine position. C: Surface electrocardiogram of the S-ICD system using alternate sensing vector while changing the body position as described above.

gradually detected the poor R wave (Figure 1A). We had a concern that this problem could cause TWOS in the future, and hence we called the patient to come to the outpatient device clinic. As a result of medical examination, it was found out that R-wave amplitude was reproducibly depressed when he changed his position to right lateral decubitus position (Figure 1B). When he turned to a supine position, R-wave amplitude recovered to the normal amplitude (Figure 1B). This alteration of R-wave amplitude was prominent in the primary sensing vector; therefore, the sensing vector was changed from primary to alternate, which attenuated the changing of R-wave amplitude owing to his postural change (Figure 1C).

Discussion

There are several potential causes of R-wave sensing failure after implantation (Table 1). At first, we thought it likely that the device was implanted too far caudally, with left colon flexure air impeding sensing. However, the position of the generator was located in the appropriate place (Figure 2A)

Table 1 Possible causes of undersensing in subcutaneous implantable cardioverter-defibrillator after implantation

- Air in the pocket
- Air in alimentary canal owing to placement too caudally
- Electrode failure at the distal or proximal position
- Electrode movement or dislodgement
- Dislodgement of generator
- Electrode fracture
- Weight loss or gain
- Not tying the generator down well enough
- Worsened cardiomyopathy
- Electrolyte imbalances

and was unlikely to be the cause for this problem. Next, we have checked whether there are any differences in the chest radiograph between preimplantation and postimplantation. Compared to the chest radiograph just after operation, the S-ICD generator was slightly displaced forward in the chest radiograph 36 months later (Figure 2B). Based on this finding, one of the possible causes for this problem may be the motion-induced minor displacement of the S-ICD generator. The cardiac position should be interposed between the ICD generator and lead to sense higher R-wave amplitude in the primary vector (Figure 3A). However, minor displacement of the generator forward owing to postural change possibly could disturb the positional relationship, especially in the primary vector (Figure 3B). It has been reported that inappropriate shock or undersensing frequently occurred in the primary vector.^{3,4} The fact that changing the sensing vector from primary to alternate solved this problem supports this speculation, as an alternate sensing vector is considered less affected by the position of the S-ICD generator (Figure 3A). Preoperative screening including postural change in the decubitus position might be recommended as one of the solutions for preventing this problem. If the depression of the R wave is observed in a primary sensing vector by this screening, the eligibilities of secondary and alternate sensing vectors should be checked, and the use of these vectors should be considered from the beginning. Also, more diligent fixation of the generator to the dorsal position may also be needed for the patient, as in the present case. On the opportunity of generator replacement in the future, refixation to the dorsal position will be required to solve this problem.

We had a concern of undersensing VF, which was not seen in the present case. In the report by Theuns and colleagues,² there was no underdetection of VF in any

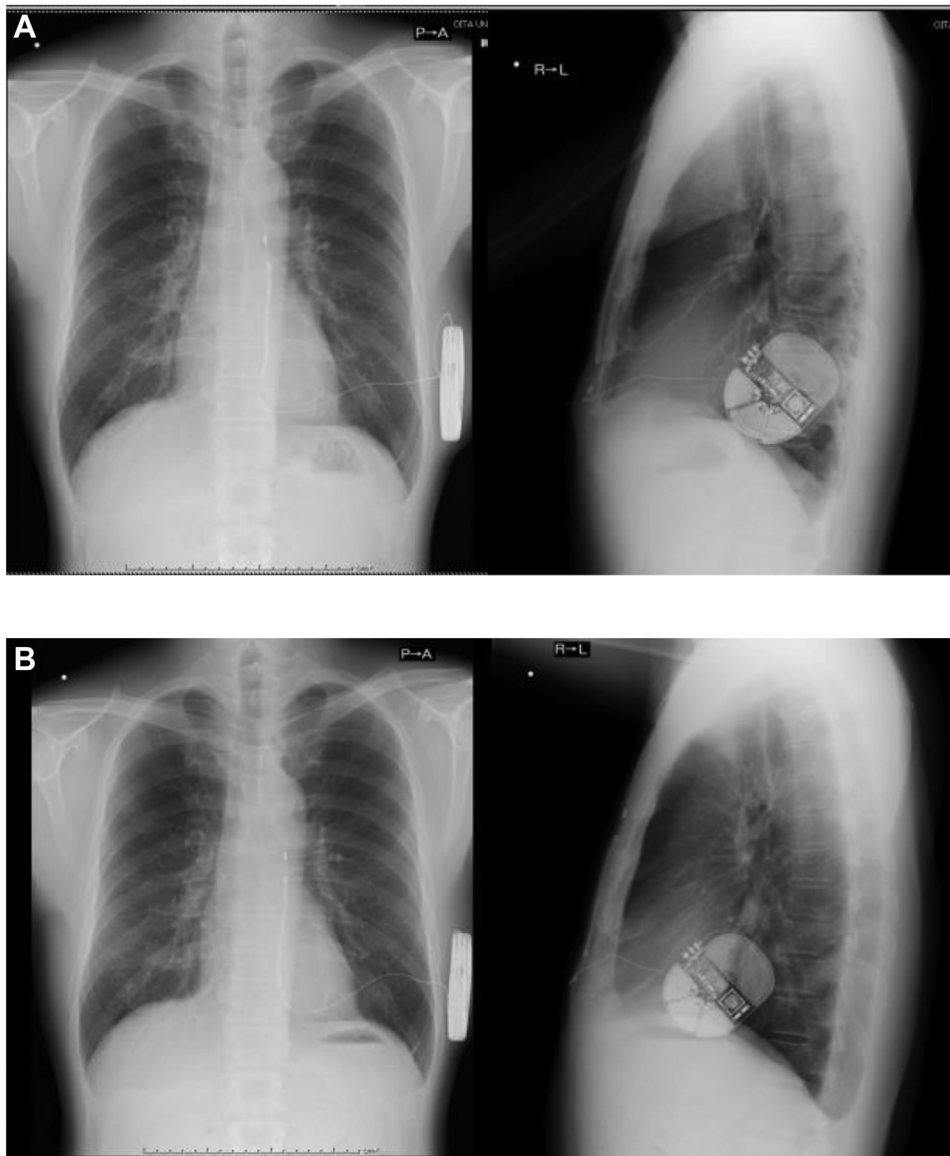


Figure 2 A: Near postoperative chest radiograph. B: Chest radiograph 36 months after implantation.

patients even if they had sudden transient changes in R-wave amplitude and deactivation of the filter. And while there might be a concern that changes in R-wave amplitude might imply a subsequent increased risk of high defibrillation thresholds and conversion failure, this has not been borne out on observation. In this case, the patient had a PRAETORIAN score of <905 ,⁵ portending a low risk of conversion failure. But changes in R-wave sensing leading to TWOS or, conversely, failure of VF detection remained a concern.

Potential reasons for R-wave sensing failure after S-ICD implantation are well documented and include any causes that lead to change in the position of the heart in relation to the chest wall (Table 1). Of these, the most likely in this scenario some years after implant included change in position of the device or lead. Figure 3A and 3B presents a demonstration of how minor changes in position can affect sensing in the primary vector. In this particular case, the chest

radiographs included belied this explanation. More likely, change in R-wave sensing with change in position had been present since implant but not detected, as this is not usually measured in the screening process for S-ICD. Preoperative screening including postural change in the decubitus position could be recommended as one of the solutions for preventing this problem. If R-wave depression is observed in a primary sensing vector by this screening, the eligibilities of secondary and alternate sensing vectors should be checked, and the use of these vectors should be considered from the beginning.

The remote monitoring alert of invalidation of the SMART Pass that became available most recently has the potential to reduce inappropriate therapy further, as demonstrated by interventions undertaken in the present case described here. In addition, utilization of an additional algorithm in future devices that compares the primary to

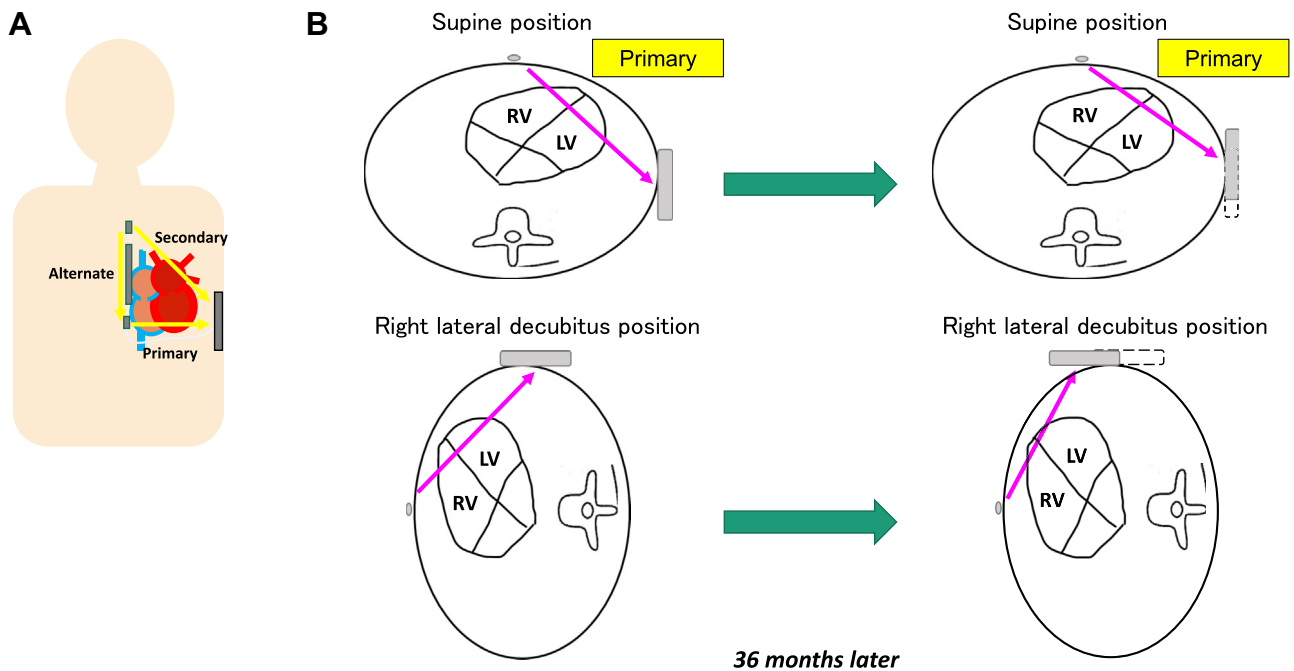


Figure 3 **A:** The 3 available sensing vectors of the subcutaneous implantable cardioverter-defibrillator: primary (from proximal electrode ring to can), secondary (from distal electrode ring to can), and alternate (from distal to proximal electrode). **B:** Potential mechanism for the R-wave depression owing to postural change (from supine position to right lateral decubitus position). After 36 months, minor displacement of the generator forward by postural change possibly could disturb the R-wave sensing in the primary vector.

the alternative vector, like those seen in some current ICDs, may help confirm the presence of a true arrhythmia and prove helpful in future device iterations.

References

1. Bardy GH, Smith WM, Hood MA, et al. An entirely subcutaneous implantable cardioverter-defibrillator. *N Engl J Med* 2010;363:36–44.
2. Theuns DAMJ, Brouwer TF, Jones PW, et al. Prospective blinded evaluation of a novel sensing methodology designed to reduce inappropriate shocks by the subcutaneous implantable cardioverter-defibrillator. *Heart Rhythm* 2018; 15:1515–1522.
3. Black-Maier E, Lewis RK, Barnett AS, et al. Subcutaneous implantable cardioverter-defibrillator troubleshooting in patients with left ventricular assist devices: a case series and systematic review. *Heart Rhythm* 2020;17:1536–1544.
4. Rudic B, Tülümen E, Fastenrath F, et al. Incidence, mechanisms, and clinical impact of inappropriate shocks in patients with a subcutaneous defibrillator. *Europace* 2020;22:761–768.
5. Quast ABE, Baalman SWE, Brouwer TF, et al. A novel tool to evaluate the implant position and predict defibrillation success of the subcutaneous implantable cardioverter-defibrillator: The PRAETORIAN score. *Heart Rhythm* 2019; 16:403–410.