

## How to safely occlude left atrial appendage with a thrombus inside? 🎥

📧 Şükür Akyüz, 📧 İlhan İlker Avcı, 📧 Can Yücel Karabay,  
 📧 Duygu Genç, 📧 Ali Palıce  
 Department of Cardiology, Siyami Ersek Thoracic and Cardiovascular  
 Surgery Hospital; Istanbul-Turkey

### Introduction

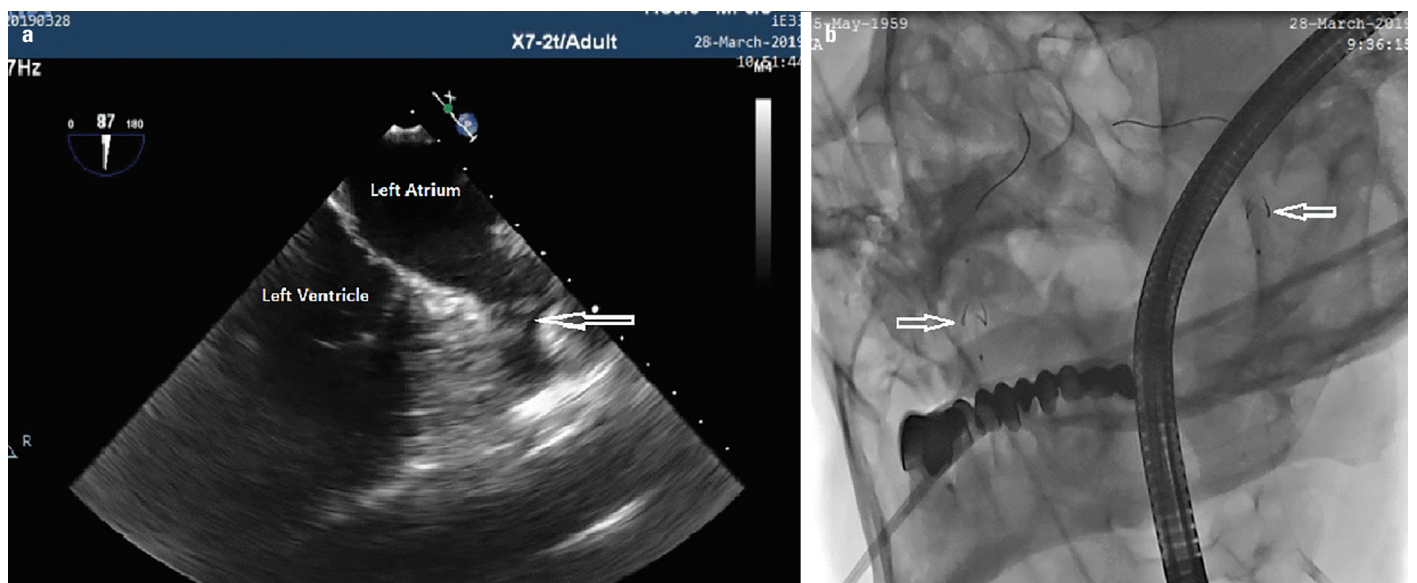
In clinical practice, the presence of a thrombus in the left atrial appendage (LAA) is considered a contraindication to percutaneous LAA occlusion. However, in rare circumstances, as in the present case, LAA occlusion is needed despite the presence of a thrombus. While attempting to occlude the LAA in such a case, there is a high risk of thrombus dislodgement. The available data regarding the safety measures that are recommended in terms of the procedural technique are sparse and can be found in only a few case reports and series (1-6). Each report described a different aspect of these safety measures. In the present case, we combined them completely. Some measures are first described in the present case.

### Case Report

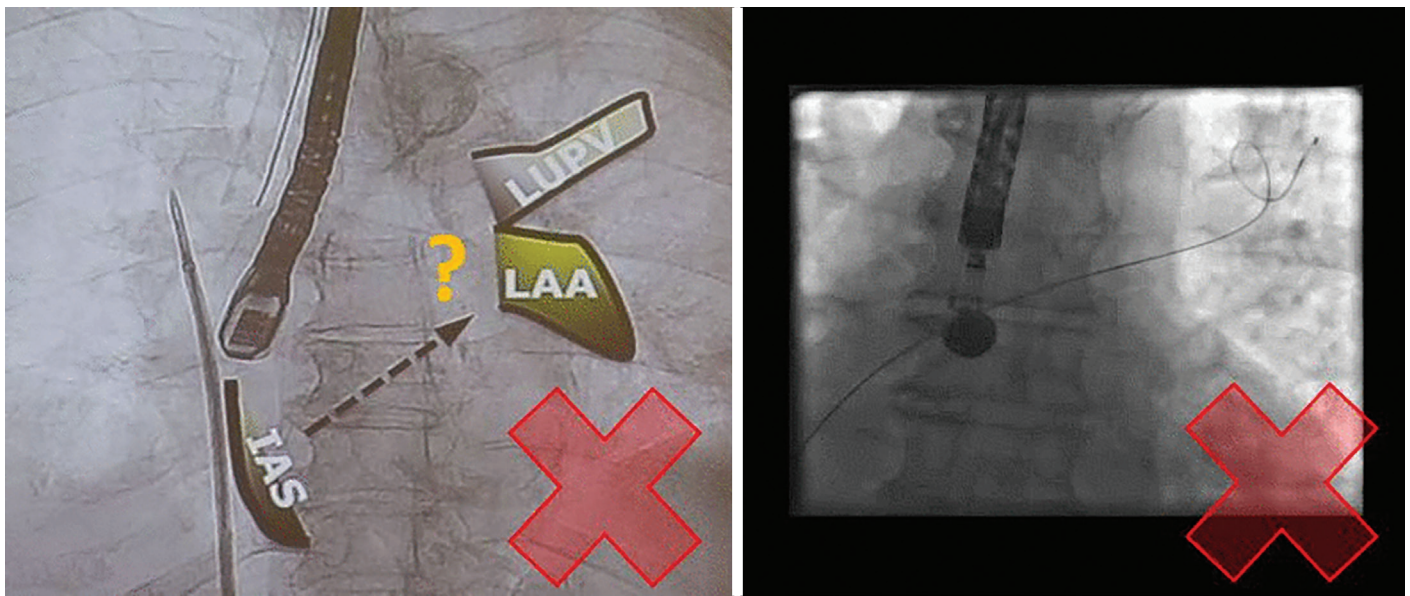
A 59-year-old man with hypertrophic cardiomyopathy and permanent atrial fibrillation with a vitreous hemorrhage in the eye while on treatment with warfarin was referred to our hospital for percutaneous occlusion of LAA. The ophthalmologist did not recommend reinitiating any oral anticoagulant to avoid recurrent

bleeding. Transesophageal echocardiogram (TEE) revealed a mobile and seemingly fresh thrombus in the middle of LAA with a high risk of embolism (Fig. 1a, Video 1). After extensive discussion with the patient about the benefits and risks, we decided to perform percutaneous occlusion of LAA after making some modifications to the well-defined standard implantation procedure (7).

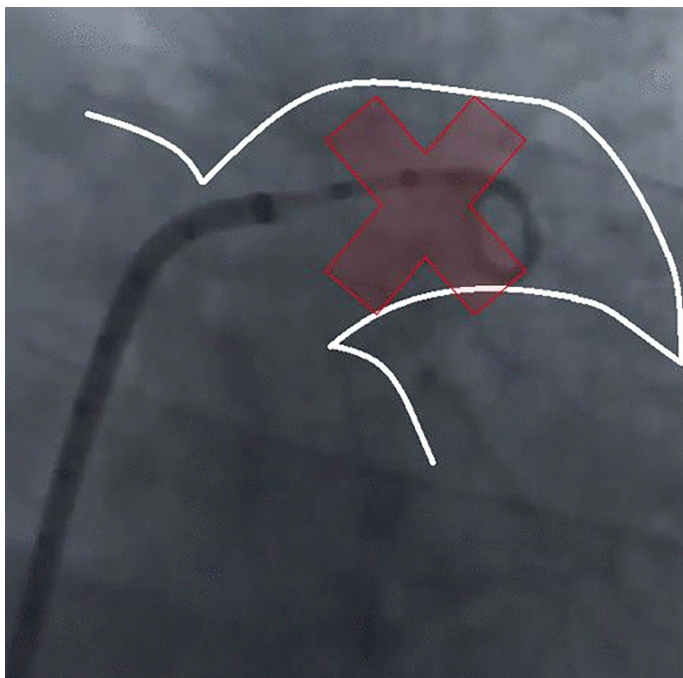
The modifications are as follows: **Safety measure 1:** Filter devices (EmboShield® NAV<sup>6</sup>, Abbott Vascular) were placed for each carotid artery to prevent stroke in case of inadvertent dislodgement of the thrombus (Fig. 1b). **Safety measure 2:** Since manipulations to achieve co-axial alignment were to be kept at a minimum, we paid even more attention than usual to puncturing the fossa ovalis at the exact postero-inferior region. **Safety measure 3:** The transeptal puncture was facilitated by the stylet of the transeptal needle (or could be the back end of a coronary wire) to release any exaggerated tension on the catheter because the puncture assembly might jump into LAA like a slingshot when it is popped across the septum (Video 2). This is of particular importance in case of a thick or floppy septum. **Safety measure 4:** When it comes to sheath exchange, blind advancement of the stiff wire toward the left upper pulmonary vein (LUPV) under the guidance of fluoroscopy may be misleading, assuming that LUPV is located in a predictable location (Fig. 2). Due to anatomical variations and a close relationship between the LUPV and LAA, the wire may enter the LAA inadvertently. Thus, a pigtail-shaped wire that is less likely to enter the LAA was used for sheath exchange in the body of left atrium instead of using a stiff wire. It was the Inoue wire in the present case but a Safari™ (Boston scientific) or Confida™ (Medtronic) wire may be used (Video 3). **Safety measure 5:** We did not cannulate LAA with a pigtail catheter or a delivery sheath (Fig. 3). **Safety measure 6:** We avoided the use of a contrast injection to delineate LAA anatomy



**Figure 1.** (a) Pre-procedural 2D TEE view showing the thrombus (arrow) in the middle of LAA. (b) Filters (arrows) placed in each carotid artery for cerebral protection



**Figure 2.** Close relationship between left upper pulmonary vein and LAA. Please note the fluoroscopic ambiguity in anatomy



**Figure 3.** No cannulation of LAA with a pigtail catheter or delivery sheath

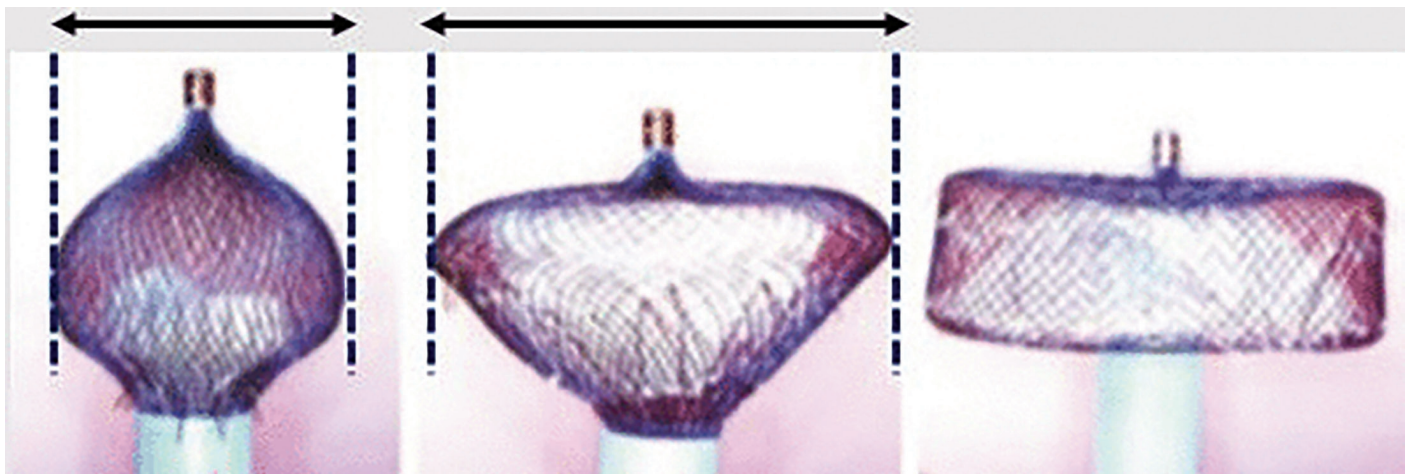
and used TEE to perform all the measurements. Imaginary right anterior oblique (RAO) cranial and caudal projections on fluoroscopy can be rotated 90 degrees clockwise to correspond to the TEE images of the LAA in the short and long axes, respectively. By focusing on these TEE images, the Amulet™ device (Abbott Vascular) was implanted in the present case. The Amulet has an opening order: first, the so-called “ball” configuration, followed by the “triangle”, and then the “lobe” (Fig. 4). It is easy to identify the relatively atraumatic ball configuration in TEE images. As such, one can be sure that it is located at the most distal part of the assembly.

By visualizing the ball configuration in the left atrium, the delivery sheath could be advanced carefully into the neck of the LAA without touching the thrombus. After this, the lobe of the device (25 mm Amulet™) was opened (Video 4 and 5). This is described as the “no-touch” technique (2, 5). **Safety measure 7:** Repositioning the device presents a clear increased risk of embolization of the thrombus. This is why having a good quality image to be able to place the implant on a single try is important. In spite of making full efforts to do this, repositioning may still be required, as in the present case (Video 6). However, we had to reposition the device only once. To achieve this, the device was recaptured only partially to reveal the triangular configuration and not the ball configuration inside the LAA, without allowing the sheath to move back into the left atrium (Video 7). As the area of the triangular configuration is bigger than the ball configuration (Fig. C), it could keep the thrombus trapped behind the device.

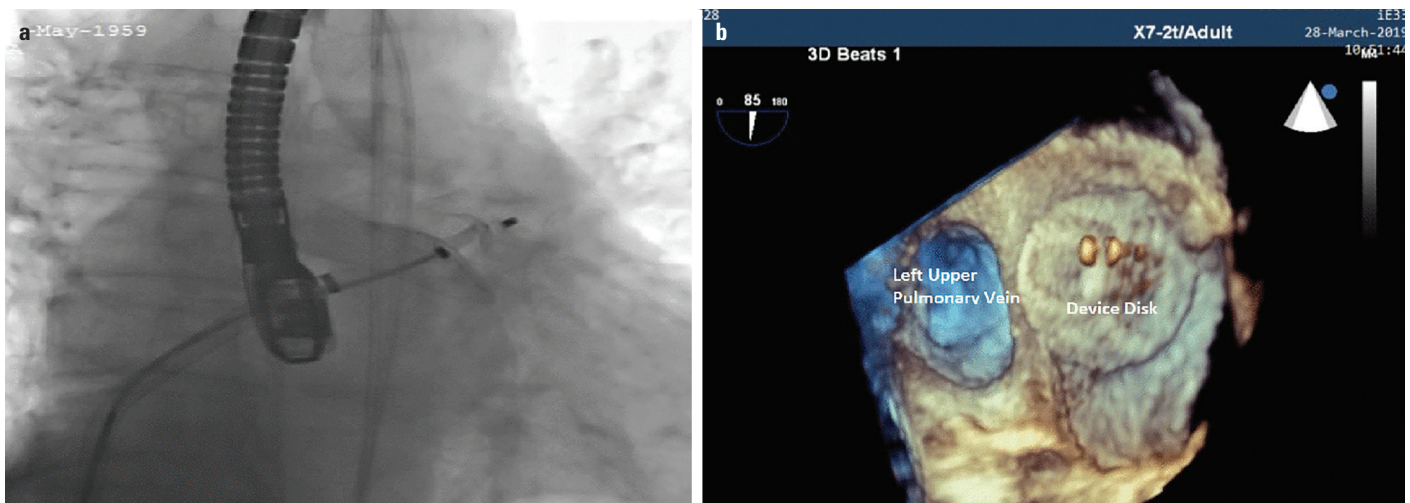
Finally, the device was used to successfully seal the LAA without complications, as demonstrated by fluoroscopy and TEE (Fig. 5a and 5b, Video 8 and 9).

## Discussion

Oral anticoagulation is a well-accepted first-line management modality for stroke prevention in patients with atrial fibrillation and a high risk of stroke. Once a thrombus develops inside the LAA, many clinicians recommend intensifying the anticoagulation with a strict monitoring protocol. However, anticoagulants may not dissolve thrombus despite effective or even supratherapeutic doses (8, 9). A further dilemma for the clinician is that rare patients may also have a very high bleeding risk that precludes long-term anticoagulation. Referring such patients for surgical excision of LAA is one option. Percutaneous occlusion of LAA is another option, which is less invasive as compared to surgery, but carries a high



**Figure 4.** Relative difference between the surface areas of the so-called ball and triangular configurations



**Figure 5.** (a) Final fluoroscopic view showing the signs of device stability. (b) Final 3D TEE “en face” view of the device disk sealing the ostium of LAA

risk of stroke as well, such that it should only be performed by operators highly experienced in LAA occlusion.

The most important aspect of this procedure is not to dislodge thrombus inadvertently. Thus, some operators believe that a cerebral protection device is essential as a safety measure (1, 4, 5). However, others believe that the use of these devices may actually complicate the procedure by prolonging the procedural time in such a fragile patient (2, 3). Acknowledging the lack of randomized studies, we believe that the benefits of using a cerebral protection device outweigh its risks.

As this procedure is performed mostly under the guidance of TEE, it is important that the interventionist has the essential knowledge of interpreting TEE images and cooperates well with the echocardiographer. In addition, because being able to place the implant on a single try is the default approach, having good quality preoperative images by means of computed tomography is important. It is strongly recommended to distinctly depict the LAA anatomy to select the correct device size.

As an alternative to safety measure 4, sheath exchange in the LUPV may be preferred, under the guidance of 3D TEE, if avail-

able. However, in case of guidance under 2D TEE, the wire tip may not be visible or the visible part, which is seen in TEE may not be the true tip because the image sector may cut the LAA parallel to the wire, which may be located anterior or posterior to the image plane.

In regard to safety measure 6, there are some navigation systems (e.g., EchoNavigator™, Philipps Healthcare) that allow a simultaneous view of the TEE along with the fluoroscopy. This system can be quite useful on these kind of procedures.

The “no-touch” technique is a safe technique. Amulet™ (Abbott Vascular), LAmbré™ (Lifetech Scientific) or second-generation Watchman FLX™ (Boston Scientific) systems can be used for this purpose, whereas a first-generation Watchman device cannot. The reason for the latter is that the first-generation device needs its sheath to be advanced deep inside the LAA, which presents a risk of thrombus dislodgement. Conversely, the Watchman FLX™ has an atraumatic closed distal end and opens in a ball configuration, similar to Amulet™, which obviates the need for deep sheath advancement, and can be partially recaptured and repositioned either proximally or distally. Despite having no

ball configuration, Lambre™ opens as an atraumatic configuration as well, which allows it to be deployed similarly.

It is speculated that the expected rate of thromboembolic events based on the CHA<sub>2</sub>DS<sub>2</sub>-VASC score might underestimate the real risk of this cohort, which is higher, considering the presence of LAA thrombosis. Further, those with the thrombus may derive greater benefits from LAA occlusion than those without a thrombus (6). It was also reported that the short- and long-term results may be similar between the interventions performed for LAA with or without a thrombus inside (5). However, it should be recognized that the occlusion of LAA with a thrombus inside are all performed by experienced operators as compared to the other procedures that may have been performed by operators having varying levels of experience, making such a comparison possibly misleading. Studies with larger sample sizes and longer follow-up periods are needed to confirm the effectiveness of this kind of intervention, to potentially extend such an indication further.

There are several limitations to this case report. This intervention can obviously be performed in the presence of a mid-to distal thrombus, whereas a proximal thrombus precludes such an intervention. We recognize that it would be better to use a dedicated cerebral protection system such as Sentinel™ (Boston Scientific), if available, which can be deployed by single radial access. Although filters prevent the most feared complication (i.e., embolic stroke), coronary and peripheral arterial embolization could occur, but these are easier to manage percutaneously or surgically. Dedicated post-interventional assessments by imaging were not performed because of the absence of any symptom or sign, thus subclinical micro-embolization could not be ruled out.

## Conclusion

In case of clinical necessity, percutaneous occlusion of LAA with a (mobile) thrombus inside may be feasible if it is the only option. However, some modifications to the standard implantation procedure and additional safety measures are important to ensure efficacy and safety.

**Conflict of interest:** Şükrü Akyüz is a consultant and proctor for Abbott. The other authors have nothing to disclose.

**Informed consent:** An informed consent was obtained after extensive discussion with the patient about the benefits and risks of the procedure.

**Video 1.** 2D TEE view showing a mobile thrombus inside the LAA with a high risk of embolism

**Video 2.** The puncture assembly jumping into the LAA like a slingshot when popped across the septum in a different patient. This is undesirable

**Video 3.** Pigtail-shaped Inoue wire for sheath exchange in the body of the left atrium

**Video 4.** Advancing the delivery sheath into the ostium of LAA

**Video 5.** Advancing the delivery sheath into the landing zone

**Video 6.** Partial recapturing of the device lobe up to the triangular shape for redeployment

**Video 7.** *In vitro* demonstration of the stages of device recapture

**Video 8.** Final fluoroscopic view showing the signs of device stability

**Video 9.** Final 3D TEE “en face” view of the device disk sealing the ostium of LAA

## References

1. Cammalleri V, Ussia GP, Muscoli S, De Vico P, Romeo F. Transcatheter occlusion of left atrial appendage with persistent thrombus using a trans-radial embolic protection device. *J Cardiovasc Med (Hagerstown)* 2016; 17 Suppl 2: e224.
2. Bellmann B, Rillig A, Leistner DM, Kasner M, Skurk C, Landmesser U, et al. Left atrial appendage closure in a patient with left atrial appendage thrombus using a novel fish ball technique. *Int J Cardiol* 2017; 234: 146-9.
3. Jalal Z, Iriart X, Dinat ML, Selly JB, Tafer N, Renou P, et al. Extending percutaneous left atrial appendage closure indications using the AMPLATZER™ Cardiac Plug device in patients with persistent left atrial appendage thrombus: The thrombus trapping technique. *Arch Cardiovasc Dis* 2016; 109: 659-66.
4. Martins JL, Paiva L, Costa M, Gonçalves L. Thrombus in left atrial appendage-Overcoming percutaneous closure limitations. *Rev Port Cardiol* 2018; 37: 269-70.
5. Lee OH, Kim JS, Pak HN, Hong GR, Shim CY, Uhm JS, et al. Feasibility of left atrial appendage occlusion for left atrial appendage thrombus in patients with persistent atrial fibrillation. *Am J Cardiol* 2018; 121: 1534-9.
6. Tarantini G, D'Amico G, Latib A, Montorfano M, Mazzone P, Fassini G, et al. Percutaneous left atrial appendage occlusion in patients with atrial fibrillation and left appendage thrombus: feasibility, safety and clinical efficacy. *EuroIntervention* 2018; 13: 1595-602.
7. Tzikas A, Gafoor S, Meerkin D, Freixa X, Cruz-Gonzalez I, Lewalter T, et al. Left atrial appendage occlusion with the AMPLATZER Amulet device: an expert consensus step-by-step approach. *EuroIntervention* 2016; 11: 1512-21.
8. Kawabata M, Goya M, Sasaki T, Maeda S, Shirai Y, Nishimura T, et al. Left atrial appendage thrombi formation in Japanese non-valvular atrial fibrillation patients during anticoagulation therapy-warfarin vs. direct oral anticoagulants. *Circ J* 2017; 81: 645-51.
9. Frenkel D, D'Amato SA, Al-Kazaz M, Markowitz SM, Liu CF, Thomas G, et al. Prevalence of left atrial thrombus detection by transesophageal echocardiography: A comparison of continuous non-vitamin k antagonist oral anticoagulant versus warfarin therapy in patients undergoing catheter ablation for atrial fibrillation. *JACC Clin Electrophysiol* 2016; 2: 295-303.

*This report was presented at the “Cardiovascular Innovations Meeting” held in Denver, USA from July 18-19 2019 and was awarded the winning prize in the “Challenging Case Competition”.*

**Address for Correspondence:** Dr. Şükrü Akyüz,  
Siyami Ersek Göğüs Kalp ve Damar Cerrahisi Hastanesi,  
Kardiyoloji Kliniği,  
İstanbul-Türkiye

Phone: +90 506 120 65 44

E-mail: [sukruakyuz@hotmail.com](mailto:sukruakyuz@hotmail.com)

©Copyright 2020 by Turkish Society of Cardiology - Available online at [www.anatoljcardiol.com](http://www.anatoljcardiol.com)

DOI:10.14744/AnatolJCardiol.2019.02222

