



Received: 2014.07.27
Accepted: 2014.09.09
Published: 2015.01.19

Central Nervous System Lymphoma in a 3-Year-Old Male Suffering from a Severe Juvenile Xanthogranuloma – the Usefulness of Perfusion Weighted Imaging and Diffusion Weighted Imaging in the Diagnostics of Pediatric Brain Tumors

Authors' Contribution:

- A** Study Design
- B** Data Collection
- C** Statistical Analysis
- D** Data Interpretation
- E** Manuscript Preparation
- F** Literature Search
- G** Funds Collection

Małgorzata Neska-Matuszewska^{1ABDEF}, Anna Zimny^{1ABDE}, Krzysztof Katwak^{2BD},
Marek J. Sasiadek^{1EF}

¹ Department of General and Interventional Radiology and Neuroradiology, Chair of Radiology, Wrocław Medical University, Wrocław, Poland

² Department of Pediatric Bone Marrow Transplantation, Oncology and Hematology, Wrocław Medical University, Wrocław, Poland

Author's address: Małgorzata Neska-Matuszewska, Department of General and Interventional Radiology and Neuroradiology, Chair of Radiology, Wrocław Medical University, Borowska 213 Str., 50-556 Wrocław, Poland, e-mail: neskamatuszewska@gmail.com

Summary

Background:

Primary Central Nervous System Lymphomas (PCNSLs) are rare, malignant brain tumors derived from lymphocytes B. Juvenile xanthogranuloma (JXG) is a non-Langerhans histiocytic cell disorder in children which mostly affects the skin. Rare fatalities have been reported in extracutaneous manifestation. Brain magnetic resonance imaging (MRI) is a method of choice in the diagnostics of all neoplastic CNS lesions. Perfusion weighted imaging (PWI) and diffusion weighted imaging (DWI) allow for more detailed analysis of brain tumors including the rate of neoangiogenesis and cellularity. We presented a pediatric patient suffering from JXG with CNS involvement and the role of brain MRI including DWI and PWI in the evaluation of brain focal lesions.

Case Report:

A 3-year-old male with severe JXG underwent two stem cell transplantations with a development of neurological complications. The patient underwent emergency CT and MRI which revealed a non-specific enhancing focal brain lesion. In DWI it showed restricted diffusion while PWI revealed low values of rCBV and the signal intensity curve returning above the baseline level. Advanced MRI techniques such as DWI and PWI suggested PCNSL. Stereotactic biopsy confirmed PCNSL due to Epstein-Barr virus reactivation.

Conclusions:

The use of advanced MRI sequences is important to differentiate brain lesions in pediatric patients. The use of PWI and DWI facilitated the diagnosis of PCNSL. It is important to remember that PCNSLs show a very typical pattern of changes visualized with MRI such as: usually strong homogenous enhancement, restricted diffusion and low perfusion.

MeSH Keywords:

Central Nervous System Neoplasms • Diffusion Magnetic Resonance Imaging • Lymphoma, B-Cell • Magnetic Resonance Angiography • Magnetic Resonance Imaging • Xanthogranuloma, Juvenile

PDF file:

<http://www.polradiol.com/abstract/index/idArt/892106>

Background

Primary Central Nervous System Lymphomas (PCNSLs) are relatively rare tumors of the central nervous system

(CNS) arising extranodularly in the absence of systemic lymphoma [1]. They comprise 6% of all CNS tumors and originate from lymphocytes B. Recently, their incidence has increased in immunocompetent patients though their

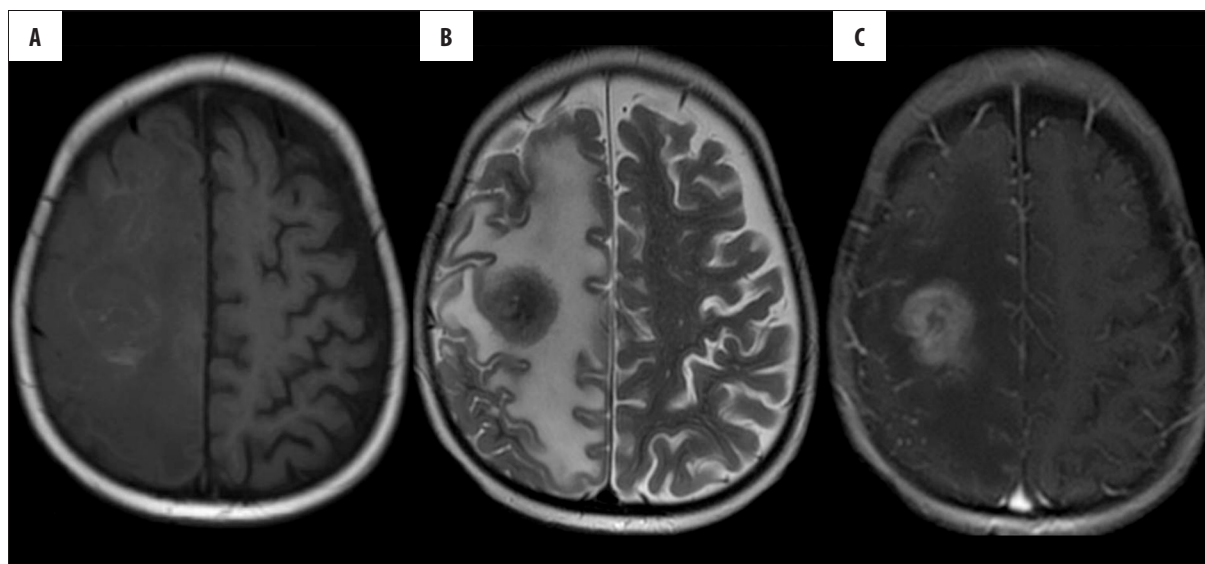


Figure 1. Primary central nervous system lymphoma. Plain MR images show a right fronto-parietal tumor: hypointense on the T1-weighted image, with small foci of hyperintense bleeding (A), with low signal within the tumor core and diffuse hyperintense surrounding edema on the T2-weighted image (B) and strong homogenous contrast enhancement on the T1-weighted post-contrast image (C).

prevalence is still higher in immunocompromised subjects (AIDS, transplantation, inherited immunodeficiency). Good but short response to steroids is characteristic with average survival period of 50 months. Biopsy is still necessary to make the final diagnosis [2].

Juvenile xanthogranuloma (JXG) is a non-Langerhans histiocytic cell disorder which mostly affects the skin. Other involvement is rare but the CNS is a well-recognized site of an extracutaneous manifestation [3,4]. JXG affects children, mostly in the first two years of life. The prognosis of JXG is generally good. Rare fatalities have been reported in children with CNS involvement. Poor-prognosis patients are treated with systemic chemotherapy, while resistant cases are followed by strong chemotherapy with subsequent bone marrow transplantation [5].

Brain magnetic resonance imaging (MRI) is a method of choice in the diagnostics of neoplastic or inflammatory CNS lesions. Advanced MRI techniques, such as perfusion weighted imaging (PWI) or diffusion weighted imaging (DWI) allow for more accurate analysis of these lesions including their microcirculation and diffusivity and thus more specific identification [6–12].

We presented a case report of a pediatric patient suffering from JXG with CNS involvement and the role of brain MRI including DWI and PWI in the evaluation of a brain focal lesion of uncertain origin.

Case Report

A 3-year-old male with severe JXG in the form of multiple cutaneous lesions and bone marrow infiltration had been hospitalized and treated since his 4 months of life. He underwent three different programs of systemic treatment and two allogenic stem cell transplantations in a 6-month interval. The second transplantation contributed to a development of an acute type of graft-versus-host

disease. General symptoms such as post-steroid hypertension, iatrogenic Cushing's syndrome, mucositis and axonal polyneuropathy were additional drug-induced complications. The patient also started to suffer from myoclonic seizures spreading into the left leg and left bulbus which were interrupted after the administration of clonazepam and dexaven. The patient presented no changes in the primary multiple cutaneous manifestation of JXS. Because of the neurological symptoms and a suspicion of JXS dissemination the patient underwent emergency unenhanced CT of the head which revealed a right fronto-parietal, slightly hyperdense tumor surrounded by an extensive vasogenic edema. Shortly after head CT, MRI examinations of the head as well as of the cervical, thoracic and lumbar spine were performed.

All brain MRI examinations were performed under general anesthesia with a 1.5 T MRI scanner (Signa Hdx, GE Medical Systems) using a 16-channel HNS (head-neck-spine) coil. Before contrast administration a standard plain MRI examination was carried out including T1-weighted axial images, T2-weighted axial, coronal and sagittal images as well as FLAIR axial images and transverse single-shot echo-planar diffusion-weighted imaging (b value=0 and 1000 mm²/s, slice thickness: 5 mm, duration: 40 seconds). Subsequently, PWI with Dynamic Susceptibility Contrast Enhanced method (DSC) was performed using fast echo-planar T2-weighted gradient echo sequence (contrast medium intravenous injection: 0.2 mmol/kg of body weight, speed: 3 mL/second, duration: 1 minute and 26 seconds). Finally, a post-contrast T1-weighted 3D sequence, based on the contrast administered earlier for the perfusion examination, was performed.

The postprocessing was performed on an AW 4.4 workstation (GE Healthcare) and involved evaluation of ADC values on ADC maps and values of Cerebral Blood Volume (CBV) on CBV maps as well as the shape of perfusion signal-intensity curves.

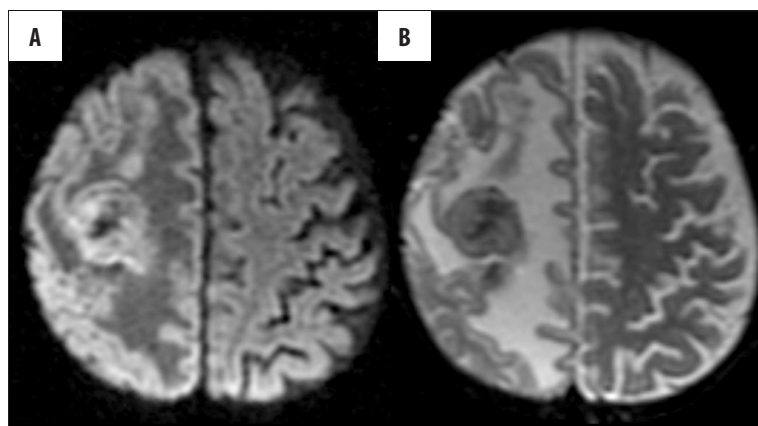


Figure 2. Primary central nervous system lymphoma showing diffusion restriction on the DWI image (A) and the ADC map (B).

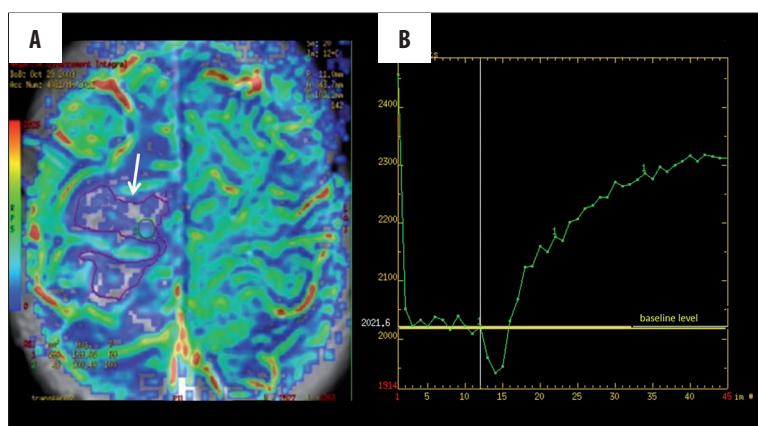


Figure 3. Primary central nervous system lymphoma showing hypoperfusion within the tumor core (outlined in violet, white arrow) on the CBV map overlaid on the contrast-enhanced T1-weighted image (A) and characteristic shape of the signal intensity curve (B) returning above the baseline level.

Standard brain MRI showed a slightly heterogeneous mass, $3.8 \times 4.6 \times 3.2$ cm in size, in the right fronto-parietal location. The lesion was mostly hypointense on T1-weighted images with hyperintense areas of subacute bleeding (Figure 1A). T2-weighted and FLAIR images revealed low signal with significant hyperintense vasogenic edema in the surrounding white matter (Figure 1B). The tumor showed strong homogenous contrast enhancement (Figure 1C). In DWI the lesion showed restricted diffusion (high signal on DWI images and low signal on ADC maps) with ADC values of 0.67×10^{-3} for the whole tumor and minimal ADC value of 0.51×10^{-3} (with normal ADC values of approx. $0.7-0.75 \times 10^{-3}$) (Figure 2). PWI study revealed low values of CBV relative to the contralateral white matter with mean rCBV values of 0.43 for the whole tumor core and 0.79 of maximal rCBV (Figure 3A). The signal intensity curve from the tumor core showed a characteristic shape with the return above the baseline level (Figure 3B).

The MRI examinations of the cervical, thoracic and lumbar spine were normal. On the basis of typical MRI, DWI/ADC and PWI pattern the radiological diagnosis of PCNSL was suggested. Ten days later a stereotactic biopsy of the brain lesion was performed to establish the final diagnosis. Histopathological examination confirmed the diagnosis of PCNSL due to reactivation of Epstein-Barr virus (CNS-EBV-PTLD: Central Nervous System Epstein-Barr Virus Post Transplant Lymphoproliferative Disorder).

Discussion

Differential diagnosis of our patient was complicated by JXS dissemination and systemic complications after two allogeneic stem cell transplantations. One of the most possible causes of CNS changes in respect of the main disease was histiocytic infiltration in the course of JXS.

CNS changes in JXG are secondary to the skin, soft tissues, lung or pancreas. They may appear as simple or multiple granulomas, originating from mesenchymal stem cells of the dura, from the intracerebral perivascular tunica vaginalis or from the wall of brain vessels themselves. Intracranial, dural-based lesions are more frequent than leptomeningeal or spinal spread. It is difficult to differentiate this kind of lesions from a meningioma, glioma, ependymoma or schwannoma only on the basis of plain MRI examination [4]. Dural infiltration and the close relation of the tumor to CSF may also suggest lymphoma or leukemia [13]. CNS lesions in the course of JXG usually demonstrate high signal on T2-weighted and low signal on T1-weighted images with contiguous dural enhancement, without edema. On the basis of this knowledge the focal intracerebral lesion found in our patient was excluded to be of histiocytic origin. It has to be stressed that there are no reports in the literature concerning the use of advanced MRI techniques in the evaluation of JXG foci.

In the majority of cases (60–80%) PCNSLs are located in deep structures: periventricularly, in the basal ganglia region or in the corpus callosum. They tend to appear

along ependymal surfaces. They may also be located more peripherally at the gray-white matter junction within the frontal, temporal or parietal lobes. Morphologically, the PCNSL foci are usually seen as multiple infiltrating lesions and less frequently as solitary, well circumscribed tumors. PCNSLs typically present strong homogenous enhancement after contrast injection. PCNSLs are highly cellular tumors with high nuclear/cytoplasmic ratio which results in characteristic hyperdense appearance of these lesions on unenhanced CT images and low signal on T2-weighted MR images [2]. PCNSL lesions are usually surrounded by mild edema. In immunocompromised patients the PCNSL lesions tend to be more heterogeneous with foci of bleeding, necrosis and heterogeneous enhancement [2].

In our patient, plain MRI examination indicated a peripherally located, solitary, strongly enhancing tumor surrounded by massive vasogenic edema, with low signal on T2-weighted images and slight bleeding. The lesion was hyperdense on unenhanced CT images. PCNSL was taken into consideration but other types of malignant tumors had to be excluded, therefore it was important to extend the MRI protocol by DWI and PWI techniques. These advanced techniques give additional information about tumor structure, cellularity and microvascularization. Different brain tumors such as PCNSLs, gliomas or metastases show various patterns of perfusion and diffusion changes which enables their differentiation [6-8].

DWI is a method that evaluates water diffusion in the extracellular space. The results of this examination are DWI images and apparent diffusion coefficient (ADC) maps. It is a relatively short (1-5 minutes) sequence which does not require contrast administration. Generally, homogeneous diffusion restriction (high signal on DWI images and low signal on ADC maps) is characteristic of highly cellular tumors such as PCNSLs [9], which was also observed in the case of our patient. On the contrary, high-grade gliomas (HGGs) or metastases show only small areas of diffusion restriction corresponding with the most cellular and thus the most malignant parts of the tumor core [9].

PWI is an advanced MRI technique that enables measurements of cerebral hemodynamics at the capillary level. The dynamic susceptibility contrast (DSC) MRI technique is most widely used. It is based on MRI signal calculations evaluated from T2-weighted sequences, after the first contrast passage through the microcirculation [14]. On the basis of these calculations, parametric maps of Cerebral Blood Volume (CBV) and perfusion curves are created. In tumors, the CBV parameter is measured within the lesion and normalized to the CBV parameter from the normal-appearing white matter of the contralateral hemisphere (rCBV) [5,10]. According to the literature, rCBV values correlate with the density of tumor vascularization and are elevated in lesions with increased pathological neoangiogenesis and increased malignancy such as high-grade gliomas and metastases [15]. The perfusion curves after contrast passage are created from the outlined regions of interest (ROIs) and in malignant tumors such as HGGs or

metastases do not reach the baseline [6]. PCNSLs present a typical perfusion pattern such as hypoperfusion and the characteristic shape of the signal intensity curves returning above the baseline level [6] which was also found in the case of our patient.

Since hypoperfusion can be explained with hypovascularization and absence of neoangiogenesis in lymphomas, the exact explanation of the signal intensity curves returning above the baseline level is difficult and not fully understood. It is probably due to gadolinium extravasation into the interstitial space and complex T1 and T2 effects which can alter the shape of the perfusion curve. The T2 effects lead to lower signal-intensity recovery while T1 effects cause higher signal-intensity recovery. In lymphomas the T1 effects, probably due to an extensive accumulation of contrast material in the interstitial space, dominate over the T2 effects and cause the characteristic overshooting from baseline [6]. However, so far, no definite explanation has been available for overshooting in lymphomas and this phenomenon is probably caused by several factors and a complex interplay between them [6].

Furthermore, DSC-PWI in pediatric patients seems to be problematic since it requires a relatively high rate of contrast administration through small veins. Administration of contrast in a dose of 0.1-0.2 mmol/kg of body weight at a rate of 3-4 mL/s is reported to be a safe procedure in children [16]. In our case we performed DSC perfusion using 0.2 mmol/kg of body weight with a speed of 3 mL/s which was well tolerated by the patient. In children under 2 years of age power injector is often not feasible. In these cases a hand injection is recommended but the image quality and reproducibility may be significantly degraded [16].

On the basis of the evaluation of all MRI sequences including DWI and PWI, a final radiological diagnosis of PCNSL was suggested. The stereotactic biopsy revealed PCNSL due to EBV reactivation (CNS-EBV-PTLD). According to the literature, EBV is the most common cause of PCNSL in immunosuppression, reported in up to 95% of patients.

Conclusions

The analysis of standard MRI sequences was not sufficient to diagnose our patient. Broad differential diagnosis and complications after bone marrow transplantation also made final diagnosis difficult. Therefore, in our opinion, the use of advanced MRI sequences is important to differentiate brain lesions in pediatric patients as well. In our patient, the use of PWI and DWI facilitated the diagnosis of PCNSL. It is important to remember that PCNSLs show a very typical pattern of changes visualized with MRI, such as: usually strong homogenous enhancement, restricted diffusion and low perfusion.

In our opinion, advanced MRI techniques should be routinely used in the diagnostics of brain focal lesions of uncertain origin.

References:

1. Hartel M, Kluczevska E: New CNS tumours in WHO Classification. Comments to the article "The New World Health Organization Classification of Central Nervous System Tumours: What Can the Neuroradiologist Really Say?". *Pol J Radiol*, 2012; 77(3): 79–80
2. Salzman KL: Primary CNS Lymphoma. In: Osborn AG, Salzman KL, Barkovich AJ (eds.) *Diagnostic imaging: Brain*. 2nd ed. Salt Lake City: Amirsys, 2010; 1-6: 150–53
3. Freyer DR, Kennedy R, Bostrom BC et al: Juvenile xanthogranuloma: forms of systemic disease and their clinical implications. *J Pediatr*, 1996; 129: 227–37
4. Sun LP, Jin HM, Yang B, Wu XR: Intracranial solitary juvenile xanthogranuloma in an infant. *World J Pediatr*, 2009; 5(1): 71–73
5. Meshkini A, Shahzadi S, Zali A et al: Systemic juvenile xanthogranuloma with multiple central nervous system lesions. *J Cancer Res Ther*, 2012; 8(2): 311–13
6. Mangla R, Kolar B, Zhu T et al: Percentage of signal recovery derived from MR dynamic susceptibility contrast imaging is useful to differentiate common enhancing malignant lesions of the brain. *Am J Neuroradiol*, 2011; 32(6): 1004–10
7. Cha S, Lupo JM, Chen MH et al: Differentiation of glioblastoma multiforme and single brain metastasis by peak height and percentage of signal intensity recovery derived from dynamic susceptibility-weighted contrast-enhanced perfusion MR imaging. *Am J Neuroradiol*, 2007; 28: 1078–84
8. Sugahara T, Korogi Y, Kochi M et al: Usefulness of diffusion-weighted imaging with echo-planar technique in the evaluation of cellularity in gliomas. *J Magn Reson Imaging*, 1999; 9: 53–60
9. Guo AC, Cummings TJ, Dash RC et al: Lymphomas and high-grade astrocytomas: comparison of water diffusibility and histologic characteristics. *Radiology*, 2002; 224: 177–83
10. Zimny A, Sasiadek M: Contribution of perfusion-weighted magnetic resonance imaging in the differentiation of meningiomas and other extra-axial tumors: case reports and literature review. *J Neurooncol*, 2011; 103(3): 777–83
11. Wieczorek-Pastusiak J, Kociński M, Raźniewski M et al: An attempt toward objective assessment of brain tumor vascularization using susceptibility weighted imaging and dedicated computer program – a preliminary study. *Pol J Radiol*, 2013; 78(1): 50–56
12. Muccio C, Di Blasi A, Esposito G et al: Perfusion and spectroscopy magnetic resonance imaging in a case of lymphocytic vasculitis mimicking brain tumor. *Pol J Radiol*, 2013; 78(3): 66–69
13. Tamir I, Davir R, Fellig Y et al: Solitary juvenile xanthogranuloma mimicking intracranial tumor in children. *J Clin Neurosci*, 2013; 20(1): 183–88
14. Rosen B, Belliveau J, Vevea J et al: Perfusion imaging with NMR contrast agents. *Magn Reson Med*, 1990; 14: 249–65
15. Aronen HJ, Gazit IE, Louis DN et al: Cerebral blood volume maps of gliomas: comparison with tumor grade and histologic findings. *Radiology*, 1994; 191: 41–51
16. Madan N, Grant PE: MR perfusion imaging in pediatrics. In: Barker PB, Golay X, Zaharchuk G (eds.). *Clinical Perfusion MRI: Techniques and Applications*. Cambridge: Cambridge University Press, 2013; 326–44