


# Non-pneumophila *Legionella* species pneumonia with orange-coloured sputum

Maki Asami-Noyama<sup>1</sup>  | Misa Harada<sup>1</sup> | Kaori Murakawa<sup>2</sup> | Junki Suizu<sup>1</sup> | Keita Murakawa<sup>1</sup> | Ayumi Chikumoto<sup>1</sup> | Kazuki Hamada<sup>1</sup> | Yoriyuki Murata<sup>1,2</sup> | Keiji Oishi<sup>1,2</sup> | Yoshikazu Yamaji<sup>1</sup> | Nobutaka Edakuni<sup>1</sup> | Tsunahiko Hirano<sup>1</sup> | Tomoyuki Kakugawa<sup>3</sup> | Kazuto Matsunaga<sup>1</sup>

<sup>1</sup>Department of Respiratory Medicine and Infectious Disease, Graduate School of Medicine, Yamaguchi University, Ube, Japan

<sup>2</sup>Division of Cardiology, Department of Medicine and Clinical Science, Graduate School of Medicine, Yamaguchi University, Ube, Japan

<sup>3</sup>Department of Pulmonary and Gerontology, Graduate School of Medicine, Yamaguchi University, Ube, Japan

## Correspondence

Maki Asami-Noyama, Department of Respiratory Medicine and Infectious Disease, Graduate School of Medicine, Yamaguchi University, 1-1-1 Minami-Kogushi, Ube, Yamaguchi, 755-8505, Japan.

Email: noyamama@yamaguchi-u.ac.jp

Associate Editor: Michael Maze

## Abstract

We herein report an immunocompromised patient familiar with gardening admitted to our hospital suffering from severe pneumonia caused by *Legionella longbeachae*. We suspected non-pneumophila *Legionella* species pneumonia because of gardening habits, the negative urine antigen test and the non-significant Gram staining results of orange-coloured sputum. The pathogen was identified using mass spectrometry analysis of bronchoalveolar lavage fluid. It is important to perform the medical interview carefully, noting the colour of sputum and gardening habits, for diagnosis and targeted therapy of non-pneumophila *Legionella* species pneumonia, even if the urine *Legionella* antigen test is negative.

## KEYWORDS

*Legionella longbeachae*, orange-coloured sputum, pneumonia

## INTRODUCTION

As the urine antigen test cannot detect *Legionella* species other than *Legionella pneumophila* serogroup 1 species, it is expected that some cases may not be diagnosed precisely. In this case, we suspected non-pneumophila *Legionella* species pneumonia based on the negative urinary antigen test, orange sputum and medical history of using potting soil, and could make a diagnosis by mass spectrometry of bronchoalveolar lavage (BAL) fluid (BALF).

## CASE REPORT


A 66-year-old woman presented to the emergency department with complaints of shortness of breath and chest pain for the preceding 2 days.

She had a history of rheumatoid arthritis (RA) and systemic lupus erythematosus (SLE), taking oral prednisolone (6 mg/day) and hydroxychloroquine (200 mg/day). She was a housewife and frequently worked with potting soils in her garden. She also had orange-coloured sputum (Figure 1A). Her vital signs upon admission were as follows: temperature, 36.1°C; blood pressure, 109/69 mmHg; pulse rate, 111 beats/min; respiratory rate, 30/min; and oxygen saturation, 96% on 9 L/min of oxygen mask with reservoir bags. She had clear consciousness. She had coarse crackles bilaterally.

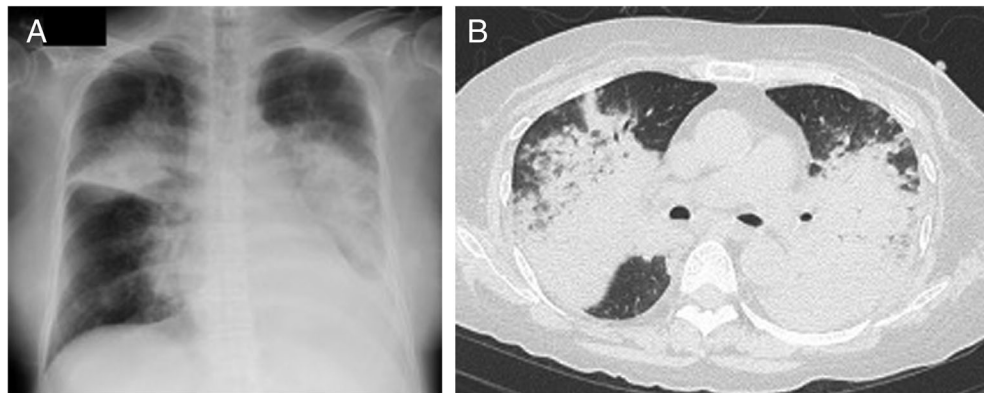
Laboratory findings were as follows: white blood cell count 30,510/ $\mu$ l (neutrophils 99.5%), haemoglobin 10.1 g/dl, platelet count  $5.0 \times 10^4$ / $\mu$ l, lactate dehydrogenase 341 U/L, urea nitrogen 30 mg/dl, creatinine 1.21 mg/dl and C-reactive protein 41.06 mg/dl. Blood gas analysis showed the following: pH 7.397, pCO<sub>2</sub> 34.4 torr, pO<sub>2</sub> 46.5 torr and HCO<sub>3</sub><sup>-</sup> 21.8 mEq/L (with room air).

This is an open access article under the terms of the Creative Commons Attribution-NonCommercial License, which permits use, distribution and reproduction in any medium, provided the original work is properly cited and is not used for commercial purposes.

© 2021 The Authors. *Respirology Case Reports* published by John Wiley & Sons Australia, Ltd on behalf of The Asian Pacific Society of Respirology.



**FIGURE 1** (A) Orange-coloured sputum is observed. (B) Orange-coloured bronchoalveolar lavage fluid is observed



**FIGURE 2** (A) Chest x-ray findings of a patient is showing extensive consolidation in the upper and middle lung fields bilaterally. (B) Chest computed tomography findings of the same patient. Bilateral consolidation is observed

Her chest x-ray showed consolidation in the upper and middle lung fields bilaterally (Figure 2A). Computed tomography (CT) of the chest showed consolidation of the right upper, middle and lower lobes and the left upper, and atelectasis of the left lower lobe (Figure 2B). Sputum Gram stain showed very few epithelial cells and some neutrophils, but not satisfactory to estimate causative bacteria. Both the BinaxNOW™ pneumococcal and *Legionella* urinary antigen test (Abott) were negative.

We suspected severe pneumonia and started with intravenous levofloxacin (500 mg q24h) and meropenem (500 mg q6h) empirically. Given her history of RA and SLE, and immunosuppressive state, we thought that viral/fungal infections, alveolar haemorrhage and interstitial pneumonia were important differential diagnoses. Thus, she underwent BAL by bronchoscopy under intubation. The colour of BALF was also orange (Figure 1B) and the cellular pattern was neutrophil predominant (90.0%) suggestive of bacterial infection. But, Gram stain of the BALF results was negative.

Cytology of BALF revealed numerous neutrophils and a few macrophages which were not hemosiderin-laden. Because it has been clinically suggested that the colour of sputum obtained from patients with pneumonia caused by *L. pneumophila* is orange, we suspected non-pneumophila *Legionella* species pneumonia. We switched meropenem to azithromycin (500 mg q24h) and increased levofloxacin to maximum dose (750 mg q24h) targeting *Legionella* species pneumonia. Acid-fast bacillus cultures of sputum resulted negative. Two sets of blood cultures were negative. Polymerase chain reactions (PCR) for *Pneumocystis*, cytomegalovirus and SARS-CoV-2 were all negative. On the fifth day, mass spectrometry analysis of colonies obtained by culturing in BCYE $\alpha$  medium from BALF identified the presence of *Legionella longbeachae*.

On the sixth day, her respiratory condition deteriorated and contrast-enhanced CT showed exacerbation of ground-glass opacity (GGO) without pulmonary thromboembolism. We suspected organizing pneumonia secondary to

*L. longbeachae* and started high-dose pulse intravenous steroid treatment with 1 g methylprednisolone for 3 days followed by prednisolone 1 mg/kg (60 mg/day) alongside levofloxacin that was administered 21 days in total. The following days she recovered gradually and she was extubated on Day 12. Eventually, consolidation and GGO improved on her chest CT of Day 23 and she was discharged home without oxygen on Day 34.

## DISCUSSION

*L. longbeachae* was first isolated in 1980 from a patient with pneumonia in Long Beach, California, USA.<sup>1</sup> *L. longbeachae*, found in soil and compost-derived products, is a globally underdiagnosed cause of legionellosis.<sup>2</sup> Isolation by sputum culture confirms the diagnosis, but it is difficult to obtain high-quality sputum. The molecular methods such as PCR are valuable in diagnosing *Legionella* infections. The *Legionella* Reference Center in Japan collected 427 *Legionella* clinical isolates between 2008 and 2016, which included 419 *L. pneumophila* and only three *L. longbeachae* isolates.<sup>3</sup>

The major source of human infection is considered to be commercial potting soil.<sup>4</sup> With regard to *L. longbeachae* infection, a case-control study of *L. longbeachae* Legionnaires' disease in New Zealand highlights chronic obstructive pulmonary disease, smoking and exposure to compost or potting mix as risk factors.<sup>2</sup> Gardening behaviours were strongly associated with *L. longbeachae* infection including having unwashed hands near the face after exposure to or tipping and trowelling compost or potting mix.<sup>2</sup>

It has been described that the colour of sputum from *L. pneumophila* pneumonia is orange.<sup>5</sup> The mechanism by which *L. pneumophila* produce the orange-coloured sputum is thought to involve tyrosine included in the epithelial lining fluid.<sup>5</sup> For the first time, this report showed that the orange-coloured sputum is also an important clinical sign in *L. longbeachae* infection. However, neither sensitivity nor specificity can be estimated. Therefore, it may only be a trigger for diagnosis.

In conclusion, the medical interview about recent gardening activity and exposure to compost or potting mix are very important for the diagnosis of *L. longbeachae*

pneumonia. In addition, orange-coloured sputum may be another clue that prompts specific testing.

## CONFLICT OF INTEREST

None declared.

## ETHICS STATEMENT

Appropriate written informed consent was obtained for publication of this case report and accompanying images.

## AUTHOR CONTRIBUTIONS

All authors contributed to the patient's therapy and this submission. All authors contributed to the conception and interpretation of the work and drafting and revision of the work.

## ORCID

Maki Asami-Noyama  <https://orcid.org/0000-0001-5218-6132>

## REFERENCES

1. McKinney RM, Porschen RK, Edelstein PH, Bissett ML, Harris PP, Bondell SP, et al. *Legionella longbeachae* species nova, another etiologic agent of human pneumonia. *Ann Intern Med.* 1981;94:739–43.
2. Kenagy E, Priest PC, Cameron CM, Smith D, Scott P, Cho V, et al. Risk factors for *Legionella longbeachae* Legionnaires' disease, New Zealand. *Emerg Infect Dis.* 2017;23:1148–54.
3. Amemura-Maekawa J, Kura F, Chida K, Ohya H, Kanatani JJ, Isobe J, et al. *Legionella pneumophila* and other *Legionella* species isolated from legionellosis patients in Japan between 2008 and 2016. *Appl Environ Microbiol.* 2018;31:e00721–18.
4. Whiley H, Bentham R. *Legionella longbeachae* and legionellosis. *Emerg Infect Dis.* 2011;17:579–83.
5. Fujita J, Touyama M, Chibana K, Koide M, Haranaga S, Higa F, et al. Mechanism of formation of the orange-colored sputum in pneumonia caused by *Legionella pneumophila*. *Intern Med.* 2007;46:1931–4.

**How to cite this article:** Asami-Noyama M, Harada M, Murakawa K, Suizu J, Murakawa K, Chikumoto A, et al. Non-pneumophila *Legionella* species pneumonia with orange-coloured sputum. *Respirol Case Rep.* 2021;9:e0814. <https://doi.org/10.1002/rccr.2.814>