



MINI REVIEW

Hepatitis C virus and non-Hodgkin's lymphomas: A minireview

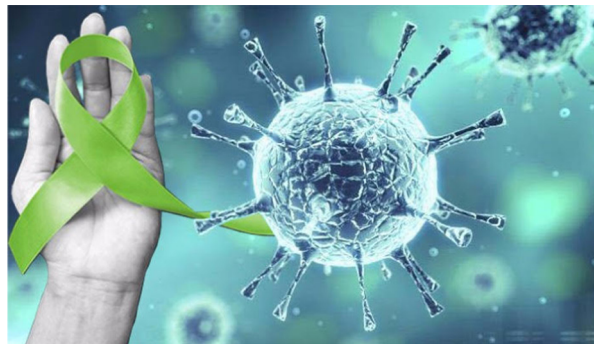


Hussein Khaled^{a,*}, Fouad Abu-Taleb^b, Rasha Haggag^b

^a Medical Oncology Department, National Cancer Institute, Cairo University, Cairo 11796, Egypt

^b Medical Oncology Department, Faculty of Medicine, Zagazig University, Zagazig 44519, Egypt

GRAPHICAL ABSTRACT



Malignant lymphomas and HCV infection have a dual relationship.

ARTICLE INFO

Article history:

Received 31 August 2016
Received in revised form 28
November 2016
Accepted 30 November 2016
Available online 12 December 2016

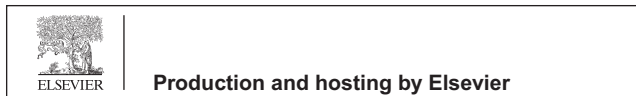ABSTRACT

B-cell NHL is strongly associated with HCV that was proved in the last 2 decades. The most common HCV infection related B-NHL subtypes include MZL and DLBCL lymphomas. HCV-positive NHL patients usually present with older age at diagnosis, higher LDH, and more extranodal disease. The standard chemo-immunotherapy tolerance is generally good. Antiviral treatment achieves virological and hematological remission in HCV associated indolent lymphoma. More aggressive lymphoma requires combination of antiviral treatment and chemotherapy. New generation of HCV antiviral drugs is safe and is highly efficacious. Regi-

* Corresponding author.

E-mail address: khussein528@gmail.com (H. Khaled).

Peer review under responsibility of Cairo University.



Keywords:

Hepatitis C virus
 Non-Hodgkin lymphoma
 Pathogenesis
 Antiviral treatment

mens including DAAs appear promising options as they can reduce the HCV-associated NHL incidence by dramatically lowering the HCV chronic carriers.

© 2016 Production and hosting by Elsevier B.V. on behalf of Cairo University. This is an open access article under the CC BY-NC-ND license (<http://creativecommons.org/licenses/by-nc-nd/4.0/>).



Dr. Hussein Khaled is a Professor of medical oncology at the National Cancer Institute of Cairo University. He was the former minister of higher education of Egypt (2012), former vice president of Cairo University for post graduate studies and research (2008–2011), and the former dean of the Egyptian National Cancer Institute (2002–2008). In 2015, he won the State Recognition Prize for advanced technological sciences in the medical field. His research activities are focused mainly on

bladder cancer (both biologic and clinical aspects), breast cancer, and malignant lymphomas, with more than 150 national and international publications (total impact factor of 470, total citations of 1741, and *h*-index of 22).



Dr. Fouad Abu-Taleb is a Professor and head of Medical Oncology Department, Zagazig University. He is an ASCOA certified ESMO member (5 times), and a member of the Egyptian Universities Promotion Committees (EUPC, Committee number 83). He has more than 50 national and international publications and national educational presentations and international posters in ASCO, and ESMO, and ICACT.



Dr. Rasha Haggag is an Assistant Professor of medical oncology at Medical Oncology Department, Zagazig University. She had finished ESMO-MORA recertification (2015–2020) and she is a member of ASCO, EASO, BCGC, EHO, and Cure & More research group. Also, she serves as an editor in *Advances in Oncology Research and Treatments* journal, *Journal of Unexplored Cancer Data* and *Cancer therapy & Oncology International Journal*. She has more than 30 national and international publications.

Epidemiology

HCV is a hepatotropic, lymphotropic virus affecting over 180 million people, all over the world by chronic infection [1,2]. HCV infection usually results in chronic hepatitis leading to liver cirrhosis and hepatocellular carcinoma (HCC) in many patients [3]. In Egypt, the prevalence rate of HCV infected individuals was 872,000 (15% of the population) in 2013, with an estimated incidence of newly infected 125,000 viremic individuals each year [4], the rate which is considered as one of the highest prevalence rates of HCV worldwide [5,6]. HCV posi-

tive NHL patients' prevalence ranged from 0.5% to 25% as published by many series [7], while HCV infected NHL ranged from 26 to 42.1% in several Egyptian studies [8–11].

Route of HCV transmission

It is reported that the most common route of transmission among young population is drug use while the iatrogenic transmission was the predominant route in elder population in Northern countries and Southern countries, respectively [12]. In Egypt, high levels of HCV transmission was reported after parenteral anti-schistosomiasis treatment 3 decades before [13], but nowadays nosocomial route of transmission is the most predominant [14].

The relation between HCV and B-NHL

Large epidemiological studies had strengthened HCV and B-NHL link. In a systematic review published by Gisbert et al. the prevalence of HCV infection in B-NHL was identified in 5542 patients in 48 studies with a mean HCV infection rate of 13%. In another 10 case-control series, HCV prevalence in B-NHL was 17% compared to 1.5% in healthy controls. Therefore, HCV prevalence in patients with B-NHL was observed to be higher than the general population, denoting the role for HCV in of B-NHL etiology [15]. Subsequently, a meta-analysis of 15 studies on the relation between HCV infection and NHL demonstrated a collective relative risk of lymphoma of 2.5 (CI: (95%), 2.1–3.1) among HCV-infected subjects in 2006 [16]. The International Lymphoma Epidemiology Consortium (InterLymph) study reported collective results of HCV associate B-NHL. The study included more than eleven thousand subjects (6269 controls and 4784 cases) from 7 case-control studies conducted in the United States, Europe, and Australia. Among NHL cases, 172 (3.6%) had positive HCV infection versus 169 (2.7%) in controls (OR = 1.8; CI, 1.4–2.3). Thus overall, several studies have shown that HCV infection plays an important role in the development of definite subtypes of B-NHL indicating that genetic and environmental factors together with local HCV prevalence may be responsible for the geographically related results [17,18].

Common features of HCV associated B-NHL are extended duration of infection (15 years) and more frequent extranodal disease presentation. The most commonly reported B-NHL subtypes in different studies were marginal zone lymphoma, particularly splenic zone lymphoma, lymphoplasmacytic lymphoma, and DLBCL [19]. On the other hand, another study reported that DLBCL (62%) is the most common HCV related B-NHLs, followed by follicular lymphoma (13%) and MZL (11%) [20]. In Egyptian population, the relationship between chronic HCV infection and B-cell NHL was proved by Goldman et al. who conducted a case-control study at the NCI,

Cairo University. NHL cases (486 patients) were compared to controls ($n = 786$). The most common subtypes were of DLBCL (54.9%), followed by chronic lymphocytic leukemia (11.9%), follicular lymphoma (6.3%), T cell lymphoma, and mantle cell lymphoma (6.6%). HCV infection was positive in 27% of controls vs. 26–48% of NHL subgroups, with a significant association with diffuse large B cell, follicular lymphomas, and marginal zone ($P < 0.001$) [21].

Abu-Taleb et al. conducted a study that included 57 B-cell NHL patients with no previous chemotherapy. Fourteen patients (24.5%) had an indolent and 43 patients (75.4%) had an aggressive NHL. HCV infection was detected in 24 patients. Most of the patients with HCV infection (75%) presented with advanced stage (III/IV) compared to 42.5% among HCV negative cases (p -value = 0.09), and no statistically significant difference regarding age, sex, clinical presentation, stage, IPI score, PS status, LDH level, pathological type, or chemotherapy type was observed between the two groups [11].

Mechanisms of HCV-related lymphomagenesis

HCV is a single stranded RNA virus. HCV nucleic acid sequence integration into the host genome seems improbable due to the absence of reverse transcriptase. So, it can exert its oncogenic role indirectly by modulating of the host immune system [22]. Three possible theories can explain the process of HCV transformation including the following: (1) the external lymphocyte receptors are continuously stimulated by the viral antigen resulting in its proliferation; (2) replication of HCV occurs inside the B cells and then mediate their oncogenic effects through intracellular HCV proteins; and (3) “hit and run” theory which means permanent damage of B-cell, caused by the intracellular virus (e.g., mutation of tumor suppressor genes) [23].

Zekri et al. studied the NHL cases associated with HCV infection gene expression profile using c-DNA microarray. They studied 15,500 genes, out of which more than 1000 genes were differentially expressed either unregulated or down regulated. Also, HCV might rescue B lymphocytes from apoptosis, possibly through suppression of CASP1 and CASP4 and the anti-apoptotic BCL2 gene over expression. The genes such as BAL and MLLT3, which are myeloid/lymphoid leukemia and B cell lymphoma related were associated with HCV, that could influence the over expression of transcription regulator genes as TATA box binding protein (TBP) and may also influence the over expression of some immunoglobulin genes as immunoglobulin super family containing leucine gene in B cells resulting in overproduction of immunoglobulins in B-lymphocyte disorders. Moreover HCV was associated with MHC class II molecule reduced expression in B lymphocytes, and thus may result in inhibition of processing and presentation of the antigen through down regulation of different MHC class II molecule genes [24].

The chronic antigenic stimulation of HCV infection to the immune system is very similar to *Helicobacter pylori* pathogenesis in gastric MALT lymphoma as after *H. pylori* infection, and there is production of T cell-dependent responses through the classic reaction of germinal center, and consequently generates reactive B and T cells. Then, *H. pylori*-specific T cells start to migrate to the marginal zone/tumor area providing

non-related help to autoreactive neoplastic B cells involved in stimulation of CD40 and other surface receptors by cytokines and soluble ligands [25,26]. The possible role of proteins of the HCV envelope was studied which focused mainly on the HCV E2 protein (Fig. 1). E2 had been shown to interact with the tetraspanin CD81, which is also present on the B-cell surface. This binding causes lowering of the threshold and the B-cell activation thus causes sustained polyclonal B-cell activation [27,28].

Mixed cryoglobulinemia is a low-grade B cell clonal lymphoproliferative disorder that initially confined to the bone marrow and then transforms to aggressive malignant lymphoma in about 10% to 20% of patients after several years of diagnosis. Mixed cryoglobulinemia had been found to be closely related to HCV infection. Additionally, chromosomal aberrations may play a role in HCV-related lymphoproliferative disorders. The translocation of (14;18) was the most investigated genetic aberration that was found to be significantly related to type II or monoclonal MC [29]. The presence of t (14;18) translocation in mixed cryoglobulinemia was correlated with the antiapoptotic bcl-2 gene over expression in B-cells, that results in an imbalance of the Bcl-2/Bax ratio and abnormal survival of B-cell survival [30,31]. In many interventional studies, low-grade HCV-related NHL regression can occur with sustained virological response (SVR) to anti-viral treatment (AVT). Also the recurrence of lymphoma happened with the virus recurrence [32,33]. The involvement of some cancer-related and newly identified miRNAs, namely miR-155, miR-146a, miR-21 and miR26b has been confirmed in the pathogenesis of different subtypes of lymphomas including some HCV-related ones (MZL and DLBCL) [34–36] (Fig. 1) [37].

Treatment of HCV-associated B-cell NHL

Treatment of HCV-associated B-cell NHL remains to be optimized. Testing of serum antibody should be used first to assess exposure to HCV infection. Those patients who are seropositive should then be tested for HCV RNA to determine their viral load. Patients having the different subtypes of indolent NHL and HCV seropositivity, where there is no urgent need to start anti lymphoma therapy may benefit from starting with antiviral treatment as demonstrated in various publications [38–42].

In a large multicenter retrospective study, antiviral therapy with interferon \pm ribavirin as a first line antiviral induced clearance of HCV-RNA in 80% of the patients (80/100) and in 67% (22/34) of the patients in whom AVT was received as second line [40]. In addition, lymphoma regression was occurred in large proportion of patients who received initial treatment with interferon \pm ribavirin.

The addition of monoclonal antibodies to the classic front-line treatment of aggressive NHL CHOP regimen (cyclophosphamide, doxorubicin, vincristine, and prednisone) had improved the lymphoma outcome. Rituximab plus CHOP (RCHOP) regimen is now the front line treatment for CD20 + DLBCL, This incorporation has been proved to improve the clinical outcomes and prognosis of those patients [43,44].

Thus, prior to the rituximab era, an earlier analysis of pooled data from GELA clinical studies suggested that HCV positive DLBCL may have dismal prognostic outcome due

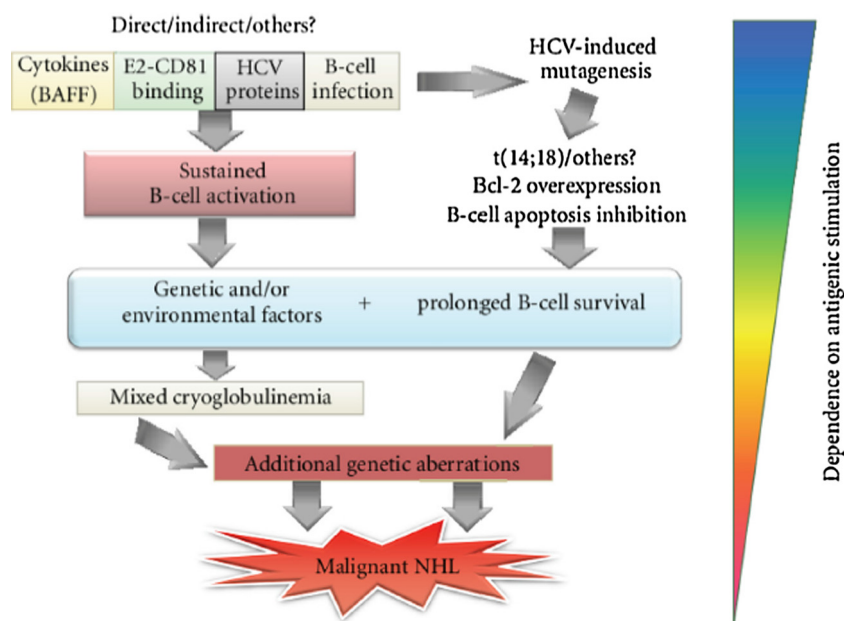


Fig. 1 Pathogenesis of HCV-related lymphomagenesis. Adopted from Zignego et al. [37].

to severe hepatic toxicity [45]. However, in the rituximab era consequent reports then showed that HCV positivity had no predictive role in terms of progression free or overall survival rates in DLBCL patients. However, more hepatotoxicity with chemoimmunotherapy was noticed among HCV-positive patients, which confirm the observation of previous GELA studies [46]. La Mura et al. conducted a retrospective study included 434 patients with indolent and aggressive NHL. Patients with HCV positive status treated with AVT (interferon-ribavirin) had better DFS than those who didn't receive the AVT (5-year DFS rates were 76% vs. 55%, respectively). In addition, patients with a SVR (sustained viral response) to AVT had no relapse ($n = 0/8$) compared with 29% for patients who did not respond to AVT ($n = 5$ of 17) [47].

The development of new antiviral agents had improved the treatment of chronic HCV infection. Combining the direct acting antiviral agents (DAA) with the standard AVT (pegylated interferon and ribavirin) had a significant improvement in the SVR rates in comparison with the standard AVT in chronic HCV carriers alone [48–51]. FDA recently approved the DAAs telaprevir and boceprevir for the treatment, in combination with pegylated interferon and ribavirin. Thus, the American Association for the Study of Liver Diseases (AASLD) updated the guidelines for the management of HCV infection and recommended to incorporate DAAs into standard AVT for patients infected with HCV [52].

In Egypt, we have conducted a retrospective study to elucidate the clinical characteristics of DLBCL patients in relation to HCV status. We included 132 DLBCL patients, with 64 (48.5%) and 68 (51.5%) of the patients who have received RCHOP and CHOP, respectively. Out of 132 DLBCL patients, HCV infection was positive in 35(26.5%). Patients with HCV infection had indistinguishable demography from HCV-negative patients except for more incidences of the presence of B symptoms and splenic involvement. Cox regression multivariate analysis showed that extra-nodal involvement, splenic involvement, and performance status were the indepen-

dent predictors for inferior OS. But for adverse DFS, the presence of splenic involvement was the only independent prognostic factor.

The incidence of hepatitis flares was 40%, (14/35) among the HCV-infected patients vs. 9.3% (9/97) among the HCV-negative individuals ($P \leq 0.001$). Of the 35 HCV-positive patients, 14 (40%) received R-CHOP. HCV reactivation occurred in 34.2% (11/35 patients) without any relation to treatment regimen (7 (11%) for RCHOP and 5(7.3%) for CHOP; $p = 0.3$). No deaths had been reported due to hepatic toxicity. So, the clinical outcome of DLBCL patients was not affected by HCV infection and its reactivation has no relation to the type of treatment [10].

Prevention of HCV reactivation

Unlike HBV reactivation, no drugs are currently approved for the prevention of HCV reactivation in patients with HCV infection who undergo chemotherapy. However, the risk of HCV reactivation in such patients might be reduced by using lower doses of immunosuppressive drugs, close monitoring of ALT levels, and measuring HCV RNA levels early during episodes of potential viral reactivation. Given the possibility of immune-mediated hepatocyte injury upon HCV reactivation, some researchers have speculated that gradual tapering of immunosuppressants could be another strategy to prevent HCV reactivation [51–53]. Others tried using prophylaxis with the antiviral drug ribavirin with no clinical benefit [11]. Thus, it could not be recommended to use initial antiviral therapy in asymptomatic patients with HCV-positive low-grade B-cell NHL. For those with HCV genotype 1, triple antiviral therapy with inclusion of DAAs should be considered as per AASLD guidelines. Patients with HCV-positive aggressive B-cell NHL should initially be treated with appropriate chemoimmunotherapy regimens. Liver function and serum HCV RNA levels should be closely monitored during and after chemo-immunotherapy for development of hepatotoxicity.

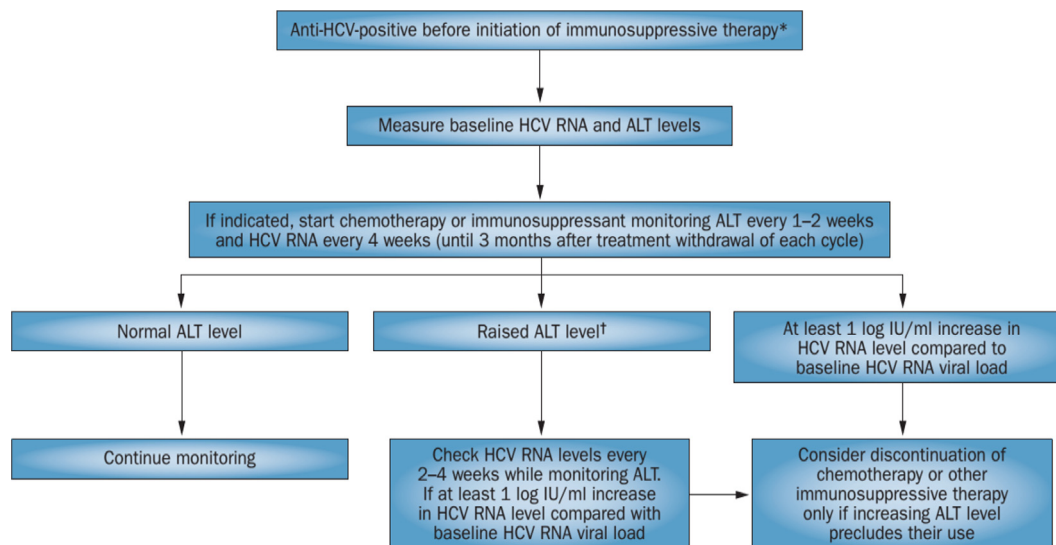


Fig. 2 An approach to the management of HCV positive cancer patients who are undergoing chemotherapy. Adopted from [55].

Antiviral therapy should then be considered in patients who achieve a CR after completion of chemo-immunotherapy. An approach to the management of HCV-positive patients with cancer who are undergoing chemotherapy or other immunosuppressive therapy is shown in Fig. 2. Chemotherapy can generally be administered in selected patients with HCV infection if they are monitored for viral reactivation during therapy [54].

Conclusions

HCV infection is a common disease worldwide, particularly in Egypt. One of its complications is the development of malignancy. On top of the list are hepatocellular carcinoma and malignant lymphomas. The optimal management of HCV-positive patients with NHL remains to be optimized. With the advent of new treatment molecules against HCV infection are showing better curative results, The hopes for lowering the incidence of the different malignant diseases caused as a complication of the viral infection, and improving their treatment outcomes is rising.

Conflict of Interest

The authors have declared no conflict of interest.

Compliance with Ethics Requirements

This article does not contain any studies with human or animal subjects.

References

- [1] Ghany MG, Strader DB, Thomas DL, Seeff LB. Diagnosis, management, and treatment of hepatitis C: an update. *Hepatology* 2009;49:1335–74.
- [2] Durand T, Di Liberto G, Colman H, Cammas A, Boni S, Marcellin P, et al. Occult infection of peripheral B cells by hepatitis C variants which have low translational efficiency in cultured hepatocytes. *Gut* 2010;59:934–42.
- [3] Simonetti RG, Camma C, Fiorello F, Cottone M, Rapicetta M, Marino L, et al. Hepatitis C virus infection as a risk factor for hepatocellular carcinoma in patients with cirrhosis. A case-control study. *Ann Intern Med* 1992;116:97–102.
- [4] Waked I, Doss W, El-Sayed MH, Estes C, Razavi H, Shiha G, et al. The current and future disease burden of chronic hepatitis C virus infection in Egypt. *Arab J Gastroenterol* 2014;15:45–52.
- [5] Shepard CW, Finelli L, Alter MJ. Global epidemiology of hepatitis C virus infection. *Lancet Infect Dis* 2005;5:558–67.
- [6] Sievert W, Altraif I, Razavi HA, Abdo A, Ahmed EA, Alomair A, et al. A systematic review of hepatitis C virus epidemiology in Asia, Australia and Egypt. *Liver Int.* 2011;31(Suppl. 2):61–80.
- [7] Ennishi D, Maeda Y, Niitsu N, Kojima M, Izutsu K, Takizawa J, et al. Hepatic toxicity and prognosis in hepatitis C virus-infected patients with diffuse large B-cell lymphoma treated with rituximab-containing chemotherapy regimens: a Japanese multicenter analysis. *Blood* 2010;116(24):5119–25.
- [8] Cowgill KD, Loffredo CA, Eissa SA, Mokhtar N, Abdel-Hamid M, Fahmy A, et al. Case-control study of non-Hodgkin's lymphoma and hepatitis C virus infection in Egypt. *Int J Epidemiol* 2004;33(5):1034–9.
- [9] Youssef SS, Nasr AS, El Zanaty T, El Rawi RS, Mattar MM. Prevalence of occult hepatitis C virus in Egyptian patients with chronic lymphoproliferative disorders. *Hepat Res Treat* 2012, 429784.
- [10] Haggag R, Abu-Taleb F, Khaled HM. Rituximab-induced hepatitis C virus reactivation in HCV-positive patients with diffuse large B-cell lymphoma. *J Clin Oncol* 2016;34 (suppl; abstr e19039).
- [11] Abu-Taleb F, El-Hefni A, Kotb A, El-Gohary TA. Efficacy of ribavirin to prevent hepatitis reactivation in hepatitis C virus-infected patients treated for non-Hodgkin lymphoma. *Afro-Egypt J Infect Endem Dis* 2013;3(1):17–26.
- [12] Esteban JI, Sauleda S, Quer J. The changing epidemiology of hepatitis C virus infection in Europe. *J Hepatol* 2008;48:148–62.
- [13] Paez Jimenez A, Sharaf Eldin N, Rimlinger F, El-Daly M, El-Hariri H, El-Hoseiny M, et al. HCV iatrogenic and intra familial transmission in Greater Cairo. *Egypt Gut* 2010;59:1554–60.
- [14] Pybus OG, Drummond AJ, Nakano T, Robertson BH, Rambaut A. The epidemiology and iatrogenic transmission of hepatitis C virus in Egypt: a Bayesian coalescent approach. *Mol Biol Evol* 2003;20(3):381–7.
- [15] Gisbert JP, Garcia-Buey L, Arranz R, Blas C, Pinilla I, Khorrami S, et al. The prevalence of hepatitis C virus

- infection in patients with non-Hodgkin's lymphoma. *Eur J Gastroenterol Hepatol* 2004;16:135–8.
- [16] Dal Maso L, Franceschi S. Hepatitis C virus and risk of lymphoma and other lymphoid neoplasms: a meta-analysis of epidemiologic studies. *Cancer Epidemiol Biomarkers Prev* 2006;15:2078–85.
- [17] Guadagnino V, Stroffolini T, Rapicetta M, Costantino A, Kondili LA, Menniti-Ippolito F, et al. Prevalence, risk factors, and genotype distribution of hepatitis C virus infection in the general population: a community-based survey in southern Italy. *Hepatology* 1997;26:1006–11.
- [18] Matsuo K, Kusano A, Sugumar A, Nakamura S, Tajima K, Mueller NE. Effect of hepatitis C virus infection on the risk of non-Hodgkin's lymphoma: a meta-analysis of epidemiological studies. *Cancer Sci* 2004;95:745–52.
- [19] Arcaini L, Paulli M, Boveri E, Vallisa D, Bernuzzi P, Orlandi E, et al. Splenic and nodal marginal zone lymphomas are indolent disorders at high hepatitis C virus seroprevalence with distinct presenting features but similar morphologic and phenotypic profiles. *Cancer* 2004;100:107–15.
- [20] Torres HA, Mahale P. Most patients with HCV-associated lymphoma present with mild liver disease: a call to revise antiviral treatment prioritization. *Liver Int* 2015;35(6):1661–4.
- [21] Goldman L, Ezzat S, Mokhtar N, Abdel-Hamid A, Fowler N, Gouda I, et al. Viral and nonviral risk factors for non-Hodgkin's lymphoma in Egypt: heterogeneity by histological and immunological subtypes. *Cancer Causes Control* 2009;20(6):981–7.
- [22] Ferri C, La Civita L, Zignego AL, Pasero G. Viruses and cancers: possible role of hepatitis C virus. *Eur J Clin Invest* 1997;27(7):711–8.
- [23] Peveling-Oberhag J, Jan, Luca Arcaini, Martin-Leo Hansmann, Stefan Zeuzem. Hepatitis C-associated B-cell non-Hodgkin lymphomas. Epidemiology, molecular signature and clinical management. *J Hepatol* 2013;59:169–77.
- [24] Zekri AR, Ahmed H, Ismail M, El-Nashar AT, El-Mokadem T, Hassan A. Genetic profiling of non-Hodgkin's lymphoma with or without hepatitis C virus infection. *Egypt J Immunol* 2010;17(2):81–90.
- [25] Du MQ. MALT lymphoma: many roads lead to nuclear factor- κ b activation. *Histopathology* 2011;58(1):26–38.
- [26] Craig VJ, Cogliatti SB, Arnold I, Gerke C, Balandat JE, Wündisch T, et al. B-cell receptor signaling and CD40 ligand-independent T cell help cooperate in Helicobacter-induced MALT lymphomagenesis. *Leukemia* 2010;24:1186–96.
- [27] Rosa D, Saletti G, De Gregorio E, Zorat F, Comar C, D'Oro U, et al. Activation of naïve B lymphocytes via CD81, a pathogenic mechanism for hepatitis C virus-associated B lymphocyte disorders. *Proc Natl Acad Sci USA* 2005;102(51):18544–9.
- [28] Pileri P, Uematsu Y, Campagnoli S, Galli G, Falugi F, Petracca R, et al. Binding of hepatitis C virus to CD81. *Science* 1988;262(5390):938–41.
- [29] Pozzato G, Mazzaro C, Crovatto M, Modolo ML, Ceselli S, Mazzi G, et al. Low-grade malignant lymphoma, hepatitis C virus infection, and mixed cryoglobulinemia. *Blood* 1994;84:3047–53.
- [30] Zignego AL, Ferri C, Giannelli F, Giannini C, Caini P, Monti M, et al. Prevalence of bcl-2 rearrangement in patients with hepatitis C virus-related mixed cryoglobulinemia with or without B-cell lymphomas. *Ann Intern Med* 2002;137(7):571–80.
- [31] Zignego AL, Giannelli F, Marrochi ME, Mazzocca A, Ferri C, Giannini C, et al. T (14;18) translocation in chronic hepatitis C virus infection. *Hepatology* 2000;31(2):474–9.
- [32] Casato M, Mecucci C, Agnello V, Fiorilli M, Knight GB, Matteucci C, et al. Regression of lymphoproliferative disorder after treatment for hepatitis C virus infection in a patient with partial trisomy 3, Bcl-2 overexpression, and type II cryoglobulinemia. *Blood* 2002;99(6):2259–61, 15.
- [33] Saadoun D, Suarez F, Lefrere F, Valensi F, Mariette X, Aouba A, et al. Splenic lymphoma with villous lymphocytes, associated with type II cryoglobulinemia and HCV infection: a new entity? *Blood* 2005;105(1):74–6.
- [34] Bouteloup M, Verney A, Rachinel N, Callet-Bauchu E, Ffrench M, et al. MicroRNA expression profile in splenic marginal zone lymphoma. *Br J Haematol* 2012;156:279–81.
- [35] Peveling-Oberhag J, Crisman G, Schmidt A, Doring C, Lucioni M, et al. Dysregulation of global microRNA expression in splenic marginal zone lymphoma and influence of chronic hepatitis C virus infection. *Leukemia* 2012;26(7):1654–62.
- [36] Di Lisio L, Martinez N, Montes-Moreno S, Piris-Villaespesa M, Sanchez-Beato M, et al. The role of miRNAs in the pathogenesis and diagnosis of B-cell lymphomas. *Blood* 2012;120:1782–90.
- [37] Zignego AL, Giannini C, Gragnani L. HCV and lymphoproliferation. *Clin Dev Immunol* 2012;1–8.
- [38] Hermine O, Lefrere F, Bronowicki JP, Mariette X, Jondeau K, Eclache-Saudreau V, et al. Regression of splenic lymphoma with villous lymphocytes after treatment of hepatitis C virus infection. *N Engl J Med* 2002;347:89–94.
- [39] Tursi A, Brandimarte G, Torello M. Disappearance of gastric mucosa-associated lymphoid tissue in hepatitis C virus-positive patients after anti-hepatitis C virus therapy. *J Clin Gastroenterol* 2004;38:360–3.
- [40] Vallisa D, Bernuzzi P, Arcaini L, Sacchi S, Callea V, Marasca R, et al. Role of anti-hepatitis C virus (HCV) treatment in HCV-related, low-grade, B-cell, non-Hodgkin's lymphoma: a multicenter Italian experience. *J Clin Oncol* 2005;23:468–73.
- [41] Hosry J, Mahale P, Turturro F, Miranda RN, Economides MP, Granwehr BP, et al. Antiviral treatment in patients with indolent B-cell lymphomas associated with HCV infection: a study of the Fondazione Italiana Linfomi. *Ann Oncol* 2014;25:1404–10.
- [42] Pellicelli AM, Marignani M, Zoli V, Romano M, Morrone A, Nosotti L, et al. Hepatitis C virus-related Bcell subtypes in non Hodgkin's lymphoma. *World J Hepatol* 2011;3:278–84.
- [43] Coiffier B, Lepage E, Briere J, Herbrecht R, Tilly H, Bouabdallah R, et al. CHOP chemotherapy plus rituximab compared with CHOP alone in elderly patients with diffuse large-B-cell lymphoma. *N Engl J Med* 2002;346:235–42.
- [44] Habermann TM, Weller EA, Morrison VA, Gascoyne RD, Cassileth PA, Cohn JB, et al. Rituximab-CHOP versus CHOP alone or with maintenance rituximab in older patients with diffuse large B-cell lymphoma. *J Clin Oncol* 2006;24:3121–7.
- [45] Besson C, Canioni D, Lepage E, Pol S, Morel P, Lederlin P, et al. Characteristics and outcome of diffuse large B-cell lymphoma in hepatitis C virus-positive patients in LNH 93 and LNH 98 Grouped'Etude des Lymphomes de l'Adulte programs. *J Clin Oncol* 2006;24:953–60.
- [46] Ennishi D, Maeda Y, Niitsu N, Kojima M, Izutsu K, Takizawa J, et al. Hepatic toxicity and prognosis in hepatitis C virus-infected patients with diffuse large B-cell lymphoma treated with rituximab-containing chemotherapy regimens: a Japanese multicenter analysis. *Blood* 2010;116:5119–25.
- [47] La Mura V, De Renzo A, Perna F, D'Agostino D, Masarone M, Romano J. Antiviral therapy after complete response to chemotherapy could be efficacious in HCV-positive non-Hodgkin's lymphoma. *J. Hepatol.* 2008;49(4):557–63.
- [48] Bacon Babić JS, Bojović K, Fabri M, Kostić V, Jovanović M, Mijailović Z, et al. Boceprevir for previously treated chronic HCV genotype 1 infection. *N Engl J Med* 2011;364:1207–17.
- [49] Jacobson IM, McHutchison JG, Dusheiko G, Di Bisceglie AM, Reddy KR, Bzowej NH, et al. Telaprevir for previously untreated chronic hepatitis C virus infection. *N Engl J Med* 2011;364:2405–16.

- [50] Jacobson IM, McHutchison JG, Dusheiko G, Di Bisceglie AM, Reddy KR, Bzowej NH, et al. Telaprevir with peginterferon and ribavirin for chronic HCV genotype 1 infection. *N Engl J Med* 2009;360:1827–38.
- [51] Poordad F, McCone Jr J, Bacon BR, Bruno S, Manns MP, Sulkowski MS, et al. Boceprevir for untreated chronic HCV genotype 1 infection. *N Engl J Med* 2011;364:1195–206.
- [52] Ghany MG, Nelson DR, Strader DB, Thomas DL, Seeff LB. An update on treatment of genotype 1 chronic hepatitis C virus infection: 2011 practice guideline by the American Association for the study of liver diseases. *Hepatology* 2011;54:1433–44.
- [53] Vento S, Cainelli F, Mirandola F, Cosco L, Di Perri G, Solbiati M, et al. Fulminant hepatitis on withdrawal of chemotherapy in carriers of hepatitis C virus. *Lancet* 1996;347:92–3.
- [54] Turner NC, Dusheiko G, Jones A. Hepatitis C and B-cell lymphoma. *Ann Oncol* 2003;14:1341–5.
- [55] Torres HA, Davila M. Reactivation of hepatitis B virus and hepatitis C virus in patients with cancer. *Nat Rev Clin Oncol* 2012;9:156–66.