

Original Article

Morphologic Changes of the Femoropopliteal Arterial Segment with Knee Flexion after Endovascular Therapy

Katsutoshi Sato, MD, PhD,¹ Shogo Emura, MD,¹ Hideki Tomiyoshi, MD,² and Satoru Morita, MD¹

Objective: The purpose of this study is to investigate morphologic changes of the femoropopliteal arterial segment (FPAS) with knee flexion after endovascular therapy (EVT).

Methods: From July 2012 to January 2015, EVT was performed on 12 limbs in 12 consecutive patients who had obliterative lesions in the FPAS. After the implantation of nitinol stents, angiography was performed with the knee in both extension and flexion to investigate morphologic changes of the FPAS.

Results: On angiography, the distal end of the implanted stent was placed at various distances (5–10 cm in two cases, 10–15 cm in nine cases, and 15–20 cm in one case) above the knee joint line with the knee in extension. In all cases, although the popliteal artery was highly bent with the knee in flexion, the FPAS morphology was highly variable. However, the most proximal bending point of the FPAS was about 10 cm above the knee joint line. In one case, the artery was occluded at the distal part of the stent 16 months later, probably due to EVT.

Conclusion: In EVT of the FPAS, it is important to consider the characteristics and position of the stent to prevent complications.

Keywords: endovascular therapy (EVT), femoropopliteal arterial segment, knee flexion

Introduction

The clinical efficacy of nitinol stent implantation for the femoropopliteal arterial segment is favorable when endovascular therapy (EVT) is used to treat peripheral artery disease.^{1,2)} However, some problems have been reported in this segment, and these are related to both the implanted stents and the morphologic changes of the artery during limb movements.^{3–7)}

EVT is usually performed in the supine position on an angiographic table with the knee in extension. After stent deployment, angiography is performed to confirm the results only in knee extension; however, angiography is never performed with the knee in flexion. Therefore, morphologic changes of the artery during limb movements cannot be confirmed. It seems that these morphologic changes might potentially affect long-term results.

In this study, we performed angiography with the knee in both extension and flexion after stent deployment. Based on these images, we investigated morphologic changes of the artery during limb movements, and discussed the influences of stent implantation in the femoropopliteal arterial segment.

Methods

Patients

Between July 2012 and January 2015, 12 limbs were treated in 12 consecutive patients who met the following criteria: obliterative lesions in the FPAS, no severe stenosis in the popliteal artery, and one or more patent arteries in the lower leg. The age of the patients was 48–88 years (73.2 ± 11.3 years), and all the cases were male. Based on the Trans-Atlantic Inter-Society Consensus (TASC) II classification,⁸⁾ one case was class A, 10 were class B, and one was class C. Six cases had total occlusion in this segment. Five cases had ulcer and/or gangrene of the foot. In

¹Department of Cardiovascular Surgery, National Hospital Organization, Higashihiroshima Medical Center, Higashihiroshima, Hiroshima, Japan

²Department of Radiology, National Hospital Organization, Higashihiroshima Medical Center, Higashihiroshima, Hiroshima, Japan

Received: December 17, 2018; Accepted: March 18, 2019
Corresponding author: Katsutoshi Sato, MD, PhD. Department of Cardiovascular Surgery, National Hospital Organization, Higashihiroshima Medical Center, 513 Jike, Saijou, Higashihiroshima, Hiroshima 739-0041, Japan
Tel: +81-82-423-2176, Fax: +81-82-422-4675
E-mail: satokts-cvs@umin.ac.jp


 ©2019 The Editorial Committee of Annals of Vascular Diseases. This article is distributed under the terms of the Creative Commons Attribution License, which permits use, distribution, and reproduction in any medium, provided the credit of the original work, a link to the license, and indication of any change are properly given, and the original work is not used for commercial purposes. Remixed or transformed contributions must be distributed under the same license as the original.

Table 1 Background of the patients

Case	Age	DM	HT	HL	Smoking	CVD	CAD	HD	Previous surgery for vascular disease
1	88	•	•						
2	68		•		•				
3	82	•	•	•	•	•	•		
4	77		•		•				
5	68		•		•			•	
6	65	•	•		•		•	•	AP
7	77		•					•	DAA, AAA
8	64	•	•	•	•		•		AP
9	48	•	•		•		•	•	AP
10	76	•	•	•	•		•		
11	88	•	•		•		•		
12	77	•	•	•	•		•		

DM: diabetes mellitus; HT: hypertension; HL: hyperlipidemia; CVD: cerebrovascular disease; CAD: coronary artery disease; HD: hemodialysis; AP: coronary artery bypass grafting for angina pectoris; DAA: total arch replacement for dissecting aortic aneurysm; AAA: bifurcated graft replacement for abdominal aortic aneurysm

seven patients who had intermittent claudication, both medication and exercise therapy were attempted as initial therapy. However, since they did not show significant improvement, we decided that additional treatment was necessary.⁸⁾

The majority of cases had risk factors for arteriosclerotic disease, such as diabetes mellitus, hypertension, hyperlipidemia, and/or smoking. Additionally, they had previous vascular treatments and/or hemodialysis due to arteriosclerosis (Table 1).

EVT procedure

Since the target lesions in the femoropopliteal arterial segment were total obstruction or severe stenosis with calcification in all cases, we performed EVT with primary implantation of stents to avoid dissection and/or re-occlusion of the segment.⁹⁾ The patients were treated in the supine position on the angiographic table. Under local anesthesia, a 6Fr vascular introducer sheath (various manufacturers) was inserted into the superficial femoral artery via the ipsilateral common femoral artery. Through the vascular introducer sheath, a 4Fr angiographic catheter (various manufacturers) was inserted over a 0.035 inch guide wire (various manufacturers). After angiography, which was performed to assess the target lesion, the guide wire was advanced to cross the lesion. In one case that had total occlusion with severe calcification, predilatation of the lesion was needed to insure passage of the stent-bearing catheter system. Due to the availability of devices in our hospital, a SMART Control™ stent (Cordis Corp., Florida, ML, USA),¹⁰⁾ having stronger axial rigidity, was used for the first six cases, and a Misago™ stent (Terumo Corp., Tokyo, Japan),¹¹⁾ a more flexible stent, for the rest. The diameter and the length of stent were selected from both computed tomography (CT) and angiography im-

ages. An angioplasty balloon (various manufacturers) was used to perform post-dilatation in all cases.

After stent deployment, angiography was performed with the knee in extension by injecting contrast medium from the vascular introducer sheath. This resulted in the usual anteroposterior view of the leg. After that, angiography was performed with the knee in flexion. At that time, the ipsilateral hip joint was maintained in abduction and external rotation to keep the knee in flexion. The angle of the knee joint was set to maximal in a position that the patients could maintain without assistance, instead of a constant angle. Since we considered that maximal flexion would have the greatest influence on deformation of the artery, we used this method in each patient. The images were obtained from the inner thigh, and showed a lateral view of the leg. Angiography was performed by injecting contrast medium through the sheath, and morphologic changes of the artery with the knee in flexion were observed.

After EVT, all patients received one or more antiplatelet agents due to their previous vascular disease and/or stent implantation. We followed them for three years.

Evaluation of the stent position

During the operation, based on the angiographic images and preoperative CT images, the distance from the knee joint line to the distal end of the implanted stent and the size of the artery at the distal part of the stent were measured with the knee in extension. Then, the distance from the distal end of the stent to the most proximal bending point of the femoropopliteal arterial segment was measured with the knee in flexion. By subtraction (addition in Cases 10 and 12) of these distances, the distance from the knee joint line to the most proximal bending point of the popliteal artery was calculated with the knee in exten-

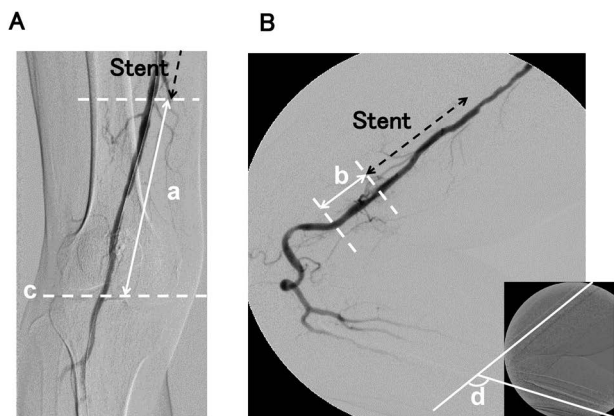


Fig. 1 Evaluation of stent position. (A) Anteroposterior view of the leg with the knee in extension. (B) Lateral view of the leg with the knee in flexion. a, Distance from the knee joint line to the distal end of the implanted stent with the knee in extension; b, distance from the distal end of the stent to the most proximal bending point of the femoropopliteal arterial segment with the knee in flexion; a-b, distance from the knee joint line to the most proximal bending point of the popliteal artery with the knee in extension (a+b, in Cases 10 and 12); c, level of the knee joint line; d, angle of the knee joint made by the center line of the thigh bone and the tibial bone.

sion. The bend angle of the knee joint was measured by the angle made by the intersection of the center line of the thigh bone and the tibial bone (Fig. 1).

This study was approved by the Ethical Committee at our institute, and informed consent was obtained from all the patients.

Results

All the cases were treated by EVT without any additional procedures. One or two self-expanding nitinol stents were used, which were 40–150 mm in length and 6–7 mm in diameter. The treated length in 12 cases was 40–177 (101.5 ± 36.4) mm. In knee extension, the distal end of the implanted stent was placed at various distances (5–10 cm in two cases, 10–15 cm in nine cases, and 15–20 cm in one case) above the level of the knee joint line. At the distal part of the stent, the diameter of the artery was 3.2–5.7 (4.6 ± 0.6) mm on preoperative CT images. In Case 2, the diameter was 3.2 mm; however, a diameter ≥ 4 mm was observed in all of the other cases.

On angiography with the knee in flexion, the popliteal artery was severely bent behind the knee in all the cases with various degrees of curvature. The angle of the knee joint was 95–133 (120 ± 11) degrees, which was anatomically close to the maximum angle of the knee joint. Although the vascular stents were implanted at several levels of the femoropopliteal arterial segment, the most

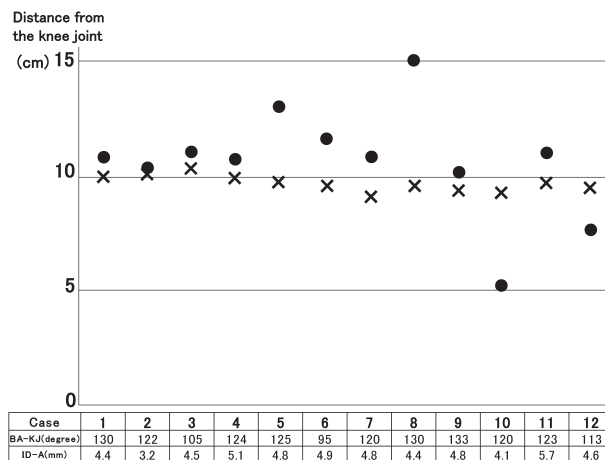


Fig. 2 Stent position and arterial bending. The vascular stents were implanted at several different levels of the femoropopliteal arterial segment. However, the most proximal bending point of the artery was observed about 10 (9.88 ± 0.61) cm above knee joint line in all cases. ●, Distance from the knee joint line to the distal end of the implanted stent with the knee in extension; x, calculated distance from the knee joint line to the most proximal bending point of the femoropopliteal arterial segment with the knee in extension. BA-KJ: bend angle of the knee joint; ID-A: internal diameter of the artery at the distal end of the stent

proximal bending point of the artery was observed at about 10 (9.88 ± 0.61) cm above the knee joint line in all cases (Fig. 2). In two cases (Cases 10 and 12) that were treated by a Misago™ stent, the distal end of the stent was placed < 10 cm above the knee joint line. However, as was observed in other cases, the most proximal bending of the artery occurred at about 10 cm above the knee joint line, and it was within the implanted stent (Fig. 3A).

In this series, seven cases had only intermittent claudication. In six cases, symptoms were improved by EVT, and the patients had no symptoms for three years. However, in one case (Case 2), the treated artery was occluded during the observation period. The patient was treated with a SMART Control™ stent, which was 6 mm in diameter and 100 mm in length. On post-implant angiography, no abnormalities were observed with the knee in extension. The distal end of the stent was placed approximately 10 cm above the knee joint line. However, with the knee in flexion, kinking of the artery was observed at the distal part of the stent. It was almost the same position as the most proximal bending point of the artery (Fig. 3B). At 16 months after EVT, a short segment of the artery was occluded at the distal part of the stent, which was just the kinked segment. However, since the artery below the occlusion was patent, we performed femoropopliteal bypass with a vascular prosthesis.

Five patients who had ulcer and/or gangrene of the foot

were included in this study. In two of these five patients, the ulcer healed after EVT; however, the other 3 died during the observation period. In one patient on dialysis, amputation below the knee was performed due to worsening gangrene after EVT; however, this patient died of acute myocardial infarction 1 month later. Another patient on dialysis was discharged after EVT and continued treatment for gangrene at another hospital. Although this

patient had another amputation at 12 months after EVT due to worsening gangrene, the patient died of sepsis. In the most recent case, although the ulcer of the malleolus had completely healed after EVT, gangrene of the toe had not. Thus, minor amputation was performed at 9 months after EVT. Two years later, he died of acute myocardial infarction. There were no complications related to the implanted stents during the observation period in the three patients who had gangrene and died (Table 2).

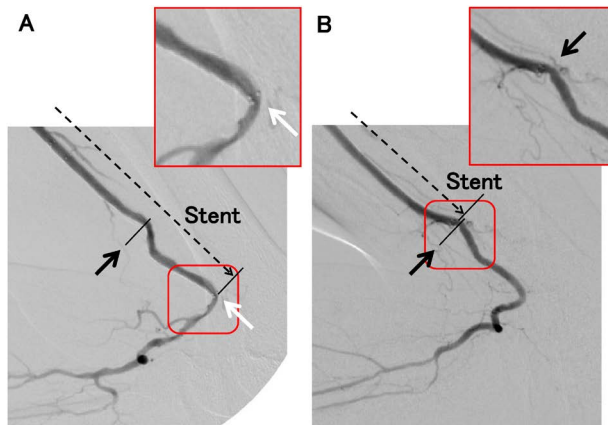


Fig. 3 The morphologic changes of the artery during the limb movements.

(A) A case treated with a Misago™ stent. The distal end of the stent was placed about 5 cm above the knee joint line. It was the 'hinge point' (white arrow). The most proximal bending of the artery 'accessory flexion' was observed about 10 cm above the knee joint line. It was within the implanted stent (black arrow). The stent bent with knee flexion without kinking the artery. (B) A case treated with a SMART Control™ stent. The distal end of the stent was placed about 10 cm above the knee joint line with the knee in extension. It was in the same position as the proximal bending point with the knee in flexion (black arrow), and the artery kinked at the distal side of the stent.

Discussion

The femoropopliteal arterial segment demonstrates bending, twisting, and axial compression to prevent kinking with the knee in flexion.^{12,13} The superficial femoral artery tends to deform more in the bottom third than in other sections, and this is likely because of less musculoskeletal constraint distal to the adductor canal.¹⁴ The artery has two fixed anatomical points around the knee joint, one proximal to the adductor canal and the other distal to the origin of the anterior tibial artery. The most significant bending of the popliteal artery occurs with the knee in flexion.¹⁵ Diaz et al. defined the main flexion of the popliteal artery as the 'hinge point,' and this accompanies flexion as the 'accessory flexion.' Some accessory flexion occurred above or below the hinge point.¹²

Previous studies reported that if vascular stents were implanted in this segment, there could be some complications such as stent fracture, intimal hyperplasia, or vascular occlusion.³⁻⁷ Furthermore, Smouse et al. reported that a stent with stronger axial rigidity implanted in the femoropopliteal arterial segment results in less bending and compression of the artery in the lesion. Consequently, the artery below the stent will tend to bend more. Moreover, there is a high possibility that the artery will be kinked at

Table 2 Results of endovascular therapy

Case	TASC II class	S/O	Vascular stent (mm)	Preoperative ABI	Postoperative ABI	Fontaine class	Prognosis of the leg
1	B	O	S: 6×80	0.58	0.81	IV: Toe	Healing
2	B	S	S: 6×100	Not measured	0.83	II	Occluded (F-P bypass)
3	B	S	S: 6×100	0.84	0.94	II	Improved
4	B	O	S: 6×100	0.53	0.99	II	Improved
5	B	O	S: 6×80	0.65	0.77	II	Improved
6	A	S	S: 6×40	0.6	0.73	II	Improved
7	C	S	M: 7×100+M: 6×100	Not measured	Not performed	IV: Foot, toe	Major amputation (death)
8	B	O	M: 6×100	0.79	0.92	II	Improved
9	B	S	M: 6×80	0.7	0.8	IV: Toe	Major amputation (death)
10	B	O	M: 6×100+M: 6×40	0.64	0.85	IV: Toe	Healing
11	B	S	M: 7×150	0.78	1.05	II	Improved
12	B	O	M: 6×80	Not measured	0.59	IV: Heel, toe	Minor amputation (death)

TASC: Trans-Atlantic Inter-Society Consensus; S/O: stenosis/occlusion, preoperatively; M: Misago™ stent; S: SMART Control™ stent; ABI: ankle-brachial pressure index; F-P bypass: femoropopliteal bypass

the margin of the stent, leading to some problems in the artery.⁷⁾

In the first 6 cases in this study, a SMART Control™ stent, having stronger axial rigidity, was implanted in the femoropopliteal arterial segment. In Case 2, the distal end of the stent was placed about 10cm above the level of knee joint line. On post-implant angiography, the artery was kinked at the distal part of the stent with the knee in flexion (Fig. 3B). The artery was occluded at this point. In the other 5 cases, since the distal end of the stent was away from the most proximal bending point with the knee in flexion, some straight segment could be seen without kinking between the distal end of the stent and the most proximal bending point. These cases had no problems in this segment. Although it is difficult to draw conclusions based on one case, it seems that there is a possibility that early occlusion might be induced by irritation from the implanted stent when a kink of the artery occurred with the knee in flexion.

In the latter six cases, a Misago™ stent, having excellent flexibility, was implanted in the femoropopliteal arterial segment. In Cases 10 (Fig. 3A) and 12, the distal end of the stent was located 5–10cm above the knee joint line due to the necessity of treatment. With the knee in flexion, a 'hinge point' and 'accessory flexion' were observed around the knee. There was a bend of the artery in the implanted stent at about 10cm above the knee joint line. This was the most proximal bending point. As the Misago™ stent has excellent flexibility, it conformed to the bending of the artery without kinking with the knee in flexion. Over a three-year observation period, there were no problems related to treatment of this segment. However, as bending of the arteries occurred within the implanted stent, other complications might occur in the future, such as stent fracture due to the repetitive flexion of the stent.⁴⁾

Vascular stents for peripheral arteries have various characteristics with each device. In this study, we selected two stents due to the availability of devices in our hospital. Coincidentally, they had opposite characteristics. The SMART Control™ stent has stronger axial rigidity, whereas the Misago™ stent has excellent flexibility. The arteries could be influenced by the structure of the leg as well as the characteristics of the implanted stent.^{12,13)} We were not able to implant these stents in the same arterial segment in each patient for a comparative trial. However, from this study, we believe that stents with stronger axial rigidity (such as SMART Control™) would be useful in a straight segment of the femoropopliteal arterial segment even in knee flexion, whereas stents with excellent flexibility (such as Misago™) would be useful in parts of the femoropopliteal arterial segment that bend with knee flexion. To prevent some complications, it seems important to select the stent according to the conditions of the treated

arterial segment during limb movement. From our cases, it seems that flexible stents should be chosen for cases in which the distal edge of the stent is <10cm above the knee joint line.

Miki et al. reported that a small vessel is an indicator of high-risk target lesion revascularization with stent implantation in superficial femoral artery lesions.¹⁶⁾ In Case 2, after considering the occluded pattern, we suspected that the most probable cause of the occlusion was kinking of the artery. However, the small arterial diameter at the distal part of the stent could have secondarily affected the occlusion. According to the device labeling of these two stents, the stents should be implanted in arteries with diameters >4mm for safety. In our series, only this case had an arterial diameter <4mm. On preoperative CT, the diameter of the artery at the distal part of the stent was 3.2mm. However, in all the other cases, the arterial diameter was >4mm. It seems that a small diameter at the distal part of the stent might easily induce kinking and occlusion of the artery. Therefore, we believe that, for the selection of the distal position of the stent, the size of the artery should also be considered.

In this report, we have discussed morphologic changes of the femoropopliteal arterial segment due to limb movements after EVT, and the relevance of the position and size of the artery and characteristics of the stent. Moreover, in the literature, calcification of the artery also influences arterial deformation with the knee in flexion.¹⁷⁾ When a stent with strong axial rigidity is in contact with a calcified artery, the artery might be likely to kink easily with the knee in flexion. From this point of view, it seems that the distal end of the stent should not be placed at the proximal side of a severely calcified lesion in this segment. In our series, calcification of the artery was not a problem, since there were no cases with severe calcification of the artery at the distal side of the stent.

In this study, we performed angiography with the knee in both extension and flexion for all cases. It was difficult to predict morphologic changes of the artery during limb movements based only on the image before stent implantation with the knee in extension. Although the image after stent implantation with the knee in flexion is not necessary for all cases, it seems that it might be useful for predicting some complications in the future. Based on the image with the knee in flexion, cases that show kinking of the artery at the distal side of the stent should be observed carefully. Moreover, if the injected contrast medium is delayed or stopped due to kinking of the artery, additional procedures would be required to avoid early occlusion.

A limitation of this study is there were a small number of cases and a short follow-up period. Furthermore, to give priority to observation of the morphologic changes of the femoropopliteal arterial segment, we included patients

with claudication or critical limb ischemia. Outcomes would have been expected to be different in these two groups. In this study, three out of five cases of critical limb ischemia died during the observation period. We were unable to evaluate the arterial conditions during 3 years due to the death of some patients and the inability to perform the image examination of some cases without occlusion. In the future, we will investigate patency and restenosis rates, amputation-free survival and other endpoints for each stent, with a special focus on the claudication group. Then, we would like to consider how to place a stent in this segment that would not show dangerous morphologic changes from extension to flexion.

Conclusion

To prevent complications in EVT of the femoropopliteal arterial segment, it is important to consider the characteristics and position of the stent, which adapt to the morphology and deformation of the artery during limb movements.

Disclosure Statement

All authors have no conflict of interest.

Additional Note

We presented an overview of our manuscript at the 55th Annual Meeting of Japanese College of Angiology on October 30th, 2014, in Okayama, Japan.

Author Contributions

Study conception: KS

Data collection: KS, HT, SE, SM

Analysis: KS, HT

Investigation: KS, HT, SE

Writing: KS

Funding acquisition: not applicable

Critical review and revision: all authors

Final approval of the article: all authors

Accountability for all aspects of the work: all authors

References

- 1) Malas MB, Enwerem N, Qazi U, et al. Comparison of surgical bypass with angioplasty and stenting of superficial femoral artery disease. *J Vasc Surg* 2014; **59**: 129-35.
- 2) Sakamoto Y, Hirano K, Iida O, et al. Five-year outcomes of self-expanding nitinol stent implantation for chronic total occlusion of the superficial femoral and proximal popliteal artery. *Catheter Cardiovasc Interv* 2013; **82**: E251-6.
- 3) Shibuya T, Shintani T, Edogawa S, et al. A review of surgically treated patients with obstruction after stenting in the femoropopliteal artery region. *Ann Vasc Dis* 2013; **6**: 573-7.
- 4) Lin Y, Tang X, Fu W, et al. Stent fractures after superficial femoral artery stenting: risk factors and impact on patency. *J Endovasc Ther* 2015; **22**: 319-26.
- 5) Banerjee S, Das TS, Abu-Fadel MS, et al. Pilot trial of cryoplasty or conventional balloon post-dilation of nitinol stents for revascularization of peripheral arterial segments: the COBRA trial. *J Am Coll Cardiol* 2012; **60**: 1352-9.
- 6) Tamashiro GA, Tamashiro A, Villegas MO, et al. Flexions of the popliteal artery: technical considerations of femoropopliteal stenting. *J Invasive Cardiol* 2011; **23**: 431-3.
- 7) Smouse HB, Nikanorov A, LaFlash D. Biomechanical forces in the femoropopliteal arterial segment. *Endovasc Today* 2005; **1**: 60-6.
- 8) Norgren L, Hiatt WR, Dormandy JA, et al. Inter-Society Consensus for the Management of Peripheral Arterial Disease (TASC II). *J Vasc Surg* 2007; **45** Suppl S: S5-67.
- 9) Laird JR, Katzen BT, Scheinert D, et al. Nitinol stent implantation vs. balloon angioplasty for lesions in the superficial femoral and proximal popliteal arteries of patients with claudication: three-year follow-up from the RESILIENT randomized trial. *J Endovasc Ther* 2012; **19**: 1-9.
- 10) Gray WA, Feiring A, Cioppi M, et al. S.M.A.R.T. self-expanding nitinol stent for the treatment of atherosclerotic lesions in the superficial femoral artery (STROLL): 1-year outcomes. *J Vasc Interv Radiol* 2015; **26**: 21-8.
- 11) Schulte KL, Kralj I, Gissler HM, et al. MISAGO 2: one-year outcomes after implantation of the Misago self-expanding nitinol stent in the superficial femoral and popliteal arteries of 744 patients. *J Endovasc Ther* 2012; **19**: 774-84.
- 12) Diaz JA, Villegas M, Tamashiro G, et al. Flexions of the popliteal artery: dynamic angiography. *J Invasive Cardiol* 2004; **16**: 712-5.
- 13) Nikanorov A, Schillinger M, Zhao H, et al. Assessment of self-expanding nitinol stent deformation after chronic implantation into the femoropopliteal arteries. *EuroIntervention* 2013; **9**: 730-7.
- 14) Cheng CP, Choi G, Herfkens RJ, et al. The effect of aging on deformations of the superficial femoral artery resulting from hip and knee flexion: potential clinical implications. *J Vasc Interv Radiol* 2010; **21**: 195-202.
- 15) Avisse C, Marcus C, Ouedraogo T, et al. Anatomoradiological study of the popliteal artery during knee flexion. *Surg Radiol Anat* 1995; **17**: 255-62.
- 16) Miki K, Fujii K, Fukunaga M, et al. Impact of post-procedural intravascular ultrasound findings on long-term results following self-expanding nitinol stenting in superficial femoral artery lesions. *Circ J* 2013; **77**: 1543-50.
- 17) Gökçöl C, Diehm N, Kara L, et al. Quantification of popliteal artery deformation during leg flexion in subjects with peripheral artery disease: a pilot study. *J Endovasc Ther* 2013; **20**: 828-35.