

Endoscopic coblation treatment for congenital pyriform sinus fistula in children

Wei Chen, MD, Jiarui Chen, MD, Fang Chen, MD, Jiali Wu, MD, Limin Zhao, MD, Hongming Xu, MD, Xiaoyan Li, MD*

Abstract

Congenital pyriform sinus fistula (CPSF) is a very rare branchial apparatus malformation. Traditional open surgery for fistulectomy might fail to excise the lesion completely, leading to continual recurrence. Herein, we report our experience of endoscopic coblation technique for treatment of CPSF in children.

To observe the clinical efficacy of endoscopic coblation treatment of CPSF in children, especially for those in acute infection stage.

Retrospective case series with 54 patients (including 20 cases in acute infection stage and 34 cases in non infection stage) who were diagnosed with CPSF between October 2017 to November 2019, all patients were treated with endoscopic coblation to close the pyriform fossa fistula, neck abscess incision and drainage performed simultaneously for acute infection stage cases. Data collected including age of diagnosis, presenting symptoms, diagnostic methods, prior and subsequent treatments, length of hospitalization, and recurrence were analyzed.

Of the 20 cases in acute infection stage, there were 3 children with transient vocal cord paresis all of which resolved with 1 month. Four children of the 34 cases in non infection stage appeared reddish swelling of the neck on the 4th, 5th, 6th, and 7th days after coblation and then underwent abscess incision and drainage. All cases experienced no recurrence, vocal cord paralysis, pharyngeal fistula and massive hemorrhage after their first endoscopic coblation of the sinus tract in the follow up of 3 to 28 months.

Endoscopic coblation is an effective and safe approach for children with CPSF, neck abscess incision and drainage could be performed simultaneously in acute infection stage. We advocate using this minimally invasive technique as first line of treatment for CPSF.

Abbreviations: AIS = acute infection stage, CPSF = congenital pyriform sinus fistula, CT = computed tomography, NIS = non infection stage.

Keywords: acute infection stage, children, congenital pyriform sinus fistula, endoscopic coblation, non infection stage

1. Introduction

Congenital pyriform sinus fistula (CPSF) is a rare branchiogenic disease of the neck, which may be associated with an incomplete obliteration of the third or fourth branchial pouch. The main clinical manifestations are recurrent neck abscess and suppurative

thyroiditis that are predominantly left sided.^[1-2] Most clinical literature on CPSF exists in the form of case reports. Large clinical reports and systematic studies are rare. As such, CPSF cases are often misdiagnosed in clinical practice.^[2-3] The traditional treatment for CPSF in acute infection stage (AIS) is

Editor: Khaled Saad.

Shanghai Shenkang hospital development center clinical science and technology innovation project - municipal hospital clinical research and cultivation project (20873999).

All authors have read and agreed with this manuscript and its submission.

This research did not increase the risk and economic burden of patients; the patients' rights were fully protected; the project design was conducted in line with the principles stated in the Declaration of Helsinki "Ethical Principles for Medical Research Involving 'Human Subjects'".

This retrospective study was approved by the Ethics Committee of Shanghai Children's Hospital, Shanghai Jiao Tong University.

This study (2020R021-E01) was approved by the Institutional Review Board of Shanghai Children's Hospital, Shanghai Jiao Tong University.

All participants in this study have provided informed written consent prior to enrollment.

The authors have no conflicts of interests to disclose.

The datasets generated during and/or analyzed during the current study are available from the corresponding author on reasonable request.

Department of Otolaryngology-Head and Neck Surgery, Shanghai Children's Hospital, Shanghai Jiao Tong University, Shanghai, China.

* Correspondence: Xiaoyan Li, Department of Otolaryngology-Head & Neck Surgery, Shanghai Children's Hospital, Shanghai Jiaotong University, Shanghai, Luding Road No. 355, PuTuo District, Shanghai 200062, China (e-mail: lixiaoyanent@sina.com).

Copyright © 2021 the Author(s). Published by Wolters Kluwer Health, Inc.

This is an open access article distributed under the terms of the Creative Commons Attribution-Non Commercial License 4.0 (CCBY-NC), where it is permissible to download, share, remix, transform, and buildup the work provided it is properly cited. The work cannot be used commercially without permission from the journal.

How to cite this article: Chen W, Chen J, Chen F, Wu J, Zhao L, Xu H, Li X. Endoscopic coblation treatment for congenital pyriform sinus fistula in children. *Medicine* 2021;100:19(e25942).

Received: 25 September 2020 / Received in final form: 22 April 2021 / Accepted: 23 April 2021

<http://dx.doi.org/10.1097/MD.0000000000025942>

conservative, which mainly includes incision and drainage of neck abscess and anti-infective treatment. During the non infection stage (NIS) complete surgical excision of the fistula associated hemithyroidectomy is performed. However, the open surgery has some weaknesses such as surgical trauma, many complications, long time recovery and formation of neck scars leading to an unpleasant appearance.^[4–6] In recent years, with the advancement of technology, endoscopic electrocautery, chemical cauterization, CO2 laser cauterization and other similar strategies in the treatment of CPSF were reported due to their minimally invasive nature, safety, and clinically effective features. However, the disadvantages of these technologies gradually exposed over time.^[7–10] NIS has been considered to prerequisite for the endoscopic technique and typical open surgery.^[11] Furthermore, very few studies have detailed the use of endoscopic coblation to treat CPSF. Thus, to date there have been few reports of endoscopic coblation as a minimally invasive treatment for CPSF in children during AIS in conjunction with incision and drainage of neck abscesses.^[4–5] In this study, endoscopic coblation was used to close the internal opening of the sinus tract both in AIS and NIS, and then, the clinical effectiveness were evaluated to provide a new approach for the current treatment protocol for children with CPSF especially in AIS.

2. Materials and methods

2.1. General information

In this study, we performed a retrospective review of patients with CPSF underwent endoscopic coblation between October

2017 to November 2019. The following data were collected: gender, age at presentation, type, presenting symptoms, diagnostic methods, initial and subsequent treatments, length of hospitalization, recurrence, and follow-up (Table 1). The clinical course and outcomes of these patients were analyzed with descriptive statistics. This study was approved by the Institutional Review Board of our hospital.

2.2. Surgical methods

NIS, 20 cases: The patients were placed in the supine position and tracheal intubation was performed under general anesthesia. A suspension laryngoscope was utilized to expose the pyriform sinus and search for the fistula. Once the internal opening of the sinus tract was identified (Fig. 1 A), diluted iodine was used for disinfection in the fistula and lumen, and then, a low-temperature plasma electrode device (EIC7070-01, ArthroCare Corporation, USA) was used to ablate the sinus tract (Fig. 1 B, C), distally to proximally. Taking the size of fistula into consideration, coblation was performed to a depth about 0.5 cm into the fistula with a diameter of ~0.5 cm around the fistula.

AIS, 34 cases: General anesthesia was performed prior to tracheal intubation, after which suspension laryngoscopy exploration and endoscopic coblation was performed combined with incision and drainage of the neck abscess. In cases where it was difficult to find the sinus tract due to the swelling tissue, pressing on the neck gently could express purulent drainage through the tract into the pyriform fossa, confirming identification of the sinus. The endoscopic procedure was the same as that used in inflammatory quiescent stage. Immediately after

Table 1
Basic data for CPSF patients.

Variation	All cases (54)		Follow up cases (54)	
	AIS (20)	NIS (34)	AIS (20)	NIS (34)
Sex (Male/Female)	9/11	16/18	9/11	16/18
Lesion site (left/right)	20/0	32/2	20/0	32/2
Median age at surgery (yr)	6	5	6	5
Type (Sinus/fistula)	20/0	33/1	20/0	33/1
Treatment before admission				
antibiotic	19	34	19	34
Incision and drainage	7	20	7	20
Open resection	1	3	1	3
Past history				
Repeated neck swelling	15	29	15	29
Neck abscess	12	21	12	21
Neck mass	4	3	4	3
Imaging exam				
Fiberoptic laryngoscopy (positive* / negative)	6/14	16/18	6/14	16/18
Enhanced CT (abnormal [†] / normal)	20/0	33/1	20/0	33/1
Ultrasound (abnormal [‡] / normal)	20/0	34/0	20/0	34/0
Length of hospital stay (median)	5	3	5	3
Complication				
Hoarseness	3	0	0	0
Dysphagia	0	0	0	0
Reddish swelling	0	4	0	0
Recurrence	0	0	0	0

AIS = acute inflammation stage, NIS = non infection stage.

* confirmed internal opening of sinus tract.

[†] CT revealed the shallower or disappearing pyriform sinus, soft tissue cellulitis, abscess, large cystic lesion with air and fluid, association or obscuration of the left superior thyroid lobe with the neck mass or abscess, gas-containing ducts originating from the pyriform fossa and tubular structures seen inside the thyroid gland.

[‡] detectable fistula (cable-like, tubular hypoechoic connected to body surface or subcutaneous), gas echo in the upper area of the ipsilateral thyroid or inflammatory-abscess formation or uneven hypoechoic signal closely related to thyroid in the deep soft tissue of the neck.

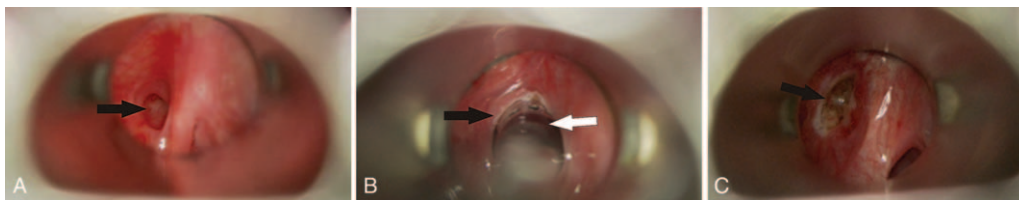


Figure 1. Endoscopic view of left pyriform sinus fistula. (A): view before coblation; (B): low-temperature plasma electrode in sinus tract during coblation; (C): view after coblation. black arrow, pyriform sinus fistula. White arrow, electrode.

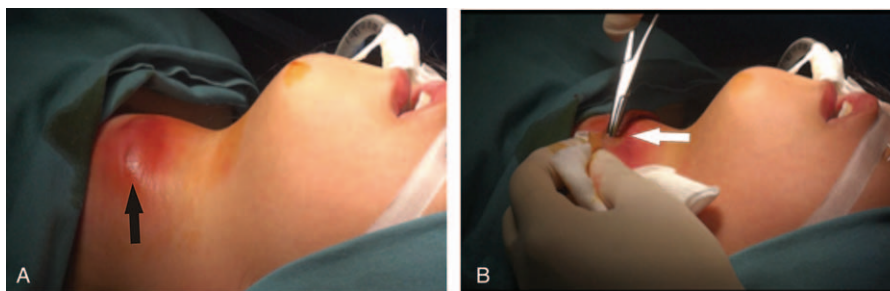


Figure 2. Incision and drainage of the neck abscess. (A): Routine disinfection of neck skin; (B): Placing drainage strip of iodoform. Black arrow, neck abscess. White arrow, drainage strip of iodoform.

endoscopic coblation, external incision and drainage of the neck abscess was performed yielding much purulent material. The wound was irrigated and drainage strip of iodoform was placed (Fig. 2 A,B).

All patients were fed via nasogastric tube for 2 weeks without any oral intake (including water) and treated with antibiotics for 7 to 10 days.

2.3. Determination of CPSF healing

Patients who met the following 2 criteria after endoscopic obliteration of the sinus tract were considered healed from CPSF:^[12–13]

1. absence of neck symptoms such as neck swelling and dysphagia or odynophagia;
2. laryngoscopy showing internal opening of sinus tract scar formation and closure.

3. Results

This study included 54 children with CPSF (Table 1). Among them, there were 25 males and 29 females aged 22 days to 14 years and 1 month, with a median age of 5 years and 2 months. The overwhelming majority of cases (96.3%) occurred on the left side. Of these cases, 98% were sinuses. There were 20 cases of AIS and 34 cases of NIS. Initial treatments at other hospitals included oral or intravenous antibiotics in 53 cases (98.1%), incision and drainage in 27 cases (12 cases a history of 1 procedure, 7 cases a history of 2 procedures, 8 cases a history ≥ 3 procedures) and failed open surgical resection in 4 cases. In our study, 44 patients (81.5%) presented with a recurrent neck reddish swelling (15 cases of AIS, 29 cases of NIS). Due to the rarity of pyriform sinus fistula, 46 cases (85.2%) experienced at least onetime misdiagnosis prior to diagnosis of CPSF: 33 patients

were misdiagnosed with neck abscess, 6 with acute thyroiditis and 7 with neck masses (2 with simple cyst, 2 with thyroglossal cyst, 1 with lymphangioma and 2 with hematoma).

In this study, all children underwent fiberoptic laryngoscopy, neck enhanced computed tomography (CT) scan, and neck ultrasound before endoscopic coblation. Fiberoptic laryngoscopy confirmed internal opening of sinus tract in 22 cases (6 in AIS and 16 in NIS). Enhanced CT scan showed abnormalities in 53 cases, and 35 cases (64.8%) were diagnosed with CPSF directly. CT revealed the shallower or disappearing pyriform sinus, soft tissue cellulitis, abscess, large cystic lesion with air and fluid, association or obscuration of the left superior thyroid lobe with the neck mass or abscess, gas-containing ducts originating from the piriform fossa and tubular structures seen inside the thyroid gland (Fig. 3 A,B). Ultrasonography indicated abnormalities in all cases, and the CPSF was diagnosed in 33 cases (61.1%). The main manifestations of these cases included: detectable fistula (cable-like, tubular hypoechoic connected to body surface or subcuta-

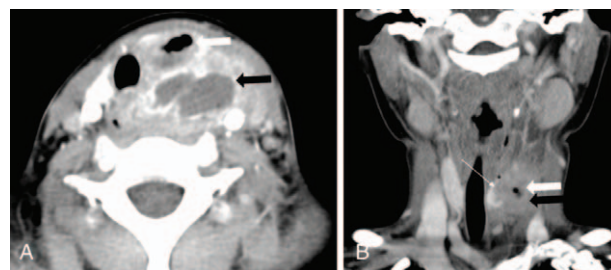


Figure 3. CT scan of neck. (A). Axial view with hypodense, rim-enhancing fluid collection in left neck consistent with deep cervical abscess adjacent to obscured left thyroid gland; (B). coronal view with effacement of left superior thyroid lobe adjacent to soft tissue inflammation and multiloculated abscess. Thin arrow, left superior thyroid lobe. Black arrow, abscess. White arrow, air.

neous), gas echo in the upper area of the ipsilateral thyroid or inflammatory-abscess formation or uneven hypoechoic signal closely related to thyroid in the deep soft tissue of the neck.

The sinus tracts were confirmed with suspension laryngoscope in all patients. The endoscopic coblation technique was performed in 54 patients as described (Fig. 1). The AIS cases experienced neck abscess incision and drainage as a concomitant procedure during the same anesthesia. Of the 34 cases in NIS, 4 cases appearing reddish swelling of the neck on the fourth, fifth, sixth, and seventh days after coblation underwent abscess incision and drainage. There were only transient hoarseness in 3 patients of the 20 cases in AIS, all of which normalized within 1 month. The AIS cases were hospitalized for an average of 5 days, and the NIS cases were hospitalized for an average of 3 days. The sinus tracts were closed by fiberoptic laryngoscopy, and all cases experienced no recurrence, permanent vocal cord paralysis, pharyngeal fistula and massive hemorrhage after their first endoscopic coblation of the sinus tract in the follow up of 3 to 28 months.

4. Discussion

CPSF is a rare anomaly from failure of the third and fourth brachial clefts to involute and few studies in the literature have more than a handful of patients.^[2,3] There is no significant difference between males and females and 90% of cases occur on the left side.^[14] The asymmetric development of branchial apparatus may be the cause of the left-sided predominance of CPSF.^[5] In this study, 52 children exhibited CPSF on the left side (96.3%), and the male to female ratio was 1: 1.16, which was consistent with the literatures.^[3,15]

Clinically, there can be only 1 internal opening but no external opening named sinus. An opening in the skin can also be caused by the neck skin rupture or incision and drainage due to abscesses, which can form a fistula. Most lesions are sinuses rather than fistulas and consistent with this, 98% were sinuses (53/54) in our study. In clinical practice, patients often suffer from a long time repeated infection before being diagnosed and infections are often misdiagnosed as “neck abscess” leading to multiple abscess incisions and drainage though this is not an effective treatment for CPSF.^[8] In our study, of the 53 cases with a history of antibiotic treatment, 44 cases of repeated neck redness and swelling, 46 cases experience 1 misdiagnosis at least (33 patients were misdiagnosed with neck abscess, 6 with acute thyroiditis and 7 with neck masses) and 27 presented a history of incision and drainage from once to 7 times, consistent with the literature. In cases of fibrous capsule, prominent vascularity, robust lymphatic drainage and high iodine ion concentration, the thyroid tissues are not prone to primary bacterial infection nor infections of adjacent tissues and organs. However, if the fistula passes through or terminates in the thyroid, inflammation can occur. Based on these anatomic course and fusion, clinical manifestations of recurrent deep neck infections or suppurative thyroiditis, especially occurring in the left side, CSPF should be considered.^[2,4]

Although the existence of internal opening of the sinus tract under suspension laryngoscopy is the gold standard for the diagnosis of CSPF, but general anesthesia limited widespread application of this examination. Some experts recommend the fiberoptic laryngoscopy, however, we have found that it is difficult to find all sinus tracts, possibly due to the inability to fully expose.^[8] In this study, 22 cases (40.74%) examined with

fiberoptic laryngoscopy revealed the internal opening of CPSF. In our experience, the endoscope would offer some advantages, namely, popular use in pediatric general surgical practice, reaching pyriform sinus easily, and a good stretching effect on the wrinkly mucosa. Other experts believe that CT can not only provide typical imaging indications,^[16–17] the airspace, air abscesses in the medial and inferior margin of cricothyroid joint or upper thyroid of the thyroid gland (Fig. 3 A,B), but also clarify the length and position of the fistula and its relationship with adjacent structures. CT may also guide precision surgery through 3D reconstruction, which is an effective method of examination.^[17] However, the positive rate of CT diagnosis fluctuates greatly (11%–85.7%) and is closely related to the diagnosis experience of doctors.^[18] In this study, 53 cases of enhanced CT showed abnormality, and 35 cases (64.8%) of enhanced CT were directly diagnosed as CPSF, which is consistent with the rate reported in the literature. Due to the radiation associated with CT, ultrasound technology has been considered a noninvasive alternative providing real-time dynamics and good repeatability. As such it is recommended as the preferred inspection method for CSPF.^[3] It can be used to detect cord-like, low-echo tubular structures connected to body surface or subcutaneously (Fig. 4). The positive rate of diagnosis of CSPF with ultrasound can reach 75% to 87.5%.^[19] In this study, the ultrasound showed abnormalities in all cases, of which 33 cases (61.1%) were diagnosed as CPSF. Like CT, its diagnostic efficacy is believed to be closely related to the diagnostic experience of the operant. Barium esophagography has also been recommended by many scholars^[20–21] predominantly because it can show the existence and route of fistula simultaneously. Nonetheless, it may fail to demonstrate a CPSF during acute inflammation because of closure of the sinus tract by surrounding inflammatory reaction and soft tissue edema. Therefore, it is recommended that this test be performed only during the inflammatory quiescent stage, which is generally considered to be 6 to 8 weeks after control of inflammation.^[22] In view of the difficulty for infants and young children to cooperate with swallowing barium,^[23] CT or magnetic resonance imaging is typically recommended.^[17,24] Due to the high cost and long cycle of magnetic resonance imaging, it is not recommended that it as a first-line diagnostic tool for neck inflammatory lesions.^[3] Based on the aforementioned advantages and disadvantages, we recommend enhanced CT scan, fiberoptic laryngoscopy and ultrasound as the first choice in the diagnosis of CPSF.

The traditional methods of treating CSPF include antibiotics, abscess incision and drainage in AIS as well as open surgery in NIS.^[25] This procedure however, can be traumatic, complicated, continual recurrence and rife with many complications.^[2,4] In 1998, Jordan et al.^[26] first reported that 7 patients with CPSF were treated with endoscopic electrocautery with no obvious signs of complications or recurrence during the 18-month follow-up period. Since then, many clinicians^[8–10] have tested endoscopic techniques such as electrocautery, chemocauterization (trichloroacetic acid), CO2 laser, fibrin glue, and suture to treat CSPF. The therapeutic aim is to make the internal opening of CPSF adhere and close to avoid secondary infections caused by food debris, pharyngeal secretions, bacteria and viruses from upper respiratory and digestive tracts entering the fistula. Compared to the conventional open surgery, the advantages of endoscopic treatment are simpler manipulation, shorter operative time, smaller risk of surgical trauma, fewer complications, and a more preserved, scar-free after operation. Additionally, the

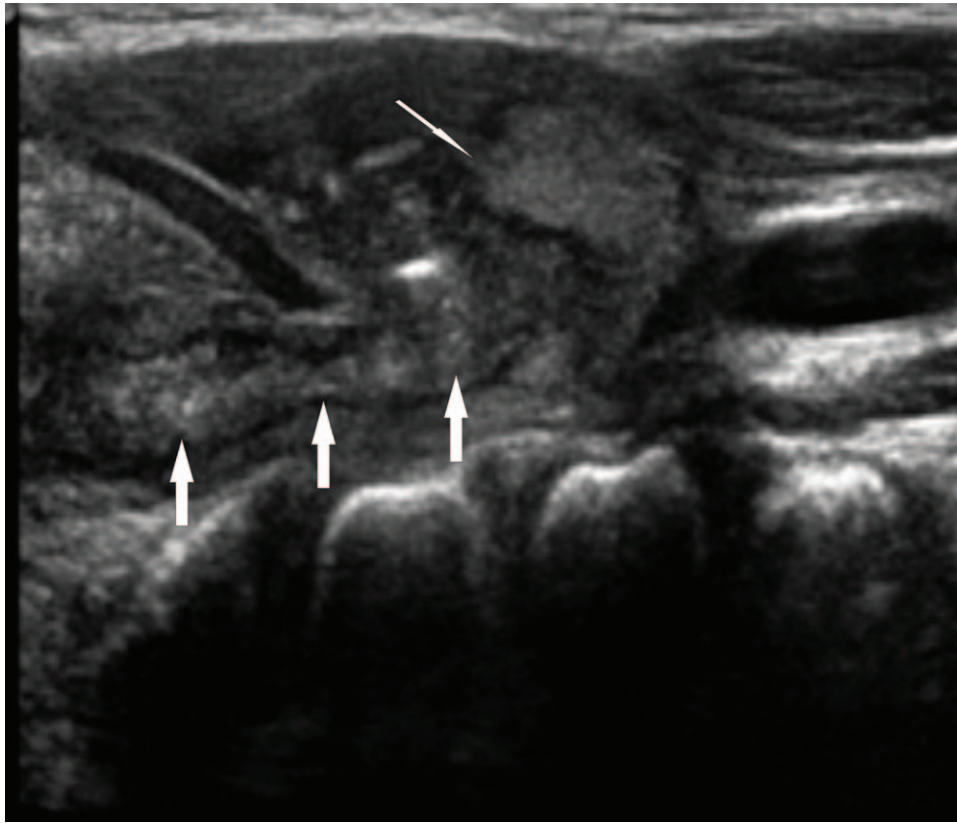


Figure 4. Ultrasound of neck. The diameter of the fistula is significantly thickened, and the boundary between it and the surrounding tissues is unclear. Thin arrow, left superior thyroid lobe. White arrow, fistula.

surgery is highly repeatable and benefits include shortened hospital stay, lower surgical cost, and comparable efficacy. However, these endoscopic techniques are not perfect, and as time passes by, many problems have occurred. For example, electrocautery and CO₂ laser cauterization produce local heat signatures between 400 to 1000°C, greatly increasing the risk of thermal damage to surrounding tissues, particularly injury of the superior laryngeal nerve and recurrent laryngeal nerve. Furthermore, laser fires need to be prevented.^[6] Chemocauterization such as trichloroacetic acid, the depth and range of cautery is not easy to control and multiple cauterizations are often required, which may lead to esophagostenosis^[27] and postoperative hoarseness.^[12] Other endoscopic sinus tract closure techniques such as internal fistula suture after cautery or fibrin glue have been described in case reports. Currently, NIS is a necessary condition for not only traditional open surgery but also endoscopic treatments for CSPF, to prevent infectious complications, inadvertent injury to the recurrent laryngeal nerve and incomplete resection.^[8,11] As such, it is extremely urgent to explore a safer and simpler minimally invasive therapy that can be implemented as early as AIS. In our study, we adopted endoscopic coblation to treat CPSF in children. Coblation is a new technique that can ablate tissue by generating a field of ionized sodium molecules through a medium of normal saline. The technique depends on the low-temperature plasma electrode device which uses bipolar radiofrequency energy, at a much lower frequency than standard bipolar diathermy, to ablate and coagulate soft tissue. During coblation, conductive saline solution is converted in the gap between the device tip and the

tissue into an ionized plasma layer. Where this plasma layer meets the tissue, there is competent energy to break molecular bonds, resulting in molecular dissociation. Now let's share some of our experiences in endoscopic coblation: do not use force to ablate the internal opening of sinus tract, but gently contact the mucous membrane through the attraction of low-temperature plasma electrode, pay attention to direction and keep a depth about 0.5 cm into the fistula with a diameter of ~0.5 cm around the fistula to avoid nerve injury. Incision and drainage of internal opening can also perform by coblation. We successfully used radiofrequency ablation to close the internal opening of sinus tracts under suspension laryngoscope and all of the 54 cases indicated effective closure with no recurrence, vocal cord paralysis or other complications after their first endoscopic coblation in the follow up of 3 to 28 months. Four children of the 34 cases in NIS appeared reddish swelling of the neck on the 4th, 5th, 6th, and 7th days after coblation and then underwent abscess incision and drainage. Of the 20 cases in AIS, there were no postoperative complications observed except transient hoarseness in 3 patients, all of which returned to normal within 1 month. We exploited the following characteristics of low-temperature plasma cautery:

1. it can work at relatively low temperatures (40 –70°C) by integrating saline flushing and suction, minimizing thermal damage to tissues, nerves and vessels around the sinus tract;
2. it can close the microvessels in the mucosa tissue surrounding sinus tract, reducing surgical bleeding;
3. it has a relatively short operation time, usually 10 to 20 minutes, which can reduce the compression of the patient's

oral mucosa and related anatomical structures by the suspension laryngoscope, reducing the child's postoperative neck pain;

4. its oral and minimally invasive nature can circumvent the need for neck incisions, minimizing trauma and scarring in the neck after surgery. This characteristic can also allow repeated cauterization for children with relapses.
5. Finally, for patients with neck abscesses, low temperature plasma surgery can be performed concurrently with incision and drainage of the abscess.

Considering the advantages of endoscopic coblation compared with traditional open surgery or other endoscopic cauterizations, we advocate this minimally invasive as primary treatment for CPSF. This study highlights that neck abscess incision and drainage can be performed simultaneously with this minimally invasive approach for children in AIS. All parents should be fully informed in advance that neck abscesses may form after endoscopic coblation and performed incision and drainage, but it can be cured eventually.

The limitations of this study are its retrospective nature, small numbers and short clinical follow-up. In addition, the endoscopic cautery of the sinus tract may lead to the formation of a closed cavity which can either remain closed and absorbed or may close and persist, the latter being prone to infection.^[6] Hence, large, multicenter prospective and controlled clinical studies with long-term follow-up are necessary.

5. Conclusions

Endoscopic coblation is an effective and safe approach for children with CPSF, neck abscess incision and drainage could be performed simultaneously in acute infection stage. We advocate using this minimally invasive technique as first line of treatment for CPSF.

Acknowledgments

We thank the support from our department and colleague.

Author contributions

Conceptualization: Wei Chen, Xiaoyan Li.

Data curation: Wei Chen, Jiarui Chen, Fang Chen, Jiali Wu, Limin Zhao, Hongming Xu, Xiaoyan Li.

Formal analysis: Wei Chen, Jiarui Chen, Fang Chen, Limin Zhao, Hongming Xu.

Funding acquisition: Xiaoyan Li.

Investigation: Wei Chen, Jiali Wu, Xiaoyan Li.

Methodology: Wei Chen, Jiarui Chen, Jiali Wu, Xiaoyan Li.

Project administration: Wei Chen, Xiaoyan Li.

Resources: Xiaoyan Li.

Supervision: Wei Chen, Xiaoyan Li.

Validation: Wei Chen, Jiarui Chen, Xiaoyan Li.

Visualization: Wei Chen, Jiali Wu.

Writing – original draft: Wei Chen, Jiarui Chen, Fang Chen, Jiali Wu, Limin Zhao, Hongming Xu, Xiaoyan Li.

Writing – review & editing: Wei Chen, Jiarui Chen, Fang Chen, Jiali Wu, Limin Zhao, Hongming Xu, Xiaoyan Li.

References

- [1] Zhang P, Tian X. Recurrent neck lesions secondary to pyriform sinus fistula. *Eur Arch Otorhinolaryngol* 2016;273:735–9.

- [2] Ishinaga H, Kobayashi M, Qtsu K, et al. Endoscopic electrocauterization of pyriform sinus fistula. *Eur Arch Otorhinolaryngol* 2017;274:3927–31.
- [3] Dongbin A, Joon LG, Ho SJ. Ultrasonographic characteristics of pyriform sinus fistulas involving the thyroid gland. *J Ultrasound Med* 2018;37:2631–6.
- [4] Abbas PI, Roehm CE, Friedman EM, et al. Successful endoscopic ablation of a pyriform sinus fistula in a child: case report and literature review. *Pediatr Surg Int* 2016;32:623–7.
- [5] Lulu Wang, Jianzhong Sang, Yamin Zhang, et al. Evaluation of endoscopic coblation treatment for obliteration of congenital pyriform sinus fistula. *Acta Otolaryngol* 2018;138:574–8.
- [6] Kamide D, Tomifuji M, Maeda M, et al. Minimally invasive surgery for pyriform sinus fistula by transoral videolaryngoscopic surgery. *Am J Otolaryngol* 2015;36:601–5.
- [7] Lachance S, Chadha NK. Systematic review of endoscopic obliteration techniques for managing congenital piriform fossa sinus tracts in children. *Otolaryngol Head Neck Surg* 2016;154:241–6.
- [8] Chen EY, Inglis AF, Ou H, et al. Endoscopic electrocauterization of pyriform fossa sinus tracts as definitive treatment. *Int J Pediatr Otorhinolaryngol* 2009;73:1151–6.
- [9] Watson GJ, Nichani JR, Rothera MP, et al. Case series: endoscopic management of fourth branchial arch anomalies. *Int J Pediatr Otorhinolaryngol* 2013;77:766–9.
- [10] Sun JY, Berg EE, McClay JE. Endoscopic cauterization of congenital pyriform fossa sinus tracts: an 18-year experience. *JAMA Otolaryngol Head Neck Surg* 2014;140:112–7.
- [11] Nicoucar K, Giger R, Pope HG Jr, et al. Management of congenital fourth branchial arch anomalies: a review and analysis of published cases. *J Pediatr Surg* 2009;44:1432–9.
- [12] Cha W, Cho SW, Hah JH, et al. Chemocauterization of the internal opening with trichloroacetic acid as first-line treatment for pyriform sinus fistula. *Head Neck* 2013;35:431–5.
- [13] Pereira KD, Smith SL. Endoscopic chemical cautery of piriform sinus tracts: a safe new technique. *Int J Pediatr Otorhinolaryngol* 2008;72:185–8.
- [14] Sandborn WD, Shafer AD. A branchial cleft cyst of fourth pouch origin. *J Pediatr Surg* 1972;7:82.
- [15] Mali VP, Prabhakaran K. Recurrent acute thyroid swellings because of pyriform sinus fistula. *J Pediatr Surg* 2008;43:27–30.
- [16] Miyauchi A, Tomoda C, Uruno T, et al. Computed tomography scan under a trumpet maneuver to demonstrate piriform sinus fistulae in patients with acute suppurative thyroiditis. *Thyroid* 2005;15:1409–13.
- [17] Haitao Z, Xianmin X, Shan Z, et al. Diagnosis and management of pyriform sinus cyst in neonates: 16-year experience at a single center. *J Pediatr Surg* 2017;52:1989–93.
- [18] Huang YC, Peng SF, Hsu WC. KTP laser assisted endoscopic tissue fibrin glue biocauterization for congenital pyriform sinus fistula in children. *Int J Pediatr Otorhinolaryngol* 2016;85:115–9.
- [19] Liu Z, Tang SS. Diagnosis of pyriform sinus fistula in children via ultrasonography. *Am J Otolaryngol* 2013;34:579–81.
- [20] Wang HK, Tiu CM, Chou YH, et al. Imaging studies of pyriform sinus fistula. *Pediatr Radiol* 2003;33:328–33.
- [21] Xiao X, Zheng S, Zheng J, et al. Endoscopic-assisted surgery for pyriform sinus fistula in children: experience of 165 cases from a single institution. *J Pediatr Surg* 2014;49:618–21.
- [22] Chauhan NS, Sharma YP, Bhagra T, et al. Branchial fistula arising from pyriform fossa: CT diagnosis of a case and discussion of radiological features. *Clin Imaging* 2012;36:591–4.
- [23] Ahn D, Sohn JH, Kim H, et al. Clinical and microbiological differences between pyriform sinus fistulae in pediatric and non-pediatric patients. *Auris Nasus Larynx* 2015;42:34–8.
- [24] Pan J, Zou Y, Li L, et al. Clinical and imaging differences between neonates and children with pyriform sinus fistula: which is preferred for diagnosis, computed tomography, or barium esophagography? *J Pediatr Surg* 2017;52:1878–81.
- [25] Yolmo D, Madana J, Kalaiarasi R, et al. Retrospective case review of pyriform sinus fistulae of third branchial arch origin commonly presenting as acute suppurative thyroiditis in children. *J Laryngol Otol* 2012;126:737–42.
- [26] Jordan JA, Graves JE, Manning SC, et al. Endoscopic cauterization for treatment of fourth branchial cleft sinuses. *Arch Otolaryngol Head Neck Surg* 1998;124:1021–4.
- [27] Wong PY, Moore A, Daya H. Management of third branchial pouch anomalies—An evolution of a minimally invasive technique. *Int J Pediatr Otorhinolaryngol* 2014;78:493–8.