

A case series of orthodontic traction of maxillary impacted canine

ABSTRACT

Impacted maxillary canine is frequently encountered in clinical practice. Being the cornerstone of the dentition, orthodontic traction of impacted canine is always desirable in order to achieve successful functional occlusion. The aim of this case series is to illustrate different methods employed for orthodontic traction of maxillary impacted canine.

Keywords: Impaction, maxillary canine, surgical exposure

INTRODUCTION

Impaction of maxillary canine is frequently encountered in clinical practice. Canine plays an important role in facial appearance, dental esthetics, arch development, and occlusion.^[1] Canine impaction is more than twice common in maxilla as compared to mandible.^[2] The incidence of canine impaction is twice common in females as compared to males. Palatal canine impaction is more common as compared to labial canine impaction.

Several localized, systemic, and genetic etiologic factors have been proposed for impacted canines.

The most common methodology acquired to move the impacted canines to the desired place is to surgically expose the canine, place a bonded attachment overexposed area, and then use orthodontic traction to move teeth.

The purpose of this case series is to clinically exhibit the different methods used for orthodontic assisted eruption of impacted maxillary canine.

CASE REPORTS

Case report-1

- A 14-year-old female patient reported to the department of orthodontics with chief complaints (1) forward

placement of upper front teeth and (2) missing tooth in the left upper side region of the mouth. Intraoral examination revealed proclined incisors, class I molar relationship on both sides, and missing left maxillary canine [Figure 1a and b]. A bulge was present on labial alveolar mucosa in distal area with respect to left maxillary incisors which was hard on palpation. Orthopantomograph (OPG) unveiled impacted left maxillary canine [Figure 1c]. Fixed mechanotherapy using McLaughlin, Bennett, and Trevisi technique was started

- Open window was created over the canine bulge. A lingual button was bonded overexposed surface. Using 0.017" × 0.025" titanium–molybdenum alloy (TMA) cantilever spring was made. One end of the cantilever spring was inserted into

SNEHA SINGH, AJIT VIKRAM PARIHAR, THAKUR PRASAD CHATURVEDI, NEETEESH SHUKLA

Department of Orthodontics and Dentofacial Orthopedics, Faculty of Dental Sciences, Institute of Medical Sciences, Banaras Hindu University, Varanasi, Uttar Pradesh, India

Address for correspondence: Prof. Ajit Vikram Parihar, Department of Orthodontics and Dentofacial Orthopedics, Faculty of Dental Sciences, Institute of Medical Sciences, Banaras Hindu University, Varanasi - 211 005, Uttar Pradesh, India. E-mail: drajitparihar@gmail.com

Received: 24 October 2020, **Revised:** 29 January 2021, **Accepted:** 08 April 2021, **Published:** 20 April 2022

Access this article online	
Website: www.njms.in	Quick Response Code 
DOI: 10.4103/njms.NJMS_235_20	

This is an open access journal, and articles are distributed under the terms of the Creative Commons Attribution-NonCommercial-ShareAlike 4.0 License, which allows others to remix, tweak, and build upon the work non-commercially, as long as appropriate credit is given and the new creations are licensed under the identical terms.

For reprints contact: WKHLRPMedknow_reprints@wolterskluwer.com

How to cite this article: Singh S, Parihar AV, Chaturvedi TP, Shukla N. A case series of orthodontic traction of maxillary impacted canine. Natl J Maxillofac Surg 2022;13:147-52.

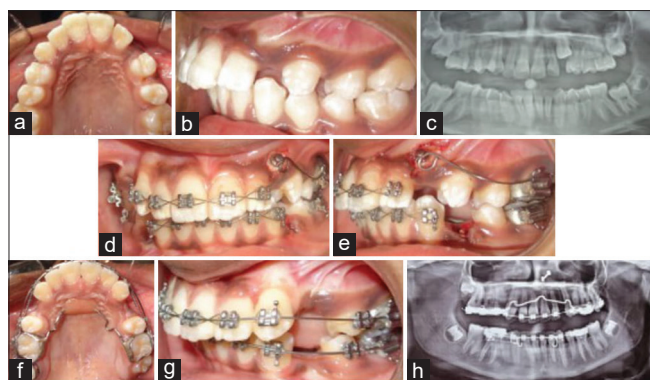


Figure 1: (a) Maxillary occlusion, and (b) left buccal occlusion view showing missing left maxillary canine. (c) Orthopantomograph showing impacted left maxillary canine. (d and e) Frontal and left buccal occlusion view respectively, showing cantilever spring made up of 0.017" X 0.025" titanium-molybdenum alloy. (f) Maxillary occlusion view, (g) left buccal occlusion view, and (h) Orthopantomograph after alignment of left maxillary canine

the accessory tube and another end was tied with ligature wire on lingual button [Figure 1d and e]. After 1 and ½ month, the canine was erupted into the arch. A bracket was bonded over erupted left maxillary canine and alignment was started. Figure 1f and g shows an intraoral view and Figure 1h shows OPG after alignment of left maxillary canine.

Case report-2

- A 24-year-old female student has been referred for orthodontic management of impacted maxillary left canine. Intraoral examination revealed missing left maxillary canine and lower right mandibular first molar with class I molar relationship on the left side and deep bite [Figure 2a and b]. A bulge was present palatally near edentulous area. OPG revealed palatally impacted left maxillary canine in Lindauer sector 3^[3] [Figure 2c]
- A flap surgery was performed to expose palatally impacted canine 23 and lingual button was bonded overexposed surface [Figure 2d]. Temporary anchorage device (TAD) was inserted palatally between the second premolar and first molar on the left side. TAD was loaded 1 week after its placement with 0.017" × 0.025" TMA single cantilever spring. Other end of this spring was tied with ligature wire on lingual button [Figure 2e]. After 1 month, the canine was erupted in the oral cavity [Figure 2f]. Fixed anterior bite plate was cemented and orthodontic traction was carried using active tie back from canine bracket to main archwire [Figure 2g]. Figure 2h and i shows maxillary occlusal view and OPG, respectively, after alignment of left maxillary canine.

Case report-3

- A 15-year-old male patient presented in the department of orthodontics with irregular placement of front teeth.

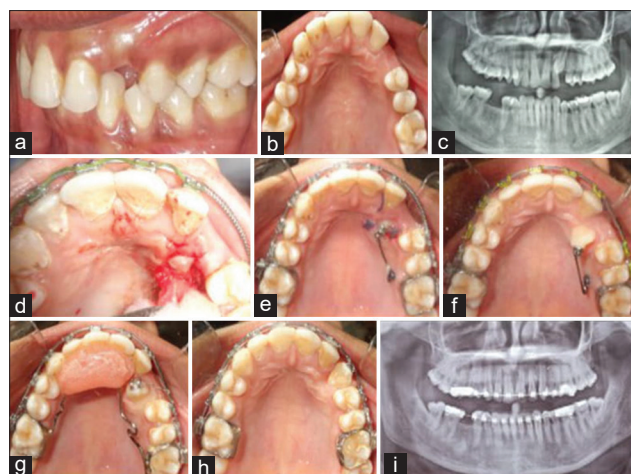


Figure 2: (a) Left buccal occlusion, and (b) maxillary occlusion view showing missing left maxillary canine. (c) Orthopantomograph revealed impacted left maxillary canine in Lindauer sector 2. (d) Surgical exposure of impacted left maxillary canine. (e) Temporary anchorage device supported cantilever spring (0.017" X 0.025" titanium-molybdenum alloy). (f and g) Maxillary occlusion view after eruption of maxillary left canine. (h and i) Maxillary occlusion view and Orthopantomograph respectively after alignment of left maxillary canine

Intraoral examination shows the presence of bilateral deciduous maxillary canine on both sides with anterior crossbite involving both maxillary central incisors and maxillary right lateral incisor and deciduous canine [Figure 3a and b]. Crossbite was also present with respect to the right maxillary first molar. OPG revealed impacted right maxillary canine in Lindauer sector 2 [Figure 3c]

- After alignment and leveling, surgical exposure of impacted right maxillary canine was done. Lingual button was bonded and ligature tie was given from button to main archwire [Figure 3d and e]. Elastic was given from the lingual button to the right mandibular canine for buccal and caudal eruption of right maxillary canine [Figure 3f]. Once the canine erupted into the arch, alignment and leveling was carried out. The aligned right maxillary canine is shown in Figure 3g and h along with OPG in Figure 3i.

Case report-4

- A 17-year-old female patient reported with a chief complaint of forward placement of teeth. Intraoral examination shows the presence of bilateral retained deciduous maxillary canine [Figure 4a and b]. OPG revealed bilateral palatally impacted canine in Lindauer sector 3 with congenital missing of lower central incisors [Figure 4c]
- After alignment and leveling, flap surgery was performed to expose both palatally impacted canines. Lingual button was bonded on both canines [Figure 4d].

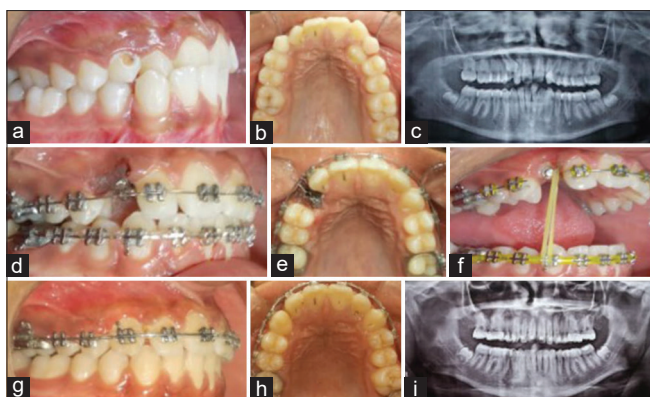


Figure 3: (a) Right buccal occlusion and (b) maxillary occlusion view showing bilateral retained deciduous maxillary canine and missing right maxillary canine. (c) Orthopantomograph pretreatment showing impacted right maxillary canine in Lindauer sector 2. (d) Right buccal occlusion and (e) maxillary occlusion view after surgical exposure of impacted right canine. (f) Interarch elastic from lingual button bonded to impacted right maxillary canine to lower right mandibular canine. (g) right buccal occlusion, (h) maxillary occlusion, and (i) Orthopantomograph after alignment of right maxillary canine

Kilroy spring was then engaged onto base archwire 0.019" × 0.025" SS over the impacted canine region. Then, the spring was activated by passing ligature tie through helix of vertical loop of spring and tying another end to lingual button bonded over impacted canine [Figure 4e and f]. Figure 4g and h represents intraoral view and Figure 4i displays OPG after alignment of left maxillary canine.

Case report-5

- A 15-year-old male came to the department of orthodontics with a chief complaint of forward placement of front teeth. On intraoral examination, left maxillary canine was missing. A bulge is present palatally in the left lateral incisor region [Figure 5a and b]. OPG revealed palatally impacted canine in Lindauer sector 4 [Figure 5c]
- After alignment and leveling, surgical exposure of the canine was done. An open window was created and lingual button was bonded overexposed crown. Modified ballista spring was used to provide extrusive force to impacted canine, with 0.019" × 0.025" SS base archwire in maxillary arch [Figure 5d and e]. Maxillary occlusion and left buccal occlusion view after alignment of left maxillary canine is shown in Figure 5f and g correspondingly with OPG in Figure 5h.

Case report-6

- A 13-years-old female presented with a chief complaint of forward placement of lower front teeth. Intraoral examination shows missing right maxillary canine along with anterior crossbite. A bulge was present labially

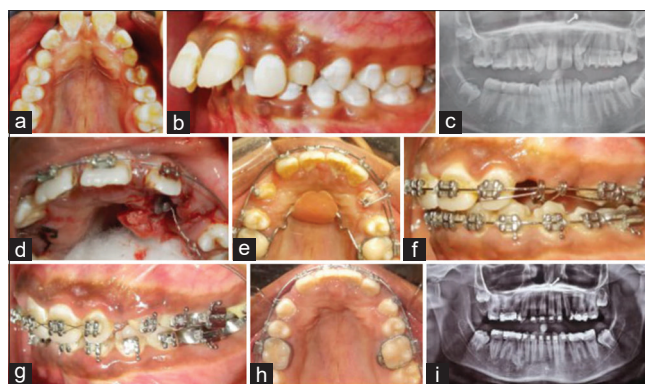


Figure 4: (a) Maxillary occlusion view showing bilateral retained deciduous maxillary canine and absence of permanent right and left maxillary canine. (b) Left buccal occlusion. (c) Orthopantomograph revealed bilateral impacted maxillary canine in Lindauer sector 3. (d) Surgical exposure of left impacted maxillary canine. (e and f) Kilroy spring was used to provide eruptive force to left maxillary impacted canine. (g) Left buccal occlusion, (h) Maxillary occlusion view, and (i) Orthopantomograph after alignment of left maxillary canine

which is hard on palpation [Figure 6a and b]. OPG revealed impacted right maxillary canine [Figure 6c]

- After correction of anterior crossbite, a window was created over canine bulge and lingual button was bonded. Using piggyback technique with round wire NiTi, orthodontic traction was started [Figure 6d and e]. After 1 and ½ month, bracket was bonded and alignment and leveling was carried out. Figure 6f-h represents the present stage of treatment after alignment of right maxillary canine.

DISCUSSION

Diagnosis of impacted maxillary canine plays an important role to determine the right time to intervene. Clinical examination involves inspection which includes lateral incisor inclination, color and mobility of deciduous canine, and location of canine bulge if present. Palpation should be done buccally as well as palatally with the pulp of index finger from the proximity of lateral incisors to the first premolar region. Usually, OPG and occlusal radiographs are employed to find the position of impacted canine, often assisted by IOPA using same-lingual-opposite-buccal rule. This is important in cases where root of impacted canine is in close vicinity/overlapping/crossing another tooth root. Dentascan/cone-beam computed tomography of particular area is advocated to know the exact root position of impacted canine in relation to the surrounding structures and plan accordingly proper direction of force to be applied without affecting nearby structures.

Observation, intervention, relocation, and extraction are the treatment options for impacted tooth.^[4] Various methods till now have been developed for orthodontic traction of

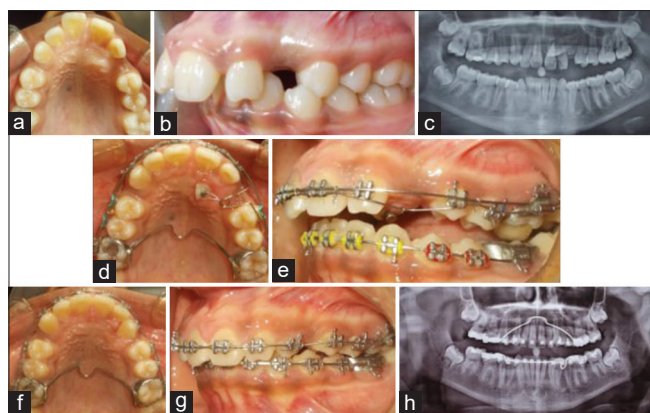


Figure 5: (a) Maxillary occlusal view display missing left maxillary permanent canine and a bulge palatally to left maxillary lateral incisor. (b) Left buccal occlusion view. (c) Orthopantomograph revealed impacted left maxillary canine in Lindauer sector 4. (d) Maxillary occlusal, and (e) left buccal occlusion view showing modified ballista spring to provide lateral and eruptive force to impacted left maxillary canine. (f) Maxillary occlusion, (g) left buccal occlusion, and (h) Orthopantomograph after alignment of left maxillary canine

impacted canine. Choice of method depends on various factors, for example, position of impacted canine, anchorage demands, etc.

A cantilever or long arm wire is inserted into auxiliary tube of molar band and bent passively in occlusal direction. It is activated by tying it to canine attachment, thereby creating a second order couple in molar tube which tends to tip molar crown mesially. Activation of cantilever spring creates an extrusive force on canine and intrusive force on molar.^[5] Tendency of molar to tip forward and intrude is minimized by joining them together with the nance palatal arch. Cantilever mechanics allow an optimal control of arch form and shortens treatment duration. Based on the impacted canine analysis, the cantilever was activated to verticalize canine. Force delivered by cantilever spring was optimal and consistent in magnitude. However, it did not allow for a proper correction of torque because of single-point force application. Use of TAD prevents reactionary intrusive force as well as moment of the couple that tend to tip molar mesially.

Kilroy spring delivers slow, continuous, and constant vertical and lateral force which slides onto a rectangular archwire over the site of palatally impacted canine. Activation of spring is done by passing ligature through helix at the apex of vertical loop and then the loop is directed toward the impacted canine and ligature is tied with canine attachment.^[6] Continuous rectangular archwire and reciprocal forces from the incisal third of adjacent teeth contacted by lateral extensions of spring provide support to activated Kilroy spring.

Ballista loop is a simple, convenient method of applying vertical force to palatally impacted canine. 0.018" continuous

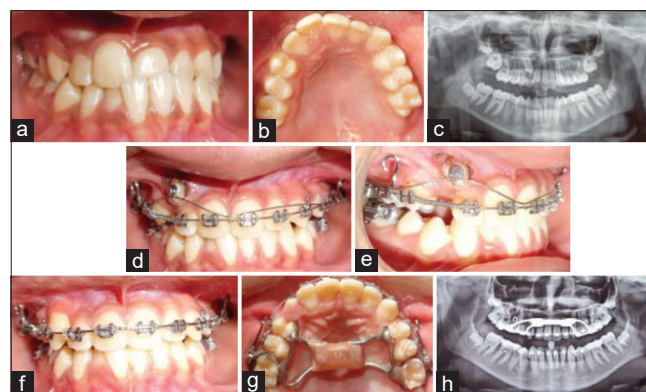


Figure 6: (a) Frontal occlusion, and (b) Maxillary occlusion view showed absence of right maxillary canine. (c) Orthopantomograph revealed impacted right maxillary canine. (d) Window was created over bulge. Piggy archwire 0.014" Niti was ligated to impacted canine button with base archwire of 0.019" X 0.025" SS. (f) Frontal occlusion, (g) maxillary occlusion view, and (h) Orthopantomograph after alignment of right maxillary canine

SS archwire is used to make ballista spring. By lengthening vertical part of the spring, it adds a force toward the palate midline and by shortening their vertical arm, it adds force toward the dental arch. It was used to prevent facial pull of canine to avoid resorption of lateral incisor root.^[7]

Piggyback technique uses double wire, i.e., auxiliary and base wire. This technique uses rigid stainless-steel base archwires which tend to increase stabilizing force on abutment teeth and auxiliary super elastic NiTi wire to provide inherent flexibility to correct malposed tooth by providing continuous eruptive force. Subsequent alignment using the piggyback technique was done by ligating auxiliary archwire to canine attachment and inserting ends into auxiliary tube of molar band. The main disadvantage of this technique is increased friction due to double wires and it also requires careful consideration of force levels.

All the above-mentioned intra-arch mechanics may tend to tip or intrude the adjacent teeth. As an alternative, vertical eruptive forces can be applied using intermaxillary elastic. In the mentioned case, the lower arch was stabilized with rigid rectangular stainless-steel wire. Upper anterior and posterior segments were made using the rectangular stainless-steel wire, leaving canine to be erupted. However, use of intermaxillary elastic requires patient compliance.

All the cases and mechanics employed are summarized in Table 1 and the direction of force used to bring impacted canine into arch for few cases is shown in Figures 7 and 8.

Appointments were scheduled at the intervals of 3 weeks for regular monitoring and other adjustments.

Table 1: Summary of all cases

	Case 1	Case 2	Case 3	Case 4	Case 5	Case 6
Age (years)	14	24	15	17	15	13
Gender	Female	Female	Male	Female	Male	Female
Labial/palatal	Labial	Palatal	Palatal	Palatal	Palatal	Labial
Distance from upper occlusal plane in OPG (mm)	10	9	10	11mm	10	12
Angle between long axis of canine and midline between central incisors	0	25	28	31	55	27
Prognosis	Good No horizontal overlap of canine over incisors Presence of root apex over canine position	Average Lindauer sector 3 Complete overlap of canine crown over lateral incisor root Presence of root apex over first premolar	Average Lindauer sector 2 Canine crown overlap half root width of lateral incisor Presence of root apex over first premolar	Average Lindauer sector 3 Complete overlap of canine crown over lateral incisor root Presence of root apex over first premolar	Poor Lindauer sector 4 Complete overlap of canine crown over central and lateral incisors root-canine angulation to midline 58°	Average Canine crown overlapping less than half width of lateral incisor root Presence of root apex over first premolar
Mechanics employed	Molar supported cantilever spring	TAD supported cantilever spring	Inter-maxillary elastic	Kilroy spring	Modified ballista spring	Piggy archwire
Remarks	Cantilever spring easy to fabricate and biomechanically effective for occlusal movement.	Simultaneous alignment and leveling of maxillary teeth and orthodontic assisted canine eruption was carried out	Patient co-operation was required for elastic wearing	Inherent flexibility Direction and magnitude of force can be adjusted by adjusting the vertical loop.	This spring prevent a facial pull of canine to avoid resorption of roots of incisors and the spring was activated to deliver extrusive force to canine.	NiTi wire used as auxiliary wire provide light, relatively constant force to canine Increased friction due to double archwires

OPG: Orthopantomogram, TAD: Temporary anchorage devices

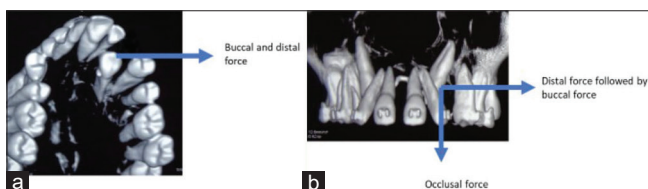


Figure 7: Dentascan of maxillary arch showing maxillary palatal canine impaction (a) case 2 and (b) case 4, first eruptive force was applied followed by distal and buccal force to bring the maxillary canine into arch

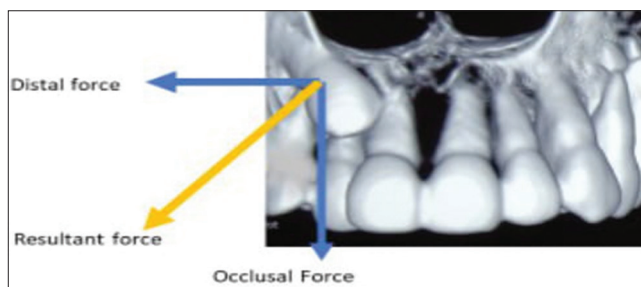


Figure 8: Dentascan (case 6) maxillary arch showing labial impaction of right canine, forced applied was first in distal direction so as to move canine crown distally away from root of lateral incisor followed by occlusal force to bring canine into alignment in the arch

Time taken by different methods for eruption of canine depends on certain factors:

- Total path of the canine to erupt: Distance between the impacted canine tip to the horizontal plane passing through upper horizontal line tangential to incisal edges of incisors is measured on OPG, as shown in Figure 9a. As the distance increases, time taken for eruption also increases
- Angulation of canine to midline between maxillary central incisors in OPG, as shown in Figure 9b: As the angle between long axis of impacted canine and midline increases, time taken for eruption also increases. In this case series, case 1 had minimum angulation almost parallel to midplane, time taken for fully eruption of canine was minimum. In her next appointment after

- 25 days, the canine was fully erupted in the oral cavity; however, the greatest angulation was present in case 5 between midline between maxillary central incisors and long axis of impacted canine which took the longest time among all other cases approximately after 4 visits
- Proximity to other teeth: If impacted canine is present in close proximation to another root, it may cause resorption of the root while erupting. In such cases, for example, in case 6, the crown of impacted canine is in close vicinity to lateral incisor root, as revealed in Figure 8. If directly eruptive vertical force is applied, it

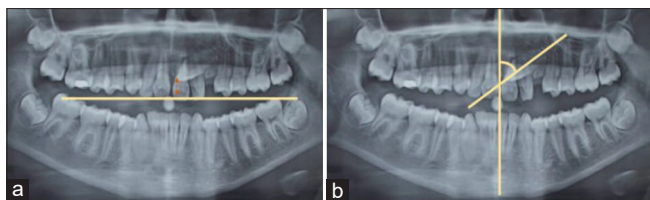


Figure 9: Case 5 Orthopantomograph showing (a) distance between impacted canine tip to tangential horizontal plane to maxillary incisors incisal edge indicated by arrow, (b) angulation between long axis of impacted canine and midplane between maxillary incisors

may cause resorption of lateral incisor root resulting in sacrifice of one tooth over the other. Hence, to prevent this, the first force is applied in distal direction to move impacted canine crown away from the root followed by eruptive force. Similarly, in case 5, impacted canine is in close proximation to lateral incisor; if the first facial pull is applied, it will cause interference with lateral incisor root. To prevent this, the first direction of force applied is vertical eruptive force followed by distal pull to move it away from lateral incisor root. This change in the direction of force adds to time taken for ultimate eruption of canine into its final position

- d. Abnormal curvature of the roots: Curved root or dilacerated root takes more time to erupt. None of the such findings were present in discussed cases in this series.

From the above-discussed cases, it can be postulated that each degree of uprighting takes about an average of 2 days. For displacement toward occlusal plane, time duration is

greatly determined by angulation of canine to midplane, following a direct proportionality with it.

CONCLUSION

Proper diagnosis and treatment planning is the key to success of managing impacted canine. Each method should be carefully evaluated in terms of force vector required, angulation, and position of impacted canine in relation to surrounding structures before implementation in the patient.

Financial support and sponsorship

Nil.

Conflicts of interest

There are no conflicts of interest.

REFERENCES

1. Bedoya MM, Park JH. A review of the diagnosis and management of impacted maxillary canines. *J Am Dent Assoc* 2009;140:1485-93.
2. Yavuz MS, Aras MH, Büyükkurt MC, Tozoglu S. Impacted mandibular canines. *J Contemp Dent Pract* 2007;8:78-85.
3. Lindauer SJ, Rubenstein LK, Hang WM, Anderson WC, Isaacson RJ. Canine impaction identified early with panoramic radiographs. *J Am Dent Assoc* 1992;123:91-7.
4. Frank CH. Treatment options for impacted teeth. *J Am Dent Assoc* 2000;131:623-32.
5. Lindauer SJ, Isaacson RJ. One-couple orthodontic appliance systems. *Semin Orthod* 1995;1:12-24.
6. Bowman SJ, Carano A. The Kilroy Spring for impacted teeth. *J Clin Orthod* 2003;37:683-8.
7. Jacoby H. The "ballista spring" system for impacted teeth. *Am J Orthod* 1979;75:143-51.