

A repeated carpal tunnel syndrome due to tophaceous gout in flexor tendon

A case report

Hui Lu, MD^{a,*}, Qiang Chen, MD^b, Hui Shen, MD^a

Abstract

Rationale: Gouty tophi is a rare cause of CTS. We first report a unique case of repeated CTS with gouty tophi in flexor tendon. In the previous literature, the symptoms cases of CTS were gradually increased.

Patient concerns: We report a 44-year-old male porter presented with mass on his left distal forearm combined a repeated carpal tunnel syndrome for 5 years. He felt numbness in fingers and his left palmar. The CTS symptoms had been eased through rest and dugs medication. It recurred twice.

Diagnoses: Monosodium urate crystal deposits were found in surgery. Histologic findings confirmed the diagnosis of gout.

Interventions: We removed partial of gouty tophus and retained the integrity of the tendon.

Outcomes: Two years after the surgery, the patient had not experienced any symptom recurrence.

Lessons: Early diagnosis and control of gout are necessary to avoid irreversible complications. The surgery combined with decreasing trioxypurine treatment can improve the treatment outcome of gouty tophus.

Abbreviations: CTS = Carpal Tunnel Syndrome, EMG = electromyography, MR = magnetic resonance, NSAIDs = Non-Steroidal Antiinflammatory Drugs.

Keywords: carpal tunnel syndrome, flexor tendon, gouty tophus infiltration, surgery

Editor: Bernhard Schaller.

Ethics Approval and Consent to Participate: These study protocols were approved by the medical ethics committee of the First Affiliated Hospital, College of Medicine, Zhejiang University.

Consent for Publication: Written informed consent for publication of clinical details and images was obtained from the patient. A copy of the consent form is available for review upon request.

Availability of data and materials section: The data supporting the conclusions of this article are included within the article.

Authorship: HL drafted the manuscript. QC and HS participated in the design of the study and performed the statistical analysis. All authors read and approved the final manuscript.

Funding: This work was supported by the Zhejiang Traditional Chinese Medicine Research Program (grant number 2016ZA124, 2017ZB057), Zhejiang Medicine and Hygiene Research Program (grant number 2016KYB101, 2015KYA100) and Zhejiang medical association clinical scientific research Program (2013ZYC-A19, 2015ZYC-A12).

The authors have no conflicts of interest to disclose.

^a Department of Hand Surgery, The First Affiliated Hospital, College of Medicine, Zhejiang University, Hangzhou, Zhejiang Province, P.R. China, ^b Department of Hand Surgery, Zhejiang Province People's Hospital, Hang Zhou, Zhejiang Province, P.R. China.

* Correspondence: Hui Lu, Department of Hand Surgery, The First Affiliated Hospital, College of Medicine, Zhejiang University, Hang Zhou, ZheJiang Province, China PR (e-mail: hitman1982@hotmail.com).

Copyright © 2017 the Author(s). Published by Wolters Kluwer Health, Inc. This is an open access article distributed under the terms of the Creative Commons Attribution-Non Commercial-No Derivatives License 4.0 (CCBY-NC-ND), where it is permissible to download and share the work provided it is properly cited. The work cannot be changed in any way or used commercially without permission from the journal.

Medicine (2017) 96:9(e6245)

Received: 1 November 2016 / Received in final form: 3 February 2017 /

Accepted: 6 February 2017

<http://dx.doi.org/10.1097/MD.0000000000006245>

1. Introduction

The carpal tunnel syndrome (CTS) is a disease caused by excessive pressure on the median nerve as it travels through the wrist at the carpal tunnel. If the syndrome is treated properly, there are usually no complications. If untreated, the nerve can be damaged, and it can lead to numbness, constant pain, paresthesias, and muscle weakness. CTS is the most commonly diagnosed compression neuropathy of the upper limb.^[1,2] Causes of CTS include tissue edema, tissue inflammation, hemorrhage after injury, and space occupying lesions.^[3–7] Gouty tophi is a rare cause of CTS, the incidence is 0.6%.^[8] The management options of CTS include physiotherapy, steroids either orally or injected locally, splinting, and surgical decompression.^[1,3] CTS caused by gouty tophi in flexor tendons are extremely rare, with only 4 cases reported in the literature.^[9–12] Those patients reported with relatively severe carpal tunnel symptoms, and clinical manifestations were long-term continuous. We report a unique case of repeated CTS with gouty tophi in flexor tendon. This repeated phenomenon has not been reported in the literature. We reviewed the literature and discuss the etiology and therapeutic options in this report.

2. Case presentation

A 44-year-old male porter presented with mass on his left distal forearm that had slowly increased in size over 5 years. The mass was painless and the patient reported no history of trauma. He felt numbness and tingling in the thumb, the index, middle fingers, half of the ring finger, and his left palmar after severe physical work. The symptoms lasted for several weeks. And through rest and Non-Steroidal Antiinflammatory Drugs medication (NSAIDs, 200 milligrams of Celebrex, twice a day), the patient's symptoms had been eased, or even disappeared. The patient's symptoms recurred twice. On local examination,

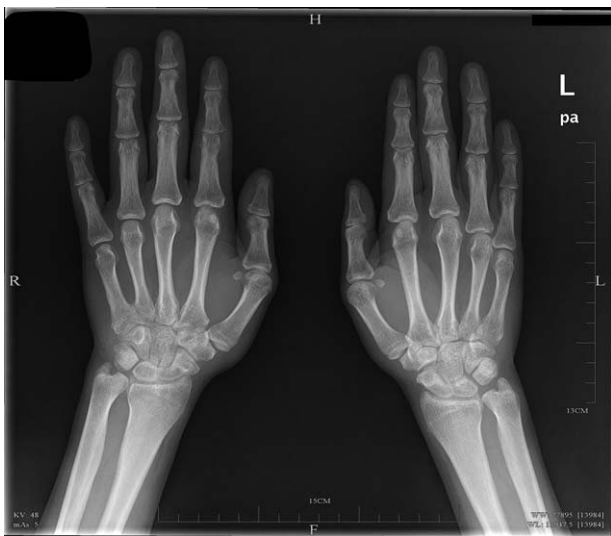

Figure 1. Preoperative radiographs showing a bone cystic defect in his proximal interphalangeal joint of right index finger.

the mass was circumscribed firm and located on the volar aspect of distal forearm. It was a 2 × 1.5 cm elevated, superficial, external mass. The boundary shape was egg circular and the surface had no tenderness, inflamed, and ulceration clinically. It was movable following the movement of tendon gliding. Atrophy of the thenar muscle was not seen. The mass entered the carpal tunnel and was difficult to reach when patient's fingers completely straightened. The patient had the normal activities of hand function and grip strength. The proximal interphalangeal joint of right index finger was slightly swollen with normal active motion, confirming the gouty arthritis. A neurologic examination revealed numbness in the thumb, index finger, middle finger, half of the ring finger, and his left palmar. Tinel's sign was positive at the wrist. Phalen's maneuver and carpal compression test were also positive. Electromyography (EMG) showed the conduction velocity of median nerve decreased, and the patient's sensory function of median nerve was impaired. Tumor biological markers and laboratory analyses including complete blood count, C-reactive protein, and electrolytes were normal. The uric

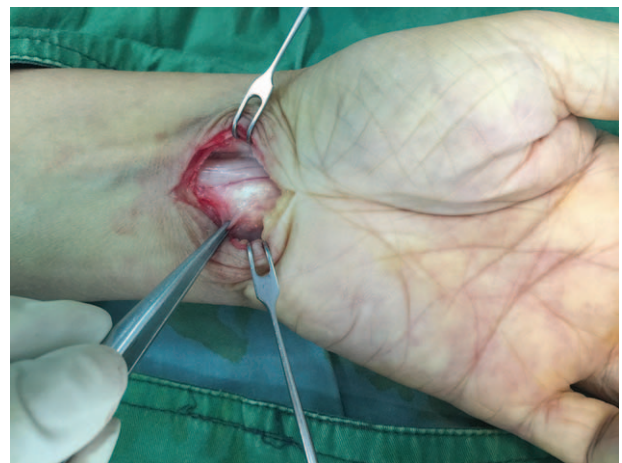

Figure 3. Intraoperative photograph showing that the lesion located in the flexor digitorum superficialis tendon sheath of the middle finger.

acid level was 627 μmol/L (237.9–356.9 μmol/L), and the diagnosis of hyperuricemia was made. The patient had a 10-year history of gouty arthritis and mild hypertension. Patients had acute gouty attacks 3 times, which may be related to poor compliance of low-purine diet therapy. Two gouty attacks after consumption of seafood and beer, and 1 attack had no apparent cause. He took colchicines and NSAIDs to treat the acute gouty attacks. Patients did not take uric acid-lowering drugs. The patient previously suffered from mumps, with a history of appendicitis surgery. Radiographs (Fig. 1) showed a bone cystic defect in his proximal interphalangeal joint of right index finger. Magnetic resonance (MR) (Fig. 2) showed a giant mass in the flexor tendons at the level of carpal tunnel and it was pressing on the median nerve. The mass showed low to intermediate signal intensity on T1-weighted images and high signal intensity on T2-weighted images. Because of the gout history, we speculated this case as a tophaceous gout for entrapment of median nerve, and the patient declined biopsy to confirm. The operative management was performed. A longitudinal incision was made on the volar aspect of distal forearm with the position of fingers flexion. The mass located at an unusual site, in the flexor digitorum

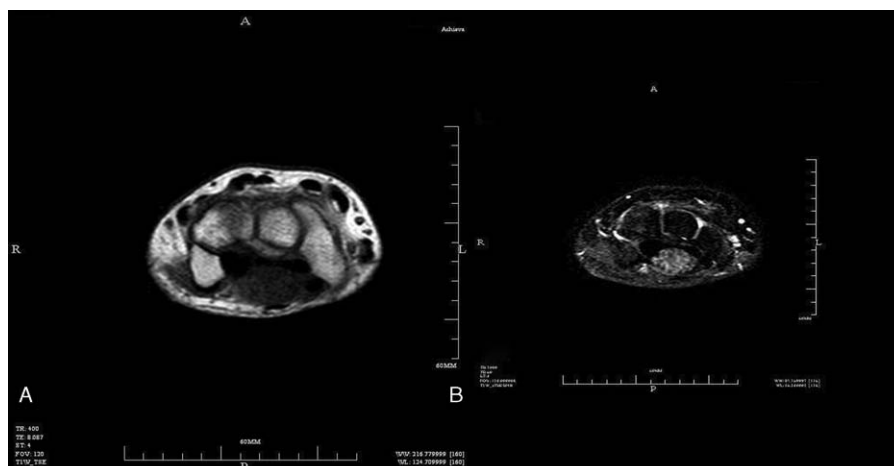


Figure 2. Preoperative MR of the lesion. (A) The mass showed low to intermediate signal intensity on T1-weighted images, (B) high signal intensity on T2-weighted images. MR = magnetic resonance.

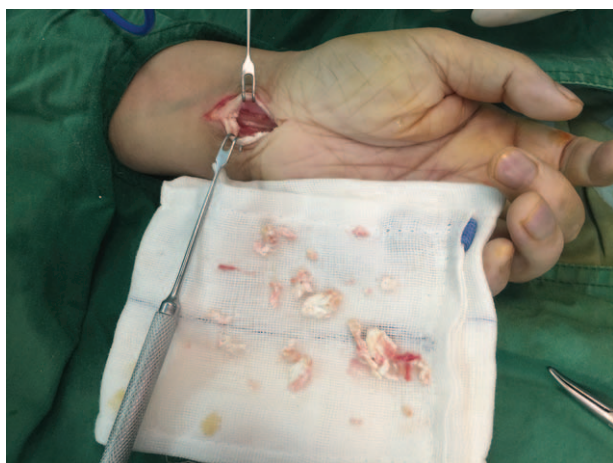


Figure 4. The chalky white substances were removed from the tendon.

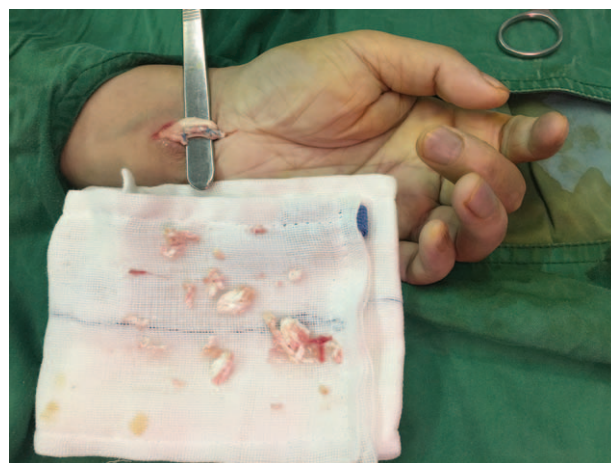


Figure 5. The tendon defect was sutured by a continuous suture technique.

superficialis tendon sheath of the middle finger, was presented (Fig. 3). A tophaceous gout occupied the most of his superficial flexor tendon and was pressing on his median nerve. The tophaceous gout entered the carpal tunnel when patient's middle fingers were completely extension. We removed the partial of gouty tophus to preserve integrity of flexor tendon, which was infiltration with chalky white substances (Fig. 4). The tendon defect was sutured by a continuous suture technique with 4-0 Ti-Cron coated braided polyester sutures (COVIDIEN) (Fig. 5). Epineurium neurolysis of median nerve was made completely, and the adherent tissue was released. Incarceration was not seen in the sutured tendon as patient wiggled his fingers. So the resection was not performed at the distal of the transverse carpal ligament. Surgical procedure was carried out with surgical loupes. Monosodium urate crystal deposits were found in surgery. Histologic findings confirmed the diagnosis of gout.

The incision was healed with no hospital infection occurred. One week after the surgery, the patient was able to perform full motion of the operated hand. The patient had taken methylcobalamin tablets for 3 months. Symptom of numbness was disappeared, and his finger range of motion recovered to the normal level. The electromyography showed the normal nerve conduction velocity half a year after surgery. The routine treatment of decreasing trioxypurine was significant in daily life. We had strengthened the health education of patients, including diet structure control and uric acid determination. The patient was followed up by telephone every 3 months. Patient reported their feelings of recovery, joint activity, the local hospital review of uric acid levels, and so on. Two years after the surgery, the patient had not experienced any symptom recurrence. Tendon rupture, tendon adhesions, acute gout, and so on—these conditions did not occur.

3. Discussion

With our patient's special location of lesions, the symptoms of median nerve compression recurred frequently for a period of time. In our case, the repeated median nerve compression was due to a gouty tophus into the gliding flexor tendons. Because of its rare frequency, gouty involvement of the flexor tendons and CTS might be difficult to consider the differential diagnoses. Rand reported a case of triggered wrist and severe CTS.^[10] Hernandez-Cortes et al^[13] reported a case of digital flexion contracture and severe

CTS. In the above 2 cases because of obvious clinical signs, with imaging characteristics and medical history, the diagnosis was not difficult. Triggered and tendon contracture did not appear in our case. Fortunately, through careful elemental examination, clinic medical history, and vigilance against gout, we achieved the correct diagnosis of the disease. Delays in diagnosis can lead to finger contracture and an irreversible axon injury of nerve.^[11,14]

Ultrasound can also be used in the diagnosis. Bsc^[12] reported a case of sonography showed a heterogenous mass infiltrating the flexor tendons and displacing the median nerve in the carpal tunnel, and MRI findings were initially suggestive of a median nerveschwannoma before.

Gouty tophus infiltration can lead to tenosynovitis^[15] or flexor tendon rupture of the fingers.^[16,17] Generally, tendon graft using the palmaris longus tendon acquired satisfactory results.^[18] Every effort has been made to preserve the tendon as its defect will impair the function of hand.

Partial removal of gouty tophus and retain the integrity of the tendon had been achieved a good result in our patient. Our treatment has the advantage of high tendon strength and less tendon adhesion, and no donor site complications. But surgeons must pay attention to residual and recurrence of gout. Febuxostat and Allopurinol can be recommended as medical treatment for lowering serum urate.^[19] The control of gout is necessary to avoid disease recurrence.

4. Conclusion

Early diagnosis and control of gout are necessary to avoid irreversible nerve injury. Delays in diagnosis and treatment can lead to functional damage and residual deformity. The surgery combined with decreasing trioxypurine treatment can improve the treatment outcome of gouty tophus. For patients with gout and high uric acid, we must pay attention to this situation of CTS caused by gouty tophus of the flexor tendons of the fingers.

Acknowledgments

First, I would like to express my deepest gratitude to my colleagues Dr. Qiang Chen and Dr. Hui Shen who have provided me with valuable assistance in every stage of writing this paper. I also appreciate the Zhejiang Traditional Chinese Medicine

Research Program, Zhejiang Medicine and Hygiene Research Program. Finally, I would like to thank all of my friends, especially my lovely wife for her encouragement and support.

References

- [1] Bland JDP. Carpal tunnel syndrome. *Ann R Coll Surg Engl* 2005;89:392–5.
- [2] Burton C, Chesterton LS, Davenport G. Diagnosing and managing carpal tunnel syndrome in primary care. *Br J Gen Pract* 2014;64:262–3.
- [3] Carneiro RS. Carpal tunnel syndrome: the cause dictates the treatment. *Cleve Clin J Med* 1999;66:159–64.
- [4] Kowalewska-Zietek J, Dawson TP, Damodaran D, et al. An unusual cause of carpal tunnel syndrome. *Pract Neurol* 2011;11:352–4. doi:10.1136/practneurol-2011-000037.
- [5] McGrath MH, Polayes IM. Posttraumatic median neuroma: a cause of carpal tunnel syndrome. *Ann Plast Surg* 1979;3:227–30.
- [6] Pappas G, Markoula S, Seitaridis S, et al. Brucellosis as a cause of carpal tunnel syndrome. *Ann Rheumat Dis* 2005;64:792–3. doi:10.1136/ard.2004.028944.
- [7] Lu H, Chen Q, Shen H. Hamartoma compress medial and radial nerve in neurofibromatosis type 1. *Int J Clin Exp Med* 2015;8:15313–6.
- [8] Rich JT, Bush DC, Lincoski CJ, et al. Carpal tunnel syndrome due to tophaceous gout. *Orthopedics* 2004;27:862–3.
- [9] Tan G, Chew W, Lai CH. Carpal tunnel syndrome due to gouty infiltration of the lumbrical muscles and flexor tendons. *Hand Surg* 2003;8:121–5.
- [10] Rand B, McBride TJ, Dias RG. Combined triggering at the wrist and severe carpal tunnel syndrome caused by gouty infiltration of a flexor tendon. *J Hand Surg Eur Vol* 2010;35:240–2.
- [11] Hernández-Cortés P, Caba M, Gómez-Sánchez R, et al. Digital flexion contracture and severe carpal tunnel syndrome due to tophaceous infiltration of wrist flexor tendon: first manifestation of gout. *Orthopedics* 2011;34:S115–6.
- [12] Bsc AT. Carpal tunnel syndrome caused by gouty tophus of the flexor tendons of the fingers: Sonographic features. *J Clin Ultrasound* 2011;39:463–5.
- [13] Hernandez-Cortes P, Caba M, Gomez-Sanchez R, et al. Digital flexion contracture and severe carpal tunnel syndrome due to tophaceous infiltration of wrist flexor tendon: first manifestation of gout. *Orthopedics* 2011;34:e797–9. doi:10.3928/01477447-20110922-36.
- [14] Kamiya H, Kimura M, Hoshino S, et al. Prognosis of severe carpal tunnel syndrome with absent compound muscle action potential. *Muscle Nerve* 2016;54:427–31. doi:10.1002/mus.25004.
- [15] Aslam MN, Lo DS, McNab MI. Gouty flexor tenosynovitis of the digits: report of three cases. *J Hand Surg* 2003;28:669–72.
- [16] Hankin FM, Mayhew DE, Coapman RA, et al. Gouty infiltration of a flexor tendon simulating rupture. *Clin Orthop Relat Res* 1985;172–5.
- [17] Wurapa RK, Zelouf DS. Flexor tendon rupture caused by gout: a case report. *J Hand Surg* 2002;27:591–3.
- [18] Lu H, Yang H, Shen H, et al. The clinical effect of tendon repair for tendon spontaneous rupture after corticosteroid injection in hands: a retrospective observational study. *Medicine* 2016;95:e5145doi:10.1097/MD.0000000000005145.
- [19] Keenan RT, Pillinger MH. Febuxostat: a new agent for lowering serum urate. *Drugs Today* 2009;45:247–60. doi:10.1358/dot.2009.45.4.1354217.