



Two case reports of non-small cell lung cancer patients harboring acquired *EGFR* T790M-*cis*-C797S benefit from immune checkpoint inhibitor combined with platinum-based doublet chemotherapy

Zizheng Song^{1#}, Guanying Ren^{1#}, Ling Hu¹, Xiaolei Wang¹, Jin Song¹, Youchao Jia¹, Guofa Zhao¹, Aimin Zang¹, Haiwei Du², Ying Sun³, Xiaopeng Zhao⁴

¹Department of Medical Oncology, Affiliated Hospital of Hebei University, Baoding, China; ²Department of Data Science, Burning Rock Biotech, Guangzhou, China; ³Department of Medicine, Burning Rock Biotech, Guangzhou, China; ⁴Department of Thoracic surgery, The Fourth Hospital of Hebei Medical University, Shijiazhuang, China

[#]These authors contributed equally to this work

Correspondence to: Xiaopeng Zhao. Department of Thoracic surgery, The Fourth Hospital of Hebei Medical University, No. 12, Jiankang Road, Chang'an District, Shijiazhuang, China. Email: zhiaoshen@hotmail.com

Background: Acquired resistance is inevitable in non-small cell lung cancer (NSCLC) patients treated with epidermal growth factor receptor tyrosine kinase inhibitors (EGFR-TKIs). The emergence of *EGFR* exon 20 C797S is one of the major resistance mechanisms to osimertinib as a third-generation EGFR-TKI. To date, there is no standard of care for NSCLC patients after acquiring *EGFR* C797S. Immune checkpoint inhibitors (ICIs) have revolutionized the treatment of various types of cancers in the last decade. Whether NSCLC patients with acquired *EGFR* C797S could benefit from ICIs remains elusive.

Case Description: Herein, we reported two cases of *EGFR*-mutant NSCLC patients who acquired a tertiary *EGFR* mutation C797S benefited from ICIs. A 28-year-old woman presented with anepithymia and nausea. Chest computed tomography (CT) revealed a mass in the right lung. She was diagnosed with stage IV lung adenocarcinoma (LUAD) with *EGFR* exon 19 deletion (19del) based on imaging and next-generation sequencing (NGS) findings. She received icotinib followed by osimertinib, then acquired *EGFR* T790M-*cis*-C797S. She had low tumor mutation burden (TMB) and achieved partial response (PR) to a programmed cell death-1 (PD-1) inhibitor sintilimab combined with platinum-based doublet chemotherapy as late-line treatment lasting more than 5 months. A 66-year-old man complained with chest tightness, hemoptysis, and back pain. CT scans revealed a mass in the right lung and metastases to the bilateral lungs, liver, adrenal gland, mediastinal lymph nodes, and bone. He was also diagnosed with *EGFR* 19del-positive LUAD and treated with icotinib followed by osimertinib. He also acquired *EGFR* T790M-*cis*-C797S. The patient had low TMB also and benefited from a PD-1 inhibitor camrelizumab combined with platinum-based doublet chemotherapy as late-line treatment with a progression-free survival (PFS) of 8 months. Two cases had no treatment-related adverse events leading to discontinuation of PD-1 inhibitors.

Conclusions: Our study provides the first clinical evidence that ICIs combined with platinum-based doublet chemotherapy may be effective treatment options for overcoming resistance mediated by *EGFR* T790M-*cis*-C797S. Clinical trials are needed to evaluate the efficacy and safety of PD-1 inhibitors in the treatment of NSCLC patients harboring *EGFR* T790M-*cis*-C797S.

Keywords: Epidermal growth factor receptor (EGFR); non-small cell lung cancer (NSCLC); T790M-*cis*-C797S; immune checkpoint inhibitor (ICI); case report

Submitted Apr 24, 2022. Accepted for publication Jun 20, 2022.

doi: 10.21037/atm-22-2436

View this article at: <https://dx.doi.org/10.21037/atm-22-2436>

Introduction

Lung cancer is a leading cause of malignancy-related death worldwide. Non-small cell lung cancer (NSCLC) accounts for approximately 85% of primary lung tumors. The development of tyrosine kinase inhibitors (TKIs), such as first-generation epidermal growth factor receptor (EGFR)-TKI gefitinib against *EGFR* 19del/L858R and third-generation EGFR-TKI osimertinib against primary or acquired *EGFR* T790M, has revolutionized the treatment of NSCLC (1). However, resistance to EGFR-TKI inevitably develops. About 30% of *EGFR* T790M-positive NSCLC patients acquire tertiary *EGFR* C797S mutation after receiving osimertinib treatment (2). At present, there are no established agents for *EGFR*-C797S-positive NSCLCs. Immune checkpoint inhibitors (ICIs) display promising efficacy and manageable safety in a variety of malignancies. The efficacy of ICIs in NSCLC patients with *EGFR* C797S has not been documented. Herein, we reported two cases of *EGFR*-mutant NSCLC patients harboring a tertiary *EGFR* mutation C797S who benefited from programmed cell death-1 (PD-1) inhibitors combined with platinum-based doublet chemotherapy. Our data might pave the way for the potential clinical utilization of PD-1 inhibitors in NSCLC patients harboring *EGFR* T790M-*cis*-C797S. We present the following article in accordance with the CARE reporting checklist (available at <https://atm.amegroups.com/article/view/10.21037/atm-22-2436/rc>).

Case presentation

Case 1

A 28-year-old woman without smoking history presented with headache, anepithymia, and nausea for 2 weeks on October 18, 2015. Chest computed tomography (CT) revealed a mass (3.1 cm × 3.1 cm) in the right upper lung and an enlarged mediastinal lymph node (3.1 cm × 3.0 cm). Emission CT (ECT) revealed high metabolic activity in the left 3rd rib and sacral bone and ultrasound revealed enlargement of the bilateral cervical lymph nodes (1.0 cm × 0.9 cm and 2.5 cm × 1.7 cm). Moreover, brain magnetic resonance imaging (MRI) indicated several masses in the brain (largest mass: 3.0 cm × 2.1 cm). Also, the specific tumor marker carcinoembryonic antigen (CEA) was 58.06 ng/mL (Figure 1A). Transbronchial biopsy of the primary lung lesion revealed lung adenocarcinoma (LUAD). The patient was diagnosed with stage IV right LUAD and an Eastern Cooperative Oncology Group Performance Status (ECOG

PS) of 2 in October 2015.

Real-time polymerase chain reaction (RT-PCR) on lung biopsy showed *EGFR* 19del (p.E746_A750del) (Figure 1A). The patient received first-line icotinib plus whole-brain radiotherapy (WBRT) in November 2015. After 9 months of icotinib treatment, local progression of the primary right lung lesion was observed. Continuing icotinib and CT-guided radioactive iodine-125 (125I) seed implantation was subsequently administered until March 2017 due to progressive disease (PD), with an enlarged primary lung lesion and new metastases to the liver and adrenal gland (Figure 1B). The patient benefited from icotinib treatment, achieving a progression-free survival (PFS) of 17 months. Plasma-based next-generation sequencing (NGS) indicated the presence of a new alteration, *EGFR* T790M, with an allele frequency (AF) of 17.14% (Figure 1A).

Second-line osimertinib was given in April 2017, which resulted in a partial response (PR) after 1 month of treatment, with decreased primary lung and adrenal gland lesions (Figure 1B). However, she experienced PD after 18 months of osimertinib treatment, with enlarged primary lung and metastatic brain lesions (Figure 1B). Meanwhile, plasma-based NGS showed a new alteration *cis*-*EGFR* C797S with an AF of 0.61% as well as a blood tumor mutational burden (TMB) of 5.91 mutations/Mb (Figure 1A). *EGFR* T790M with an AF of 0.94% and *EGFR* 19del with an AF of 2.86% were also detected. The patient and her family members refused chemotherapy, so she was given anlotinib as third-line treatment, and achieved a PFS of 10 months. In March 2019, the patient received a PD-1 inhibitor (sintilimab) combined with platinum-based doublet chemotherapy. The treatment response was assessed as PR. At the last follow-up visit, she was assessed as having obtained benefit from this fourth-line treatment for more than 5 months. There was no treatment-related adverse events leading to discontinuation.

Case 2

A 66-year-old man without smoking history presented with chest tightness, hemoptysis, and back pain. CT scans revealed a mass in the right lower lung and metastases to the bilateral lungs, liver, adrenal gland, mediastinal lymph nodes, and bone. Biopsy from the lung lesion indicated a moderately differential adenocarcinoma. He was diagnosed with stage IV right LUAD and an ECOG PS of 3 in April 2017. RT-PCR, immunohistochemistry (IHC) staining, and

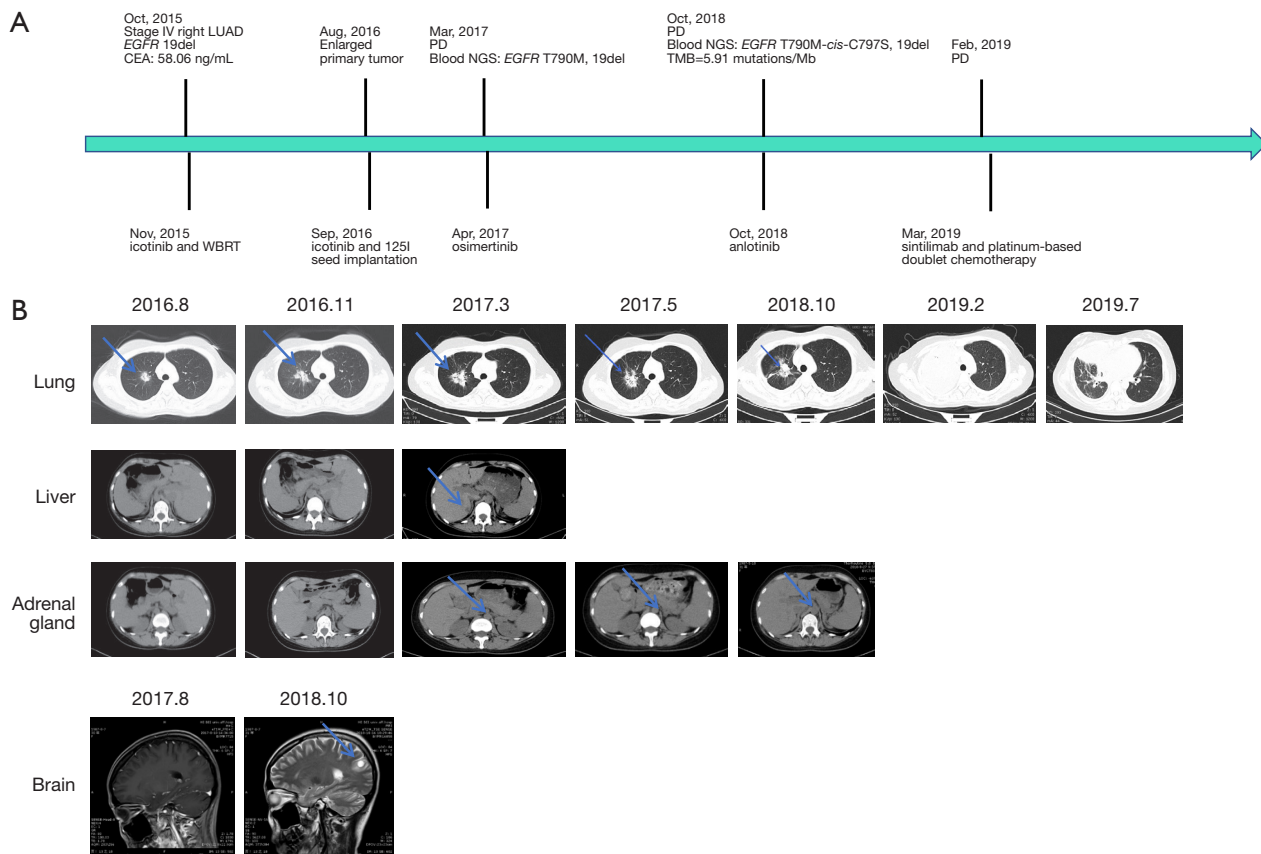


Figure 1 The treatment milestones of Case 1. (A) The entire treatment procedure of Case 1; (B) CT and MRI scans at treatment milestones. CT, computed tomography; MRI, magnetic resonance imaging; NGS, next-generation sequencing; EGFR, epidermal growth factor receptor; PD, progressive disease; TMB, tumor mutational burden; CEA, carcinoembryonic antigen; LUAD, lung adenocarcinoma; WBRT, whole-brain radiotherapy. Blue arrows indicated tumors.

fluorescence in situ hybridization (FISH) on lung biopsy showed EGFR 19del without anaplastic lymphoma kinase (ALK) fusion and hepatocyte growth factor receptor gene (MET) amplification (Figure 2A).

The patient received icotinib as first-line treatment in April 2017. The best response to icotinib was PR. After 15 months of icotinib treatment, he experienced PD with an enlarged primary lung tumor and a high CEA level of 335.6 ng/mL (Figure 2A,2B). Plasma-based NGS was performed and revealed the presence of EGFR T790M with an AF of 10.8% and EGFR 19del with an AF of 43.9% (Figure 2A). The patient was subsequently treated with osimertinib as second-line treatment. His ECOG PS decreased to 1 after 10 days of osimertinib treatment, and the treatment assessment was PR. He had PD after 14 months of osimertinib treatment in September 2019 (Figure 2B).

Next, capture-based targeted sequencing on lung biopsy using a panel comprising 520 cancer-related genes (Burning Rock Biotech, Guangzhou, China) was performed and indicated a microsatellite stability (MSS) tumor with a TMB level of 5.6 mutations/Mb as well as the presence of EGFR 19del with an AF of 49.81%. Plasma-based NGS using a panel consisting of 168 cancer-related genes (Burning Rock Biotech, Guangzhou, China) indicated the presence of EGFR T790M-cis-C797S with an AF of 18.87% and EGFR T790M with an AF of 18.07% (Figure 2A). Moreover, IHC staining [programmed cell death ligand-1 (PD-L1) IHC 22C3 pharmDx, Agilent Technologies Inc., Santa Clara, CA, USA] on lung biopsy revealed a tumor negative for PD-L1 expression (0%) (Figure 2A). The patient received a PD-1 inhibitor (camrelizumab) combined with platinum-based doublet chemotherapy as a third-line treatment in October 2019 and obtained benefit, with a PFS of 8 months

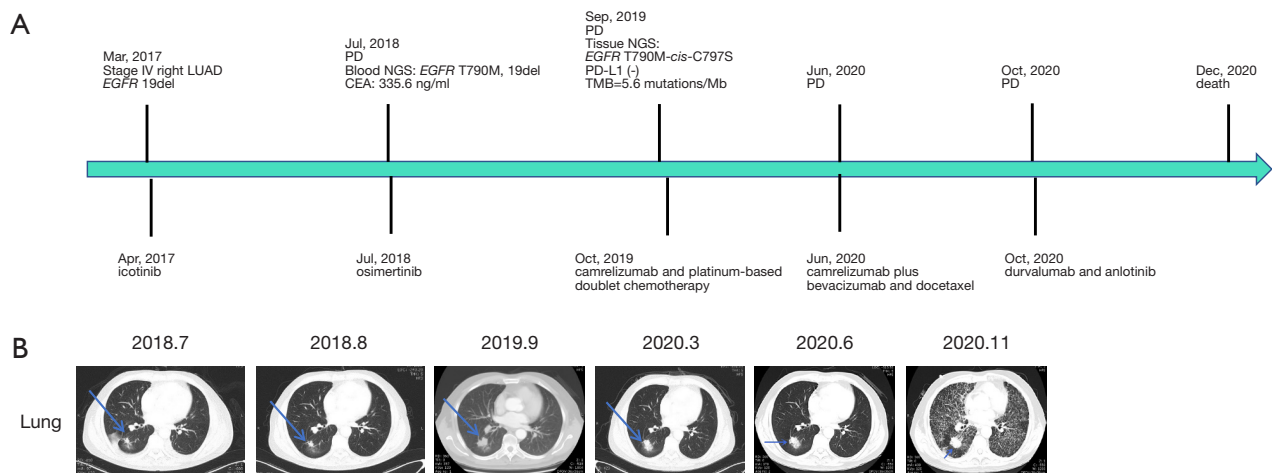


Figure 2 The treatment milestones of Case 2. (A) The entire treatment procedure of Case 2; (B) CT scans of the primary lung tumor at the treatment milestones. CT, computed tomography; NGS, next-generation sequencing; *EGFR*, epidermal growth factor receptor; PD, progressive disease; TMB, tumor mutational burden; PD-L1, programmed cell death ligand-1; CEA, carcinoembryonic antigen; LUAD, lung adenocarcinoma. Blue arrows indicated tumors.

as of June 2020 (Figure 2B). He subsequently received camrelizumab combined with bevacizumab and docetaxel as a fourth-line treatment, and achieved a PFS of 4 months following fifth-line treatment with PD-L1 inhibitor durvalumab combined with anlotinib. He had grade I pneumonitis during treatment. The patient succumbed to his disease in December 2020 (Figure 2A).

Ethical consideration

All procedures performed in this study were in accordance with the ethical standards of the institutional and/or national research committee(s) and with the Declaration of Helsinki (as revised in 2013). Written informed consent was obtained from the patients for publication of this case report and accompanying images. Copies of the written consent are available for review by the editorial office of this journal.

Discussion

EGFR C797S is the most common tertiary *EGFR* mutation, which occurs in exon 20 and accounts for 10–26% of cases that develop resistance to second-line third-generation *EGFR*-TKI osimertinib (via weakening of the covalent binding between the cysteine residue at position 797 of *EGFR* and osimertinib) (3). The occurrence of *EGFR* C797S has promoted the development of fourth-generation

EGFR inhibitors. At present, several fourth-generation *EGFR*-TKIs against C797S are in development, such as EAI045, TREA-0236, ZINC20531199, CH7233163, and LS-106 (4). However, fully effective drugs have not yet been approved for the treatment of NSCLC patients bearing C797S, and thus, there is currently no standard of care for NSCLC patients after acquiring *EGFR* C797S.

There is a pressing need to develop efficacious treatment options for patients harboring *EGFR* C797S. Previous case reports have revealed that NSCLC patients who acquired *EGFR* T790M-*cis*-C797S could benefit from several treatment strategies, including osimertinib combined with anlotinib, osimertinib plus bevacizumab and brigatinib, and cetuximab combined with brigatinib (5–7). In addition, previous reports have also indicated that patients with T790M-*trans*-C797S might respond to first- combined with third-generation *EGFR*-TKIs (8,9).

ICIs targeting the PD-1/PD-L1 axis have emerged as a pillar in the management of advanced malignancies (10). The National Comprehensive Cancer Network guidelines recommend immunotherapy, radiotherapy, continuing osimertinib, anti-angiogenesis therapy, and chemotherapy as palliative treatment options for NSCLC patients who experienced disease progression with osimertinib treatment. However, whether patients harboring T790M-*cis*-C797S could benefit from late-line ICI treatment remains unclear.

In the present study, two cases of NSCLC patients harboring *EGFR* 19del/T790M/C797S *in cis* achieved a

durable response to PD-1 inhibitors. Case 1, who had a low TMB, benefited from fourth-line treatment with a PD-1 inhibitor (sintilimab) combined with chemotherapy, which lasted for more than 5 months. Additionally, case 2, who had negative PD-L1 expression, achieved a durable response with a PD-1 inhibitor (camrelizumab) combined with chemotherapy as a third/fourth-line treatment, which lasted for 12 months.

There are several limitations associated with our study that should be noted. Only two patients were involved in the study to preliminarily explore the efficacy of ICIs in NSCLC patients who acquired *EGFR* T790M-*cis*-C797S. We cannot conclude that NSCLC patients harboring *EGFR* T790M-*cis*-C797S benefit from ICIs as late-line treatment. Therefore, more evidence/clinical trials are needed to evaluate the efficacy and safety of PD-1 inhibitors in the treatment of NSCLC patients harboring *EGFR* T790M-*cis*-C797S.

Our work provides clinical evidence that NSCLC patients harboring *EGFR* T790M-*cis*-C797S might obtain a durable response with ICI treatment. Our study suggests that ICIs might be an effective treatment option for NSCLC patients harboring *EGFR* T790M-*cis*-C797S. A large, prospective, multi-cancer study are warranted to investigate whether NSCLC patients with *EGFR* C797S could benefit from ICIs.

Acknowledgments

Funding: This study was supported by Natural Science Foundation of Hebei Province, China (No. H2022201071).

Footnote

Reporting Checklist: The authors have completed the CARE reporting checklist. Available at <https://atm.amegroups.com/article/view/10.21037/atm-22-2436/rc>

Conflicts of Interest: All authors have completed the ICMJE uniform disclosure form (available at <https://atm.amegroups.com/article/view/10.21037/atm-22-2436/coif>). HD and YS are from Burning Rock Biotech, Guangzhou, China. The other authors have no conflicts of interest to declare.

Ethical Statement: The authors are accountable for all aspects of the work in ensuring that questions related to the accuracy or integrity of any part of the work are

appropriately investigated and resolved. All procedures performed in this study were in accordance with the ethical standards of the institutional and/or national research committee(s) and with the Declaration of Helsinki (as revised in 2013). Written informed consent was obtained from the patients for publication of this case report and accompanying images. Copies of the written consent are available for review by the editorial office of this journal.

Open Access Statement: This is an Open Access article distributed in accordance with the Creative Commons Attribution-NonCommercial-NoDerivs 4.0 International License (CC BY-NC-ND 4.0), which permits the non-commercial replication and distribution of the article with the strict proviso that no changes or edits are made and the original work is properly cited (including links to both the formal publication through the relevant DOI and the license). See: <https://creativecommons.org/licenses/by-nc-nd/4.0/>.

References

1. Wu SG, Shih JY. Management of acquired resistance to EGFR TKI-targeted therapy in advanced non-small cell lung cancer. *Mol Cancer* 2018;17:38.
2. Leonetti A, Sharma S, Minari R, et al. Resistance mechanisms to osimertinib in EGFR-mutated non-small cell lung cancer. *Br J Cancer* 2019;121:725-37.
3. Mok TS, Wu YL, Ahn MJ, et al. Osimertinib or Platinum-Pemetrexed in EGFR T790M-Positive Lung Cancer. *N Engl J Med* 2017;376:629-40.
4. He J, Zhou Z, Sun X, et al. The new opportunities in medicinal chemistry of fourth-generation EGFR inhibitors to overcome C797S mutation. *Eur J Med Chem* 2021;210:112995.
5. Zhou R, Song L, Zhang W, et al. Combination of Osimertinib and Anlotinib May Overcome the Resistance Mediated by in cis EGFR T790M-C797S in NSCLC: A Case Report. *Onco Targets Ther* 2021;14:2847-51.
6. Zhao J, Zou M, Lv J, et al. Effective treatment of pulmonary adenocarcinoma harboring triple EGFR mutations of L858R, T790M, and cis-C797S by osimertinib, bevacizumab, and brigatinib combination therapy: a case report. *Onco Targets Ther* 2018;11:5545-50.
7. Wang X, Zhou L, Yin JC, et al. Lung Adenocarcinoma Harboring EGFR 19del/C797S/T790M Triple Mutations Responds to Brigatinib and Anti-EGFR Antibody Combination Therapy. *J Thorac Oncol* 2019;14:e85-8.
8. Arulananda S, Do H, Musfer A, et al. Combination

- Osimertinib and Gefitinib in C797S and T790M *EGFR*-Mutated Non-Small Cell Lung Cancer. *J Thorac Oncol* 2017;12:1728-32.
9. Zhou Z, Zhao Y, Shen S, et al. Durable Clinical Response of Lung Adenocarcinoma Harboring *EGFR* 19Del/T790M/in trans-C797S to Combination Therapy of First- and Third-Generation *EGFR* Tyrosine Kinase Inhibitors. *J Thorac Oncol* 2019;14:e157-9.
10. Dolladille C, Ederhy S, Sassier M, et al. Immune Checkpoint Inhibitor Rechallenge After Immune-Related Adverse Events in Patients With Cancer. *JAMA Oncol* 2020;6:865-71.
- (English Language Editor: A. Kassem)

Cite this article as: Song Z, Ren G, Hu L, Wang X, Song J, Jia Y, Zhao G, Zang A, Du H, Sun Y, Zhao X. Two case reports of non-small cell lung cancer patients harboring acquired *EGFR* T790M-*cis*-C797S benefit from immune checkpoint inhibitor combined with platinum-based doublet chemotherapy. *Ann Transl Med* 2022;10(12):719. doi: 10.21037/atm-22-2436