

## Review Article

# Coronary CT Angiography in the Quantitative Assessment of Coronary Plaques

Zhonghua Sun<sup>1</sup> and Lei Xu<sup>2</sup>

<sup>1</sup> *Discipline of Medical Imaging, Department of Imaging and Applied Physics, Curtin University, Perth, WA 6845, Australia*

<sup>2</sup> *Department of Radiology, Beijing Anzhen Hospital, Capital Medical University, No. 2, Anzhen Road, Chaoyang District, Beijing 100029, China*

Correspondence should be addressed to Lei Xu; [leixu2001@hotmail.com](mailto:leixu2001@hotmail.com)

Received 10 April 2014; Accepted 17 July 2014; Published 5 August 2014

Academic Editor: Michael Ralph Rees

Copyright © 2014 Z. Sun and L. Xu. This is an open access article distributed under the Creative Commons Attribution License, which permits unrestricted use, distribution, and reproduction in any medium, provided the original work is properly cited.

Coronary computed tomography angiography (CCTA) has been recently evaluated for its ability to assess coronary plaque characteristics, including plaque composition. Identification of the relationship between plaque composition by CCTA and patient clinical presentations may provide insight into the pathophysiology of coronary artery plaque, thus assisting identification of vulnerable plaques which are associated with the development of acute coronary syndrome. CCTA-generated 3D visualizations allow evaluation of both coronary lesions and lumen changes, which are considered to enhance the diagnostic performance of CCTA. The purpose of this review is to discuss the recent developments that have occurred in the field of CCTA with regard to its diagnostic accuracy in the quantitative assessment of coronary plaques, with a focus on the characterization of plaque components and identification of vulnerable plaques.

## 1. Introduction

Invasive coronary angiography is considered the gold standard for the diagnosis of coronary artery disease since it provides an excellent visualization of coronary lumen change and a roadmap of the entire coronary tree. However, invasive coronary angiography is an invasive procedure with associated morbidity and mortality. Furthermore, coronary angiography can only provide a two-dimensional outline of the coronary lumen and cannot thoroughly demonstrate the complex nature of atherosclerotic plaques which are responsible for association between the angiographic findings and clinical outcome [1]. It has been reported that almost two-thirds of acute coronary events occur in noncritical lesions (those with less than 50% lumen stenosis), highlighting the necessity for complementary imaging modalities to characterize plaque composition and to detect vulnerable plaques [2].

The noninvasive characterization of plaque morphology has potential clinical significance, since autopsy studies in coronary death have indicated that the site of coronary thrombosis is often associated with plaque rupture at sites

with a thin fibrous plaque cap and a large lipid core [3–5]. Intravascular ultrasound (IVUS) is a widely used invasive imaging modality with high diagnostic accuracy for detection and quantification of coronary artery disease (CAD). IVUS allows assessment of vessel cross-sectional areas which are closely correlated with hemodynamically significant coronary stenoses [6–8]. IVUS has also been used to monitor the progression or regression of coronary plaque volume in response to clinical therapies [9, 10]. Although IVUS is the standard reference for the assessment of coronary plaque composition and progression in clinical studies [11, 12], it is an invasive procedure which is not commonly performed in routine clinical practice and thus may be limited to research studies. Coronary CT angiography (CCTA) has been widely used as an effective less invasive imaging modality to diagnose CAD [13–17]. Further, CCTA allows evaluation of coronary plaque characteristics, including plaque compositions [18]. Classification of coronary plaque compositions by CCTA has important clinical implications, with significant association of plaque components with myocardial ischemia and prediction of adverse cardiac events and prognosis [19–22]. The purpose of this review is to provide an overview

of the diagnostic applications of CCTA in the quantitative assessment of coronary plaques. We focus our discussion on issues related to diagnostic accuracy, identification of vulnerable plaques, and 3D characterization of coronary plaques.

## 2. Definition of Vulnerable or High-Risk Plaques

The vulnerable atherosclerotic plaque is called a “high-risk” or “thrombosis-prone” plaque. Major criteria to characterize such plaques include the presence of active inflammation, a thin inflamed fibrous cap ( $<65\ \mu\text{m}$ ) covering a lipid-rich necrotic core ( $>40\%$  of the total volume of the plaque), the presence of endothelial denudation with superficial platelet aggregation, and the presence of hemodynamically significant stenosis ( $>90\%$ ) [23]. A more clinical relevant definition of a vulnerable plaque is a lesion that places a patient at risk for developing future major adverse cardiac events, including death, myocardial infarction, or progressive angina. The identification of such plaques before they become symptomatic would enable prognostic stratification and facilitate primary prevention (e.g., aspirin, statins, and risk factor modification).

The concept of vulnerable plaque or high-risk plaque originated from data of several studies that analyzed angiograms postthrombolytic therapy or through analysis of serial angiographic data before and after ST-elevation acute myocardial infarction [2, 27, 28]. These studies showed that most infarctions were caused by lesions that were less than severely narrowed in coronary lumen. Yamagishi et al. reported that after thrombolytic therapy the actual size of the plaque responsible for the infarction was only moderate, and the remaining luminal narrowing was related to residual thrombus formation [29]. Due to positive remodelling, the lumen remains relatively uncompromised until the plaque has grown to a larger volume [27]. Thus, in most cases, these plaques are clinically silent before the acute cardiac events occur. This emphasizes the importance of detecting vulnerable atherosclerotic plaques.

Large lipid core and calcified areas (defined as  $>10\%$  of the plaque area) and thin-cap fibroatheroma have been found to be associated with positive vascular remodelling [30–32]. Clinical and biomechanical studies have explored the risk factors associated with plaque vulnerability and have identified plaque composition and morphology as key determining factors for plaque vulnerability and likelihood of rupture [33–35]. Longitudinal clinical studies indicate a strong correlation between quantitative analysis of plaque volume and composition and prediction of future cardiac events. According to a retrospective study of 1,059 patients with stable chest pain, the coronary plaque volume was found to be significantly larger in patients who developed acute coronary syndromes (ACS) than those who did not have ACS over a follow-up of  $27 \pm 10$  months ( $134.9 \pm 14.1\ \text{mm}^3$  versus  $57.8 \pm 5.7\ \text{mm}^3$ ) [36]. Another study published in 2013 investigated the additional value of using CCTA-derived semiautomatic plaque quantification in 1,650 patients with a mean follow-up of

$26 \pm 10$  months for ACS [37]. Similarly, the ACS patients had higher total plaque volume (median  $94\ \text{mm}^3$  versus  $29\ \text{mm}^3$ ) and total noncalcified volume ( $28\ \text{mm}^3$  versus  $4\ \text{mm}^3$ ) than those who did not develop ACS. Specifically, the volume of nonobstructive noncalcified plaques has been reported to be a strong indicator of predicting future cardiac events [38].

In the following sections, a critical appraisal of the literature is given to the diagnostic value of CCTA in the quantitative analysis of coronary plaques with regard to the diagnostic value, assessment of plaque vulnerability, and 3D characterization of plaques.

## 3. Coronary CT Angiography Quantitative Assessment of Plaques

It has become well established that plaque composition is a key determinant of plaque stability [35, 39]. High-risk plaques tend to be large, demonstrate positive remodelling, and have a large lipid core that occupies 40% or more of the plaque volume. A large plaque size and a larger extent of positive remodelling are prone to rupture and develop intraplaque hemorrhage in comparison to stable plaques. Thus, the ability to noninvasively detect and analyse these plaques at early stages, especially in asymptomatic and low-risk patients, would improve risk stratification without the need for more invasive procedures [35]. The development of high-speed CT allows noninvasive coronary artery visualization, detection of lumen stenosis, characterization and quantification of atherosclerotic coronary plaque, and even coronary risk stratification [33, 40].

Rapid developments in the CT technique, in particular, the increasingly worldwide use of CCTA, have demonstrated that CCTA has the potential to revolutionize how patients are risk-stratified by identifying rupture-prone, noncalcified, or mixed coronary plaques accurately and reliably. As our understanding of plaque histology has improved, there has been an increasing interest in the ability of CCTA to identify particularly the high-risk or vulnerable plaques [41, 42]. According to the SCCT (Society of Cardiovascular Computed Tomography) criteria of subdividing plaques into noncalcified, calcified, and partially calcified types, coronary CT angiography shows excellent inter- and intraobserver agreement [43]. Early comparisons of CCTA with intravascular ultrasound showed promise for characterization and quantification of plaques, although results were affected by limited scan resolution and reproducibility [44–46]. Improvements in CT technology in recent studies using 64- and post-64-slice CT have led to improved ability of CCTA to quantify and distinguish plaque types.

*3.1. Literature Review Based on Single-Center Experiences.* Pfloderer et al. analysed morphological features of coronary plaques in 55 patients with acute coronary syndrome using dual-source CT angiography in comparison to 55 patients as the control group with stable angina pectoris [47]. Their results showed that culprit lesions in acute coronary syndrome show specific morphologic characteristics which are characterized by larger plaque volumes, higher remodelling

indices, greater proportions of noncalcified material, and presence of spotty calcification. Motoyama et al. in their large retrospective study showed that plaques with positive vascular remodelling and containing large areas of low attenuation assessed by CCTA are associated with a higher risk of acute coronary syndrome when compared with patients without these characteristics (22.2% versus 0.5%) [36]. These CT characteristics confirm features of unstable plaques which were previously reported by pathology.

A head to head comparison of CCTA with IVUS further confirms the diagnostic accuracy of CCTA in the quantitative assessment of coronary plaques. Nakazato et al. performed a direct comparison between CCTA and IVUS with regard to the quantification and characterization of coronary plaque volume and adverse plaque features in 27 consecutive patients with a total of 30 individual coronary plaques [48]. They observed a high correlation between total plaque volumes as quantified by CCTA in comparison to IVUS with no significant differences between the two methods. Bland-Altman limits of agreement for vessel volume, lumen volume, and plaque volume ranged from  $-53.7$  to  $53.1$  mm<sup>3</sup> with a bias of  $-0.3$  mm<sup>3</sup>,  $-24.1$  to  $32.2$  mm<sup>3</sup> with a bias of  $4.0$  mm<sup>3</sup>, and  $-40.6$  to  $31.8$  mm<sup>3</sup> with a bias of  $-4.4$  mm<sup>3</sup>, respectively. Furthermore, their results showed that CCTA has high diagnostic accuracy for identification of adverse plaque characteristics (low-attenuation plaque, positive remodelling, and spotty calcification) with no significant differences between CCTA and IVUS. Similarly, Papadopoulou et al. compared 64-slice CT angiography with IVUS in 32 patients consisting of 44 coronary arteries which were coregistered for quantitative analysis of the diagnostic performance of CCTA [49]. They analysed 1364 coregistered 1 mm cross-sections and 255 segments of 5 mm length. The sensitivity and specificity of CCTA were 86% and 71% at cross-sectional level assessment and 96% and 88% at segment level assessment, respectively. A significantly strong correlation was found between CCTA and IVUS in the quantification of plaque volumes. CCTA demonstrated underestimation of the plaque volume of noncalcified and overestimation of mixed/calcified plaque, although this was not significantly different from those measured by IVUS.

The ATLANTA (assessment of tissue characteristics, lesion morphology, and hemodynamics by angiography with fractional flow reserve, intravascular ultrasound and virtual histology, and noninvasive computed tomography in atherosclerotic plaques) study was a prospective, single-center study with the aim of determining if CCTA-derived measurements of plaque components correlated well with IVUS/VH (virtual histology) measurements [50]. Fifty lesions in 50 patients were analysed in this study with all of the patients undergoing invasive angiography, CCTA, and IVUS/VH examinations. A significant correlation was found between CCTA and IVUS/VH in terms of plaque geometric, compositional, lumen area and vessel area measurements. This study adds to the current literature on the accuracy of CCTA for coronary plaque quantification as it is the first study that used a multimodality approach involving 3 morphological methods to assess coronary lesions.

*3.2. Literature Review Based on Multicenter Trials.* The ACCURACY (assessment by coronary computed tomographic angiography of individuals undergoing invasive coronary angiography) study is currently the only available multicenter trial involving 16 centers which was designed to determine the relationship between coronary plaque composition as detected by CCTA and lumen diameter stenosis as quantified by invasive coronary angiography [51]. This prospective study involved 230 patients with obstructive CAD diagnosed in 38.7% of patients (>50% lumen stenosis). Results of the ACCURACY trial demonstrate a strong association between the presence of mixed plaque composition and obstructive CAD at a per-segment and per-patient level assessment. In contrast, coronary artery segments with calcified plaques are rarely associated with obstructive coronary stenosis. This is consistent with those reported by single centers [36, 52], highlighting the prognostic significance of plaque composition characterization, although more studies based on multicenter trials are necessary to confirm these findings.

*3.3. Literature Review Based on Systematic Review and Meta-Analysis.* There are one systematic review and three meta-analysis reports available in the literature with regard to the diagnostic value of CCTA in detecting coronary plaques [53–56]. Springer and Dewey in their early systematic review reported that CCTA has the potential to become a useful diagnostic tool for the analysis of coronary plaques when compared to IVUS, based an analysis of 9 studies [53]. Their results were limited by the small sample sizes and methodological flaws in the studies reviewed. Recent reports with inclusion of more studies have confirmed the reliable diagnostic accuracy of CCTA for detection of coronary plaques [54–56].

Gao et al. conducted a meta-analysis of 17 articles by comparing CCTA with IVUS with regard to the diagnostic accuracy of CT in detecting coronary plaques [54]. They observed a good weighted sensitivity of 92% and specificity of 93% for CCTA in the detection of any type of coronary plaque as compared with IVUS and a good positive and negative predictive value (>84%) for diagnosis of any plaque in a wide range of pretest probabilities. They recommended that CT be considered the prime noninvasive alternative to intravascular ultrasound for detecting coronary plaques.

Voros et al. conducted a meta-analysis of CCTA against IVUS for the assessment of coronary vessel, plaque sizes, and the diagnostic accuracy [55]. The authors identified 20 studies eligible for assessment of diagnostic accuracy of CCTA to detect plaques and 22 studies for comparison of vessel and plaque dimensions. CCTA has been shown to demonstrate excellent diagnostic accuracy for the detection of coronary plaques when compared to the reference standard, IVUS, with the pooled sensitivity and specificity of 90% (95% confidence interval [CI]: 83% to 94%) and 92% (95% CI: 90% to 93%). Plaque area, volume, and area stenosis measurements were similar between CCTA and IVUS, while CCTA slightly overestimated luminal area. This is also confirmed by a recently published meta-analysis comparing CCTA with IVUS for quantitative assessment of coronary stenosis



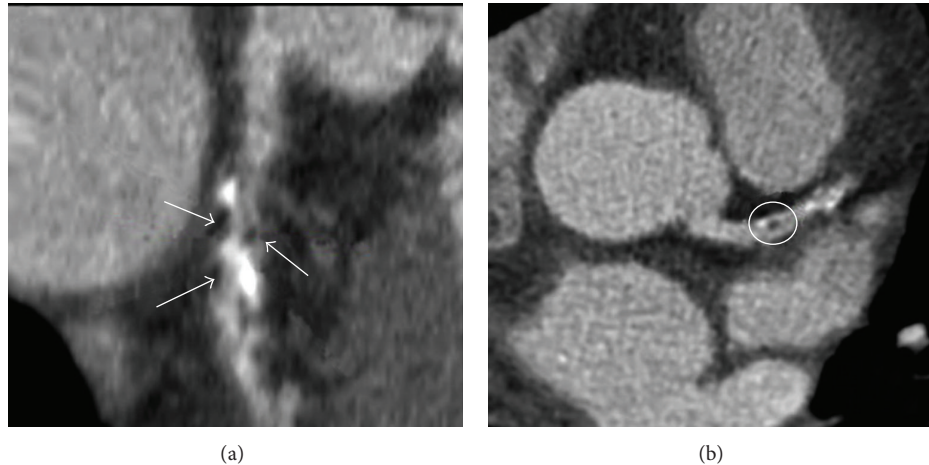


FIGURE 1: 64-slice coronary CT angiography (CCTA) in a 57-year-old man with non-ST elevation myocardial infarction. (a) CCTA image of multiplanar reconstruction of left anterior descending artery (LAD) showing multiple black low-density areas (white arrows) within the plaque. (b) Visualization of the LAD stenosis showing positive remodelling and presence of low-density plaque (<30 Hounsfield units) in the middle of the plaque (black area, white circle). Reprint with permission from [24].

and plaque burden [56]. Forty-two studies consisting of 1,360 patients were identified in this analysis with results showing no significant difference between CCTA and IVUS measurements of vessel cross-sectional area, plaque area, percentage of area stenosis, or plaque volume. The sensitivity and specificity of CCTA to detect any plaque were 93% and 92% when compared to IVUS, indicating that CCTA is accurate for the quantification of coronary plaques.

In summary, CCTA not only allows accurate detection of coronary atherosclerotic plaques but also enables quantitative analysis of plaque vessel area, lumen area, and plaque burden. Attempts at plaque quantification and characterisation using coronary CT angiography have been successful, although further refinements regarding reproducibility, accuracy, and ability to predict future cardiac events are required. With further improvements in CT imaging processing and diagnostic value, coronary CT angiography will become an integral part of the routine diagnostic approach for the noninvasive detection of vulnerable plaques that are prone to rupture so that appropriate preventive strategies can be implemented in a targeted population.

#### 4. Detection of Coronary Plaque Composition to Determine Plaque Vulnerability

Specific plaque features demonstrated by CCTA have been linked with ACS and other adverse cardiac events. These “adverse” plaque features include the low-attenuation plaque, remodelling index, spotty calcification, and the “napkin-ring” sign. The low-attenuation plaque refers to focal noncalcified plaque, within a specific low-attenuation threshold range between 30 and 60 HU [36, 52]. The remodelling index is defined as the ratio of the maximum vessel area (or diameter) to a normal reference vessel area (or diameter) as a measure of coronary arterial remodelling, and plaques are classified as having positive remodelling when the remodelling index

is >1.0 [57–59]. Spotty calcifications are defined by IVUS as small calcified nodules with length <3 mm within an IVUS arc of  $\leq 90^\circ$  [60, 61]. The napkin-ring sign, or the presence of a “contrast rim,” has recently been reported to be a CT signature of high-risk coronary atherosclerotic plaque [62, 63].

**4.1. Low-Attenuation Area.** A major focus of current research is targeted toward identification of vulnerable plaques destined to become index lesions [64]. This has been driven by classic pathological and imaging (mainly coronary angiographic) observations suggesting that ACS is most commonly associated with rupture of mild angiographic stenoses. The pathological features of vulnerable coronary plaques are well established, including the presence of a large necrotic core, a large volume, and positive remodelling of the vessel [65, 66].

Studies comparing CCTA images with IVUS have shown that CCTA can accurately evaluate image characteristics in vulnerable plaques in patients with ACS. Takaoka et al. in their study compared CCTA with IVUS for analysing unstable plaques and they found that CT densities correlated with soft plaques as diagnosed by IVUS were  $32.9 \pm 8.7$  HU and those associated with thrombus were  $43.2 \pm 10.7$  HU, while both values were significantly lower than those of fibrous plaques as identified by IVUS, which were  $82.5 \pm 22.6$  HU [67]. Their findings showed that CT values for plaque density are significantly lower for the soft components than for fibrous components of the atherosclerotic plaques. Benedek et al. also reported that CT characterizes the unstable coronary culprit lesion with a large total plaque volume, higher remodelling index, and larger amount of low-density atheroma or necrotic core within the plaque when compared with nonculprit lesions (Figure 1) [24]. Vulnerable plaques were found to present a significantly higher burden with the low-density plaque with 30 HU ( $23.3 \text{ mm}^3$  versus  $7.6 \text{ mm}^3$ ) and 60 HU ( $33.4 \text{ mm}^3$  versus  $16.9 \text{ mm}^3$ ) thresholds than non-vulnerable plaques; however, no significant difference was reached for higher density plaques (60–100 HU threshold).

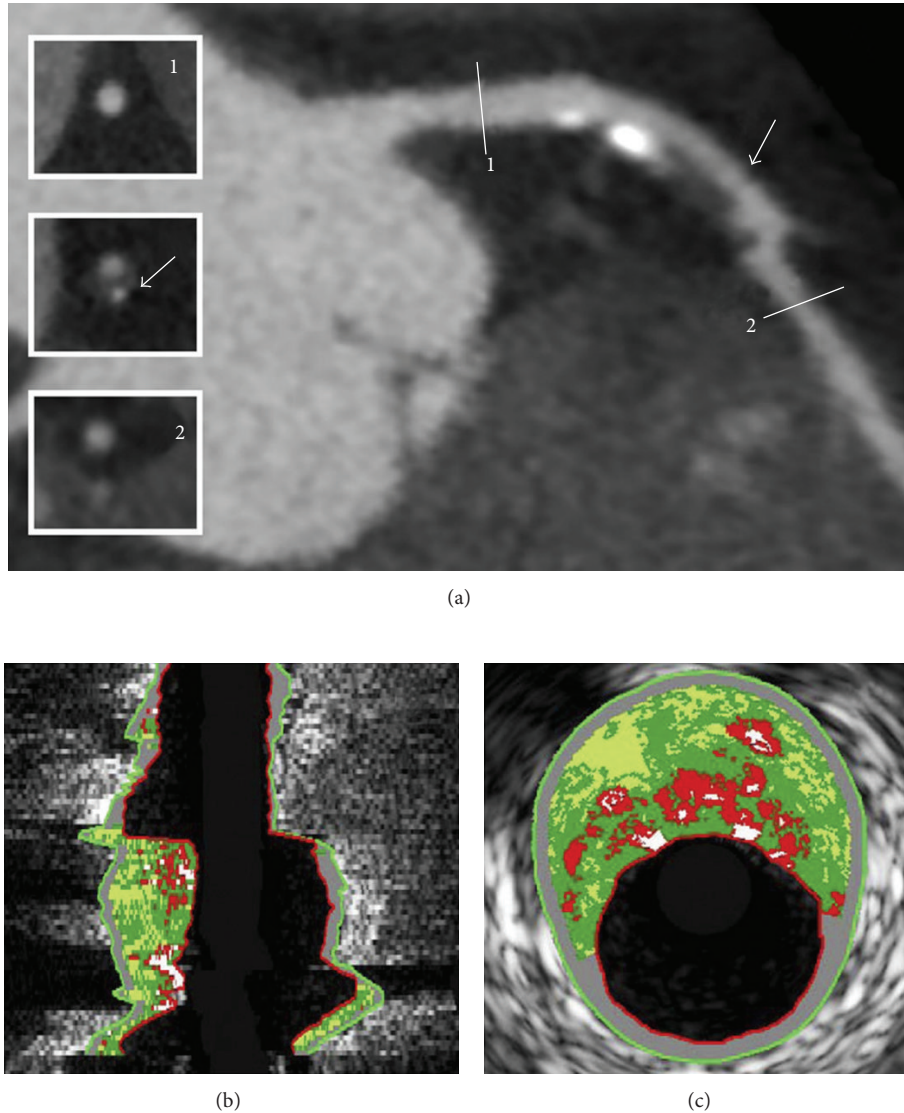


FIGURE 2: Example of lesion with positive remodelling on 320-row CT angiography and corresponding findings on virtual histologic intravascular ultrasound image. Curved multiplanar reconstruction of left anterior descending coronary artery showing a large plaque in the proximal segment of the vessel (a). The diameter of the vessel at the plaque site (arrow) is larger compared to the diameter at the reference sections (1, 2), indicating the presence of positive remodeling. Corresponding longitudinal (b) and cross-sectional (c) virtual histologic intravascular ultrasound images demonstrate an outward-remodeled lesion, with a large plaque burden (69%) and a large amount of necrotic core (19%) (red areas), corresponding to a thin-capped fibroatheroma lesion. Reprint with permission from [25].

The PROSPECT (providing regional observations to study predictors of events in the coronary tree) trial used multimodality intravascular imaging to identify the lesion characteristics that represent risk markers for future adverse cardiac events and concluded that lesion characteristics predictive of future events were a large plaque burden, a small luminal area, and thin-cap fibroatheroma, further confirming the importance of higher volume lesions as substrates for ACS [68].

**4.2. Positive Remodelling.** The response of coronary arteries to atherosclerosis and plaque growth manifested as either

compensatory enlargement or shrinkage is referred to as coronary artery remodelling. Increase in vessel size due to outward expansion of the vessel wall is called positive remodelling, while decrease in vessel size due to vessel shrinkage is defined as negative remodelling [69]. The assessment of compensatory enlargement or positive remodelling of coronary arteries has attracted a lot of attention due to the association of positively remodelled coronary plaques with plaque vulnerability and the propensity to cause future cardiac events based on histopathological and clinical studies [70–74]. IVUS is the preferred method for the assessment of coronary artery remodelling in vivo [70–75], whereas CCTA as a less invasive imaging modality can not only visualize




FIGURE 3: Late fibroatheroma as classified by histology (a). Note the large necrotic core (\*) in the center of the plaque, which correlates with the hypodense center of the plaque (\*) in CT (b). The core is surrounded by prominent fibrotic tissue (open arrows), which appears as a hyperdense ring around the core in CT. Thus the plaque has a ring-like appearance in coronary CT angiography which was coined as napkin-ring sign. Additionally neovascularization is present within the plaque (closed arrow). Reprint with permission from [26].




FIGURE 4: Virtual intravascular endoscopy visualization of normal coronary artery, (a) right coronary artery and (b) left coronary artery.

the coronary artery lumen but also coronary atherosclerotic plaque, with promising results reported compared with IVUS [75, 76].

Achenbach et al. in their early study based on 16-slice CT indicated that CCTA has potential to assess remodelling of coronary plaques in selected patients when compared to IVUS [77]. They found a lesser degree of remodelling in lesions with a significant (>50%) lumen stenosis as compared to nonstenotic coronary lesions. Latest reports confirm the diagnostic value of CCTA in the quantification of positive remodelling of coronary lesions [25, 75, 78]. CCTA with use of high resolution 64- or more slice scanners significantly improves image quality, resulting in accurate assessment of coronary lesions. Kröner et al. evaluated the association between positive remodelling on 64-/320-slice CCTA and

plaque characteristics on IVUS/VH in 55 patients with a total of 99 plaques being identified and analysed [25]. Positive remodelling on CCTA was related to vulnerable plaque characteristics on IVUS/VH as lesions with positive remodelling on CCTA were found to have a significantly higher plaque burden (large necrotic core and thin-cap fibroatheroma) on IVUS/VH images (Figure 2). Guass et al. in their recent study explored the accuracy of dual-source CCTA for detecting coronary remodelling of atherosclerotic plaques in comparison with IVUS and their results are in line with other studies [78]. In particular, authors in this study found that a cut-off remodelling index  $\geq 1.1$  improved specificity to 78% compared with the specificity of 45% using the standard cut-off remodelling index  $\geq 1.05$ , although the sensitivity reduced from 100% to 83%. They suggested that



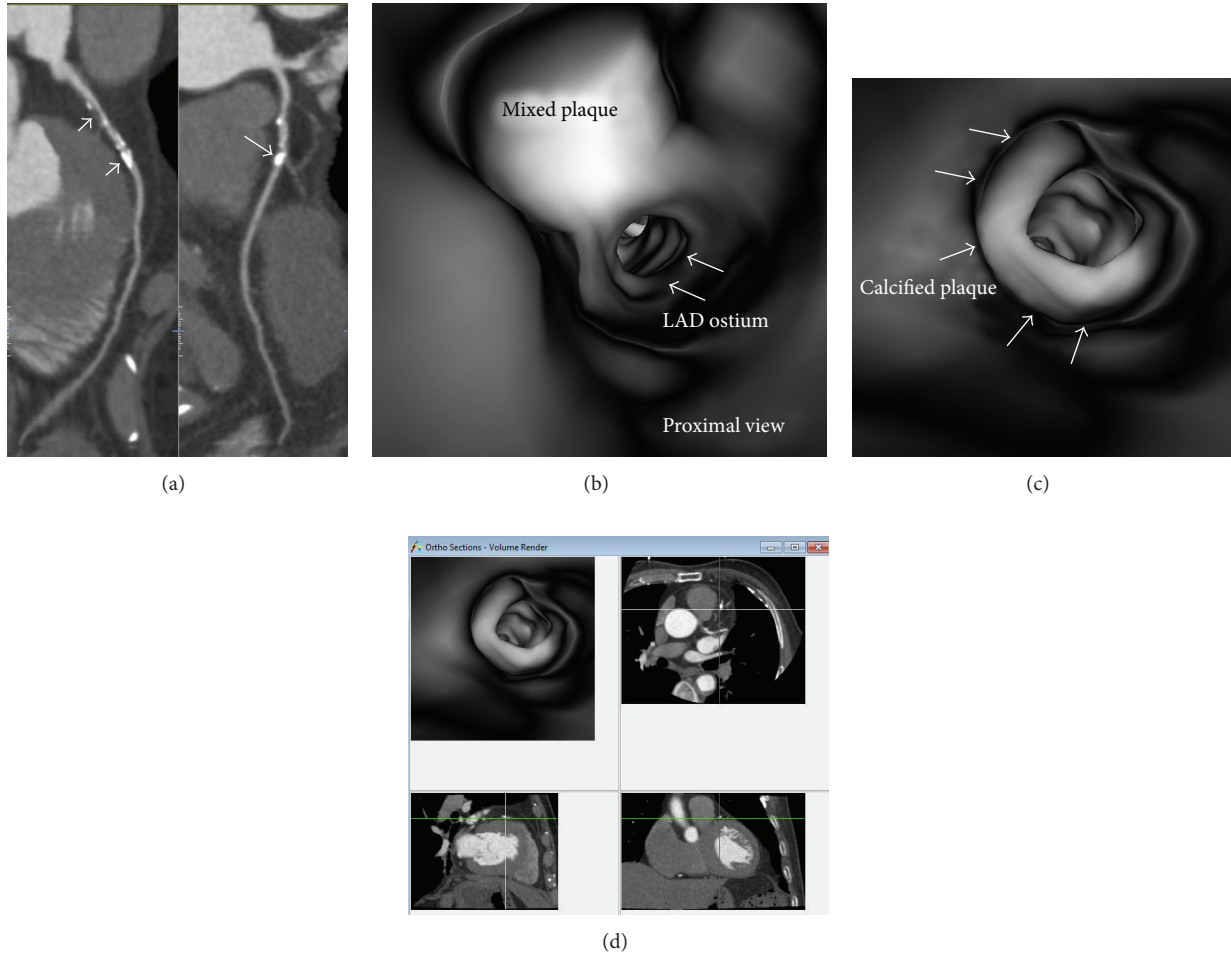


FIGURE 5: Virtual intravascular endoscopy (VIE) visualization of mixed and calcified plaques in a 75-year-old male with coronary artery disease. (a) Curved planar reformation shows mixed plaque (short arrow) and calcified plaques (long arrows) in the proximal segment of left anterior descending coronary artery (LAD). (b) Close VIE view of the mixed plaque. (c) VIE view of the calcified plaque at LAD with significant lumen stenosis. (d) Orthogonal views help to confirm the intraluminal plaque position of the calcified plaque.

a threshold of 1.1 for the remodelling index should be used to enable accurate classification of positively remodelling plaques by CCTA.

**4.3. Napkin-Ring Sign.** Recently, several studies have described specific attenuation pattern of atherosclerotic plaques on coronary CT images characterized by a plaque core with low CT attenuation surrounded by a rim-like area of higher CT attenuation as napkin-ring sign [79–81]. A similar ring-like enhancement was found in plaques with thin-cap fibroatheromas or in patients presenting with ACS but less commonly seen in plaques without thin fibrous caps or never seen in patients with stable angina [26, 82]. Nishio et al. reported that a ring-like enhancement pattern was observed in 445 of disrupted plaques detected by angiography in patients with suspected ischemic heart disease but only in 6% of plaques without signs of rupture [82]. This sign has been reported to be associated with high-risk

plaques and development of acute coronary syndromes [26, 82–85].

Seifarth et al. in their ex vivo study assessed histopathological features of advanced atherosclerotic plaques in 7 human donor hearts in relation to the napkin-ring sign observed in CCTA [26]. In this study, the results showed that plaques with a napkin-ring sign were associated with greater necrotic core area than plaques without this sign (1.1 mm<sup>2</sup> versus 0.46 mm<sup>2</sup>) (Figure 3). Further, the plaque size surrounding the necrotic core was twice as large in plaques with a napkin-ring sign compared to those plaques without the sign (10.15 mm<sup>2</sup> versus 6.36 mm<sup>2</sup>). These findings indicate that the napkin-ring sign could serve as a marker for advanced plaques on CCTA. Otsuka et al. in their prospective study consisting of 895 patients with a mean follow-up of 2.3 years further determined the predictive value of the napkin-ring sign for future ACS [84]. Plaques with a napkin-ring sign on CCTA were found to be of significant prognostic importance for ACS events, independent of other CCTA

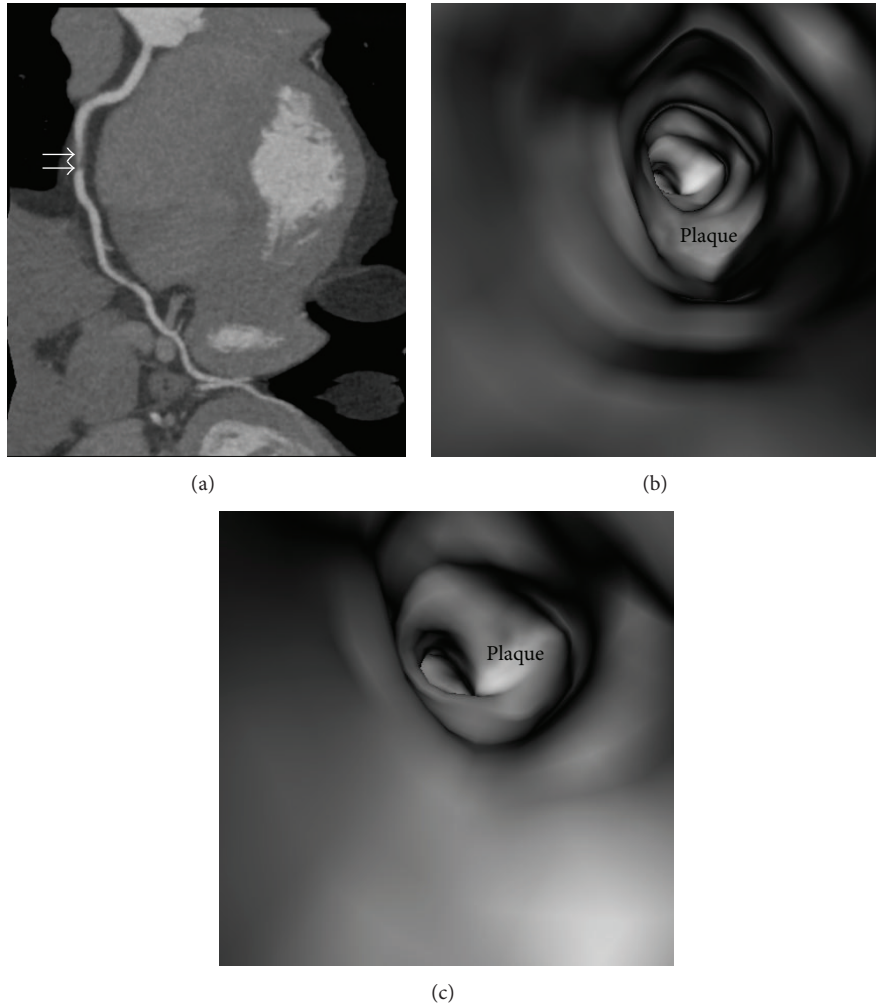


FIGURE 6: Virtual intravascular endoscopy (VIE) visualization of noncalcified plaque in a 42-year-old male with suspected coronary artery disease. (a) Curved planar reformation shows a noncalcified plaque at the proximal segment of right coronary artery (arrows). (b) and (c) VIE views of the plaque demonstrate smooth intraluminal appearance with significant stenosis.

features including positive remodelling and low-attenuation plaque. Kaplan-Meier analysis showed the plaques with napkin-ring signs were associated with a higher risk of ACS events compared with those without such a sign.

In summary, the current analysis confirms that the majority of acute coronary syndromes are caused by coronary plaques with features of positive remodelling, low-attenuation area, and napkin-ring sign. The substudy of the PROSPECT trial demonstrated that vulnerable plaques are frequently seen in the proximal coronary tree, followed by the mid coronary tree and the least in the distal coronary tree [85]. Of these three characteristics of vulnerable plaques, the current evidence shows that the napkin-ring sign represents the most reliable indicator of predicting ACS. The possible mechanisms of the napkin-ring sign include intraplaque vasa vasorum enhancement by the CCTA [86, 87], intraplaque hemorrhage or thrombus with peripheral enhancement by contrast media, or microcalcifications in the plaque which are strongly associated with the development of future ACS [36]. Detection of a napkin-ring sign could help identify

patients at high risk of future ACS events, although large-scale multicenter studies are needed to confirm these findings.

### 5. 3D Virtual Intravascular Endoscopy Characterization of Coronary Plaques

Coronary angiography allows direct visualization of the intraluminal surface and is the gold standard for assessing surface characteristics of the coronary wall in patients, such as plaque colour, presence of thrombus, and integrity of the plaque [88–90]. Coronary angiography can be used to identify vulnerable plaques in patients with CAD. The plaque in the coronary artery can be white or yellow angiographically, depending on the histological presence of thick or thin fibrous cap [91]. However, some limitations that exist in angiography include the inherently limited ability to identify only surface morphology and its blindness to subsurface pathology and internal plaque composition [88]. Visualization of the proximal coronary artery segments is limited



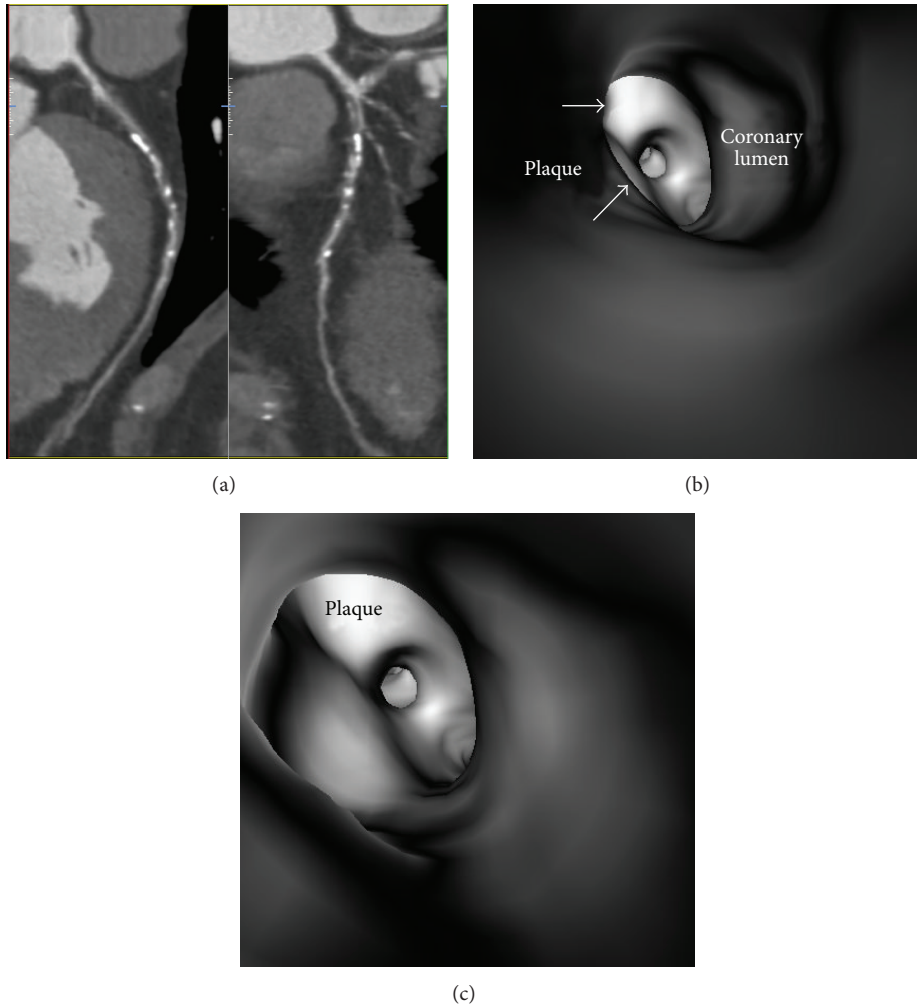


FIGURE 7: Virtual intravascular endoscopy (VIE) visualization of mixed plaque in a 56-year-old male with coronary artery disease. (a) Curved planar reformation shows mixed plaques at the proximal segment of left anterior descending artery (LAD). Corresponding VIE images (b) and (c) show that the irregular intraluminal appearance is due to presence of different plaque components within the plaque.

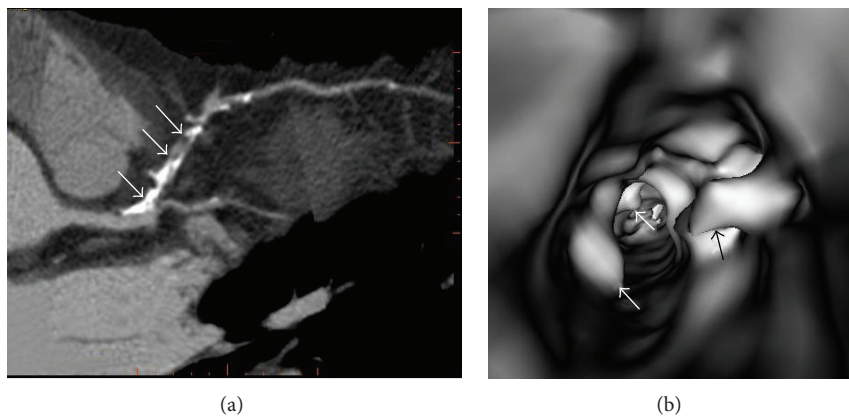


FIGURE 8: Virtual intravascular endoscopy (VIE) appearance of extensively calcified plaque in a 52-year-old man with coronary artery disease. (a) Curved planar reformation shows significant stenosis of left anterior descending coronary artery due to presence of plaques with heavy calcification (arrows). (b) VIE shows irregular intraluminal changes due to different compositions within the plaques (arrows).

as the left main stem cannot be occluded and very distal arteries are not readily visualized. Finally, balloon occlusion which is required to generate clear visible field can lead to the complications of coronary ischemia. Thus, coronary angiography is not commonly performed in clinical practice, while virtual angiography or virtual endoscopy with aid of high resolution medical imaging is increasingly used as a less invasive method to generate similar endoscopic images.

CT virtual intravascular endoscopy (VIE) is a 3D imaging technique which presents intraluminal views of the anatomy of human vessels in a noninvasive way. By acquiring volumetric CT data after contrast enhancement in a single breath-hold, it is possible to render 3D images of vascular structures that simulate images obtained from conventional endoscopy/angiography. VIE images of the normal arterial anatomy as well as pathological changes such as calcification, arterial stenosis, aneurysm, and intraluminal thrombus can be visualized in a way that may enhance diagnostic capability compared with conventional 2D or 3D visualization methods [91–102].

In normal coronary artery without presence of coronary plaques or atherosclerotic changes, the coronary wall appears smooth with clear demonstration of the ostial configuration and lumen on VIE visualization (Figure 4). When the plaques are present in the artery wall, different configurations are noticed, depending on the composition of the plaques. Studies have shown that VIE, as a novel visualization tool, clearly demonstrates the intraluminal changes of different types of plaques and offers additional information compared to conventional 2D or 3D extraluminal views [103, 104]. The appearance of coronary plaques visualized on VIE images can be classified into regular, smooth, and irregular appearance, depending on the type and composition and extent of the plaques.

**5.1. VIE Visualization of Coronary Plaques: Smooth Intraluminal Appearance.** When calcified or noncalcified plaques are present in the coronary wall, VIE shows smooth appearance in the coronary wall, with a protruding sign arising from the artery wall, resulting in the lumen stenosis, as shown in Figures 5 and 6.

**5.2. VIE Visualization of Coronary Plaques: Irregular Intraluminal Appearance.** Irregular appearance of the coronary wall is commonly observed in the mixed plaques as shown on VIE since different components are contained within the plaques (Figure 7). This indicates that the coronary wall undergoes different stages of remodelling, consisting of both stable stage involving formation of calcified plaques and unstable period involving deposition of noncalcified plaques which contain lipid-rich components.

Irregular appearance of the coronary wall is also seen in extensively calcified plaques due to the remodelling of the artery wall caused by plaques which are formed along the coronary artery (Figure 8), as most of the calcified plaques are eccentric. For the type of concentrically calcified plaques,

smooth and regular appearance is noticed at the artery wall but with central lumen stenosis (Figure 5(c)).

In summary, 3D VIE visualization has potential applications for assessment of coronary plaques in terms of plaque characterization and intraluminal appearances. VIE findings are considered valuable for enhancing our understanding of the effect of coronary plaques on coronary wall and subsequent clinical outcomes. Further studies are needed to correlate coronary wall changes due to different types of plaques with corresponding disease progression (e.g., major adverse cardiac events) with the aim of providing risk stratification and patient management.

## 6. Summary and Concluding Remarks

Significant progress has been made in the last decade to advance our understanding of the biology of atherosclerosis. This has resulted in accurate identification of vulnerable plaques that are prone to inducing ACS, which can account for the sudden onset of clinical presentation in the majority of patients with CAD. Coronary CT angiography has been widely investigated to define the specific characteristics of vulnerable atherosclerotic plaques, with promising results having been achieved compared to intravascular ultrasound. Coronary CT angiography allows visualization of coronary atherosclerotic lesions with characteristics assumed to be associated with plaque vulnerability in patients with ACS as compared with patients with stable clinical presentation. Furthermore, coronary CT angiography enables generation of 3D intraluminal views of coronary wall and plaque with regard to different types of atherosclerotic plaques, which further strengthen CT contribution toward the differentiation of vulnerable patients. However, there exists a large variability regarding the plaque characteristics in relation to the plaque vulnerability in coronary CT angiography, making it more difficult to identify the actual culprit lesion in patients with ACS. Future research will be focusing on the ability of coronary CT angiography to investigate plaque characteristics throughout the entire coronary system rather than identifying a single lesion in a noninvasive fashion with the aim of identifying vulnerable patients at risk for ACS. Large, longitudinal, multicenter trials to determine the prognostic value of comprehensive plaque assessment and standardized CT indicators of vulnerable plaques are also warranted.

## Conflict of Interests

The authors declare that there is no conflict of interests regarding the publication of this paper.

## References

- [1] E. J. Topol and S. E. Nissen, "Our preoccupation with coronary luminology: the dissociation between clinical and angiographic findings in ischemic heart disease," *Circulation*, vol. 92, no. 8, pp. 2333–2342, 1995.
- [2] W. C. Little, M. Constantinescu, R. J. Applegate et al., "Can coronary angiography predict the site of a subsequent myocardial

- infarction in patients with mild-to-moderate coronary artery disease?" *Circulation*, vol. 78, no. 5, pp. 1157–1166, 1988.
- [3] A. P. Burke, A. Farb, G. T. Malcom, Y. Liang, J. Smialek, and R. Virmani, "Coronary risk factors and plaque morphology in men with coronary disease who died suddenly," *The New England Journal of Medicine*, vol. 336, no. 18, pp. 1276–1282, 1997.
  - [4] M. J. Davies, "The composition of coronary-artery plaques," *The New England Journal of Medicine*, vol. 336, no. 18, pp. 1313–1314, 1997.
  - [5] R. Virmani, A. P. Burke, A. Farb, and F. D. Kolodgie, "Pathology of the vulnerable plaque," *Journal of the American College of Cardiology*, vol. 47, no. 8, pp. C13–C18, 2006.
  - [6] C. Briguori, A. Anzuini, F. Airoldi et al., "Intravascular ultrasound criteria for the assessment of the functional significance of intermediate coronary artery stenoses and comparison with fractional flow reserve," *American Journal of Cardiology*, vol. 87, no. 2, pp. 136–141, 2001.
  - [7] V. Jasti, E. Ivan, V. Yalamanchili, N. Wongpraparut, and M. A. Leesar, "Correlations between fractional flow reserve and intravascular ultrasound in patients with an ambiguous left main coronary artery stenosis," *Circulation*, vol. 110, no. 18, pp. 2831–2836, 2004.
  - [8] T. Nishioka, A. M. Amanullah, H. Luo et al., "Clinical validation of intravascular ultrasound imaging for assessment of coronary stenosis severity: comparison with stress myocardial perfusion imaging," *Journal of the American College of Cardiology*, vol. 33, no. 7, pp. 1870–1878, 1999.
  - [9] S. E. Nissen, E. M. Tuzcu, P. Schoenhagen et al., "Effect of intensive compared with moderate lipid-lowering therapy on progression of coronary atherosclerosis: a randomized controlled trial," *The Journal of the American Medical Association*, vol. 291, no. 9, pp. 1071–1080, 2004.
  - [10] I. Sipahi, S. J. Nicholls, E. M. Tuzcu, and S. E. Nissen, "Coronary atherosclerosis can regress with very intensive statin therapy," *Cleveland Clinic Journal of Medicine*, vol. 73, no. 10, pp. 937–944, 2006.
  - [11] S. E. Nissen, S. J. Nicholls, I. Sipahi et al., "Effect of very high-intensity statin therapy on regression of coronary atherosclerosis: the ASTEROID trial," *The Journal of the American Medical Association*, vol. 295, no. 13, pp. 1556–1565, 2006.
  - [12] S. E. Nissen, E. M. Tuzcu, P. Schoenhagen et al., "Statin therapy, LDL cholesterol, C-reactive protein, and coronary artery disease," *The New England Journal of Medicine*, vol. 352, no. 1, pp. 29–38, 2005.
  - [13] M. J. Budoff, D. Dowe, J. G. Jollis et al., "Diagnostic performance of 64-multidetector row coronary computed tomographic angiography for evaluation of coronary artery stenosis in individuals without known coronary artery disease: results from the prospective multicenter ACCURACY (Assessment by Coronary Computed Tomographic Angiography of Individuals Undergoing Invasive Coronary Angiography) trial," *Journal of the American College of Cardiology*, vol. 52, no. 21, pp. 1724–1732, 2008.
  - [14] J. M. Miller, C. E. Rochitte, M. Dewey et al., "Diagnostic performance of coronary angiography by 64-row CT," *The New England Journal of Medicine*, vol. 359, no. 22, pp. 2324–2336, 2008.
  - [15] W. B. Meijboom, M. F. Meijjs, J. D. Schuijf et al., "Diagnostic accuracy of 64-slice computed tomography coronary angiography: a prospective, multicenter, multivendor study," *Journal of the American College of Cardiology*, vol. 52, no. 25, pp. 2135–2144, 2008.
  - [16] Z. Sun, G. H. Choo, and K. H. Ng, "Coronary CT angiography: current status and continuing challenges," *The British Journal of Radiology*, vol. 85, no. 1013, pp. 495–510, 2012.
  - [17] L. Xu, L. Yang, Z. Fan, W. Yu, B. Lv, and Z. Zhang, "Diagnostic performance of 320-detector CT coronary angiography in patients with atrial fibrillation: preliminary results," *European Radiology*, vol. 21, no. 5, pp. 936–943, 2011.
  - [18] G. Foster, H. Shah, G. Sarraf, N. Ahmadi, and M. Budoff, "Detection of noncalcified and mixed plaque by multirow detector computed tomography," *Expert Review of Cardiovascular Therapy*, vol. 7, no. 1, pp. 57–64, 2009.
  - [19] G. Pundziute, J. D. Schuijf, J. W. Jukema et al., "Head-to-head comparison of coronary plaque evaluation between multislice computed tomography and intravascular ultrasound radiofrequency data analysis," *JACC: Cardiovascular Interventions*, vol. 1, no. 2, pp. 176–182, 2008.
  - [20] F. Lin, L. J. Shaw, D. S. Berman et al., "Multidetector computed tomography coronary artery plaque predictors of stress-induced myocardial ischemia by SPECT," *Atherosclerosis*, vol. 197, no. 2, pp. 700–709, 2008.
  - [21] G. Pundziute, J. D. Schuijf, J. W. Jukema et al., "Prognostic value of multislice computed tomography coronary angiography in patients with known or suspected coronary artery disease," *Journal of the American College of Cardiology*, vol. 49, no. 1, pp. 62–70, 2007.
  - [22] J. M. van Werkhoven, J. D. Schuijf, O. Gaemperli et al., "Prognostic value of multislice computed tomography and gated single-photon emission computed tomography in patients with suspected coronary artery disease," *Journal of the American College of Cardiology*, vol. 53, no. 7, pp. 623–632, 2009.
  - [23] S. S. Dhawan, R. P. A. Nanjundappa, J. R. Branch et al., "Shear stress and plaque development," *Expert Review of Cardiovascular Therapy*, vol. 8, no. 4, pp. 545–556, 2010.
  - [24] T. Benedek, M. Gyöngyösi, and I. Benedek, "Multislice computed tomographic coronary angiography for quantitative assessment of culprit lesions in acute coronary syndromes," *Canadian Journal of Cardiology*, vol. 29, no. 3, pp. 364–371, 2013.
  - [25] E. S. J. Kröner, J. E. van Velzen, M. J. Boogers et al., "Positive remodeling on coronary computed tomography as a marker for plaque vulnerability on virtual histology intravascular ultrasound," *The American Journal of Cardiology*, vol. 107, no. 12, pp. 1725–1729, 2011.
  - [26] H. Seifarth, C. L. Schlett, M. Nakano et al., "Histopathological correlates of the napkin-ring sign plaque in coronary CT angiography," *Atherosclerosis*, vol. 224, no. 1, pp. 90–96, 2012.
  - [27] G. W. Stone, A. Maehara, and G. S. Mintz, "The reality of vulnerable plaque detection," *JACC Cardiovascular Imaging*, vol. 4, no. 8, pp. 902–904, 2011.
  - [28] J. A. Ambrose, M. A. Tannenbaum, D. Alexopoulos et al., "Angiographic progression of coronary artery disease and the development of myocardial infarction," *Journal of the American College of Cardiology*, vol. 12, no. 1, pp. 56–62, 1988.
  - [29] M. Yamagishi, M. Terashima, K. Awano et al., "Morphology of vulnerable coronary plaque: Insights from follow-up of patients examined by intravascular ultrasound before an acute coronary syndrome," *Journal of the American College of Cardiology*, vol. 35, no. 1, pp. 106–111, 2000.
  - [30] G. Sarno, P. Vanhoenacker, I. Decramer et al., "Characterisation of the 'vulnerable' coronary plaque by multi-detector computed tomography: a correlative study with intravascular ultrasound-derived radiofrequency analysis of plaque composition," *EuroIntervention*, vol. 4, no. 3, pp. 318–323, 2008.



- [31] A. Varnava, P. Mills, and M. Davies, "Relationship between coronary artery remodeling and plaque vulnerability," *Circulation*, vol. 105, no. 8, pp. 939–943, 2002.
- [32] K. K. L. Wong, P. Thavornpattanonpong, S. C. P. Cheung, Z. Sun, and J. Tu, "Effect of calcification on the mechanical stability of plaque based on a three-dimensional carotid bifurcation model," *BMC Cardiovascular Disorders*, vol. 12, article 7, 2012.
- [33] T. Kitagawa, H. Yamamoto, J. Horiguchi et al., "Characterization of noncalcified coronary plaques and identification of culprit lesions in patients with acute coronary syndrome by 64-slice computed tomography," *JACC: Cardiovascular Imaging*, vol. 2, no. 2, pp. 153–160, 2009.
- [34] P. Schoenhagen, E. M. Tuzcu, C. Apperson-Hansen et al., "Determinants of arterial wall remodeling during lipid-lowering therapy: serial intravascular ultrasound observations from the reversal of atherosclerosis with aggressive lipid lowering therapy (REVERSAL) trial," *Circulation*, vol. 113, no. 24, pp. 2826–2834, 2006.
- [35] M. Schmid, T. Pflederer, I. K. Jang et al., "Relationship between degree of remodeling and CT attenuation of plaque in coronary atherosclerotic lesions: an in-vivo analysis by multi-detector computed tomography," *Atherosclerosis*, vol. 197, no. 1, pp. 457–464, 2008.
- [36] S. Motoyama, M. Sarai, H. Harigaya et al., "Computed tomographic angiography characteristics of atherosclerotic plaques subsequently resulting in acute coronary syndrome," *Journal of the American College of Cardiology*, vol. 54, no. 1, pp. 49–57, 2009.
- [37] M. O. Versteyleen, B. L. Kietselaer, P. C. Dagnelie et al., "Additive value of semiautomated quantification of coronary artery disease using cardiac computed tomographic angiography to predict future acute coronary syndrome," *Journal of the American College of Cardiology*, vol. 61, no. 22, pp. 2296–2305, 2013.
- [38] T. S. Kristensen, K. F. Kofoed, J. T. Khl, W. B. Nielsen, M. B. Nielsen, and H. Kelbæk, "Prognostic implications of nonobstructive coronary plaques in patients with non-ST-segment elevation myocardial infarction: a multidetector computed tomography study," *Journal of the American College of Cardiology*, vol. 58, no. 5, pp. 502–509, 2011.
- [39] P. Maurovich-Horvat, M. Ferencik, S. Voros, B. Merkely, and U. Hoffmann, "Comprehensive plaque assessment by coronary CT angiography," *Nature Reviews Cardiology*, vol. 11, pp. 390–402, 2014.
- [40] J. Hausleiter, T. Meyer, M. Hadamitzky, A. Kastrati, S. Martinoff, and A. Schömig, "Prevalence of noncalcified coronary plaques by 64-Slice CT in patients with an intermediate risk for significant coronary artery disease," *Journal of the American College of Cardiology*, vol. 48, no. 2, pp. 312–318, 2006.
- [41] J. Butler, M. Shapiro, J. Reiber et al., "Extent and distribution of coronary artery disease: a comparative study of invasive versus noninvasive angiography with computed angiography," *American Heart Journal*, vol. 153, no. 3, pp. 378–384, 2007.
- [42] A. Saraste and J. Knuuti, "Novel CT-based imaging markers for high-risk coronary plaques," *European Heart Journal Cardiovascular Imaging*, vol. 13, no. 8, pp. 633–634, 2012.
- [43] A. C. Kwan, G. Cater, J. Vargas, and D. A. Bluemke, "Beyond coronary stenosis: coronary computed tomographic angiography for the assessment of atherosclerotic plaque burden," *Current Cardiovascular Imaging Reports*, vol. 6, no. 2, pp. 89–101, 2013.
- [44] S. Rinehart, G. Vazquez, Z. Qian, L. Murrieta, K. Christian, and S. Voros, "Quantitative measurements of coronary arterial stenosis, plaque geometry, and composition are highly reproducible with a standardized coronary arterial computed tomographic approach in high-quality CT datasets," *Journal of Cardiovascular Computed Tomography*, vol. 5, no. 1, pp. 35–43, 2011.
- [45] A. F. Kopp, S. Schroeder, A. Baumbach et al., "Non-invasive characterisation of coronary lesion morphology and composition by multislice CT: first results in comparison with intracoronary ultrasound," *European Radiology*, vol. 11, no. 9, pp. 1607–1611, 2001.
- [46] S. Schroeder, A. F. Kopp, A. Baumbach et al., "Noninvasive detection and evaluation of atherosclerotic coronary plaques with multislice computed tomography," *Journal of the American College of Cardiology*, vol. 37, no. 5, pp. 1430–1435, 2001.
- [47] T. Pflederer, M. Marwan, T. Schepis et al., "Characterization of culprit lesions in acute coronary syndromes using coronary dual-source CT angiography," *Atherosclerosis*, vol. 211, no. 2, pp. 437–444, 2010.
- [48] R. Nakazato, A. Shalev, J. H. Doh et al., "Quantification and characterisation of coronary artery plaque volume and adverse plaque features by coronary computed tomographic angiography: a direct comparison to intravascular ultrasound," *European Radiology*, vol. 23, no. 8, pp. 2109–2117, 2013.
- [49] S. Papadopoulou, L. A. Neefjes, M. Schaap et al., "Detection and quantification of coronary atherosclerotic plaque by 64-slice multidetector CT: a systematic head-to-head comparison with intravascular ultrasound," *Atherosclerosis*, vol. 219, no. 1, pp. 163–170, 2011.
- [50] S. Voros, S. Rinehart, Z. Qian et al., "Prospective validation of standardized, 3-dimensional, quantitative coronary computed tomographic plaque measurements using radiofrequency backscatter intravascular ultrasound as reference standard in intermediate coronary arterial lesions: results from the ALTANTA (Assessment of Tissue Characteristics, Lesion Morphology, and Hemodynamics by Angiography with Fractional Flow Reserve, Intravascular Ultrasound and Virtual Histology, and Noninvasive Computed Tomography in Atherosclerotic Plaques) I Study," *JACC: Cardiovascular Interventions*, vol. 4, no. 2, pp. 198–208, 2011.
- [51] J. K. Min, M. Edwardes, F. Y. Lin et al., "Relationship of coronary artery plaque composition to coronary artery stenosis severity: results from the prospective multicenter ACCURACY trial," *Atherosclerosis*, vol. 219, no. 2, pp. 573–578, 2011.
- [52] S. Motoyama, T. Kondo, M. Sarai et al., "Multislice Computed Tomographic Characteristics of Coronary Lesions in Acute Coronary Syndromes," *Journal of the American College of Cardiology*, vol. 50, no. 4, pp. 319–326, 2007.
- [53] I. Springer and M. Dewey, "Comparison of multislice computed tomography with intravascular ultrasound for detection and characterization of coronary artery plaques: A systematic review," *European Journal of Radiology*, vol. 71, no. 2, pp. 275–282, 2009.
- [54] D. Gao, N. Ning, Y. Guo, W. Ning, X. Niu, and J. Yang, "Computed tomography for detecting coronary artery plaques: a meta-analysis," *Atherosclerosis*, vol. 219, no. 2, pp. 603–609, 2011.
- [55] S. Voros, S. Rinehart, Z. Qian et al., "Coronary atherosclerosis imaging by coronary CT angiography: current status, correlation with intravascular interrogation and meta-analysis," *JACC: Cardiovascular Imaging*, vol. 4, no. 5, pp. 537–548, 2011.

- [56] C. Fischer, E. Hulten, P. Belur et al., "Coronary CT angiography versus intravascular ultrasound for estimation of coronary stenosis and atherosclerotic plaque burden: a meta-analysis," *Journal of Cardiovascular Computed Tomography*, vol. 7, pp. 256–266, 2013.
- [57] A. P. Burke, F. D. Kolodgie, A. Farb, D. Weber, and R. Virmani, "Morphological predictors of arterial remodeling in coronary atherosclerosis," *Circulation*, vol. 105, no. 3, pp. 297–303, 2002.
- [58] P. C. Smits, G. Pasterkamp, M. A. Quarles van Ufford et al., "Coronary artery disease: arterial remodelling and clinical presentation," *Heart*, vol. 82, no. 4, pp. 461–464, 1999.
- [59] M. Sabaté, I. P. Kay, P. J. de Feyter et al., "Remodeling of atherosclerotic coronary arteries varies in relation to location and composition of plaque," *The American Journal of Cardiology*, vol. 84, no. 2, pp. 135–140, 1999.
- [60] S. Ehara, Y. Kobayashi, M. Yoshizawa et al., "Spotty calcification typifies the culprit plaque in patients with acute myocardial infarction: an intravascular ultrasound study," *Circulation*, vol. 110, no. 22, pp. 3424–3429, 2004.
- [61] B. L. van der Hoeven, S. Liem, P. V. Oemrawsingh et al., "Role of calcified spots detected by intravascular ultrasound in patients with ST-segment elevation acute myocardial infarction," *The American Journal of Cardiology*, vol. 98, no. 3, pp. 309–313, 2006.
- [62] P. Maurovich-Horvat, U. Hoffmann, M. Vorpahl, M. Nakano, R. Virmani, and H. Alkadhi, "The napkin-ring sign: CT signature of high-risk coronary plaques?" *JACC: Cardiovascular Imaging*, vol. 3, no. 4, pp. 440–444, 2010.
- [63] J. Narula and S. Achenbach, "Napkin-ring necrotic cores: defining circumferential extent of necrotic cores in unstable plaques," *JACC: Cardiovascular Imaging*, vol. 2, no. 12, pp. 1436–1438, 2009.
- [64] F. Sharif and R. T. Murphy, "Current status of vulnerable plaque detection," *Catheterization and Cardiovascular Interventions*, vol. 75, no. 1, pp. 135–144, 2010.
- [65] R. Virmani, A. P. Burke, F. D. Kolodgie, and A. Farb, "Pathology of the thin-cap fibroatheroma: a type of vulnerable plaque," *Journal of Interventional Cardiology*, vol. 16, no. 3, pp. 267–272, 2003.
- [66] M. J. Budoff, S. Achenbach, R. S. Blumenthal et al., "Assessment of coronary artery disease by cardiac computed tomography: a scientific statement from the American Heart Association Committee on Cardiovascular Imaging and Intervention, Council on Cardiovascular Radiology and Intervention, and Committee on Cardiac Imaging, Council on Clinical Cardiology," *Circulation*, vol. 114, no. 16, pp. 1761–1791, 2006.
- [67] H. Takaoka, I. Ishibashi, M. Uehara, G. D. Rubin, I. Komuro, and N. Funabashi, "Comparison of image characteristics of plaques in culprit coronary arteries by 64 slice CT and intravascular ultrasound in acute coronary syndromes," *International Journal of Cardiology*, vol. 160, no. 2, pp. 119–126, 2012.
- [68] G. W. Stone, A. Maehara, A. J. Lansky et al., "A prospective natural-history study of coronary atherosclerosis," *The New England Journal of Medicine*, vol. 364, no. 3, pp. 226–235, 2011.
- [69] T. Nishioka, H. Luo, N. L. Eigler, H. Berglund, C. Kim, and R. J. Siegel, "Contribution of inadequate compensatory enlargement to development of human coronary artery stenosis: an *in vivo* intravascular ultrasound study," *Journal of the American College of Cardiology*, vol. 27, no. 7, pp. 1571–1576, 1996.
- [70] G. Pasterkamp, A. H. Schoneveld, A. C. van der Wal et al., "Relation of arterial geometry to luminal narrowing and histologic markers for plaque vulnerability: the remodeling paradox," *Journal of the American College of Cardiology*, vol. 32, no. 3, pp. 655–662, 1998.
- [71] A. M. Varnava, P. G. Mills, and M. J. Davies, "Relationship between coronary artery remodeling and plaque vulnerability," *Circulation*, vol. 105, no. 8, pp. 939–943, 2002.
- [72] M. Gyongyosi, P. Yang, A. Hassan et al., "Intravascular ultrasound predictors of major adverse cardiac events in patients with unstable angina," *Clinical Cardiology*, vol. 23, no. 7, pp. 507–515, 2000.
- [73] M. Nakamura, H. Nishikawa, S. Mukai et al., "Impact of coronary artery remodeling on clinical presentation of coronary artery disease: An intravascular ultrasound study," *Journal of the American College of Cardiology*, vol. 37, no. 1, pp. 63–69, 2001.
- [74] P. Schoenhagen, K. M. Ziada, S. R. Kapadia, T. D. Crowe, S. E. Nissen, and E. M. Tuzcu, "Extent and direction of arterial remodeling in stable versus unstable coronary syndromes: an intravascular ultrasound study," *Circulation*, vol. 101, no. 6, pp. 598–603, 2000.
- [75] M. Schmid, T. Pflederer, I. Jang et al., "Relationship between degree of remodeling and CT attenuation of plaque in coronary atherosclerotic lesions: an *in-vivo* analysis by multi-detector computed tomography," *Atherosclerosis*, vol. 197, no. 1, pp. 457–464, 2008.
- [76] J. E. van Velzen, J. D. Schuijff, F. R. de Graaf et al., "Plaque type and composition as evaluated noninvasively by MSCT angiography and invasively by VH IVUS in relation to the degree of stenosis," *Heart*, vol. 95, no. 24, pp. 1990–1996, 2009.
- [77] S. Achenbach, D. Ropers, U. Hoffmann et al., "Assessment of coronary remodeling in stenotic and nonstenotic coronary atherosclerotic lesions by multidetector spiral computed tomography," *Journal of the American College of Cardiology*, vol. 43, no. 5, pp. 842–847, 2004.
- [78] S. Gauss, S. Achenbach, T. Pflederer, A. Schuhbäck, W. G. Daniel, and M. Marwan, "Assessment of coronary artery remodeling by dual-source CT: a head-to-head comparison with intravascular ultrasound," *Heart*, vol. 97, no. 12, pp. 991–997, 2011.
- [79] M. Kashiwagi, A. Tanaka, H. Kitabata et al., "Feasibility of non-invasive assessment of thin-cap fibroatheroma by multidetector computed tomography," *JACC: Cardiovascular Imaging*, vol. 2, no. 12, pp. 1412–1419, 2009.
- [80] A. Tanaka, K. Shimada, K. Yoshida et al., "Non-invasive assessment of plaque rupture by 64-slice multidetector computed tomography—comparison with intravascular ultrasound," *Circulation Journal*, vol. 72, no. 8, pp. 1276–1281, 2008.
- [81] J. A. Goldstein, C. Grines, T. Fischell et al., "Coronary embolization following balloon dilation of lipid-core plaques," *JACC: Cardiovascular Imaging*, vol. 2, no. 12, pp. 1420–1424, 2009.
- [82] M. Nishio, Y. Ueda, K. Matsuo et al., "Detection of disrupted plaques by coronary CT: comparison with angiography," *Heart*, vol. 97, no. 17, pp. 1397–1402, 2011.
- [83] P. Maurovich-Horvat, C. L. Schlett, H. Alkadhi et al., "The napkin-ring sign indicates advanced atherosclerotic lesions in coronary CT angiography," *JACC: Cardiovascular Imaging*, vol. 5, no. 12, pp. 1243–1252, 2012.
- [84] K. Otsuka, S. Fukuda, A. Tanaka et al., "Napkin-ring sign on coronary CT angiography for the prediction of acute coronary syndrome," *JACC: Cardiovascular Imaging*, vol. 6, no. 4, pp. 448–457, 2013.
- [85] J. J. Wykrzykowska, G. S. Mintz, H. M. Garcia-Garcia et al., "Longitudinal distribution of plaque burden and necrotic

- corerich plaques in nonculprit lesions of patients presenting with acute coronary syndromes,” *JACC: Cardiovascular Imaging*, vol. 5, no. 3, pp. S10–S18, 2012.
- [86] Z. Sun, “Atherosclerosis and atheroma plaque rupture: normal anatomy of vasa vasorum and their role associated with atherosclerosis,” *The Scientific World Journal*, vol. 2014, Article ID 285058, 6 pages, 2014.
- [87] Z. Sun, “Atherosclerosis and atheroma plaque rupture: imaging modalities in the visualization of vasa vasorum and atherosclerotic plaques,” *The Scientific World Journal*, vol. 2014, Article ID 312764, 12 pages, 2014.
- [88] F. Ishibashi, K. Aziz, G. S. Abela, and S. Waxman, “Update on coronary angiography: review of a 20-year experience and potential application for detection of vulnerable plaque,” *Journal of Interventional Cardiology*, vol. 19, no. 1, pp. 17–25, 2006.
- [89] Y. Ueda, A. Hirayama, and K. Kodama, “Plaque characterization and atherosclerosis evaluation by coronary angiography,” *Herz*, vol. 28, no. 6, pp. 501–504, 2003.
- [90] T. Thieme, K. D. Wernecke, R. Meyer et al., “Angioscopic evaluation of atherosclerotic plaques: validation by histomorphologic analysis and association with stable and unstable coronary syndromes,” *Journal of the American College of Cardiology*, vol. 28, no. 1, pp. 1–6, 1996.
- [91] K. Mizuno, A. Miyamoto, K. Satomura et al., “Angioscopic coronary macromorphology in patients with acute coronary disorders,” *The Lancet*, vol. 337, no. 8745, pp. 809–812, 1991.
- [92] E. Neri, D. Caramella, F. Falaschi et al., “Virtual CT intravascular endoscopy of the aorta: pierced surface and floating shape thresholding artifacts,” *Radiology*, vol. 212, no. 1, pp. 276–279, 1999.
- [93] Z. Sun, R. J. Winder, B. E. Kelly, P. K. Ellis, and D. G. Hirst, “CT virtual intravascular endoscopy of abdominal aortic aneurysms treated with suprarenal endovascular stent grafting,” *Abdominal Imaging*, vol. 28, no. 4, pp. 580–587, 2003.
- [94] Z. Sun, J. Winder, B. Kelly, P. Ellis, P. Kennedy, and D. Hirst, “Diagnostic value of CT virtual intravascular endoscopy in aortic stent grafting,” *Journal of Endovascular Therapy*, vol. 11, no. 1, pp. 13–25, 2004.
- [95] Z. Sun, M. E. O’Donnell, R. J. Winder, P. K. Ellis, and P. H. Blair, “Effect of suprarenal fixation of aortic stent-grafts on the renal artery ostia: Assessment of morphological changes by virtual intravascular endoscopy,” *Journal of Endovascular Therapy*, vol. 14, no. 5, pp. 650–660, 2007.
- [96] Z. Sun and E. Gallagher, “Multislice CT virtual intravascular endoscopy for abdominal aortic aneurysm stent grafts,” *Journal of Vascular and Interventional Radiology*, vol. 15, no. 9, pp. 961–970, 2004.
- [97] Z. Sun and H. Zheng, “Effect of suprarenal stent struts on the renal artery with ostial calcification observed on CT virtual intravascular endoscopy,” *European Journal of Vascular and Endovascular Surgery*, vol. 28, no. 5, pp. 534–542, 2004.
- [98] Z. Sun, “3D multislice CT angiography in post-aortic stent grafting: a pictorial essay,” *Korean Journal of Radiology*, vol. 7, no. 3, pp. 205–211, 2006.
- [99] Z. Sun, Y. B. Allen, S. Nadkarni, R. Knight, D. E. Hartley, and M. M. D. Lawrence-Brown, “CT virtual intravascular endoscopy in the visualization of fenestrated stent-grafts,” *Journal of Endovascular Therapy*, vol. 15, no. 1, pp. 42–51, 2008.
- [100] Z. Sun, B. Mwipatayi, Y. Allen, D. Hartley, and M. M. Lawrence-Brown, “Multislice CT angiography of fenestrated endovascular stent grafting for treating abdominal aortic aneurysms: a pictorial review of the 2D/3D visualizations,” *Korean Journal of Radiology*, vol. 10, no. 3, pp. 285–293, 2009.
- [101] Z. Sun, B. P. Mwipatayi, Y. B. Allen, D. E. Hartley, and M. M. D. Lawrence-Brown, “Computed tomography virtual intravascular endoscopy in the evaluation of fenestrated stent graft repair of abdominal aortic aneurysms,” *ANZ Journal of Surgery*, vol. 79, no. 11, pp. 836–840, 2009.
- [102] Z. Sun, S. A. Al Dosari, C. Ng, A. Al-Muntashari, and S. Almaliky, “Multislice CT virtual intravascular endoscopy for assessing pulmonary embolisms: a pictorial review,” *Korean Journal of Radiology*, vol. 11, no. 2, pp. 222–230, 2010.
- [103] Z. Sun, F. J. Dimpudus, J. Nugroho, and J. D. Adipranoto, “CT virtual intravascular endoscopy assessment of coronary artery plaques: a preliminary study,” *European Journal of Radiology*, vol. 75, no. 1, pp. e112–e119, 2010.
- [104] Z. Sun, “Coronary CT angiography in coronary artery disease: correlation between virtual intravascular endoscopic appearances and left bifurcation angulation and coronary plaques,” *BioMed Research International*, vol. 2013, Article ID 732059, 14 pages, 2013.