

Percutaneous Radiofrequency Ablation of a Small Renal Mass Complicated by Appendiceal Perforation

Judith Boone · Axel Bex · Warner Prevoo

Received: 17 June 2011 / Accepted: 18 September 2011 / Published online: 20 October 2011
© The Author(s) 2011. This article is published with open access at Springerlink.com

Abstract Percutaneous radiofrequency ablation (RFA) has gained wide acceptance as nephron-sparing therapy for small renal masses in select patients. Generally, it is a safe procedure with minor morbidity and acceptable short-term oncologic outcome. However, as a result of the close proximity of vital structures, such as the bowel, ureter, and large vessels, to the ablative field, complications regarding these structures may occur. This is the first article describing appendiceal perforation as a complication of computed tomography-guided RFA despite hydrodissection. When performing this innovative and promising procedure one should be aware of the possibility of particular minor and even major complications.

Keywords Interventional oncology · Ablation · Radiofrequency ablation · Kidney/renal · Cancer · Ischemia

Introduction

Due to the widespread use of imaging modalities, such as ultrasonography, computed tomography (CT), and magnetic resonance imaging, the incidences of incidentally found small cortical renal masses (SRMs) and renal cell carcinoma (RCC), have increased during the past years [1]. For decades, the standard therapy for patients with clinically suspected RCC consisted of radical nephrectomy, an invasive surgical procedure with high morbidity [2]. However, in a recently published randomized trial of nephron-sparing surgery (NSS) in patients with SRM yielded comparable oncological outcome with radical nephrectomy [3]. In addition, population-based studies clearly demonstrate an overall survival benefit in patients undergoing NSS as a result of preserved renal function [4, 5]. Nephron-preserving procedures, such as partial nephrectomy and image-guided minimally invasive ablative procedures, have therefore increasingly been applied in patients with SRM [6, 7]. Initially, image-guided ablative procedures were performed in patients who were not suitable candidates for NSS based on significant medical comorbidity, advanced symptomatic disease, or refusal of conventional therapy [6, 8]. Accumulating data on follow-up and oncological safety suggest a broader indication in patients with SRM [9].

A particular form of an image-guided ablative procedure is radiofrequency ablation (RFA), which can be performed open or percutaneously [10]. In RFA, an electric current oscillates through an electrode placed centrally in the target tissue. This results in frictional ionic agitation and heat formation in the tissue surrounding the tip of the electrode, causing local protein coagulation and cellular death [11]. Compared with open and laparoscopic (partial) nephrectomy, RFA has several advantages. It is a nephron-sparing

J. Boone (✉) · W. Prevoo
Department of Radiology, The Netherlands Cancer Institute,
Antoni van Leeuwenhoek Hospital, 1066 CX Amsterdam,
The Netherlands
e-mail: j.boone@amc.uva.nl

W. Prevoo
e-mail: w.prevoo@nki.nl

J. Boone
Department of Radiology, Academic Medical Center
Amsterdam, 1105 AZ Amsterdam, The Netherlands

A. Bex
Department of Urology, The Netherlands Cancer Institute,
Antoni van Leeuwenhoek Hospital, 1066 CX Amsterdam,
The Netherlands
e-mail: a.bex@nki.nl

therapy with low morbidity and mortality, short hospital stay, and acceptable oncologic outcome [8, 10, 12]. Moreover, the procedure can easily be repeated.

Nevertheless, RFA of the kidney can be accompanied by minor and even major complications. Several investigators have postulated the occurrence of bowel perforation as a complication of RFA of renal masses due to the close proximity of bowel [13, 14]. To our current knowledge, only two articles have described such a case [15, 16]. Yet in a large series of 100 percutaneously performed renal RFAs, none of the patients had colonic injuries [8]. The reported incidence of bowel perforation complicating renal RFA therefore ranges from 0 to 8.3% [8, 15]. In this article, we describe the first case of appendiceal perforation as a complication of CT-guided percutaneous RFA of an SMR.

Case Report

Patient

A 60-year-old male patient was referred to our outpatient clinic with an incidental mass in the right kidney, which was recently diagnosed during work-up of his microscopic hematuria. His previous medical history consisted of kidney stone lithotripsy, hypertension treated with a beta-blocker and diuretic, and two episodes of transient ischemic attack.

Abdominal CT scan showed a rapidly enhancing, exophytic mass in the lower pole of the right kidney with a maximum diameter of 2.5 cm (Fig. 1A), which was radiologically suspect for RCC. The appendix was noticed in a retrocecal position, at a 1.4-cm distance from the renal mass (Fig. 1B, C). Based on his mild comorbidity and on the small size of the renal mass, minimally invasive CT-guided radiofrequency ablation of the renal mass was performed.

Procedure

Our technique of RFA in renal masses has extensively been described in previous articles [17, 18]. In short, after the patient received an antibiotic prophylaxis (1,500 mg cefuroxime) and epidural analgesic before the RFA procedure, he was placed in prone position on the CT table. A planning CT scan was performed to locate the renal mass. Under fluoroscopic CT guidance, a 17G cool-tip electrode (Valleylab, Covidien, Boulder, CO) was placed centrally into the mass. Subsequently a 20G needle was inserted lateral in the anterior pararenal space for injection of dextrose in water to hydrodissect the renal mass from the surrounding vital tissues, such as the colon and appendix. After the hydrodissection and the positions of the needles were checked with a CT scan of the area of interest, ablation was started. Final temperature after 15 min was $>75^{\circ}\text{C}$ with adequate roll-offs. The expected ablation zone was 3 cm. The electrode was removed under constant

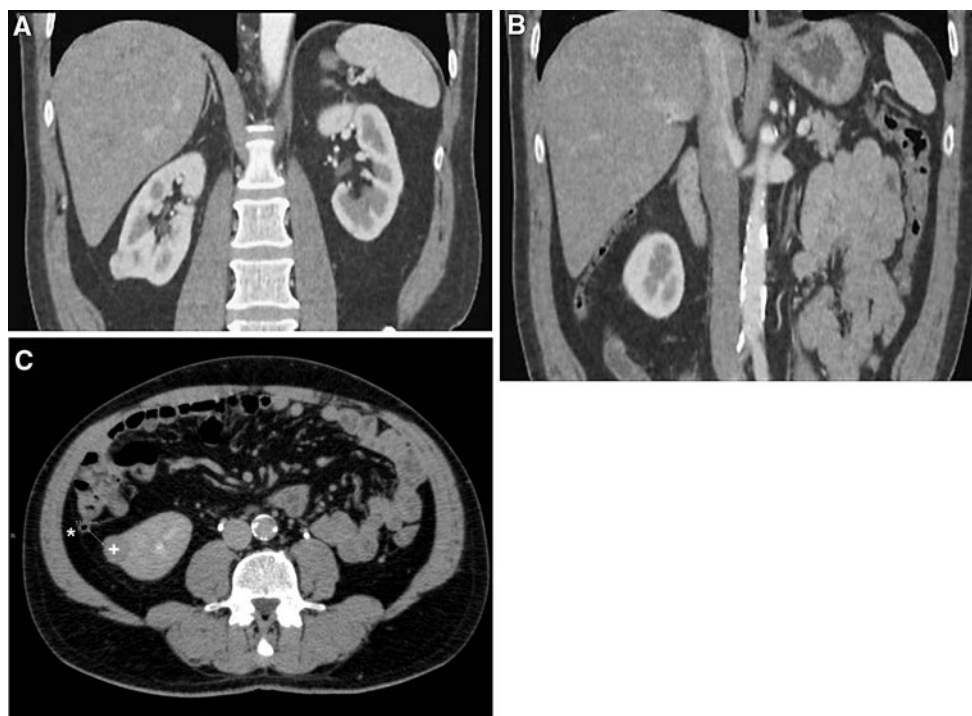

Fig. 1 **A** Small, exophytic, rapidly enhancing renal mass at the lower pole of the right kidney. **B** Retrocecal position of the appendix on the lateral site of the right kidney in the vicinity of the renal mass (**C**). *Appendix, +Renal mass

ablation to avoid any tumor spill. The RFA procedure was performed by a highly experienced interventional radiologist (W.P.) who at that time had already performed >180 percutaneous image-guided ablative procedures (including renal, liver, and lung).

Results

On the CT images performed during the procedure, the colon and appendix were considered to be a safe distance (at least 1.0 cm) from the ablative field as a result of the hydrodissection (Fig. 2). Adequate ablation of the kidney tumor was achieved without intraprocedural complications. On the first postprocedural day, the patient was discharged to home in good clinical condition.

Five days after the procedure, he presented at our hospital with fever (39.5°C) and right lumbar pain. Abdominal CT scan performed after preparation with oral contrast (Fig. 3) showed a large retroperitoneal fluid collection with air configurations, suggesting retroperitoneal abscess formation, on the lateral side of the right kidney. Moreover, a direct connection was noticed between the cecum and fluid collection, with contrast material in the retroperitoneal abscess, suggesting perforation at the base of the appendix (Fig. 3). After CT-guided drainage of the abscess and intravenous antibiotic therapy, the patient remained septic. Therefore, 2 days later laparotomy was performed. Intraoperatively, a retroperitoneally confined abscess was

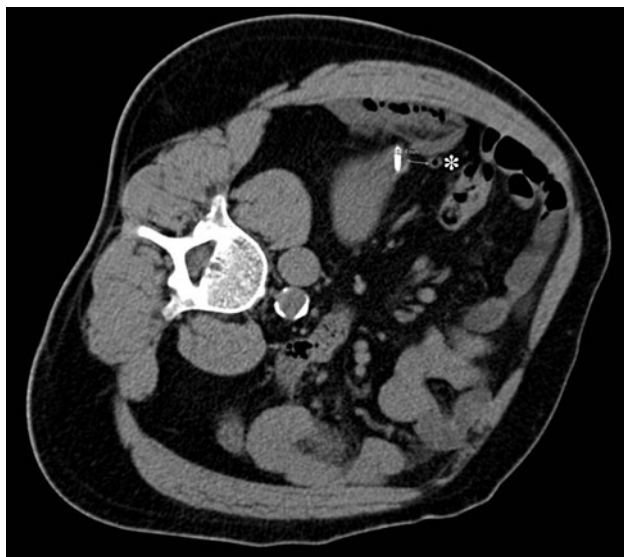


Fig. 2 Patient in left lateral decubitus position during RFA procedure. RFA electrode in the SMR. Fluid collection with air configuration on the lateral and anterior side of the renal mass as a result of hydrodissection can be seen. Retrocecal appendix (*) is in the vicinity of the ablative field

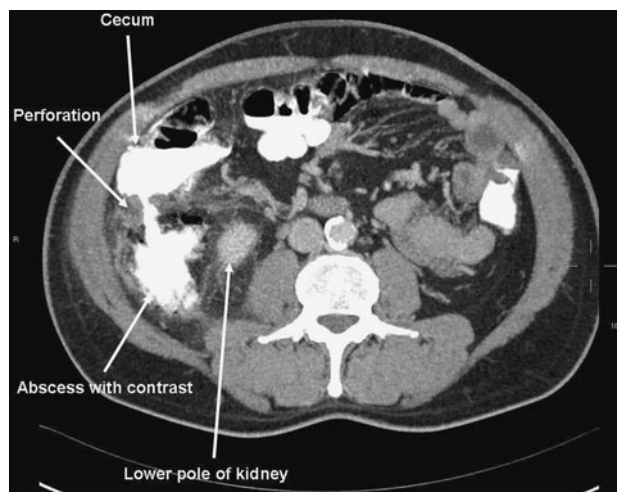


Fig. 3 Leakage of contrast material from the perforated cecum/appendiceal base into the right anterior pararenal space suggesting appendiceal perforation. Presence of air configurations in the right anterior pararenal space suggesting abscess formation

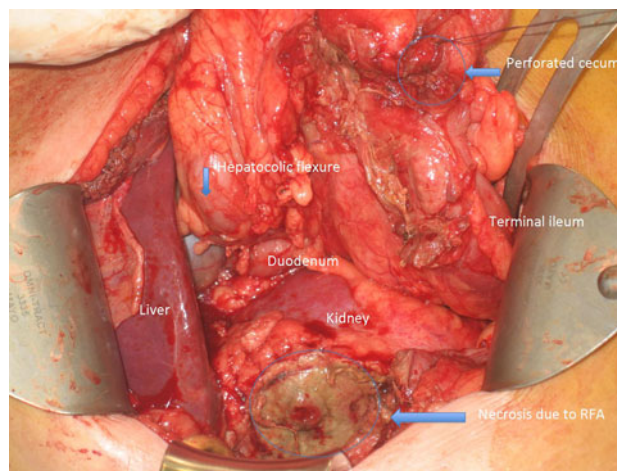


Fig. 4 Intraoperative view after abscess drainage. Necrosis at the lateral side of the right kidney after RFA. Oversewn cecal perforation at the base of the necrotic appendix

drained. However, due to an extensive local inflammatory reaction affecting the terminal ileum (Fig. 4), the approach had to be extended intra-abdominally to allow necessary resection of the ileocecal region followed by primary anastomosis between the ileum and ascending colon and an omental plasty. During this step, no putrid material was found intra-abdominally. Histopathologic examination of the resected specimen showed a perforated appendix based on ulcero-phlegmonous and gangrenous inflammation. On day 18 after the RFA, the patient was discharged to home in good condition.

Discussion

RFA of SRM was first applied in 1997 and has proven to be a promising and safe technique since [19]. In a large series of 100 patients with renal tumors treated with RFA, 11 minor and major complications were reported, of which the most common was haemorrhage [8]. The current article is the first describing retroperitoneal appendiceal perforation as a complication of RFA.

Complications of RFA can generally be divided into two categories: (1) those related to imaging-guided electrode placement and (2) those related to thermal therapy [13]. The latter are more common in kidney RFA compared with other RFA indications, e.g., hepatic RFA, as a result of the proximity of other vital structures, such as the bowel and ureter [14]. Nevertheless, only two articles so far have reported bowel perforation as a complication of renal RFA [15, 16]. This is the first case of appendiceal perforation occurring after (renal) RFA.

Thermal complications of RFA can be prevented non-invasively and invasively [13]. The first step in preventing thermal complications is thorough assessment of the tumor location on preprocedural CT scans during the process of patient selection. A second example is proper patient positioning. Percutaneous renal RFA can be performed with the patient prone or in lateral decubitus position. In both positions, vital structures in the vicinity of the target mass will be kept away from the ablative zone by way of gravity [14]. Third, the RFA electrodes can be used to lift the ablated tumor away from vital structures [20].

Examples of invasive methods include hydrodissection with glucose in water or injection of carbon dioxide in between the target tissue and the tissue that needs protection [21]. In our patient, a lateral dissection was performed with glucose in water to dissect the renal mass from the appendix and the colon, which was located caudolateral with respect to the renal mass. Unfortunately, in this way the appendix came even closer to the tract of the needle. Nevertheless, on the CT images performed during the procedure, the appendix was considered to be at sufficient distance from the ablative field. Eventually, this caused the appendiceal perforation.

Since this complication, we modified our ablative technique. Currently we start the hydrodissection before placement of the RFA electrode in the target tissue. In addition, instead of injecting 100 cm³ fluid during hydrodissection, we attach the needle to a continuous drip system.

Conclusion

In conclusion, in this article we described a case of appendiceal perforation leading to retroperitoneal abscess

formation as a complication of percutaneous RFA of an SRM. Although RFA of SRM is generally a minimally invasive and safe procedure, one should be aware of the possibility of particular minor and major complications when performing this innovative and promising procedure. If vital structures remain in close vicinity of the ablative field, one should consider treatment options other than RFA.

Conflict of interest All authors declare no conflict of interest.

Open Access This article is distributed under the terms of the Creative Commons Attribution Noncommercial License which permits any noncommercial use, distribution, and reproduction in any medium, provided the original author(s) and source are credited.

References

- Jayson M, Sanders H (1985) Increased incidence of serendipitously discovered renal cell carcinoma. *Urology* 51(2):203–205
- Lam JS, Shvarts O, Pantuck AJ (2004) Changing concepts in the surgical management of renal cell carcinoma. *Eur Urol* 45(6):692–705
- Van Poppel H et al (2011) A prospective, randomised EORTC intergroup phase 3 study comparing the oncologic outcome of elective nephron-sparing surgery and radical nephrectomy for low-stage renal cell carcinoma. *Eur Urol* 59(4):543–552
- Russo P (2008) Functional preservation in patients with renal cortical tumors: the rationale for partial nephrectomy. *Curr Urol Rep* 9(1):15–21
- Huang WC et al (2006) Chronic kidney disease after nephrectomy in patients with renal cortical tumours: a retrospective cohort study. *Lancet Oncol* 7(9):735–740
- Campbell SC et al (2009) Guideline for management of the clinical T1 renal mass. *J Urol* 182(4):1271–1279
- Choueiri TK et al (2011) Thermal ablation vs surgery for localized kidney cancer: a Surveillance, Epidemiology, and End Results (SEER) Database Analysis. *Urology* 78(1):93–98
- Gervais DA, McGovern FJ, Arellano RS, McDougal WS, Mueller PR (2005) Radiofrequency ablation of renal cell carcinoma: Part 1, indications, results, and role in patient management over a 6-year period and ablation of 100 tumors. *Am J Roentgenol* 185(1):64–71
- Feng B, Liang P (2011) Local thermal ablation of renal cell carcinoma. *Eur J Radiol*. doi:10.1016/j.ejrad.2010.12.056
- Hui GC, Tuncali K, Tatli S, Morrison PR, Silverman SG (2008) Comparison of percutaneous and surgical approaches to renal tumor ablation: metaanalysis of effectiveness and complication rates. *J Vasc Interv Radiol* 19(9):1311–1320
- Ahmed M, Brace CL, Lee FT Jr, Goldberg SN (2011) Principles of and advances in percutaneous ablation. *Radiology* 258(2):351–369
- Kunkle DA, Uzzo RG (2008) Cryoablation or radiofrequency ablation of the small renal mass: a meta-analysis. *Cancer* 113(10):2671–2680
- Rhim H et al (2004) Radiofrequency thermal ablation of abdominal tumors: lessons learned from complications. *Radiographics* 24(1):41–52
- Park BK, Kim CK (2009) Complications of image-guided radiofrequency ablation of renal cell carcinoma: causes, imaging features and prevention methods. *Eur Radiol* 19(9):2180–2190

15. Weizer AZ, Raj GV, O'Connell M, Robertson CN, Nelson RC, Polascik TJ (2005) Complications after percutaneous radiofrequency ablation of renal tumors. *Urology* 66(6):1176–1180
16. Igor PG, Raman JD (2010) Management and prevention of renal ablative therapy complications. *World J Urol* 28(5):559–564
17. Prevo W, van den Bosch MA, Horenblas S (2008) Radiofrequency ablation for treatment of sporadic angiomyolipoma. *Urology* 72(1):188–191
18. Prevo W, van den Munckhof MP, Meinhardt W, Horenblas S, van den Bosch MA (2010) Radiofrequency ablation of kidney tumours in patients with a solitary kidney. *Clin Radiol* 65(3): 230–236
19. Zlotta AR et al (1997) Radiofrequency interstitial tumor ablation (RITA) is a possible new modality for treatment of renal cancer: ex vivo and in vivo experience. *J Endourol* 11(4):251–258
20. Park BK, Kim CK (2008) Using an electrode as a lever to increase the distance between renal cell carcinoma and bowel during CT-guided radiofrequency ablation. *Eur Radiol* 18(4):743–746
21. Ginat DT, Saad W, Davies M, Walman D, Erturk E (2009) Bowel displacement for CT-guided tumor radiofrequency ablation: techniques and anatomic considerations. *J Endourol* 23(8): 1259–1264