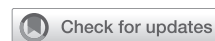

Three-dimensional printing to plan intracardiac operations



Matthew C. Henn, MD, and Nahush A. Mokadam, MD

As cardiac surgery continues to rapidly evolve to more technology-based, minimally invasive approaches, it is imperative that we as a profession seek to use and employ every tool at our disposal to achieve the best possible results. One of the most exciting tools that has evolved in medicine over the past 2 decades is 3-dimensional (3D) printing—the process in which a digital dataset is transformed and printed into physical models. The technology to enable the first 3D printer called sterolithography was invented in 1983 by inventor Charles Hull. He then made the first 3D printer called the SLA-1 in 1986, and he patented and commercialized it in 1988 (Figure 1).^{1,2} As the technology has been refined and different techniques developed, there are now commercially available printers that can produce life-sized 3D models using a variety of materials, ranging from pliable nylon, rubber, or plastic to steel capable of incorporating even the finest details. Such capabilities have broadened its applications both in the community and in medicine—and have expanded the potential utility in cardiac surgery.

The use of this transformative technology in medicine is a relatively new phenomenon, with a recent review finding only 2 reports before 2000.³ Use within cardiology and cardiac surgery is similarly a new, with the majority of experience in the literature having been published within the past decade.^{4,5} The ability to create patient-specific 3D heart models that reliably replicate real-life structures and anatomical relationships creates unique opportunities for training, operative planning, and treatment approaches. In this review, we discuss the techniques of 3D printing that are relevant to cardiac surgery and exciting applications of 3D printing as they relate to procedural-specific intracardiac surgery.

TECHNIQUE OF 3D PRINTING

The technique of medical 3D printing generally follows a series of steps that takes roughly 1 to 2 weeks to complete depending on the specific methods and materials used for processing and printing. The actual steps involved are comprehensively outlined by an excellent review by

From the Division of Cardiac Surgery, The Ohio State University Wexner Medical Center, Columbus, Ohio.


Received for publication Feb 7, 2021; accepted for publication Feb 11, 2021; available ahead of print April 20, 2021.

Address for reprints: Nahush A. Mokadam, MD, Division of Cardiac Surgery, The Ohio State University Wexner Medical Center, 410 W. 10th Ave, N-825 Doan Hall, Columbus, OH 43210 (E-mail: Nahush.Mokadam@osumc.edu).

JTCVS Techniques 2021;9:101-8
2666-2507

Copyright © 2021 The Author(s). Published by Elsevier Inc. on behalf of The American Association for Thoracic Surgery. This is an open access article under the CC BY-NC-ND license (<http://creativecommons.org/licenses/by-nc-nd/4.0/>).

<https://doi.org/10.1016/j.xjtc.2021.02.050>



Matthew C. Henn, MD, and Nahush A. Mokadam, MD

CENTRAL MESSAGE

The use of 3D printing in medicine is rapidly expanding. While there is limited experience in cardiac surgery, this technology is promising both in training and planning for intracardiac operations.

See Commentary on page 109.

Vukicevic and colleagues,⁵ and an excellent brief overview can be found in Figure 2.⁵

All methods of 3D printing begin with acquisition of a high-resolution 3D imaging dataset from the patient—usually in the form of a computed tomography (CT) scan or magnetic resonance imaging (MRI).⁵ The majority of previous work involving 3D modeling of the heart has relied on CT and MRI because of their ability to provide volumetric data with good blood pool to myocardium contrast. CT is routinely obtained for preoperative planning in cardiac surgery and has further advantages of allowing identification of calcium deposition with a high degree of accuracy. While both CT and MRI images are classically used for 3D-printing datasets, 3D echocardiography has recently been explored as potential data source for 3D printing.^{1,6}

The potential advantages of portability, no ionizing radiation, and its relative low cost make 3D echo theoretically ideal for 3D modeling dataset. However, artifact resulting in data loss, lack of defined postprocessing standardization, and lack of reproducibility have limited its use.¹ Further, the process of printing the 3D model again renders a static image that also does not account for the cardiac cycle, and its use has been limited to experimental data in congenital heart disease.⁶

Once a 3D dataset has been obtained via CT scan or MRI, the next step is a complex process called segmentation,



FIGURE 1. Original 3D printer. The first commercialized 3D printer—the SLA-1 in 1988. Reprinted with permission from 3D Systems Corp, Rock Hill, SC; available at <https://www.3dsystems.com/our-story>.

where the dataset is converted to 3D patient-specific digital model of the target anatomy. The details are beyond the scope of this review, but in general, the target anatomy is organized by the pixel intensity of the grayscale 2D image. These are arranged into so-called segmentation masks (Figure 2, step 2) in which pixels of the same intensity are grouped. These are then integrated into 3D digital models with the help of computer-aided design software, which are then converted into a format recognized by the 3D printer called Surface Tessellation Language, or stereolithography, file formats.^{4,5} The last step is the physical printing of the patient-specific model with the capability to use multiple materials (Figure 2, step 5).

There are a variety of different 3D-printing methods that have evolved since the initial 3D printers were commercialized. There are 3 different categories of technology that have been developed: photopolymers, thermoplastics, and powder fusion (Figure 3).⁴ The first 3D printers designed by Charles Hull used photopolymers, which use light to harden deposited layers of photopolymer. Thermoplastics is a technique in which a filament of thermoplastic material is delivered into a heated printer head that melts the material and extrudes it through a small opening. The material resolidifies upon cooling, allowing for deposition of layers. The last technique is largest and most varied technique, called

powder fusion, in which very fine particulates of material are selectively fused by adhesives or lasers and deposited into thin layers within a print bed.⁷

The early 3D printers were initially cost-prohibitive, with expensive materials and the cost of the printers themselves soaring to more than \$100,000. However, with the expansion of 3D-printing techniques, there are currently more than 100 different printers across all categories of 3D-printing technologies that can be purchased commercially for less than \$5000. This competition has not only driven the cost down but has also led to continued improvement in the quality of 3D printers over time—now capable of printing with resolution on the order of micrometers.⁷

3D-PRINTING APPLICATIONS IN CARDIAC SURGERY

Available 3D-printing techniques and materials have allowed a diversity of printing models from rigid, multicolor models to flexible models that can be cut and sewn (Figure 4).⁴ This has expanded potential cardiac surgery applications that include simply better visualization of the anatomy for surgical planning, practicing and/or testing trainees on the technique of a particular procedure, and patient and caregiver counseling.

PATIENT AND FAMILY EDUCATION

An important application of 3D printing is its use in patient and family education. While this application is less reported in the literature, its use can supplement communication between practitioners and patients and their families and potentially help them understand disease processes and conceptualize intended repair. While most descriptions of its use are anecdotal, Biglino and colleagues⁸ reported on its use in more than 100 congenital patients. Both practitioners and patient families reported 3D models were very useful in facilitating discussion, but the authors were unable to demonstrate an improvement in parental knowledge following the visit.

Another group used 3D models during family discussions with 11 families before congenital heart intervention.⁴ These caregivers completed surveys following their visit and all families reported that the models were “very helpful” (5 out of 5) in improving understanding of the anatomy. While these studies are hampered by the lack of objectivity and lack of a control group, the subject warrants further investigation into the potential benefits of 3D models in educating patients and their families.

TRAINING

Another promising application of this technology is in cardiac surgical training, particularly for specialized intracardiac procedures such as septal myectomies. A septal myectomy is a procedure with complex 3D intracardiac anatomy with a very small margin for error. The access to

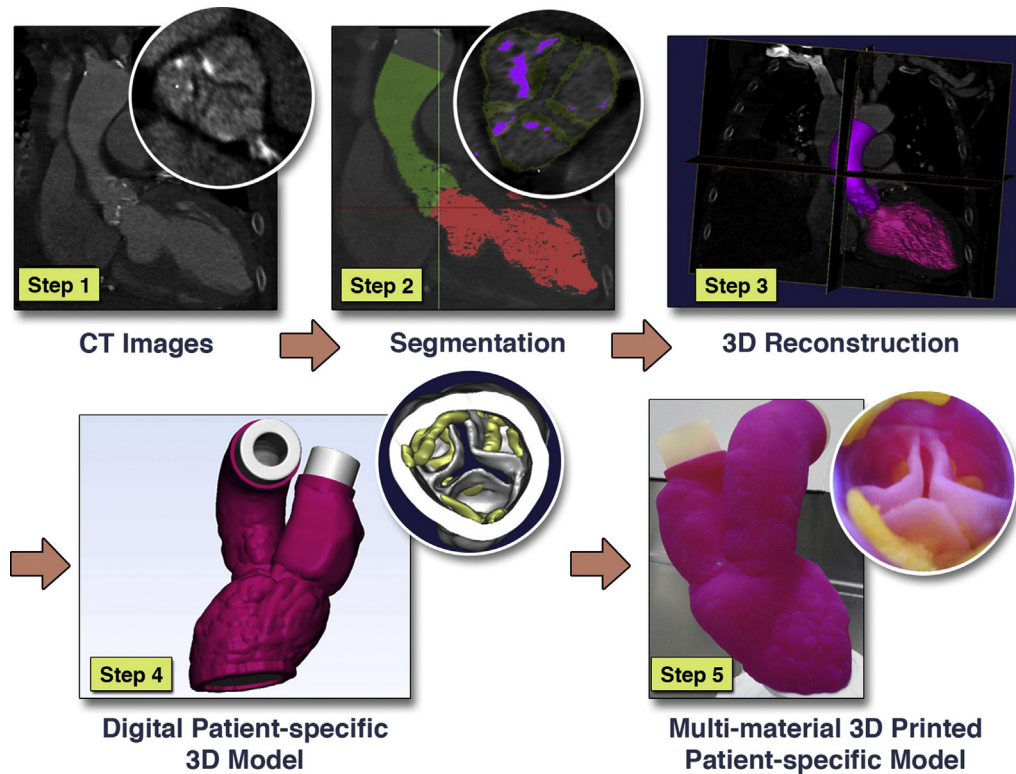


FIGURE 2. 3D-printing technique. Step 1: Data acquisition via CT. Step 2: Segmentation processing of anatomy. Step 3: 3D reconstruction. Step 4: Adjusted digital 3D patient-specific model. Step 5: 3D-printed patient-specific model. *CT*, Computed tomography; *3D*, three-dimensional. Reprinted with permission from Vukicevic and colleagues.⁵

perform a septal myectomy, usually through the aortic valve, provides limited visualization to anyone other than the primary operator, making it very difficult to teach. Further, achieving optimal results cannot be expected

with a low-volume exposure to this procedure.⁹ For these reasons, the septal myectomy is the ideal procedure to use 3D, patient-specific models for trainees and surgeons to get through their learning curve in a safe, low-risk setting.

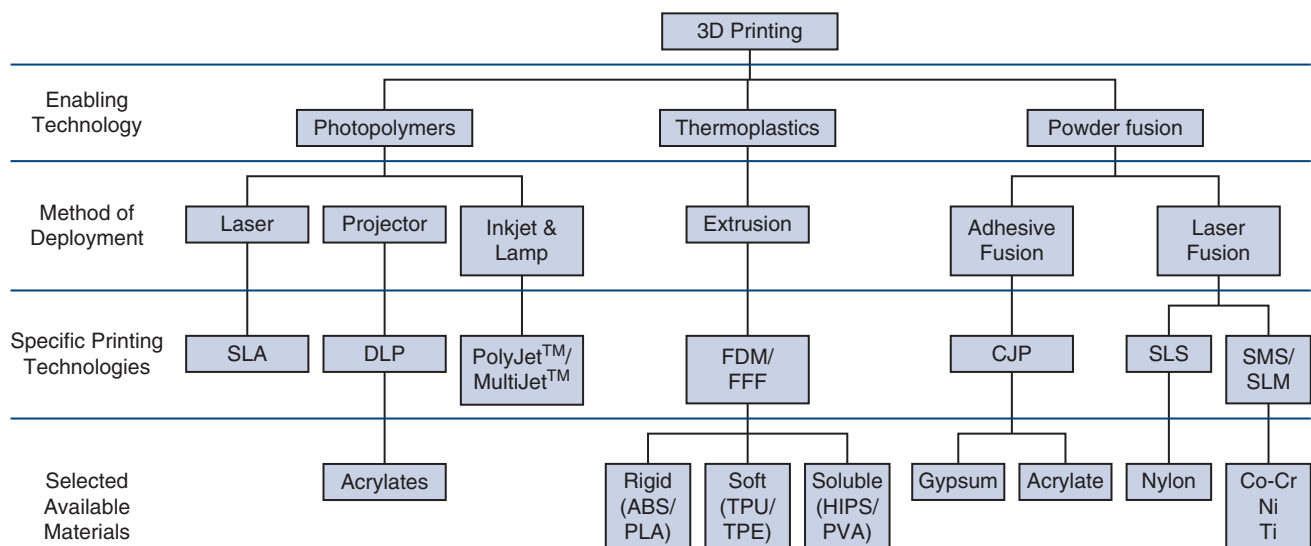


FIGURE 3. 3D-printing technologies. *3D*, Three-dimensional; *SLA*, stereolithography apparatus; *DLP*, direct light processing; *FDM*, fused deposition modeling; *FFF*, fused filament fabrication; *CJP*, color jet printing; *SLS*, selective laser sintering; *SMS*, SMS Group, Pittsburg, PA; *SLM*, selective laser melting; *ABS*, acrylonitrile butadiene styrene; *PLA*, polylactic acid; *TPU*, thermoplastic urethane; *TPE*, thermoplastic elastomer; *HIPS*, high-impact polystyrene; *PVA*, polyvinyl alcohol; *Co*, cobalt; *Cr*, chromium; *Ni*, nickel; *Ti*, titanium. Reprinted with permission from Anwar and colleagues.⁴

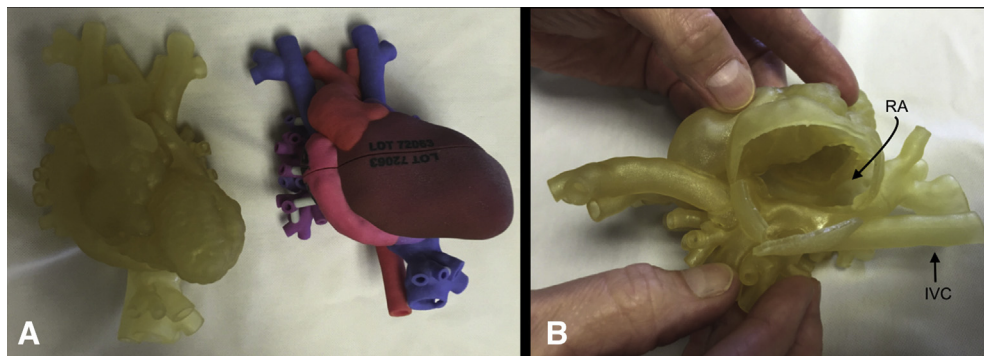


FIGURE 4. Diversity of model material. A, Flexible model on left compared with rigid, color-coded model on right. B, Surgeon view of the right atrium using a flexible model that can hold suture. RA, Right atrium; IVC, inferior vena cava. Reprinted with permission from Anwar and colleagues.⁴

In one study by Hermsen and colleagues,^{10,11} a model of hypertrophic cardiomyopathy was developed and validated. Two patients with hypertrophic cardiomyopathy were scheduled for septal myectomy, and before surgery, the operating surgeon performed a myectomy on a 3D model of each patient in a simulated operative experience.¹¹ Taking it a step further, they developed a training exercise where a curriculum was developed for the trainees and simulated septal myectomy specimens were compared among attending surgeons and trainees. The residents were able to achieve significant objective and subjective improvement of the technique over the course of several 3D models and were able to achieve myectomies comparable to those of the attending surgeons (Figure 4).¹⁰

This particular form of training where the resident is able to directly compare their results with those of attending surgeons on identical 3D models of a real patient is one of the more promising applications of 3D printing. Particularly in a complex intracardiac procedure such as a septal myectomy in which the margin for error is extremely small 3D models allow for deliberate, patient-specific practice with the ability to immediately assess the adequacy of the resident's performance.

Other applications of 3D printing for surgical technical training are limited to case reports in the literature, the majority of which are centered around congenital heart surgery.¹² However, in one elegant study Yoo and colleagues¹³ used flexible printed 3D models of several congenital heart conditions to conduct hands-on surgical training (Figure 5). In the study, 81 surgeons or trainees performed the simulated surgical procedures (Figure 6),¹⁰ and all respondents found the course helpful for their surgical skills. Further, all responders found that the models showed the necessary pathological findings, but the weaknesses were related to the lack of realism of the material of the printed models.

OPERATIVE PLANNING

Despite the promising application of 3D models for the training for septal myectomy in adult cardiac surgery, few

other groups have reported its use, and they have mainly focused on operative planning.¹⁴⁻¹⁸ The ability to visualize patient-specific 3D anatomy in a low-risk environment with no time limit is a very appealing application of this technology. There have been a variety of different procedures for which surgeons have explored 3D printing for operative planning, including septal myectomy, mitral valve interventions, transcatheter aortic valve replacement (TAVR), ventricular assist device placement, and complex congenital repairs.

Transcatheter Aortic Valve Replacement

In TAVR, preprocedural planning is of critical importance. Small details such as the shape and dimensions of the aortic annulus and aortic root, locations of coronary ostia, and distribution of calcium deposits on the left ventricular outflow, aortic valve leaflets and annulus, and the ascending aorta can lead to modifications of both the procedural plan and surgical approach. Several groups have explored the use of 3D printing for TAVR, but the majority of experience lies in retrospective evaluations and benchtop experimental models exploring paravalvular leak.¹⁹⁻²³

With already-excellent preoperative imaging techniques including virtual 3D reconstructions, the most routine TAVR procedures are unlikely to benefit from 3D printing. However, complex procedures such as valve-in-valve procedures may benefit from 3D printing for procedural planning and execution. While the literature is limited to case reports, the use of 3D printing in these scenarios may aid in predicting catastrophes such as coronary occlusion while also helping with preventative planning.²⁴⁻²⁶ While we have used 3D printing at our institution to simulate conditions after TAVR valve positioning,²⁷ we have not routinely used models for operative planning. More often, we have used 3D computer models with simulated implants for complex cases at high risk for coronary occlusion or paravalvular leak. Using these computer-based simulation models have altered our procedural plans based on numerous occasions.

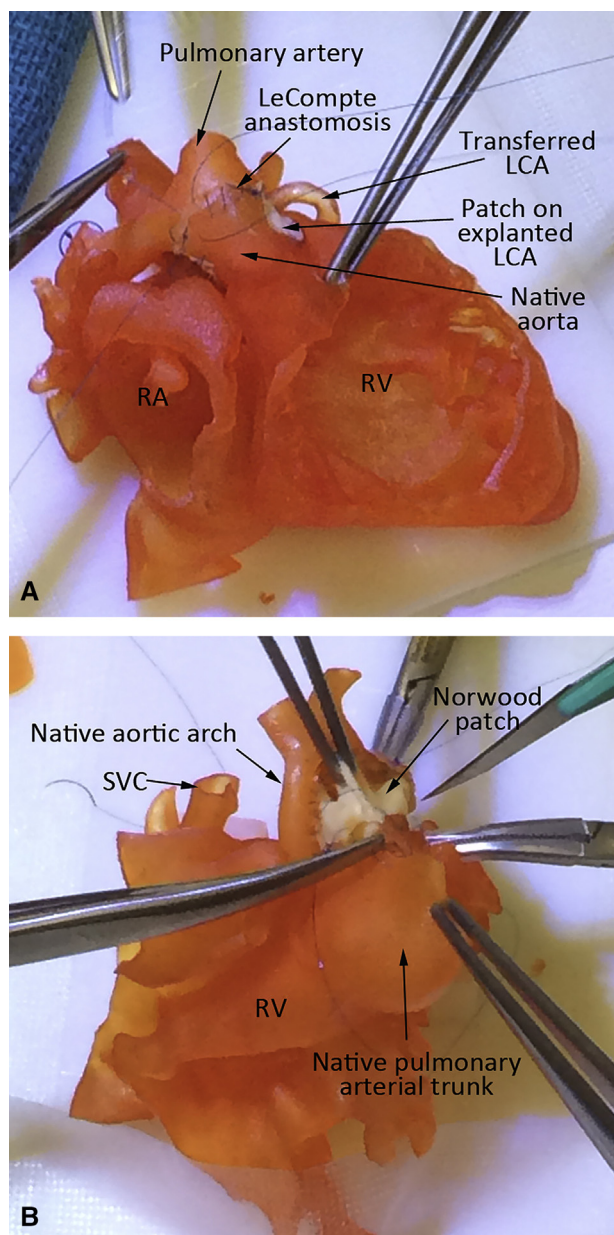


FIGURE 5. Congenital surgical training using 3D models. A, Arterial switch procedure for complete transposition of the great arteries. B, Norwood operation for hypoplastic left heart syndrome. *LCA*, Left coronary artery; *RA*, right atrium; *RV*, right ventricle; *SVC*, superior vena cava. Re-printed with permission from Yoo and colleagues.¹³

Ventricular Assist Devices

Positioning of the inflow cannula is of critical importance when implanting a ventricular assist device. There have been a few case reports of 3D printing facilitating operative planning for device implantation.^{12,28,29} The majority of applications in this setting are for adult patients with complex

anatomy, such as congenital heart disease patients or complex redo patients (Figure 7).^{12,29} In these cases, a patient-specific 3D model is printed and then opened to simulate the position of the inflow cannula prior to the operation. With the population of adults with congenital heart disease set to increase over time, 3D printing could prove to be a valuable tool when considering advanced heart failure therapies in these patients.

Congenital Heart Surgery

The most consistent and robust use of 3D printing to both train and plan intracardiac operations comes from congenital heart surgery. This population encompasses a wide range of pathology with very complex, patient-specific anatomy with often very small margin for error. These characteristics make this population ideally positioned to maximize the potential of 3D printing.

In congenital heart surgery, early decision-making with regard to treatment of a variety of congenital malformations centers on the ability to create a durable biventricular repair. When anatomy is too complex or difficult for a biventricular repair, patients are initiated down a path of single-ventricle palliation. When one makes these difficult decisions, slight anatomical details that are varied within the same diagnostic group can alter the decision. Several groups have explored the use of 3D printing to help make these complex decisions as well as assist with the repair.

Hoashi and colleagues³⁰ used 20 patient-specific 3D models to review anatomy and plan either biventricular or single ventricular repairs for patients with a functional single ventricle. All operations were performed by a young consulting surgeon who had no experience with complex biventricular repair or neonatal open heart. Before each procedure, the operating surgeon was able to dissect the 3D model and plan the operation prior to being in the operating room. They were able to achieve biventricular repair in all but 4 patients with no operative or in-hospital mortalities.³⁰

While it is common to report the subjective benefit of the use of preoperative 3D models prior to congenital heart surgery, there is limited evidence that 3D printing affects surgical strategy. Perhaps the best effort in the literature to show the merits of 3D printing in congenital surgery comes from Yang and colleagues.³¹ They identified 40 patients in whom the surgical plan was undecided after a multidisciplinary meeting, and those patients underwent 3D printing. Before printing, the patient's surgical plans were stratified into 4 categories: corrective, equivocally corrective, equivocally palliative, or palliative. After printing, the cases were re-reviewed and 27 cases had their strategies modified to a more confident category, 23 of which went from equivocally corrective to corrective. In 5 of these cases, surgical plans were completely changed from a palliative strategy

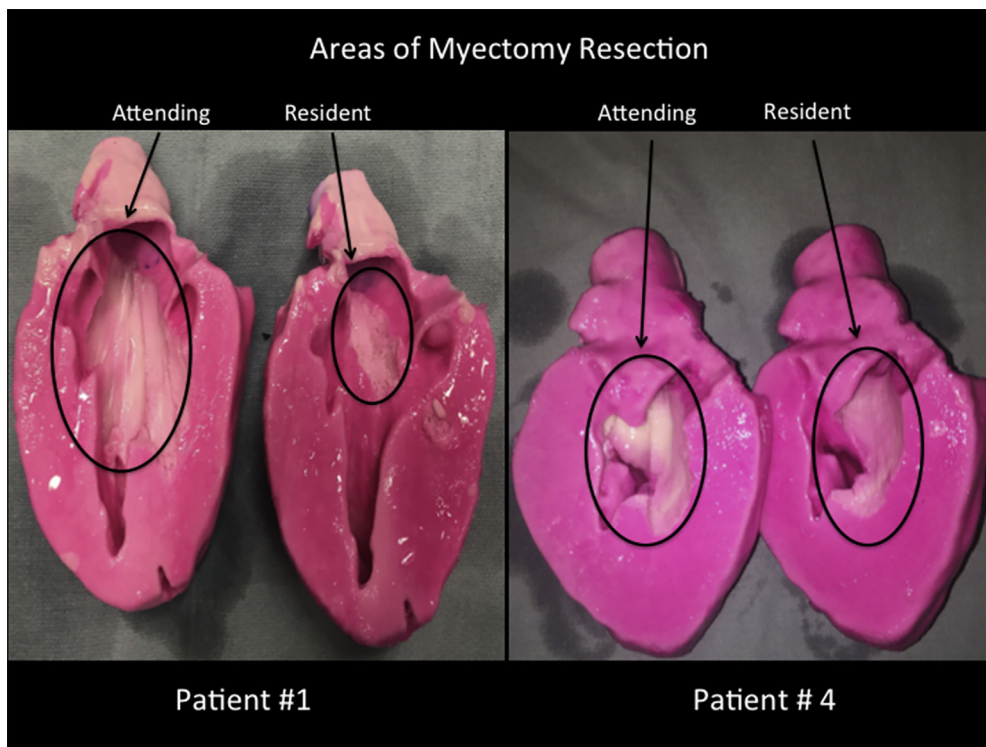


FIGURE 6. Images of 3D-printed models after simulated septal myectomy by attending surgeons and resident trainees. Reprinted with permission from Hermesen and colleagues.¹⁰

to a corrective strategy (Figure 8).³¹ This is the first evidence that 3D printing has an effect on surgical strategy.³¹

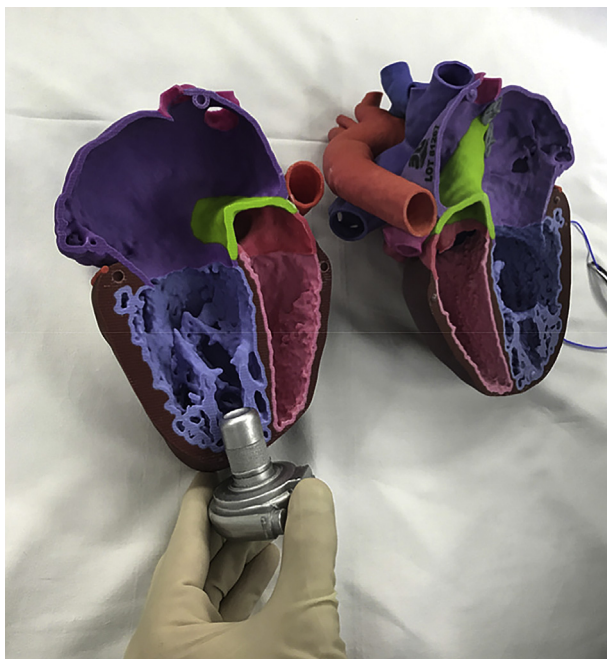

FIGURE 7. Simulating the position of the ventricular assist device inflow cannula using a 3D-printed model of a patient with a systemic right ventricle. Reprinted with permission from Miller and colleagues.¹²

LIMITATIONS

The main limitations to this technology are the cost and time commitment. Depending on the printing strategy, a single model can cost between \$1000 and \$2000 and take >1 week to make, which does not include the separate upfront cost of segmentation software, medical-grade 3D printer, material costs, and personnel with 3D-printing expertise. Further, there is no literature evaluating 3D printing cost-effectiveness in cardiac surgery. This has mainly been limited by the lack of objective outcome measures. Another major limitation is the inability to print structures that are not well-delineated from the dataset (CT or MRI), such as atrioventricular valves. This perhaps can be overcome by the use of 3D echocardiography for datasets. Further, the models only capture one moment in the cardiac cycle, and the materials used to print the models are not ideal to mimic live tissue. This limitation is compounded by the inability to print with multiple materials to mimic heterogeneity of tissue types, although efforts are underway to produce more life-like models.⁴

LOOKING TO THE FUTURE

Over the past decade, the use of 3D printing has rapidly evolved with new technological advances in imaging acquisition, segmentation software, and printers. Current and future investigations are broad and include using elements

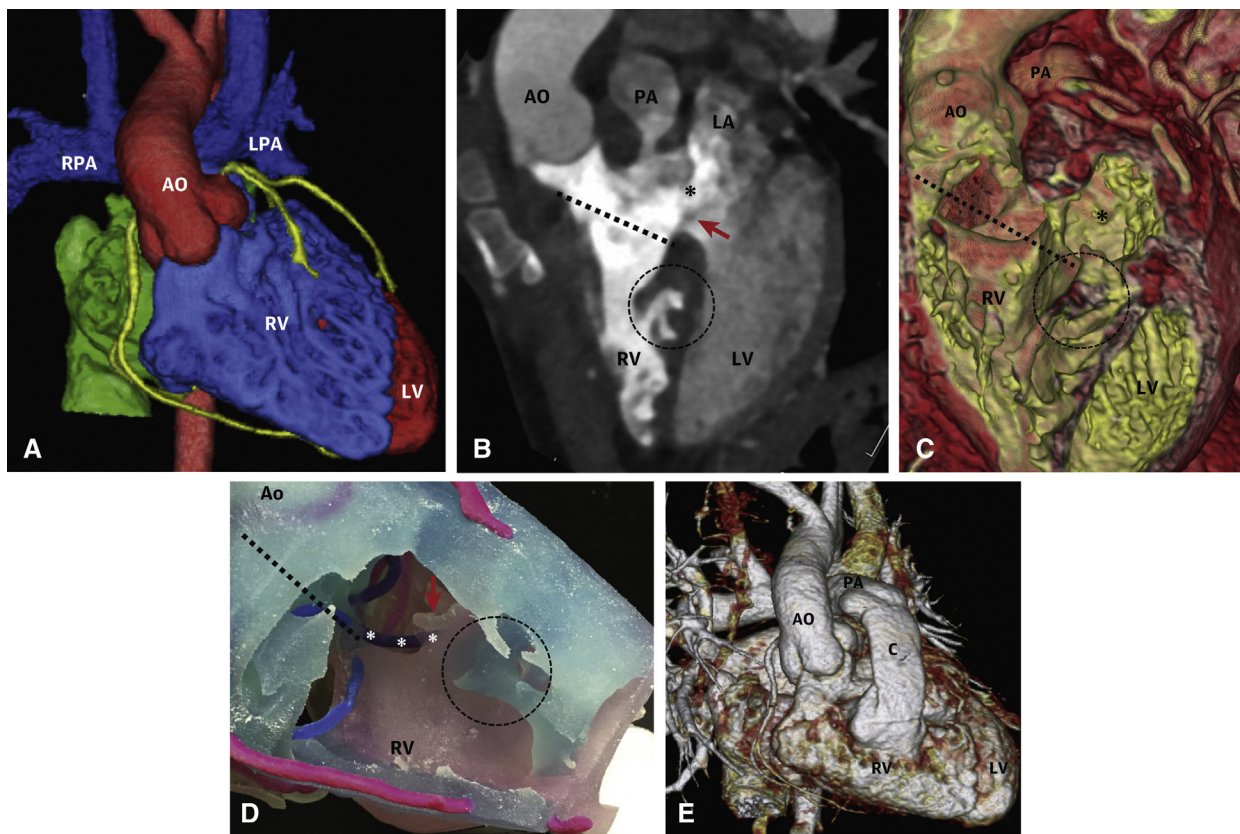


FIGURE 8. Double-outlet right ventricle in 35-month-old boy. A to C, Preoperative CT images showing double-outlet right ventricle with ventriculoseptal defect (asterisks) and straddling of the mitral valve (red arrow). The dotted line measures the distance between the ventriculoseptal defect and the aortic annulus, which before 3D modeling was deemed too difficult for biventricular repair and palliative strategy was planned. D, The 3D model demonstrating the suturing margin along the VSD (asterisks on a purple ring). Visualization of this margin and distance changed the approach to biventricular repair with VSD baffling. E, Postoperative CT shows successful VSD baffling and RV to PA conduit. RPA, Right pulmonary artery; LPA, left pulmonary artery; AO, aorta; PA, pulmonary artery; LA, left atrium; RV, right ventricle; LV, left ventricle. Reprinted with permission from Yang and colleagues.³¹

from multiple imaging modalities to create one 3D model,³² the ability to create 3D models of valve with the use of 3D echocardiography,³³ improvements in print materials to more closely mimic live tissue,⁴ 3D bioprinting of live tissue,³⁴ and dynamic 3D heart models.³⁵ New frontiers including implantable, patient-specific 3D devices such as conduits and valves, although not currently being studied, are clearly within reach. As this exciting technology improves and evolves, it is important for our field to continue to study its use and explore its potential applications. Further study into its cost-effectiveness of this technology is warranted.

CONCLUSIONS

Three-dimensional printing is a transformative technology that has the ability to augment how we image, plan, and execute intracardiac operations. The ultimate utility with this technology lies in the training and planning of high-risk, complex procedures that have no margin for error. As the technology improves and evolves, more data

needs to be accrued to confirm the potential benefits of 3D printing, but the limited experience with this technology in training and planning intracardiac operations is promising.

Conflict of Interest Statement

N.M. reported consultant and investigator for Abbott, Medtronic, and SynCardia, and a consultant for Carmat. M.H. reported no conflicts of interest.

The *Journal* policy requires editors and reviewers to disclose conflicts of interest and to decline handling or reviewing manuscripts for which they may have a conflict of interest. The editors and reviewers of this article have no conflicts of interest.

References

1. Farooqi KM, Sengupta PP. Echocardiography and three-dimensional printing: sound ideas to touch a heart. *J Am Soc Echocardiogr.* 2015;28:398-403.
2. Hull CW, Inventor; UVP, Inc, assignee. Apparatus for production of three-dimensional objects by stereolithography. US patent 4,575,330. 1986 Mar 11.

3. Tack P, Victor J, Gemmel P, Annemans L. 3D-printing techniques in a medical setting: a systematic literature review. *Biomed Eng Online*. 2016;15:115.
4. Anwar S, Singh GK, Miller J, Sharma M, Manning P, Billadello JJ, et al. 3D printing is a transformative technology in congenital heart disease. *JACC Basic Transl Sci*. 2018;3:294-312.
5. Vukicevic M, Mosadegh B, Min JK, Little SH. Cardiac 3D printing and its future directions. *JACC Cardiovasc Imaging*. 2017;10:171-84.
6. Olivieri LJ, Krieger A, Loke YH, Nath DS, Kim PC, Sable CA. Three-dimensional printing of intracardiac defects from three-dimensional echocardiographic images: feasibility and relative accuracy. *J Am Soc Echocardiogr*. 2015;28:392-7.
7. Borrello J, Backris P. Rapid prototyping technologies. In: Farooqi KM, ed. *Rapid Prototyping in Cardiac Disease*. Cham, Switzerland: Springer; 2017:41-9.
8. Biglino G, Capelli C, Wray J, Schievano S, Leaver LK, Khambadkone S, et al. 3D-manufactured patient-specific models of congenital heart defects for communication in clinical practice: feasibility and acceptability. *BMJ Open*. 2015;5:e007165.
9. Maron BJ, Dearani JA, Maron MS, Ommen SR, Rastegar H, Nishimura RA, et al. Why we need more septal myectomy surgeons: an emerging recognition. *J Thorac Cardiovasc Surg*. 2017;154:1681-5.
10. Hermsen JL, Yang R, Burke TM, Dardas T, Jacobs LM, Verrier ED, et al. Development of a 3-D printing-based cardiac surgical simulation curriculum to teach septal myectomy. *J Thorac Cardiovasc Surg*. 2018;156:1139-48.e1133.
11. Hermsen JL, Burke TM, Seslar SP, Owens DS, Ripley BA, Mokadam NA, et al. Scan, plan, print, practice, perform: development and use of a patient-specific 3-dimensional printed model in adult cardiac surgery. *J Thorac Cardiovasc Surg*. 2017;153:132-40.
12. Miller JR, Singh GK, Woodard PK, Eghtesady P, Anwar S. 3D printing for pre-operative planning and surgical simulation of ventricular assist device implantation in a failing systemic right ventricle. *J Cardiovasc Comput Tomogr*. 2020;14:e172-4.
13. Yoo SJ, Spray T, Austin EH III, Yun TJ, van Arsdell GS. Hands-on surgical training of congenital heart surgery using 3-dimensional print models. *J Thorac Cardiovasc Surg*. 2017;153:1530-40.
14. Hamatani Y, Amaki M, Kanzaki H, Yamashita K, Nakashima Y, Shibata A, et al. Contrast-enhanced computed tomography with myocardial three-dimensional printing can guide treatment in symptomatic hypertrophic obstructive cardiomyopathy. *ESC Heart Fail*. 2017;4:665-9.
15. Ma J, Liu J, Yuan H, Tang Y, Qiu H, Zhuang J, et al. Two-port thoracoscopic myectomy for hypertrophic cardiomyopathy with three-dimensional printing. *Ann Thorac Surg*. 2021;111:e165-8.
16. Veselka J, Adla T, Adlova R, Bartel T. Three-dimensional heart printing for planning of septal reduction therapy in patients with hypertrophic obstructive cardiomyopathy. *Int J Angiol*. 2018;27:165-6.
17. Andrushchuk U, Adzintsov V, Nevygla A, Model H. Virtual and real septal myectomy using 3-dimensional printed models. *Interact Cardiovasc Thorac Surg*. 2018;26:881-2.
18. Yang DH, Kang JW, Kim N, Song JK, Lee JW, Lim TH. Myocardial 3-dimensional printing for septal myectomy guidance in a patient with obstructive hypertrophic cardiomyopathy. *Circulation*. 2015;132:300-1.
19. Fujita B, Kutting M, Seiffert M, Scholtz S, Egron S, Prashovikj E, et al. Calcium distribution patterns of the aortic valve as a risk factor for the need of permanent pacemaker implantation after transcatheter aortic valve implantation. *Eur Heart J Cardiovasc Imaging*. 2016;17:1385-93.
20. Hosny A, Dilley JD, Kelil T, Mathur M, Dean MN, Weaver JC, et al. Pre-procedural fit-testing of TAVR valves using parametric modeling and 3D printing. *J Cardiovasc Comput Tomogr*. 2019;13:21-30.
21. Qian Z, Wang K, Liu S, Zhou X, Rajagopal V, Meduri C, et al. Quantitative prediction of paravalvular leak in transcatheter aortic valve replacement based on tissue-mimicking 3D printing. *JACC Cardiovasc Imaging*. 2017;10:719-31.
22. Ripley B, Kelil T, Cheezum MK, Goncalves A, Di Carli MF, Rybicki FJ, et al. 3D printing based on cardiac CT assists anatomic visualization prior to transcatheter aortic valve replacement. *J Cardiovasc Comput Tomogr*. 2016;10:28-36.
23. Tanaka Y, Saito S, Sasuga S, Takahashi A, Aoyama Y, Obama K, et al. Quantitative assessment of paravalvular leakage after transcatheter aortic valve replacement using a patient-specific pulsatile flow model. *Int J Cardiol*. 2018;258:313-20.
24. Levin D, Mackensen GB, Reisman M, McCabe JM, Dvir D, Ripley B. 3D printing applications for transcatheter aortic valve replacement. *Curr Cardiol Rep*. 2020;22:23.
25. Basman C, Seetharam K, Pirelli L, Kliger CA. Transcatheter aortic valve-in-valve-in-valve implantation with three-dimensional printing guidance: a case report. *J Card Surg*. 2020;35:1676-80.
26. Spring AM, Pirelli L, Basman CL, Kliger CA. The importance of pre-operative imaging and 3-D printing in transcatheter tricuspid valve-in-valve replacement. *Cardiovasc Revasc Med*. July 28, 2020 [Epub ahead of print].
27. Hatoum H, Dolly J, Lilly SM, Crestanello JA, Dasi LP. Sinus hemodynamics variation with tilted transcatheter aortic valve deployments. *Ann Biomed Eng*. 2019;47:75-84.
28. Barabas IJ, Hartyszky I, Kocher A, Merkely B. A 3D printed exoskeleton facilitates HeartMate III inflow cannula position. *Interact Cardiovasc Thorac Surg*. 2019;29:644-6.
29. Farooqi KM, Saeed O, Zaidi A, Sanz J, Nielsen JC, Hsu DT, et al. 3D printing to guide ventricular assist device placement in adults with congenital heart disease and heart failure. *JACC Heart Fail*. 2016;4:301-11.
30. Hoashi T, Ichikawa H, Nakata T, Shimada M, Ozawa H, Higashida A, et al. Utility of a super-flexible three-dimensional printed heart model in congenital heart surgery. *Interact Cardiovasc Thorac Surg*. 2018;27:749-55.
31. Yang DH, Park SH, Kim N, Choi ES, Kwon BS, Park CS, et al. Incremental value of 3D printing in the preoperative planning of complex congenital heart disease surgery. *JACC Cardiovasc Imaging*. August 16, 2020 [Epub ahead of print].
32. Vukicevic M, Filippini S, Little SH. Patient-specific modeling for structural heart intervention: role of 3D printing today and tomorrow (CME). *Methodist Debaque Cardiovasc J*. 2020;16:130-7.
33. Mowers KL, Fullerton JB, Hicks D, Singh GK, Johnson MC, Anwar S. 3D echocardiography provides highly accurate 3D printed models in congenital heart disease. *Pediatr Cardiol*. 2021;42:131-41.
34. Ong CS, Nam L, Ong K, Krishnan A, Huang CY, Fukunishi T, et al. 3D and 4D bioprinting of the myocardium: current approaches, challenges, and future prospects. *Biomed Res Int*. 2018;2018:6497242.
35. Wang H, Song H, Yang Y, Cao Q, Hu Y, Chen J, et al. Three-dimensional printing for cardiovascular diseases: from anatomical modeling to dynamic functionality. *Biomed Eng Online*. 2020;19:76.

Key Words: 3D printing, cardiac surgery, education, surgical planning, septal myectomy, TAVR, LVAD, congenital heart surgery