

POSTER PRESENTATION

Open Access

Assessment of left ventricular apical rotation in obese by Cardiovascular MR tagging

Gabriella M Vincenti^{1*}, Jean-Noel Hyacinthe², Joost PA Kuijjer³, Francois Mach¹, Osman Ratib⁴, Thomas Schindler¹, Jean-Paul Vallée²

From 2011 SCMR/Euro CMR Joint Scientific Sessions
Nice, France. 3-6 February 2011

Background

Obesity is associated with cardiac remodelling with increased left ventricular mass and end-diastolic volume. CMR is a unique technique to evaluate cardiac morphology and function in obese individuals. Among CMR techniques, myocardial tagging allows to quantify myocardial strain and left ventricular rotation along the RR cycle (1). The aim of this preliminary study was to explore the feasibility of left ventricular apical rotation quantification by CMR tagging in obese individuals and exploring possible alteration of myocardial motion pattern.

Methods

8 healthy controls (18 < BMI < 25) were imaged using a 3T trio system and 7 obese subjects (BMI > 30) without other cardiovascular risk factors and with normal left ventricular ejection fraction were imaged using a 1.5T Espree system (wider bore, well adapted to obese subjects). We used an ECG gated, single breath hold balanced SSFP line tagging sequence with LISA, with CSPAMM acquisition scheme (2). The field of view was 340 x 340 mm, matrix 256 with 32% phase resolution, bandwidth 850 Hz, slice thickness 7 mm, tag spacing 7 mm, TE 1.28 (TE 1.54 @ 3T) and Flip angle 20° (15° @ 3T). Images were analyzed and apical rotations were computed using Extrema Temporal Chaining (ETC) (3).

Results

The left ventricular apical systolic rotation measured by CMR tagging was increased and delayed in obese patients while the diastolic apical untwisting was prolonged, when compared to control subjects (Fig.1).

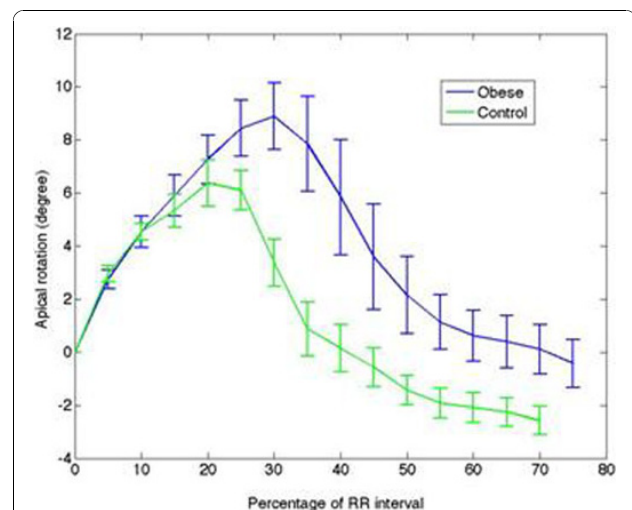


Figure 1 Left ventricular apical rotation along RR interval in Obese and control subjects.

Conclusions

Our preliminary results confirm the presence of an abnormal pattern of left ventricular rotation in obese individuals that can be identified with CMR tagging. This abnormal pattern may reflect the remodeling secondary to increased hemodynamic requirements (volume-overload and sympathetic system activation) in obese subjects, while the delayed diastolic untwisting may precede a diastolic dysfunction. These preliminary data confirm that CMR with myocardial tagging may allow identifying early abnormalities of left ventricular function in obese individuals with normal left ventricular ejection fraction.

Author details

¹Division of Cardiology, Geneva University Hospital, Geneva, Switzerland.
²Division of Radiology, Geneva University Hospital, Geneva, Switzerland.

¹Division of Cardiology, Geneva University Hospital, Geneva, Switzerland
Full list of author information is available at the end of the article

³Department of Physics & Medical Technology, VU University Medical Center, Amsterdam, Netherlands. ⁴Division of Nuclear Medicine, Geneva University Hospital, Geneva, Switzerland.

Published: 2 February 2011

References

1. Stuber M, et al: *Circulation* 1999, **100**(4):361-8.
2. Zwanenburg JJ, et al: *Magn Reson Med* 2003, **49**(4):722-30.
3. Jacob JP: *LNCS* 2006, **4179**:897-908.

doi:10.1186/1532-429X-13-S1-P326

Cite this article as: Vincenti et al.: Assessment of left ventricular apical rotation in obese by Cardiovascular MR tagging. *Journal of Cardiovascular Magnetic Resonance* 2011 **13**(Suppl 1):P326.

**Submit your next manuscript to BioMed Central
and take full advantage of:**

- Convenient online submission
- Thorough peer review
- No space constraints or color figure charges
- Immediate publication on acceptance
- Inclusion in PubMed, CAS, Scopus and Google Scholar
- Research which is freely available for redistribution

Submit your manuscript at
www.biomedcentral.com/submit

