

Late-onset descemet membrane detachment and corneal decompensation after laser peripheral iridotomy

A case report

Yana Fu, MD^a, Wuying Zhou, MD^b, Wei Li, MD^b, Xiaolei Lin, MD^a, Qi Dai, MD^{a,*}

Abstract

Rationale: The incidence of cornea disorders after laser peripheral iridotomy (LPI) is extremely low. However, cornea Descemet membrane detachment (DMD) combined with corneal decompensation after LPI could still occur.

Patient concerns: A 69-year-old Chinese woman presented with persistent widespread corneal edema and inferior bullous lesions in her right eye for half a year. She had undergone LPI in both eyes 10 years ago for a prophylactic treatment. The patient received a detailed examination of vivo corneal confocal microscopy and sept-source optical coherence tomography (SS-OCT).

Diagnoses: It was a late-onset DMD that has a positional relationship with LPI, combined with corneal decompensation.

Intervention: Treatment was only supportive with artificial tears and soft contact lenses.

Outcomes: This patient declined to accept keratoplasty because of financial difficulties.

Lessons: Laser peripheral iridotomy may cause spontaneous, late-onset DMD and corneal decompensation. Ophthalmologists should be aware of this potential complication and proceed carefully. A careful examination of cornea especially around the LPI before keratoplasty seems to be necessary to circumvent other complication.

Abbreviations: DMD = Descemet membrane detachment, IOP = intra-ocular pressure, LPI = laser peripheral iridotomy, Nd:YAG = neodymium:YAG, SS-OCT = sept-source optical coherence tomography.

Keywords: corneal decompensation, descemet membrane detachment, laser peripheral iridotomy

1. Introduction

Laser peripheral iridotomy (LPI) is the standard first-line procedure for the treatment and prevention of primary angle-closure glaucoma. Cornea Descemet membrane detachment (DMD) after LPI combined with corneal decompensation is extremely rare. This case report firstly describes the outcome of spontaneous, late-onset DMD and corneal decompensation after LPI with the aid of Swept-source optical coherence tomography (SS-OCT, SS-1000, Tomey Corporation, Japan) and in vivo corneal confocal microscopy (HRT 3, Heidelberg Engineering GmbH, Germany).

2. Case report

A 69-year-old Chinese woman presented with persistent widespread corneal edema and inferior bullous lesions in her right eye for half a year. The patient exhibited symptoms of photophobia, blurred vision, mild pain, and redness. She was diagnosed as “herpes simplex keratitis” in another large hospital 6 months ago, and was treated with oral Aciclovir Tablets 0.2 g 5 times a day and topical 0.1% fluorometholone eye drops 4 times per day for 3 months without any improvement. She received neodymium:YAG (Nd:YAG) LPI in both eyes at another hospital 10 years ago for a prophylactic treatment. She married her cousin, but her family history was negative for ocular disease.

On presentation, the best corrected visual acuity in the right eye was 20/100 (+0.75 +0.50 × 163) and in the left eye was 20/50 (+2.25 +0.75 × 110). Intra-ocular pressure (IOP) was normal in both eyes. Slit lamp evaluation of the right eye revealed diffuse corneal edema accompanied with inferior bullous lesion and mild corneal neovascularization. The endothelium of the whole cornea showed the moderate beaten metal appearance (Fig. 1A and B). The cornea of the left eye was transparent, with lots of pigmented keratic precipitates in the endothelium. The LPI was observed in the inferior quadrant in the left eye, and the depth of the anterior chamber was moderate. Moderate lens opacity was observed in both eyes and the remainder of the ocular examination was normal.

The patient received a detailed examination of in vivo corneal confocal microscopy. Multiple, round, hyporeflexive images with central highlight (guttatae, Fig. 1C) were seen at the level of the endothelium of right eye. Between them, the endothelial cells

Editor: N/A.

The authors declare no conflict of interest.

^a School of Ophthalmology and Eye Hospital, Wenzhou Medical University, Wenzhou, ^b QuZhou Yishi Eye Hospital, QuZhou, Zhejiang, China.

* Correspondence: Qi Dai, Eye Hospital of Wenzhou Medical University, 270 West Xueyuan Road, Wenzhou, Zhejiang, China (e-mail: dq@mail.eye.ac.cn).

Copyright © 2018 the Author(s). Published by Wolters Kluwer Health, Inc. This is an open access article distributed under the terms of the Creative Commons Attribution-Non Commercial-No Derivatives License 4.0 (CCBY-NC-ND), where it is permissible to download and share the work provided it is properly cited. The work cannot be changed in any way or used commercially without permission from the journal.

Medicine (2018) 97:10(e0083)

Received: 5 January 2018 / Accepted: 9 February 2018

<http://dx.doi.org/10.1097/MD.00000000000010083>

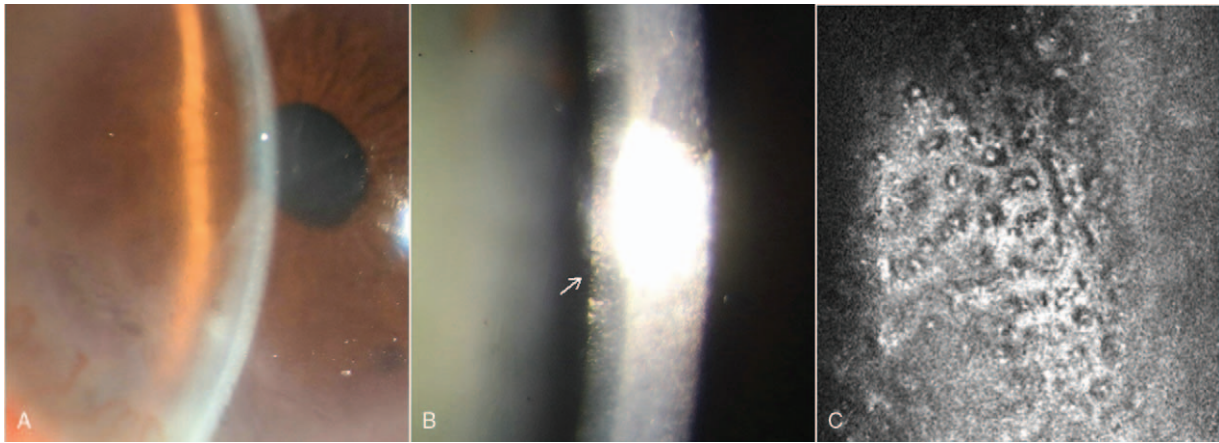


Figure 1. (A) Slit lamp evaluation of the right eye revealed diffuse corneal edema accompanied with inferior bullous corneal lesion and mild corneal neovascularization. (B) The beaten-metal appearance of guttae is appreciated posteriorly in light reflected from Descemet membrane (arrow). (C) Confocal microscopy of the right eye. Multiple, round, hyporeflective images with central highlight (guttae) were seen at the level of the endothelium.

could not be identified individually. In the left eye, there were lots of irregular hyperreflective granules in the Descemet's membrane, and the endothelial cells of left eye were 1998 cell/mm². SS-OCT images visualized LPI in the 8 o'clock and a wavy Descemet's membrane and endothelium layer, which was detached inferiorly (Fig. 2B). The corneal thickness was suggested to be 699 μm in the right eye and 555 μm in the left eye.

This patient has been rechecked regularly in our hospital. But she declined to accept keratoplasty because of financial

difficulties. The treatment was only supportive with artificial tears and soft contact lenses.

This study was approved by the Investigational Review Board of School of Ophthalmology and Optometry and Eye Hospital, Wenzhou Medical University, Wenzhou, China. The patient enrolled has given informed consent.

3. Discussion

LPI is a relatively safe procedure. However, complications, including iritis, cataract, hemorrhage, IOP elevations, disorders of Descemet membrane, and corneal endothelial damage have been reported.^[1,2] DMD represents a rare clinical entity. It occurs most commonly as a complication of intraocular surgery or after trauma associated with breaks in descemet membrane.^[3] To our knowledge, this is the first case of spontaneous, late-onset DMD after LPI to be reported in literature. The case is unique given the late-onset DMD combined with corneal decompensation after the LPI.

Corneal decompensation after LPI is a rare long-term sequelae and is usually localized to the iridotomy site.^[4,5] Accumulating evidence showed a significant central corneal endothelial loss and potential long-term risk of corneal decompensation.^[6-8] The factors contributing to endothelial cell damage or loss include direct focal injury to the endothelium by the laser, excessive heat production during the iris photodisruption process, the mechanical shock waves stirred up at the retrocorneal aqueous, iris pigment dispersion, anterior chamber inflammation, and preexisting corneal guttae.

In this case, there were lots of gutta in the endothelial cells of right eye, and the endothelial cells appeared hyperreflective and could not be identified individually. Although the corneal decompensation was definitely existed, it still could hardly explain the DMD. To our knowledge, the literature contains only one other reported a case of Descemet membrane detachment after laser peripheral iridotomy.^[9] It happened at the next day after treatment and the Descemet membrane reattached spontaneously 2 weeks later. They proposed that the propagating shock waves formed during photodisruption may deliver excessive amounts of energy toward the corneal endothelium, producing linear cracks of Descemet membrane and resulting in detachment. Unlike the former report, the onset time of DMD in this case is

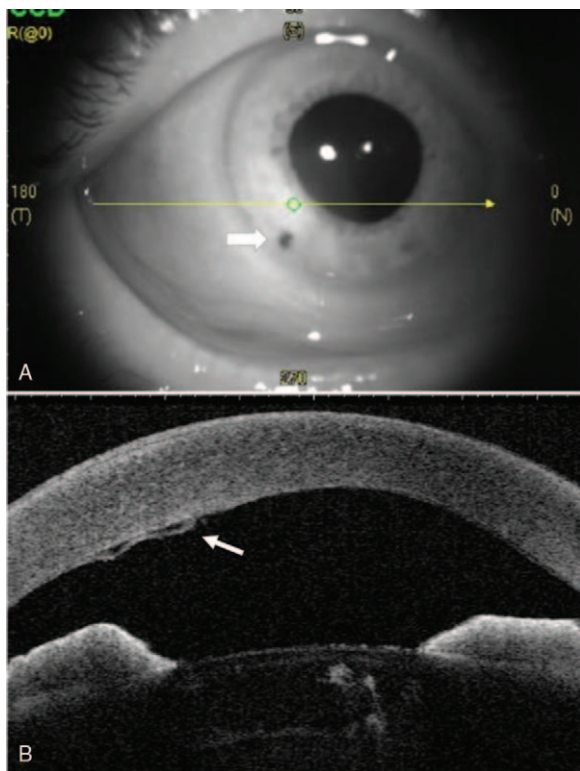


Figure 2. SS-OCT images of right eye, showing the laser peripheral iridotomy (thick short arrow) and the detached Descemet membrane (thin short arrow). The scan position of image (B) corresponds to image (A) (long arrow), respectively.

delayed by about 10 years. The exact pathogenesis of this phenomenon is not known, but we hypothesized that the LPI treatment may be a likely factor, which gives rise to the unexpected DMD. With respect to the different extent of cracks of Descemet membrane, DMD may not happen immediately after LPI because of the peripheral normal endothelium spreading. When the endothelium was getting worse over time, the peripheral endothelial cells might not be sufficient to bear the extra burden. And the spontaneous detachment of the Descemet membrane may occur. As most papers reported that the time from laser iridotomy to decompensation is about 6 years (range, 0.2–16 years),^[7,10] the time of DMD in our case may also support this perspective.

Before the application of anterior segment OCT, visualization of a partial descemet membrane detachment was difficult and the DMD may not be routinely considered as an etiology of corneal edema. Anterior segment OCT is indispensable, which can provide more excellent and precise assessment for subtle corneal changes. The best treatment for bullous keratopathy after LPI is endothelial keratoplasty. We need to consider the probability of potential DMD, which may influence or alter some procedures in surgery.

4. Conclusions

We report a rare case of spontaneous Descemet membrane detachment and corneal decompensation that has a positional relationship with LPI. Ophthalmologists should take care of performing LPI in the eyes, be aware of this potential

complication and appropriately counsel their patients. A careful examination of cornea especially around the LPI before keratoplasty seems to be necessary to circumvent other complication.

References

- [1] Wishart PK, Sherrard ES, Nagasubramanian S, et al. Corneal endothelial changes following short pulsed laser iridotomy and surgical iridectomy. *Trans Ophthalmol Soc U K* 1986;105(Pt 5):541–8.
- [2] Quigley HA. Long-term follow-up of laser iridotomy. *Ophthalmology* 1981;88:218–24.
- [3] Gorski M, Shih C, Savoie B, et al. Spontaneous descemet membrane detachment 20 years after penetrating keratoplasty for keratoconus. *Cornea* 2016;35:1023–5.
- [4] Schwartz AL, Martin NF, Weber PA. Corneal decompensation after argon laser iridectomy. *Arch Ophthalmol* 1988;106:1572–4.
- [5] Pollack IP. Current concepts in laser iridotomy. *Int Ophthalmol Clin* 1984;24:153–80.
- [6] Panek WC, Lee DA, Christensen RE. Effects of argon laser iridotomy on the corneal endothelium. *Am J Ophthalmol* 1988;105:395–7.
- [7] Ang LP, Higashihara H, Sotozono C, et al. Argon laser iridotomy-induced bullous keratopathy a growing problem in Japan. *Br J Ophthalmol* 2007;91:1613–5.
- [8] Wang LW, Lee KJ, Masselos K, et al. Management of angle-closure glaucoma in East Asian eyes: a response to argon laser iridotomy-induced bullous keratopathy, a growing problem in Japan. *Br J Ophthalmol* 2008;92:1300author reply 1300-1301.
- [9] Liu DT, Lai JS, Lam DS. Descemet membrane detachment after sequential argon-neodymium:YAG laser peripheral iridotomy. *Am J Ophthalmol* 2002;134:621–2.
- [10] Lim LS, Ho CL, Ang LP, et al. Inferior corneal decompensation following laser peripheral iridotomy in the superior iris. *Am J Ophthalmol* 2006;142:166–8.