

## Idiopathic hypertrophic cranial pachymeningitis treated by oral methotrexate: a case report and review of literature

T. Bosman · C. Simonin · D. Launay · S. Caron ·  
A. Destée · L. Defebvre

Received: 15 August 2007 / Accepted: 17 November 2007 / Published online: 19 December 2007  
© The Author(s) 2007

**Abstract** Idiopathic hypertrophic cranial pachymeningitis (IHCP) is a rare clinical entity, characterized by a chronic inflammation causing thickening of the dura. Adequate therapeutic management is still a matter of debate. We present a patient with an IHCP, non-responsive to corticotherapy. Oral methotrexate was introduced (12.5 mg weekly) and total remission was observed after 6 weeks, both clinically and after neuro-imaging. We conclude that methotrexate can be effective and a therapeutic option in patients with IHCP who are resistant to corticotherapy or present major side-effects of chronic corticosteroids use.

### Introduction

Hypertrophic pachymeningitis (HP) is a rare clinical entity of diverse aetiology causing thickening of the dura. It was first described by Charcot and Joffroy regarding spinal meninges in 1869. These early reports of hypertrophic

pachymeningitis were related to tuberculosis or syphilis [1]. Naffziger described the first case of idiopathic hypertrophic cranial pachymeningitis (IHCP) [2].

Compression of anatomic structures by the meninx, thickened by inflammatory infiltration is the most important cause of the clinical features. These include headache, cranial nerve palsies and ataxia [3–9].

Several other causes have been recognized, including infections, autoimmune disorders and neoplasms. When an exhaustive evaluation fails to reveal a cause, IHCP is considered. IHCP is a very rare disorder that affects predominantly male patients. Adequate therapeutic management is still a matter of debate. Several therapeutic strategies have been proposed, including steroids and other immunosuppressive agents, as well as radiotherapy and surgical removal of the affected tissue [10].

In this case report, we present a patient with an IHCP and his responsiveness to oral methotrexate.

### Case report

A 62-year-old male consulted in 2002 about a bi-temporal, non-throbbing headache, jaw claudication and diffuse articular pains. He described episodes of transitory hemianopsia. Neurological examination showed no signs of focalisation. He had no history of clinical signs or symptoms of systemic collagen vascular disease, syphilis, tuberculosis or obvious metastatic cancer. Laboratory test showed an erythrocyte sedimentation rate (ESR) of 91 mm and a C-reactive protein of 104 mg l<sup>-1</sup> (normal < 3.2 mg l<sup>-1</sup>). Brain MRI study and biopsies of both temporal arteries were negative. After introduction of oral corticotherapy (prednisone 1 mg kg<sup>-1</sup> day<sup>-1</sup>) an immediate (less than 24 h) and total remission was observed. His neurologist

---

T. Bosman (✉)  
Department of Neurology,  
Leiden University Medical Centre, Leiden, The Netherlands  
e-mail: T.Bosman@LUMC.nl

C. Simonin · A. Destée · L. Defebvre  
Department of Neurology and Movement Disorders,  
Salengro Hospital, Lille University Medical Centre, Lille, France

D. Launay  
Department of Internal Medicine, Claude-Huriez Hospital,  
Lille University Medical Centre, Lille, France

S. Caron  
Department of Radiology, Salengro Hospital,  
Lille University Medical Centre, Lille, France

concluded the disease as a giant cell arteritis. In the following years, multiple attempts were made by his physician to reduce his corticotherapy. With daily doses of less than 30 mg the headache and the inflammatory syndrome reappeared.

A few months before his admission to our hospital the patient presented with recurring headaches, different from the headaches of 2002. He described intense occipital, non-throbbing headaches and cervical pain. The inflammatory syndrome worsened (ESR 100 mm). This exacerbation was accompanied by a lingual hypoesthesia and an important photophobia. Attempts to control this aggravation by intensifying his corticotherapy (80 mg daily) were unsuccessful.

He was admitted in our hospital in November 2005. At this time neurological examination showed a 4th, 5th and 12th left cranial nerve paresis and paresthesia of the left leg. The rest of the clinical examination was normal. Ophthalmologic examination showed glaucoma as a complication of his chronic corticotherapy. Blood analysis revealed an ESR of 60 mm and a C-reactive protein level of  $55 \text{ mg l}^{-1}$ . Brain MRI revealed a diffuse thickening and enhancement of the pachymeninges along both sides of the tentorium (Fig. 1).

All known causes of pachymeningitis were explored. Blood analyses of rheumatoid factor, complement activation, antineutrophilic cytoplasmic antibodies (ANCA), antinuclear antibodies and tumour markers were normal. Cerebrospinal fluid (CSF) analyses revealed discrete pleocytosis (white blood cell count  $23 \text{ mm}^{-3}$  and elevated protein levels  $1.33 \text{ g l}^{-1}$ , normal value  $0.6\text{--}1 \text{ g l}^{-1}$ ) but the virologic, parasitologic and bacteriologic analyses were negative. PCR assay for the detection of *Mycobacterium tuberculosis* DNA was negative. Carcinomatous cells were not detected in two CSF samples. Angiotensin converting enzyme was slightly elevated ( $2.2 \text{ UI L}^{-1}$ , interval  $0.5\text{--}1.50$ ). Chest CT and MRI, bronchial fibroscopy with biopsy,

gallium scintigraphy, neurophysiologic explorations presented no arguments for a systemic disease. Investigation for a neoplasia (tumour markers, chest and abdominal CT and bone scintigraphy) was negative. C-reactive protein continued to rise ( $115 \text{ mg L}^{-1}$ ) and a significant worsening of the patient's general condition was noted with a weight loss of 8 kg in 3 months. A control MRI study confirmed the worsening of the diffuse thickening of the dura (Fig. 2).

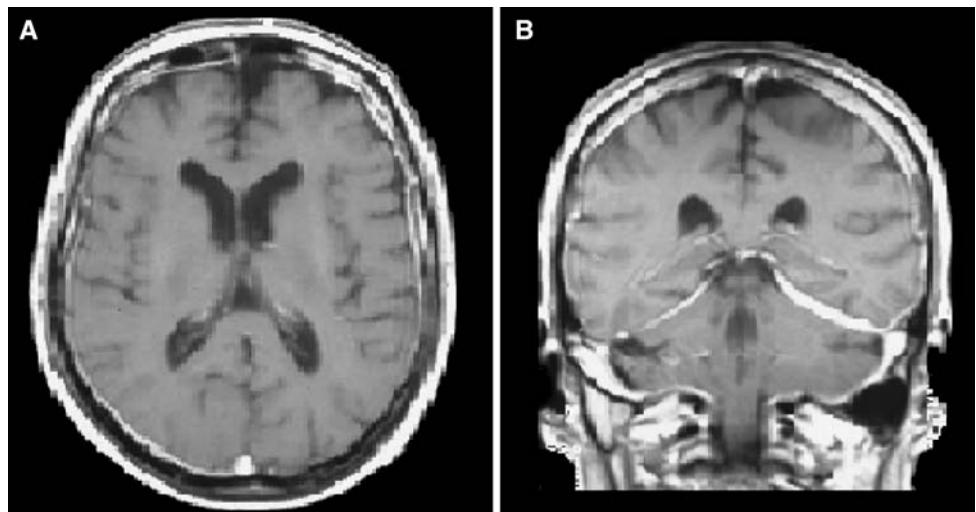
A meningeal biopsy was performed which showed an inflammatory infiltration, locally granulomatous but non-specific. No signs of vasculitis, neoplastic cells or infectious agents were found.

With these exhaustive clinical and para-clinical investigations being negative, we concluded at an IHCP. At that moment the patient was still treated with 60 mg of prednisone daily.

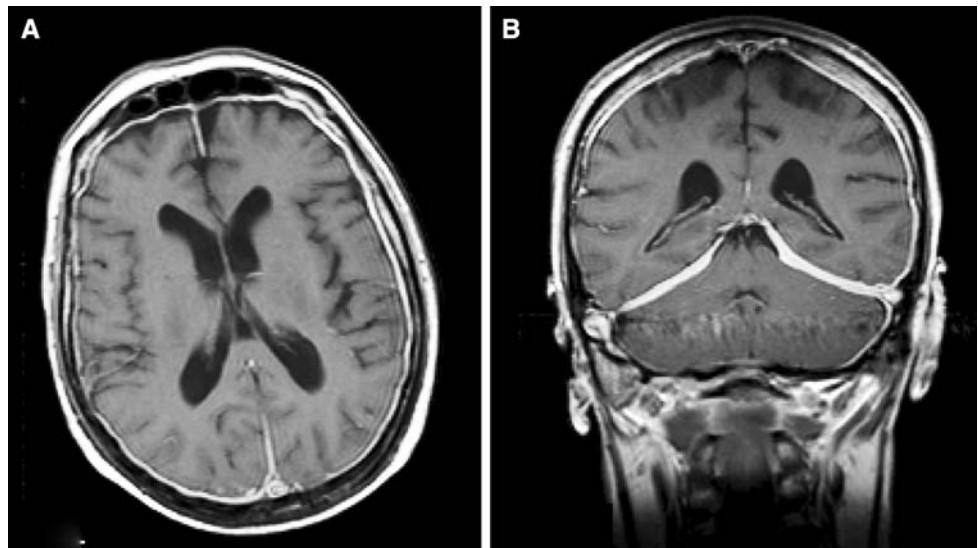
Because of his resistance to chronic steroid therapy, IV methylprednisone was administered ( $1 \text{ g day}^{-1}$  for 3 days) and oral methotrexate  $12.5 \text{ mg}$  weekly was started. Total remission of the clinical and biologic abnormalities was evident 6 weeks after introduction of methotrexate as long as there was a progressive reduction of corticotherapy. He regained 7 kg in the following weeks. No side effects were noted. A control MRI study, performed 6 weeks after introduction of methotrexate, demonstrated a practically total abolition of the dural enhancement (Fig. 3).

Currently, after 10 months of follow-up (after introduction of methotrexate), the patient is doing well and his corticotherapy is continually reduced. He recovered for his glaucoma and had no side effects for methotrexate. He currently takes  $15 \text{ mg}$  of oral methotrexate weekly and  $12.5 \text{ mg}$  cortisone daily and continues to reduce his corticotherapy. ESR and C-reactive protein remain normal. However he continues to describe facial paresthesias. Our therapeutic strategy is to lower the cortisone dosage until  $10 \text{ mg}$  daily and after a stable condition (clinically and

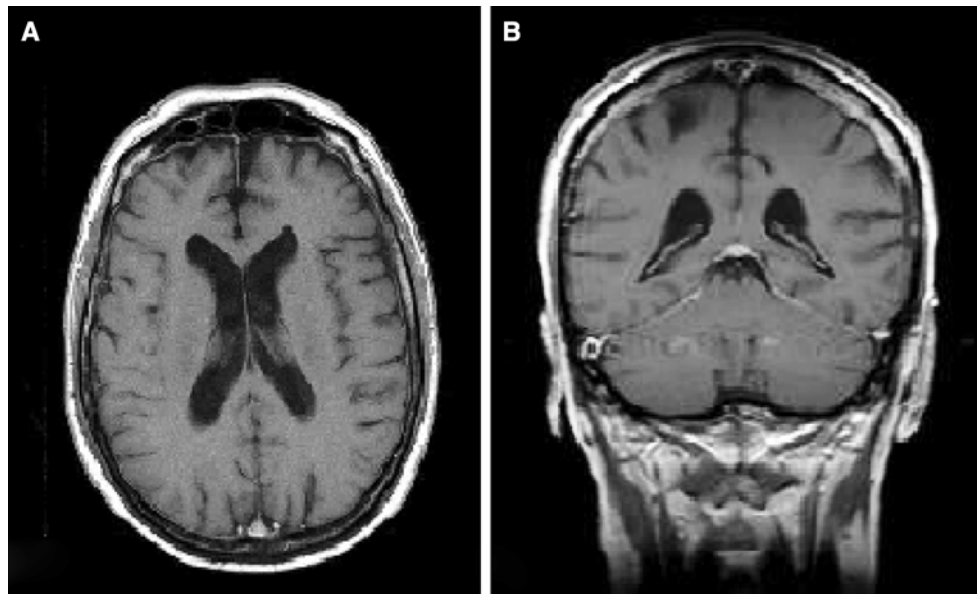
**Fig. 1** Axial (a) and coronal (b) T1-weighted contrast-enhanced MR images show markedly thickened and enhanced dura extending from the vertex to the tentorium



**Fig. 2** Axial (a) and coronal (b) T1-weighted contrast-enhanced MR images show progression of dural thickening corresponding with the clinical worsening at the time of the biopsy



**Fig. 3** Axial (a) and coronal (b) T1-weighted contrast-enhanced MR images obtained 6 weeks after introduction of methotrexate show regression of dural thickening and enhancement



biologically) of minimum 6 months, we will try to lower the methotrexate dosage.

## Discussion

Our patient presented with IHCP, which was confirmed by neuroimaging and biopsy, and which improved with the association of corticosteroids and methotrexate. Since the introduction of CT and MRI, IHCP has been increasingly reported in recent literature. The clinical picture can be heterogeneous. Parney et al. [11] described headache, cranial nerve palsy and ataxia in 88, 62 and 32% of the cases, respectively. Cranial nerve palsies are due to compression of the exit zone of the nerve roots by the hypertrophic basal pachymeningitis. Riku and kato [12] described two

patterns of the multiple cranial neuropathies depending on the site of dural inflammation: cavernous sinus to superior orbital fissure involvement and falcotentorial to posterior fossa dural involvement. The headache is probably related to the dural inflammation because in many cases no evidence of raised intracranial pressure was present. Recently, the headache profile was described by Wang et al. [13] and characterized as a chronic daily headache, often resembling chronic migraine. Our patient also described daily headache, but the headache did not resemble chronic migraine. Rarely, IHCP has been reported to lead to internal carotid artery occlusion, venous sinus occlusion and obstructive hydrocephalus [14–18].

Hypertrophic pachymeningitis can be divided into two types: secondary, in which there is an identifiable coexisting cause and idiopathic, in which no identifiable cause, as

in our patient. IHCP is thus a diagnosis of exclusion. Differential diagnoses are extensive. In our case, we performed a diagnostic work-up based on all known causes in current literature [10]. Most authors consider intracranial hypotension, infections, systemic autoimmune disorders, malignancy and meningioma as the main aetiologies of enhanced dura mater on gadolinium MRI.

Although by definition no cause is found for IHCP, different abnormalities are described. In a series of 12 patients, Kupersmith et al. described an elevated ESR in 41%. The chemistry of CSF was variable and non-diagnostic, but protein was elevated in 50% of their patients. They recommend biopsy of the dura when the patient clinically deteriorates or the neuro-imaging worsens, despite treatment [10]. Until now the pathogenesis of IHCP remains unclear. The close relationship to autoimmune disorders such as Wegner's granulomatosis, rheumatoid arthritis or other connective tissue diseases has been described. Recently p-ANCA positive HP has been reported. As p-ANCA antibodies have been detected in many vasculitides, microvasculitis may be involved in some cases of IHCP [19].

Neuroimaging plays a key role in the evaluation of IHCP. Nevertheless, image study of IHCP can remain negative for 2 years before there is any significant finding [20]. The MR images show a diffusely thickened dura, usually isointense on T1-weighted slices that enhances strongly after paramagnetic contrast injection due to an inflammatory reaction of the pachymeninges. On T2-weighted imaging, the dura appears commonly hyperintense, rarely hypointense related to fibrosis process. The use of gadolinium is important for the evaluation of the pattern of meningeal enhancement that may differentiate between pachy- and lepto-meningitis. MRI can also demonstrate areas suitable for biopsy. In our case, the MRI was normal in the beginning. Although there was an evident change in symptomatology of disease progression, the possibility remains that the symptoms diagnosed as a giant cell arteritis in 2002 was the initial presentation of an occult IHCP.

As mentioned above, the role of the dural biopsy is important in the diagnostic process but even more important is to exclude other causes of HP. Taken into account the high number of relapses reported in literature, biopsy in an early disease stage must be discussed. Non-specific inflammatory changes in the dura are common histopathologic features. Vasculitis or granulomatous changes have been described as well [19].

In our case report angiotensin converting enzyme levels in CSF were elevated and although no other argument was found, neurosarcoidosis must be discussed in our patient. Although the biopsy performed in our patient did not find

elements in favour of neurosarcoidosis, we must admit that chronic immunosuppressive therapy can mask the results.

In recent literature there is no consensus on the adequate management of IHCP. Spontaneous resolution of both clinical symptoms and signs, and dural thickening has been reported [21]. A variety of therapeutic approaches have been tried alone or in combination. Corticosteroid therapy is often effective in ameliorating the symptoms and signs, and in stopping the disease progression [22]. In those who do not respond to steroids or those who develop steroid dependence, other immunosuppressive therapies have been used [23].

Most authors agree that corticotherapy should be the first approach in IHCP. Some authors describe only a partial effectiveness of corticosteroid therapy, with partial clinical improvement and relapse when tapering the dosage [10]. Table 1 gives an overview of the therapeutic trials since 1990. Searching the pubmed database in the English-language literature for patients with IHCP receiving treatment, we identified a total of 60 patients. The most frequently used treatment was steroid therapy ( $n = 56$ , 93%). Thirty-nine patients were treated with corticosteroids as monotherapy (65%). In this subgroup, 18 patients experienced relapses (46%). Different add-on therapeutic options are proposed; six patients received azathioprine, one patient cyclophosphamide, one patient underwent surgery and two patients were treated with methotrexate. In all these patients receiving add-on therapy, a sustained remission was described, permitting to stop or reduce the daily dose of corticosteroids. Considering occult tuberculosis, one patient was empirically treated with antitubercular medication as monotherapy. Surgical excision is sometimes necessary for patients with mass effect due to thickening of the skull base [19]. Symptomatic hydrocephalus sometimes requires ventriculoperitoneal shunting. In the identified patient group, five were operated, one after therapeutic failure of the corticotherapy. Recently the use of low-dose pulse subcutaneous methotrexate was proposed as monotherapy. Total remission of the clinical and neuro-imaging abnormalities was evident after 6 months [24–32].

In our patient we chose a low-pulse oral methotrexate scheme of 12.5 mg weekly. Although, large randomized trials are required to prove the efficacy and tolerability of methotrexate at different doses and routes of administration, we noted a spectacular improvement within the 6 weeks following introduction of methotrexate. After introduction of methotrexate we were able to taper the corticotherapy and reduce the side-effects of its chronic use (glaucoma). There is no consensus about the duration of this therapy. After minimum 12 months we will try to stop the methotrexate.

**Table 1** Therapeutic options: an overview of the literature

Author	PY	N	Treatment	Outcome
Hamilton et al. [24]	1993	3	Corticosteroid + Aza ( <i>N</i> = 2) Mtx + chloroquine ( <i>N</i> = 1)	Remission with after addition Aza No improvement with Mtx Remission after addition chloroquine
Masson et al. [25]	1993	7	Corticosteroid ( <i>N</i> = 4) Radiotherapy ( <i>N</i> = 1) Corticotherapy + Aza ( <i>N</i> = 1)	Improvement but corticoid dependent No lasting improvement Permitting lowering of corticotherapy after introduction of Aza
Botella et al. [26]	1994	1	Surgery	Temporary relief
Parney et al. [11]	1997	1	Antituberculous therapy	Total remission
Nishioka et al. [27]	1998	1	Corticotherapy	Relapse
Hatano et al. [23]	1999	6	Corticotherapy ( <i>N</i> = 4) Surgery + corticotherapy ( <i>N</i> = 1) Corticotherapy + cyclophosphamide ( <i>N</i> = 1)	Three sustained remissions Three relapses
Yamamoto et al. [28]	2000	1	Corticotherapy Lymphocytapheresis	Remission after lymphocytapheresis
Dumont et al. [29]	2000	2	One corticotherapy One surgery	Sustained remission Sustained remission
Sylaja et al. [3]	2002	4	Four corticotherapy	One complete remission Three partial remission
Lee et al. [5]	2003	1	Surgery	Remission
Riku et al. [12]	2003	14	Thirteen corticotherapy One corticotherapy + Aza One surgery	Relapses in 7 patients Long-term improvement
Kupersmith et al. [10]	2004	12	Twelve corticotherapy Two corticotherapy + Mtx Two corticotherapy + Aza	Relapses in 6 patients Reduction of corticotherapy Reduction of corticotherapy
Rossi et al. [30]	2004	4	Corticotherapy	Three remission One relapse
Kanemoto et al. [31]	2005	1	Corticotherapy	Remission
Ruiz et al. [32]	2006	1	Subcutaneous methotrexate	Total remission
Rudnik et al. [33]	2007	1	Corticotherapy	Remission

PY publication year, N number of patients, Aza azathioprine, Mtx methotrexate

## Conclusion

In this patient with an IHCP, methotrexate was a safe and effective treatment, resulting in a total remission after 6 weeks and allowing to reduce corticotherapy. In patients with IHCP which is non-responsive to corticotherapy, or in patients who present major side-effects of their chronic use of corticosteroids, methotrexate seems indicated. However further work is required to determine the place of oral methotrexate in the therapeutic management of IHCP.

**Open Access** This article is distributed under the terms of the Creative Commons Attribution Noncommercial License which permits any noncommercial use, distribution, and reproduction in any medium, provided the original author(s) and source are credited.

## References

1. Charcot JM, Joffroy A (1869) Deux cas d'athrophie musculaire progressive avec lésions de la substance gris et des faisceaux ant-ériolatéraux de la melle épinière. Arch Physiol Norm Pathol 2:354–367, 629–649, 744–769
2. Naffziger HC, Stern WE (1949) Chronic pachymeningitis: report of a case and review of the literature. Arch Neurol Psychiatry 62:383–411
3. Sylaja PN, Cherian PJ, Das CK, Radhakrishnan VV, Radhakrishnan K (2002) Idiopathic hypertrophic cranial pachymeningitis. Neurol India 50:53–59
4. D'Andrea G, Trillo G, Celli P, Roperto R, Crispo F, Ferrante L (2004) Idiopathic intracranial hypertrophic pachymeningitis: two case reports and review of the literature. Neurosurg Rev 27:199–204
5. Lee YC, Cueng YC, Hsu SW, Lui CC (2003) Idiopathic Hypertrophic Cranial pachymeningitis: Case report with 7 years of imaging follow-up. AJNR 24:119–123

6. Misra UK, Kalita J (2002) Idiopathic Hypertrophic Pachymeningitis: Easy to Suspect, Difficult to prove. *Neurol India* 50:4–5
7. Prabhakar S, Bhatia R, Lai V, Singh P (2002) Hypertrophic pachymeningitis: varied manifestations of a single disease entity. *Neurol India* 50:45–52
8. De Deus-Silva L, de Queiroz LS, Zanardi Vd Vde A, Ghizone E, da Pereira HC, Malveira GL, Pirani C Jr, Damasceno BP, Cendes F (2003) Hypertrophic pachymeningitis: case report. *Arq Neuropsiquiatr* 61:107–111
9. Bang OY, Kim DI, Yoon SR, Choi IS (1998) Idiopathic hypertrophic pachymeningeal lesions: correlation between clinical patterns and neuroimaging characteristics. *Eur Neurol* 39:49–56
10. Kupersmith MJ, Martin V, Heller G, Shah A, Mitnick HJ (2004) Idiopathic hypertrophic pachymeningitis. *Neurology* 62:686–694
11. Parney IF, Johnson ES, Allen PB (1997) Idiopathic cranial hypertrophic pachymeningitis responsive to antituberculous therapy: a case report. *Neurosurgery* 41:965–971
12. Riku S, Kato S (2003) Idiopathic hypertrophic pachymeningitis. *Neuropathology* 23:335–344
13. Wang YJ, Fuh JL, Lirng JF, Lu SR, Wang SJ (2004) Headache profile in patients with idiopathic hypertrophic cranial pachymeningitis. *Headache* 44:916–923
14. Fain O, Seror O, Wirth JF, Heron C, Mathieu E, Chamouard JM, Guillevin L, Thomas M (1999) Les pachyméningites crâniennes. *Rev Méd Interne* 20:234–246
15. Lam BL, Barrett DA, Glaser JS, Schatz NJ, Brown HH (1994) Visual loss from idiopathic intracranial pachymeningitis. *Neurology* 44:694–698
16. Willing SJ, Broghamer W (1992) Internal carotid artery occlusion due to idiopathic cranial pachymeningitis. *AJNR* 13:1594–1596
17. Oku T, Yamashita M, Inoue T, Sayama T, Kodama T, Nagatomi H, Wakisake S (1995) A case of posterior fossa hypertrophic pachymeningitis with hydrocephalus. *No To Shinkei* 47:569–573
18. Eguchi K, Kodama Y, Hotta T, et al (1996) A case of cranial hypertrophic pachymeningitis with intracranial haemorrhage. *No To Shinkei* 48:475–480
19. Takuma H, Shimada H, Inoue Y, Ishimura E, Himuro K, Miki T, Nishizawa (2001) Hypertrophic pachymeningitis with anti-neutrophil cytoplasmic antibody (p-ANCA), and diabetes insipidus. *Acta Neurol Scand* 104:397–401
20. Mamelak AN, Kelly WM, Davis RL, Rosenblum ML (1993) Idiopathic hypertrophic cranial pachymeningitis. Report of three cases. *J Neurosurg* 79:270–276
21. Nishio S, Morioka T, Togawa A, Yanase T, Nawata H, Fukui M, Hasuo K (1995) Spontaneous resolution of hypertrophic cranial pachymeningitis. *Neurosurg Rev* 18:201–204
22. Tanaka M, Suda M, Ishikawa Y, Fujitake J, Fujii H, Tatsuoka Y (1996) Idiopathic hypertrophic cranial pachymeningitis associated with hydrocephalus and myocarditis: Remarkable steroid induced remission of hypertrophic duramater. *Neurology* 46:554–556
23. Hatano N, Behari S, Nagatani T, Kimura M, Ooka K, Saito K, Yoshida J (1999) Idiopathic hypertrophic cranial pachymeningitis: clinico-radiological spectrum and therapeutic options. *Neurosurgery* 45:1336–1342
24. Hamilton SF, Smith Ch, Lessell S (1993) Idiopathic hypertrophic cranial pachymeningitis. *J Clin Neuroophthalmol* 13:127–134
25. Masson C, Henin D, Hauw JJ, Rey A, Raverdy P, Masson M (1993) Cranial pachymeningitis of unknown origin: A study of seven cases. *Neurology* 43:1329–1334
26. Botella C, Orozco M, Navarro J, Riesgo P (1994) Idiopathic chronic hypertrophic craniocervical pachymeningitis: case report. *Neurosurgery* 35(6):1144–1149
27. Nishioka H, Ito H, Haraoka J, Takahashi M, Shinmura F (1998) Idiopathic hypertrophic cranial pachymeningitis of the cavernous sinus mimicking lymphocytic hypophysitis. *Neurol Med Chir* 36(6):377–382
28. Yamamoto T, Goto K, Suzuki A, Nakamura N, Mizuno Y (2000) Long-term improvement of idiopathic hypertrophic cranial pachymeningitis by lymphocytapheresis. *Ther Apher* 4(4):313–316
29. Dumont AS, Clark AW, Sevick RJ, Myles ST (2000) Idiopathic hypertrophic pachymeningitis: a report of two patients and review of the literature. *Can J Neurol Sci* 27(4):333–340
30. Rossi S, Giannini F, Cerase A, Bartalini S, Tripodi S, Volpi N, Vatti G, Passero S, Galluzi P, Ulivelli M (2004) Uncommon findings in idiopathic hypertrophic cranial pachymeningitis. *J Neurol* 251(5):548–555
31. Kanemoto M, Ota Y, Karahashi T, Nozue N (2005) A case of idiopathic hypertrophic cranial pachymeningitis manifested only by positive rheumatoid factor and abnormal findings of the anterior falx. *Rheumatol Int* 25(3):230–233
32. Ruiz-Sandoval JL, Bernard-Medina H, Ramos-Gomez EJ, Romero-Vargas S, Gutierrez-Urena S, Gonzalez-Cornejo S, Chiquete E (2006) Idiopathic hypertrophic cranial pachymeningitis successfully treated with weekly subcutaneous methotrexate. *Acta Neurochir* 148:1011–1014
33. Rudnik A, Larysz D, Gamrot J, Rudnik A, Skorupa A, Bierzynska-macyszyn G, Bazowski P (2007) Idiopathic hypertrophic pachymeningitis—case report and literature review. *Folia Neuropathol* 45(1):36–42