

Mutation-in-Brief

A case of spondyloepiphyseal dysplasia tarda caused by a novel intragenic deletion of *TRAPPC2*

Masaki Takagi^{1, 2}, Hiroko Yagi³, Yoshie Nakamura³, Hiroyuki Shinohara², Ryojun Takeda², Aya Shimada², Gen Nishimura⁴, and Yukihiro Hasegawa^{2, 3}

¹Department of Pediatrics, Keio University School of Medicine, Tokyo, Japan

²Department of Endocrinology and Metabolism, Tokyo Metropolitan Children's Medical Center, Tokyo, Japan

³Department of Genetic Research, Tokyo Metropolitan Children's Medical Center, Tokyo, Japan

⁴Department of Radiology, Tokyo Metropolitan Children's Medical Center, Tokyo, Japan

Introduction

Spondyloepiphyseal dysplasia tarda (SEDT; MIM # 313400) is a rare X-linked recessive skeletal disease characterized by disproportionate short stature with vertebral malformation and degenerative changes involving the spine and major joints (1). During infancy and early childhood, affected males show normal development and unremarkable findings on radiographs (1). Clinical expression of SEDT begins with a flattening of the growth curve before puberty. At this time, radiographs show characteristic deformities of the vertebrae, including platyspondyly with a posterior hump. Degenerative joint disease is a common problem in male patients making hip joint replacement often necessary in the fourth or fifth decade of life (2).

The causative gene of SEDT is *TRAPPC2*, which encodes trafficking protein particle complex

subunit 2, a 140 amino acid protein, also known as Sedlin. *TRAPPC2* may play a role in vesicular transport from the endoplasmic reticulum to the Golgi (3, 4). To date, 50 *TRAPPC2* mutations have been reported in families with SEDT of different ethnic origin (Human Gene Mutation Database; <http://www.hgmd.cf.ac.uk/ac>). The underlying mutations are spread over the entire coding region of the *TRAPPC2* gene comprising exons 3-6, without clear genotype-phenotype correlation. Here, we report a Japanese SEDT patient with a novel intragenic deletion mutation in *TRAPPC2*.

Patient Report

The proband was a 15-yr-old Japanese male, who was born at 39 wk of gestation after an uncomplicated pregnancy and delivery. He was the second child of nonconsanguineous healthy parents (Fig. 1). At birth, his length was 50.0 cm (+ 0.5 SD), and his weight was 3.28 kg (+ 0.7 SD). He was referred to us at 10 yr of age because of short stature. His height was 110.5 cm (−4.5 SD), and his weight was 20.7 kg (−1.7 SD). His trunk was disproportionately short. The longitudinal growth record of the patient is shown in Fig. 1. The patient's facial features were unremarkable, and his serum concentrations of insulin-like growth factor 1 and thyroid hormone were normal. Radiographs showed platyspondyly

Received: December 5, 2014

Accepted: February 25, 2015

Corresponding author: Yukihiro Hasegawa, Department of Endocrinology and Metabolism, Tokyo Metropolitan Children's Medical Center, 2-8-29 Musashidai, Fuchuyushi, Tokyo 183-8561, Japan
E-mail: yhaset@gmail.com

This is an open-access article distributed under the terms of the Creative Commons Attribution Non-Commercial No Derivatives (by-nc-nd) License <<http://creativecommons.org/licenses/by-nc-nd/3.0/>>.

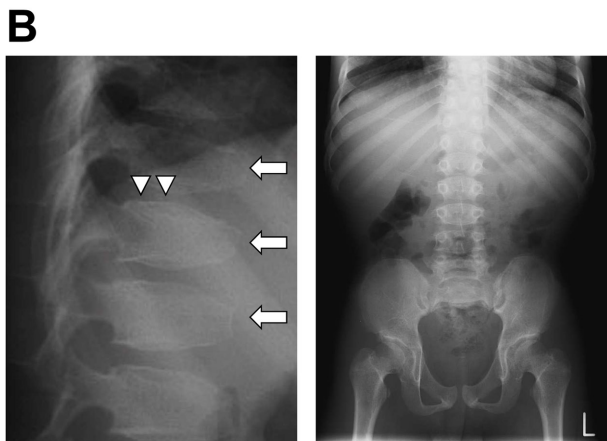
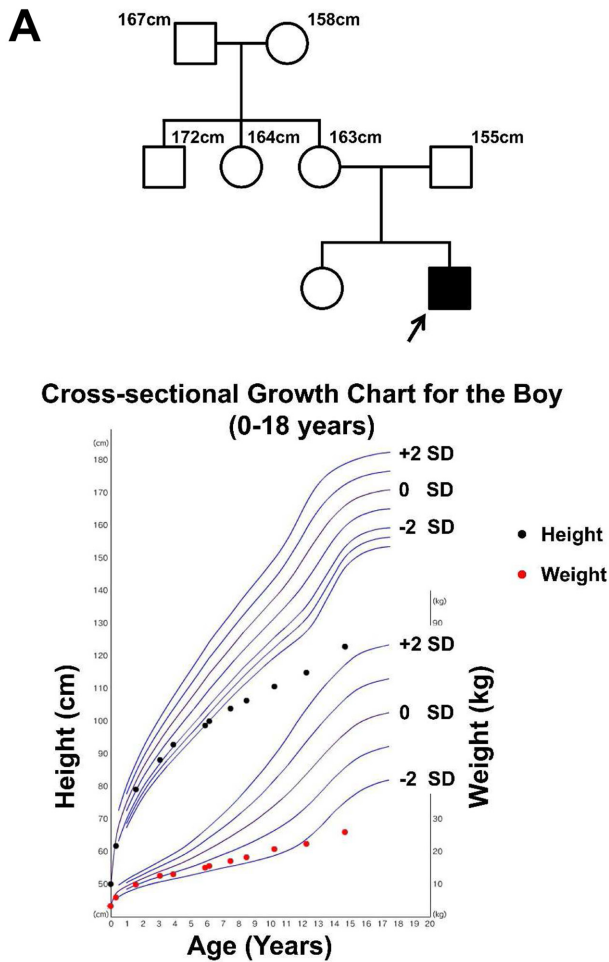


Fig. 1. Characterization of the patient. (A) Pedigree and longitudinal growth record of the Japanese patient with SEDT. (B) Radiographs of the patient at 14 yr of age. Radiographs of the lateral lumbosacral spine (left) showed platyspondyly (arrows) with a posterior hump of the vertebral bodies (arrowheads). The pelvis (right) was normal.

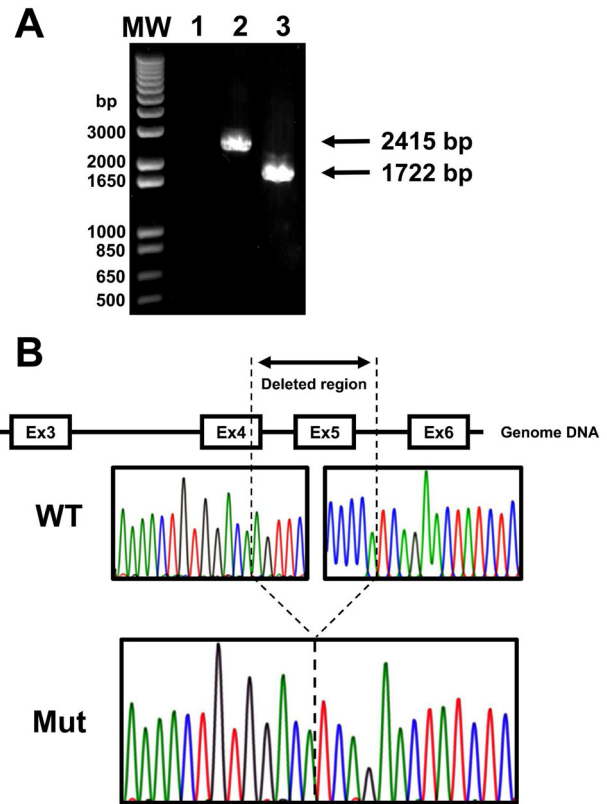


Fig. 2. Identification of a 693 bp intragenic deletion in *TRAPPC2*. (A) To determine the size and possible location of the deletion, primers encompassing exons 4–6 were used. A size difference of 693 bp was apparent. Lanes 1, negative control; lane 2, Control; lane 3, Patient. (B) Schema of the *TRAPPC2* genomic organization and partial sequences of PCR products of the patient are shown.

with a posterior hump of the vertebral bodies, while the pelvis and tubular bones were normal (Fig. 1). A diagnosis of SEDT was made, based on the late onset of disproportionately short stature with short trunk and radiological findings. At 12 yr of age, his height was 114.8 cm (-4.9 SD), his weight was 22.3 kg (-1.9 SD), and his arm span was 121.5 cm. At his last examination at the age of 14 yr and 8 mo, his height was 122.8 cm (-6.8 SD), his weight was 25.9 kg (-2.9 SD), and his arm span was 128 cm. The father of the patient was 155.0 cm (-2.7 SD) tall, and the mother was 163.0 cm (0.9 SD) tall.

Mutational Analysis

After obtaining informed consent, and with the approval of the Institutional Review Board of Keio University School of Medicine, genomic DNA was extracted from the patient's peripheral blood leukocytes. We checked all four coding exons (exons 3-6) and flanking introns of *TRAPPC2* by PCR-direct sequencing. We failed to amplify exons 4 and 5 from the patient, whereas exons 3 and 6 from the patient and all 4 exons from the control DNA were successfully amplified. Then, we performed long-range PCR encompassing exons 4-6. Gel electrophoresis of the PCR products showed a smaller fragment than expected in the patient (Fig. 2A). Sequencing of the mutant fragment revealed a 693-bp deletion, which started in exon 4 and ended in intron 5 (c.197_324+121del693bp) (Fig. 2B). No other family member was available for genetic studies.

Discussion

We report a case of SEDT with partial deletion in *TRAPPC2*. The *TRAPPC2* deletion that we identified is novel and has not been registered as a frequent nonpathogenic copy number variations in existing databases, including the Database of Genomic Variants, DECIPHER and UCSC. The abnormal transcript from this mutant *TRAPPC2* would generate, if translated, a protein lacking one-fifth of TRAPPC2. Although the functional consequence of this deletion has not been determined *in vitro*, we believe that this deletion is pathological.

Since first described by Gedeon *et al.* in 1999 (3), 50 mutations of *TRAPPC2* have been reported, without clear genotype-phenotype correlation. Our findings provide additional evidence that helps us better understand the pathogenesis of TRAPPC2 in SEDT. Clinical characterization of further mutations including deletion cases is necessary to correlate genotype to phenotype.

Acknowledgments

We thank the patient and his families for participation in this study. We also thank Kazue Kinoshita for technical assistance.

References

1. Whyte MP, Gottesman GS, Eddy MC, McAlister WH. X-linked recessive spondyloepiphyseal dysplasia tarda. Clinical and radiographic evolution in a 6-generation kindred and review of the literature. *Medicine (Baltimore)* 1999;78: 9–25. [[Medline](#)] [[CrossRef](#)]
2. Fiedler J, Le Merrer M, Mortier G, Heuertz S, Faivre L, Brenner RE. X-linked spondyloepiphyseal dysplasia tarda: Novel and recurrent mutations in 13 European families. *Hum Mutat* 2004;24: 103. [[Medline](#)] [[CrossRef](#)]
3. Gedeon AK, Colley A, Jamieson R, Thompson EM, Rogers J, Sillence D, *et al.* Identification of the gene (SEDL) causing X-linked spondyloepiphyseal dysplasia tarda. *Nat Genet* 1999;22: 400–4. [[Medline](#)] [[CrossRef](#)]
4. Fan L, Yu W, Zhu X. Interaction of Sedlin with chloride intracellular channel proteins. *FEBS Lett* 2003;540: 77–80. [[Medline](#)] [[CrossRef](#)]