

# Management of presumed candida endophthalmitis during the COVID-19 pandemic: Case report and review of the literature

European Journal of Ophthalmology  
1–5

© The Author(s) 2022

Article reuse guidelines:

sagepub.com/journals-permissions

DOI: 10.1177/11206721221092190

journals.sagepub.com/home/ejo



Federica Fossataro<sup>1,2</sup> , Francesco Martines<sup>1</sup>,  
Piergiorgio Neri<sup>3,4</sup> , Pia Allegri<sup>5</sup> and Alfredo Pece<sup>1</sup>

## Abstract

**Purpose:** To report the management of a case of candida endophthalmitis following intubation for SARS-CoV-2 ARDS, during the first lockdown, underlining consequently the limited access to the gold standard of care.

**Methods:** Case report.

**Results:** We have described the case of a 56-year-old Hispanic man who developed bilateral Candida endophthalmitis after one month of hospitalization in the intensive care unit for severe SARS-CoV-2 pneumonia. Multimodal imaging was obtained. Full serological screening for infection was done resulting negative. A diagnostic vitrectomy was impossible due to the limited access at the surgery room. Diagnosis of presumed candida endophthalmitis was made, according to a highly qualified center, and therapy with intravenous liposomal amphotericin B was administered. At three months, we observed lack of vitreous opacities and atrophic scars with no active lesions.

**Conclusions:** Diagnosis of candida endophthalmitis was a challenge in this pandemic scenario, given the impossibility of performing a diagnostic vitrectomy. Therefore, it was mainly based on patient's clinical manifestations, multimodal imaging and on unanimity of collegiality between our hospital and the highly specialized center.

## Keywords

COVID-19, uveitis, candida, endophthalmitis

Date received: 4 August 2021; accepted: 5 March 2022

## Introduction

Severe acute respiratory syndrome-coronavirus-2 (SARS-CoV-2) had its outbreak worldwide since December 2019.<sup>1</sup> Two months later, the first case of SARS-CoV-2 was registered in Italy - the first among European countries. Italy was in fact hit hard by this pandemic and is still listed among those with the highest numbers of infections and deaths.<sup>1</sup> The disease ranges widely in severity from mild flu-like symptoms to acute respiratory distress syndromes (ARDS) and - even more serious - hemophagocytic lymphohistiocytosis (HLH), which represents the most severe form of the SARS-CoV-2 disease.<sup>2,3</sup> Severe cases rescued by mechanical ventilation were more likely to develop opportunistic superimposed infections, such as fungal ones,

<sup>1</sup>The Eye clinic, Melegnano Hospital, Milan, Italy

<sup>2</sup>Department of Neurosciences, Reproductive Sciences and Dentistry, University of Naples Federico II, Naples, Italy

<sup>3</sup>The Eye Institute, Uveitis service, Cleveland Clinic Abu Dhabi, United Arab Emirates

<sup>4</sup>Cleveland Clinic Lerner College of Medicine of Case Western Reserve University, Cleveland, Ohio, USA

<sup>5</sup>Ocular Inflammatory Diseases Regional Referral Center, Rapallo Hospital, Genova, Italy

### Corresponding author:

Federica Fossataro, Department of Neurosciences, Reproductive Sciences and Dentistry, University of Naples Federico II, Via S. Pansini 5, 80133 Naples, Italy; The Eye clinic, Melegnano Hospital, via Pandina I, Melegnano, Milan, Italy.

Email: federicafossataro@alice.it

which could easily be missed or misdiagnosed in these very complicated circumstances.<sup>4</sup>

Herein, we report a case of candida endophthalmitis following intubation for SARS-CoV-2 ARDS, during the first lockdown, highlighting the challenging management in a limited access healthcare period.

## Case report

A 56-year-old Hispanic male was referred to the Department of Ophthalmology, presenting metamorphopsia and progressive vision loss in the right eye (RE) for one week. The patient was discharged by ten days following one month of hospitalization in the intensive care unit (ICU) of the Melegnano Hospital due to severe SARS-CoV-2 pneumonia. During the hospitalization he received the following care: central venous access catheter (CVC), mechanical ventilation and treatment with hydroxychloroquine, enoxaparin, methylprednisolone and anti-IL-6 receptor monoclonal antibody therapy (aIL-6R, Tocilizumab, Actemra, Roche, Basel, Switzerland).

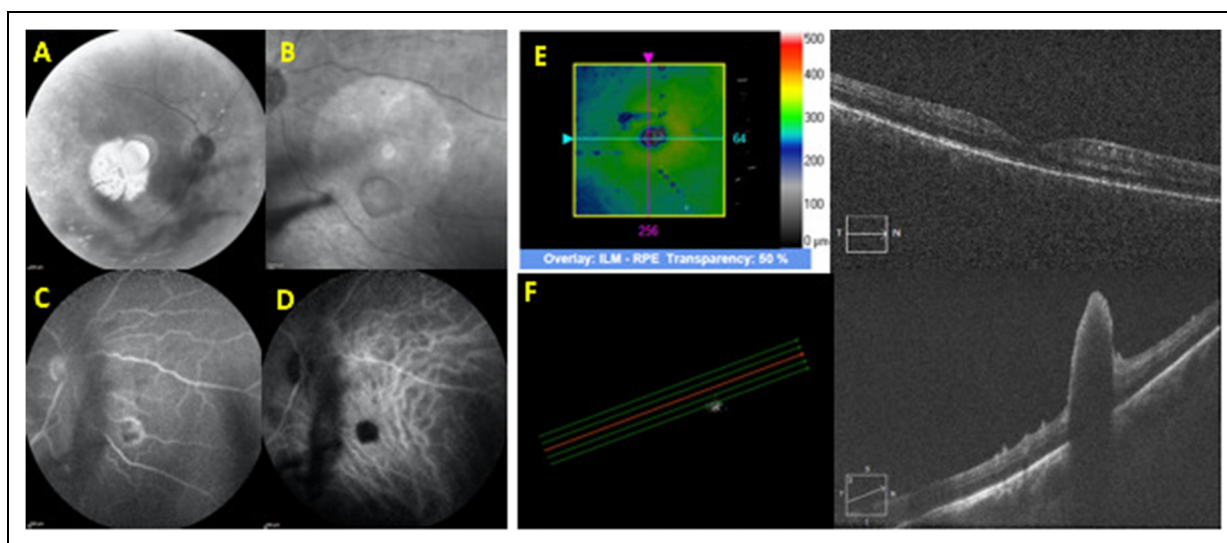
Best-corrected visual acuity (BCVA) was 20/100 in RE and 20/25 in the left eye (LE). Slit-lamp examination of the anterior segment (AS) showed conjunctival injection with ciliary flush, anterior chamber (AC) flare +2, cells 2+ in both eyes (OU) and iris posterior synechiae in RE. There were no cataracts. Vitreous examination presented a binocular indirect ophthalmoscopy (BIO) score<sup>5</sup> of +3, showing “string of pearls” vitreous clots, prevalently located at the inferior retinal periphery of the RE and in the peripapillary region in OU. Intraocular pressure

(IOP) was normal in OU. Fundus examination showed multiple whitish chorioretinal lesions at the inferonasal edge of the optic nerve in RE and in the supero-nasal area of the optic nerve in LE. Infrared examination highlighted the vitreous opacities and the hyperreflective lesions in the juxta-papillary region of OU (Figure 1-A, B and Figure 2-A).

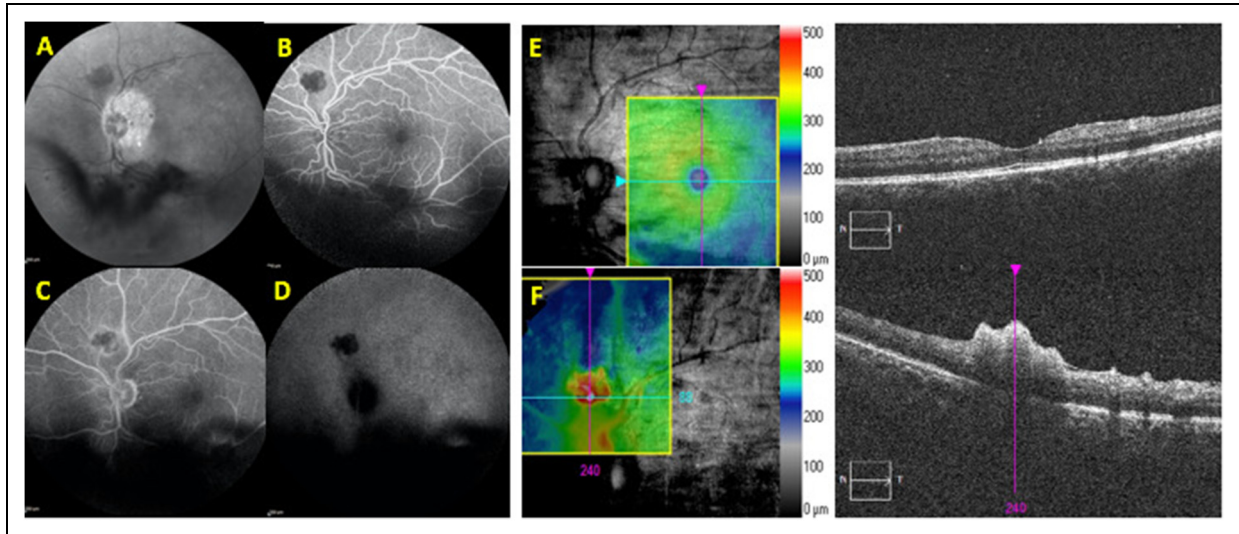
At fluorescein angiography (FA) the retinal lesions presented early hypofluorescence and late leakage (Figure 1-C and Figure 2-B, C), while at indocyanine green angiography (ICGA) the chorioretinal lesions remained hypofluorescent in both early and late phases (Figure 1-D and Figure 2-D). Spectral domain optical coherence tomography (SD-OCT) showed full-thickness hyper-reflective retinal infiltrates protruding into the vitreous and back-shadowing, at the mid-periphery of the retinal and in the juxta-papillary area in OU (Figure 1-E, F and Figure 2-E, F).

Full serological screening for infection was done, including blood cultures, *Toxoplasma gondii*, Quantiferon TB Gold test, VDRL/TPHA, *Herpes simplex virus* (HSV1-2-6), *Varicella zoster virus* (VZV), cytomegalovirus (CMV), Epstein-Barr virus (EBV), and HIV. An AC tap was taken and analyzed by polymerase chain reaction (PCR) for HSV-1, 2, 6, *Toxoplasma gondii*, and CMV. All of them turned out negative. Nasal swab for SARS-CoV-2 PCR resulted negative.

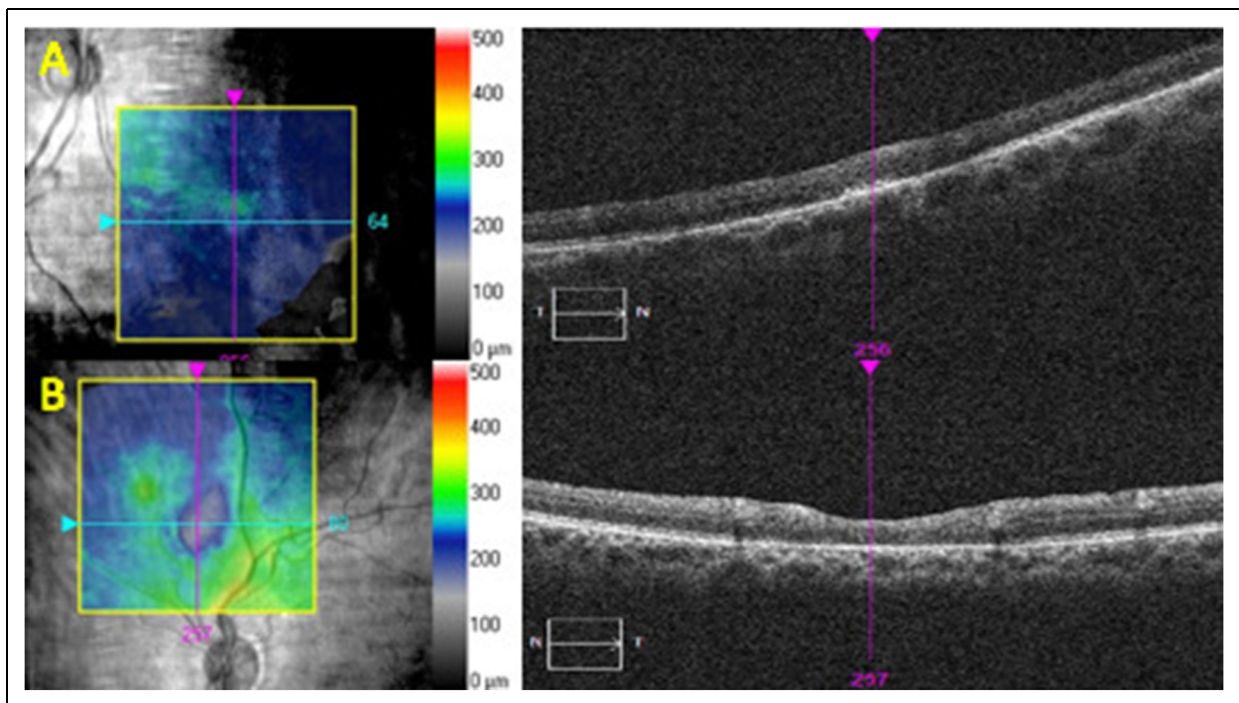
At that stage we suggested a diagnostic vitrectomy, but the patient refused the proposal for a possible SARS-Cov-2 reinfection concern. In addition, access to the operating room was very limited during the first lockdown which made the procedure unfeasible.



**Figure 1.** Right eye of 56-year-old man at baseline: infra-Red (IR) images showed vitreous opacities and hyperreflective lesion in the infero-nasal sector (A, B). At Fluorescein angiography (FA) examination the retinal lesion presented early hypofluorescence (C) while at indocyanine green angiography (ICGA) the chorioretinal lesions remained hypofluorescent in all the phases of the exam (D). Spectral domain-optical coherence tomography (SD-OCT) showed normal macular thickness with vitreous opacities and full-thickness hyper-reflective retinal infiltrates protruding into the vitreous and back-shadowing, at the mid-periphery of the retinal and in the juxta-papillary area (E, F).



**Figure 2.** Left eye of 56-year-old man at baseline: IR images showed lower vitreous opacities and hyperreflective lesion in the juxta-papillary region (A). An early hypofluorescence and late leakage was detected at FA (B, C), while a late hypofluorescence was observed at ICGA (D). SD-OCT showed tiny vitreous hyperreflective opacities in the macular region and “string of pearls” vitreous clot in the super-nasal sector (E, F).



**Figure 3.** Both eyes (OU) of 56-year-old man at 3 months-follow-up: SD-OCT showed atrophic scars with no active lesions in the juxta-papillary region (A,B).

However, based on patient’s history, clinical characteristics and multimodal imaging hallmarks, a clinical suspect of presumed candida endophthalmitis was done, according to the Uveitis Service of Cleveland Clinic Abu Dhabi consultation.

Therefore, the patient started intravenous liposomal amphotericin B (Ambisome™) 5 mg/kg/day, planned for 3 weeks. At one-week follow-up BCVA had improved to 20/50 in RE and 20/20 in LE. AS and AC inflammatory biomarkers all showed improvements, with both cells

and flare of +1 OU. The BIO score improved to +1. Treatment was extended for further 3 weeks.

One month later the patient was discharged and prescribed oral Fluconazole 200 mg twice a day. SARS-Cov-2 swab and blood cultures were negative. At 1 month after his discharge, the BCVA remained stable in OU, with no evidence of active endophthalmitis. Furthermore, vitreitis was reduced, with an evident improvement of the chorioretinal lesions. At 3 months follow-up, BCVA was 25/20 in RE and 20/20 in LE. Moreover, vitreous opacities sub-optimally solve with no relevance to the BCVA and full thickness retinal lesions turned into atrophic scars (Figure 3-A,B). The antifungal therapy, based on Fluconazole 200 mg twice a day, was consequently interrupted and the patient is currently on follow-up.

## Discussion

Since COVID-19 outbreak began, the large numbers of patients requiring hospitalization and mechanical ventilation, represented the main driver of possible superimposed infections, particularly fungal related ones.<sup>6,7</sup> Although no obvious dysregulation of the immune system has been identified in SARS-Cov-2 patients, the use of immunosuppressive drugs for severe cases and CVC, combined with the severe pulmonary damage, led to an increasing number of opportunistic infections. A recent study from Italy reported a significant number of *Candida albicans* endophthalmitis among SARS-Cov-2 patients treated with Tocilizumab for HLH.<sup>8</sup>

The case described here is characterized by a superimposed infection threatening the visual acuity, while the logistic hardships created by the pandemic limited the range of action for complicated cases. More specifically, the lockdown severely affected the access to surgical facilities and, consequently, to specific molecular tests necessary for the diagnosis. Providers were forced to rely on clinical hallmarks, as well as multimodal imaging techniques in order to make the correct diagnosis and rule out potential COVID eye involvement. Intubation and mechanical ventilation for SARS-CoV-2 ARDS were described as main drivers of possible superimposed infections, particularly fungal related ones as described in scientific literature.<sup>6</sup> Moreover, the compromised clinical status of the patient consequent to the use of immunosuppressive drugs for COVID-19 and of CVC, combined with the severe pulmonary damage, could led to an opportunistic infection. Therefore, multimodal imaging and serological tests helped us to rule out several pathogens, performing a presumptive diagnosis of candida endophthalmitis.

*Candida* endophthalmitis is frequently bilateral, although it may have a unilateral onset.<sup>9</sup> Our patient presented typical clinical hallmarks such as vitreitis, “string of pearls” vitreous opacities, retinal lesions with the characteristic “rain-cloud

sign” in both eyes and obvious risk factors that represent the typical identikit for endogenous *Candida* infection. Furthermore, SD-OCT findings, deeply described in scientific literature in the last few years, helped us to better clarify the nature of retinal lesions.<sup>10</sup> Indeed, the rain-cloud lesions are strongly suggestive for candida etiology.<sup>10</sup> As our case, in candida endophthalmitis, blood cultures are usually negative and only a minority of the cases affected result positive. Moreover, aqueous and vitreous samples have a poor sensitivity in these cases.<sup>11</sup>

The suspect diagnosis was also confirmed by the high qualified center of Abu Dhabi involved in the discussion board and therefore, since our clinical hypothesis was also supported by the peculiar clinical features, we promptly started amphotericin B rescue treatment.<sup>12</sup> The progressive obvious improvement both in terms of symptoms and clinical status, made us confident that the diagnosis of presumed *Candida* endophthalmitis might have been correct. It is likely that different species of *Candida* such as *albicans* or *parapsilosis* or another types of fungi might have a good response to amphotericin and fluconazole. However, the patient’s visual acuity improvement represented a challenge and a great result for us in a historical moment in which the medical team feared a potential COVID-19 ocular involvement, still not well known, and at the same it had suddenly felt deprived of diagnostic tools which in other conditions would have been free accessible.

The take-home message might be the following: during the pandemic, semeiology, collegial discussion, and multimodal imaging are the main clinical weapons in our armamentarium. Although that might appear an old-fashioned strategy, the pandemic still forces many physicians worldwide to adhere to such a methodology, although the introduction in the market of effective vaccines for SARS-Cov-2 is opening a chink for a return to gold standard of care, hopefully as soon as possible.

## Statement of ethics



Written informed consent was obtained from the patient for the preparation of this work (including publication of images).

## Declaration of conflicting interests

The author(s) declared no potential conflicts of interest with respect to the research, authorship, and/or publication of this article.

## Funding

The author(s) received no financial support for the research, authorship, and/or publication of this article.

**ORCID iDs**Federica Fossataro  <https://orcid.org/0000-0001-5798-1899>Piergiorgio Neri  <https://orcid.org/0000-0002-7673-4276>**References**

1. Zhu N, Zhang D, Wang W, et al. A novel coronavirus from patients with pneumonia in China, 2019. *N Engl J Med* 2020; 382: 727–733.
2. Zhou P, Yang XL, Wang XG, et al. A pneumonia outbreak associated with a new coronavirus of probable bat origin. *Nature* 2020; 579: 270–273.
3. Opoka-Winiarska V, Grywalska E and Roliński J. Could hemophagocytic lymphohistiocytosis be the core issue of severe COVID-19 cases? *BMC Med* 2020 Jul 15; 18: 14. PMID: 32664932; PMCID: PMC7360379.
4. Gangneux JP, Bougnoux ME, Dannaoui E, et al. Invasive fungal diseases during COVID-19: we should be prepared. *J Mycol Med* 2020 Jun; 30: 100971.
5. Jabs DA, Nussenblatt RB and Rosenbaum JT, Standardization of Uveitis Nomenclature (SUN) Working Group. Standardization of uveitis nomenclature for reporting clinical data. Results of the first international workshop. *Am J Ophthalmol.* 2005 Sep;140: 509–516.
6. Arastehfar A, Carvalho A, Njuyen MH, et al. COVID-19-Associated candidiasis (CAC): an underestimated complication in the absence of immunological predispositions? *J Fungi (Basel)* 2020 Dec; 6: 211.
7. Agarwal M, Sachdeva M, Pal S, et al. Endogenous endophthalmitis a complication of COVID-19 pandemic: a case series. *Ocul Immunol Inflamm* 2021 May 19; 29: 726–729.
8. Antinori A, Bonazzetti C and Gubertini G. Tocilizumab for cytokine storm syndrome in COVID-19 pneumonia: an increased risk for candidemia? *Autoimmun Rev* 2020 Jul; 19: 102564.
9. Edwards JEJR, Foos RY, Montgomerie JZ, et al. Ocular manifestations of Candida septicemia: review of seventy-six cases of hematogenous Candida endophthalmitis. *Medicine (Baltimore)* 1974; 53: 47–75.
10. Invernizzi A, Symes R, Miserocchi E, et al. Spectral domain optical coherence tomography findings in endogenous candida endophthalmitis and their clinical relevance. *Retina* 2018 May; 38: 1011–1018.
11. Shah CP, McKey J, Spirm MJ, et al. Ocular candidiasis: a review. *Br J Ophthalmol* 2008; 92: 466–468.
12. Pappas PG, Kauffman CA, Andes DR, et al. Clinical practice guideline for the management of candidiasis: 2016 update by the infectious disease society of America. *Clin Infect Dis* 2016 Feb 15; 62: e1–e50.