



Ossification of the ligamentum flavum in the thoracic spine mimicking sciatica in a young baseball pitcher : a case report

Kinshi Kato¹⁾, Shoji Yabuki¹⁾, Koji Otani¹⁾, Takuya Nikaido¹⁾, Ken-ichi Otoshi¹⁾²⁾,
Kazuyuki Watanabe¹⁾, Shin-ichi Kikuchi¹⁾ and Shin-ichi Konno¹⁾

¹⁾Department of Orthopaedic Surgery, Fukushima Medical University School of Medicine, Fukushima City, Fukushima, Japan, ²⁾Department of Sport Medicine, Fukushima Medical University School of Medicine, Fukushima City, Fukushima, Japan

(Received December 14, 2020, accepted February 4, 2021)

Abstract

Thoracic ossification of the ligamentum flavum (OLF) is a pathological condition that causes myelopathy, with unilateral lower extremity pain rarely a feature in the presenting complaint. Moreover, most symptomatic cases of thoracic OLF occur in middle-aged men, with younger individuals rarely affected. We present a rare case of severe and chronic unilateral buttock and leg pain mimicking sciatica due to thoracic OLF in a professional baseball pitcher. A 28-year-old, right-handed, Japanese professional baseball pitcher experienced intractable left leg pain with numbness and spasticity. After the initial presentation, extensive testing focusing on lumbar, hip, and pelvis lesions failed to identify a cause for the pain. One year after onset, careful neurological examination showed signs of upper motor neuron disturbance, and thoracic computed tomography and magnetic resonance imaging revealed thoracic OLF at the level of the thoracolumbar junction. After resection of the thoracic OLF, the pain, numbness, and spasticity completely resolved. He resumed full training and was pitching in top condition within four months after surgery. Though rare, thoracic OLF should be considered in the differential diagnosis of lower extremity pain in young athletes, especially amongst high-level baseball pitchers.

Key words : thoracic spine, ossification of the ligamentum flavum, sciatica, baseball, athlete

Introduction

Thoracic ossification of the ligamentum flavum (OLF) has been widely recognized as a possible cause of thoracic myelopathy, whereas unilateral lower extremity pain is rare as part of the presenting complaint^{1,2)}. In addition, as most surgical cases of thoracic OLF occur in middle-aged men, patients in their 20s are extremely rare³⁻¹¹⁾. The pathogenesis of OLF is still not fully understood, but repeated mechanical stress might influence the development of OLF in younger patients^{12,13)}. To the best of our knowledge, there are no reports describing young athletes with chronic unilateral lower extremity pain due to thoracic OLF.

We report herein a case of buttock and posterior thigh pain and numbness mimicking sciatica due to thoracic OLF in a young Japanese professional baseball pitcher.

Case presentation

A 28-year-old, right-handed, Japanese professional baseball pitcher was referred to our hospital because of a one-year history of intractable left leg pain with numbness and spasticity. He had no history of past spinal injury, spinal operation, systemic disorders, nor a family history of ossification of the posterior longitudinal ligament or ligamentum flavum. One year earlier, he had felt left buttock and

Corresponding author : Kinshi Kato, M.D., Ph.D. E-mail : kinshi@fmu.ac.jp

©2021 The Fukushima Society of Medical Science. This article is licensed under a Creative Commons [Attribution-NonCommercial-ShareAlike 4.0 International] license.
<https://creativecommons.org/licenses/by-nc-sa/4.0/>

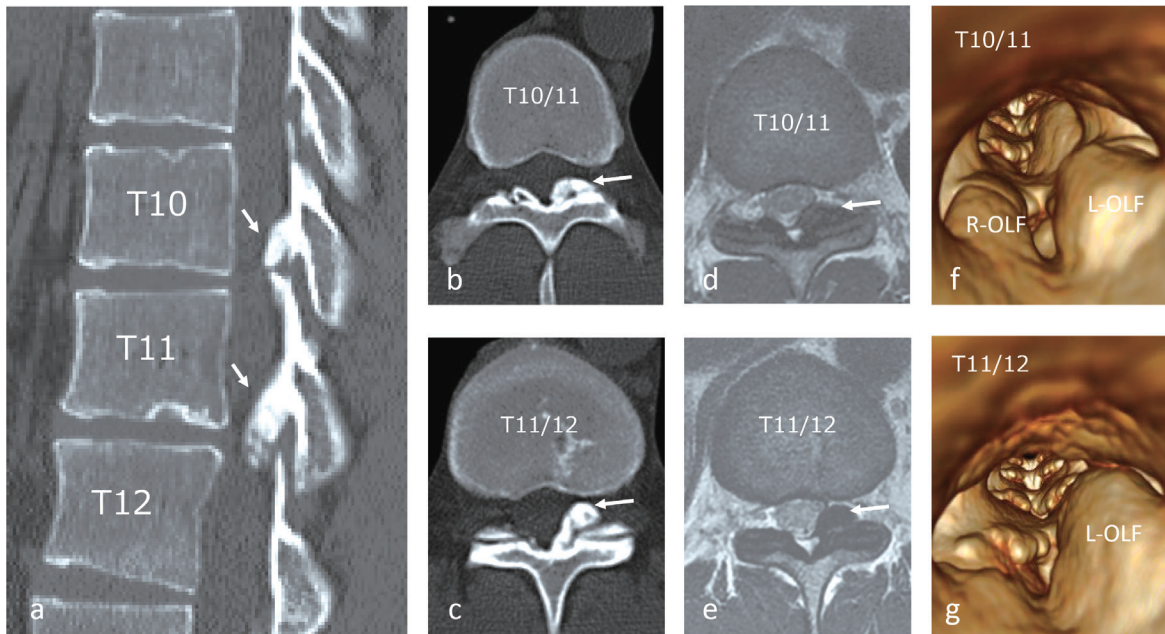


Figure 1. Sagittal (a), axial at T10/11 (b), and T11/12 (c) computed tomography (CT) scan revealing the presence of OLF (arrows). Axial T2-weighted magnetic resonance imaging (MRI) demonstrated dural tube compression by OLF situated postero-laterally at T10/11 (d) and T11/12 (e) levels. 3D-CT (spinal canal view at T10/11(f) and T11/12(g)) of the thoracic spine showing the stenosis of the spinal canal.

posterior thigh pain while pitching during a game and became aware of increasing muscle tightness in the left leg a month later. Several doctors had evaluated his condition with no obvious abnormality on physical examination or on imaging of the lumbar spine identified, including on x-ray, computed tomography (CT), magnetic resonance imaging (MRI), and bone scintigraphy. Although he was able to continue pitching in games during the season by taking non-steroidal anti-inflammatory drugs, the pain gradually increased, and he started to feel spasticity and numbness in the left leg before his first visit to our hospital.

Neurological examination revealed no muscle weakness or sensory disturbance other than loss of the left cremaster reflex and increased deep tendon reflexes of the left lower extremity. No bowel, bladder, or sexual dysfunction was identified. No pathological physical findings were found on examining the hip and sacroiliac joints. CT and MRI of the thoracic spine revealed left unilateral OLF at the T10-T11 and T11-T12 levels with marked compression of the dural tube (Figure 1). According to these findings, unilateral thoracic myelopathy due to OLF was suspected, and spinal decompression of the thoracic spine was planned. At surgery, posterior decompression at the level of T10-11 and T11-12 was performed. By three weeks after surgery, the left leg pain and numbness had entirely resolved.

The patient started physical exercise 3 weeks after surgery and gradually increased the intensity. He experienced no further symptoms during rehabilitation, including to the level of full training. He resumed full training and was pitching in top condition by four months after surgery.

Discussion

In this report, we present a rare case of severe and chronic unilateral buttock and posterior thigh pain mimicking sciatica due to thoracic OLF in a professional baseball pitcher. Three crucial clinical issues require attention. First, thoracic OLF can cause unilateral lower extremity pain in athletes. Second, detailed neurological examination and imaging including the thoracic spine is necessary for the diagnosis of this condition. Third, high-level baseball pitchers might be at particularly high risk of symptomatic thoracic OLF.

Buttock and posterior thigh pain, including sciatica, is relatively common in athletes. Assessing any reported buttock and posterior thigh pain in athletes should always first try to ascertain involvement from the lumbar spine¹⁴. In addition, clinicians must differentiate hip, pelvis, and sacroiliac joint disorders, hamstring origin tendinopathy, and muscle strain by evaluating physical and imaging findings¹⁴. In this case, physical examination and

Table 1. Published cases of athletes with thoracic OLF (compared with this case).

Author	Age	Sex	Level/shape	Nationality	Sports	Symptoms	Treatment	Outcome	
Kaneyama <i>et al.</i>	Case 1	28	M	T10/11 Left unilateral	Japanese	Baseball (pitcher) Right-handed	Weakness in ipsilateral leg Numbness on soles of both feet Frequent urination	Surgical resection	Improved
	Case 2	24	M	T10/11 Left unilateral T11/12 Left unilateral	Japanese	Baseball (pitcher) Right-handed	Weakness in ipsilateral leg	Surgical resection	Improved ; Returned to play
Tadokoro <i>et al.</i>		28	M	T6/7 Bilateral T11/12 Left unilateral	Japanese	Baseball (pitcher) Right-handed	Weakness in both leg Numbness in ipsilateral leg Bladder and bowel dysfunction	Surgical resection and posterior minimally invasive spine stabilization	Improved ; Returned to play (as a fielder)
This case		28	M	T10/11 Left unilateral T11/12 Left unilateral	Japanese	Baseball (pitcher) Right-handed	Pain in Ipsilateral buttock, thigh	Surgical resection	Improved ; Returned to play

imaging studies did not suggest these disorders.

Thoracolumbar junction lesions can present with a variety of signs and symptoms, including sciatica, due to the complexity of the spinal cord, cauda equina, and nerve roots^{15,16}. Amongst the few reports on pain mimicking sciatica caused by thoracic cord compressive lesions¹⁷⁻¹⁹, two cases have shed some light on unilateral lower extremity pain mimicking sciatica that results from disc herniation at the lower thoracic spine (T10-11 and T11-12 levels, respectively)^{20,21}. Unilateral lower extremity pain is known to be uncommon among patients with thoracic OLF, but at least one case report has suggested that unilateral OLF at the thoracolumbar junction might cause unilateral lower extremity pain in athletes¹². Since the lower thoracic segment of T10-11 is the most frequently affected segment²²⁻²⁴, OLF at this region could compress the lumbosacral nerves after their exit from the lumbar enlargement of the spinal cord, which would cause pain radiating through the lower extremity²¹.

Since thoracolumbar junction lesions present with a variety of signs and symptoms, detailed neurological examination and imaging are necessary for the diagnosis of this condition. In our case, loss of left cremaster reflex, posterior hamstring tightness, and increased deep tendon reflexes of the ipsilateral lower extremities were the only abnormal findings which led to suspicion of upper neuron disturbance at the L1 to L2 spinal cord segments. The cremasteric reflex is generally maintained in healthy young adults^{25,26}. Radiographic assessment of the thoracolumbar junction is also important. Since routine

MRI protocols for the evaluation of a lumbar spinal lesion might not include the level of the lower thoracic region (especially the axial sections), MRI of the thoracic spine should be considered for athletes who complain of pain in the lower extremity with neurological deficits, especially when lumbar/hip/pelvis lesions have already been ruled out.

The pathogenesis of OLF is still not fully understood, but mechanical stress has been proposed as a cause of hypertrophy and OLF^{1,5,12,27,28}. High-level baseball pitchers reportedly experience a greater rotational angle of motion in the thoracolumbar spine of the non-throwing arm side compared to the throwing side²⁹. Kaneyama *et al.* describe repeated, localized, asymmetrical rotatory stress caused by pitching motions as potential influences on the unilateral development of OLF on the non-throwing side among high-level baseball pitchers¹². The repeated traction force might act unilaterally on the ligamentum flavum due to asymmetrical rotational flexion-extension movement of the thoracic spine^{12,13,27,28}. To the best of our knowledge, only 3 published cases have described symptomatic thoracic OLF in high-level young athletes (Table 1)^{12,13}. Interestingly, all cases involved Japanese males in their 20s, playing as high-level baseball pitchers, who unilaterally developed OLF on the non-throwing side at T10/11 and/or T11/12 levels. OLF appears relatively common in the East Asian population compared with the American and European populations^{1-4,22-24}. According to previous reports and our case, high-level Asian baseball players, especially pitchers, might represent a high-risk popu-

lation for symptomatic thoracic OLF in athletes. However, no reports have investigated the incidence of thoracic OLF in athletes. Further epidemiological study of thoracic OLF in athletes is therefore needed.

In conclusion, thoracic OLF can cause unilateral lower extremity pain in athletes, and detailed neurological examination and CT/MRI confirmation are useful for the diagnosis of this condition. Although relatively rare, thoracic OLF should be considered when lower extremity pain is seen in athletes with neurological deficit, especially among high-level baseball pitchers.

Consent

The patient described in this paper has given their informed consent for the case report to be published.

Conflict of interest

The authors declare that there is no conflict of interest regarding the publication of this paper.

References

1. Yonenobu K, Ebara S, Fujiwara K, *et al.* Thoracic myelopathy secondary to ossification of the spinal ligament. *J Neurosurg*, **66** : 511-518, 1987.
2. Okada K, Oka S, Tohge K, *et al.* Thoracic myelopathy caused by ossification of the ligamentum flavum. Clinicopathologic study and surgical treatment. *Spine (Phila Pa 1976)*, **16** : 280-287, 1991.
3. Sato T, Kokubun S, Tanaka Y, *et al.* Thoracic myelopathy in the Japanese : epidemiological and clinical observations on the cases in Miyagi Prefecture. *Tohoku J Exp Med*, **184** : 1-11, 1998.
4. Shiokawa K, Hanakita J, Suwa H, *et al.* Clinical analysis and prognostic study of ossified ligamentum flavum of the thoracic spine. *J Neurosurg*, **94** : 221-226, 2001.
5. Liao CC, Chen TY, Jung SM, *et al.* Surgical experience with symptomatic thoracic ossification of the ligamentum flavum. *J Neurosurg Spine*, **2** : 34-39, 2005.
6. Aizawa T, Sato T, Sasaki H, *et al.* Thoracic myelopathy caused by ossification of the ligamentum flavum : clinical features and surgical results in the Japanese population. *J Neurosurg Spine*, **5** : 514-519, 2006.
7. Sun X, Sun C, Liu X, *et al.* The frequency and treatment of dural tears and cerebrospinal fluid leakage in 266 patients with thoracic myelopathy caused by ossification of the ligamentum flavum. *Spine (Phila Pa 1976)*, **37** : E702-707, 2012.
8. Ando K, Imagama S, Ito Z, *et al.* Predictive factors for a poor surgical outcome with thoracic ossification of the ligamentum flavum by multivariate analysis : a multicenter study. *Spine (Phila Pa 1976)*, **38** : E748-754, 2013.
9. Yu S, Wu D, Li F, *et al.* Surgical results and prognostic factors for thoracic myelopathy caused by ossification of ligamentum flavum : posterior surgery by laminectomy. *Acta Neurochir (Wien)*, **155** : 1169-1177, 2013.
10. Zhao Y, Xue Y, Shi N, *et al.* The CT and intraoperative observation of pedicle-ossification tunnel in 151 cases of thoracic spinal stenosis from ossification of ligamentum flavum. *Eur Spine J*, **23** : 1325-1331, 2014.
11. Feng F, Sun C, Chen Z. A diagnostic study of thoracic myelopathy due to ossification of ligamentum flavum. *Eur Spine J*, **24** : 947-954, 2015.
12. Kaneyama S, Doita M, Nishida K, *et al.* Thoracic myelopathy due to ossification of the yellow ligament in young baseball pitchers. *J Spinal Disord Tech*, **21** : 68-71, 2008.
13. Tadokoro Y, Tokioka T, Hayashi T. A case report of thoracic vertebrae ossification of ligamentum flavum in adult baseball pitcher. (in Japanese) *J C-S Orthop Assoc*, **29** : 209-213, 2017.
14. Brukner P, Khan K. Buttock pain. Brukner P, Khan K, editors. *In : Clinical Sports Medicine*. Sydney, Australia, McGraw-Hill, 745-747, 2012.
15. Tokuhashi Y, Matsuzaki H, Uematsu Y, *et al.* Symptoms of thoracolumbar junction disc herniation. *Spine (Phila Pa 1976)*, **26** : E512-518, 2001.
16. Fujimoto K, Kanchiku T, Imajo Y, *et al.* Neurologic findings caused by ossification of ligamentum flavum at the thoracolumbar junction. *J Spinal Cord Med*, **40** : 316-320, 2016.
17. Scott M. Lower extremity pain simulating sciatica ; tumors of the high thoracic and cervical cord as causes. *J Am Med Assoc*, **160** : 528-534, 1956.
18. Ito T, Homma T, Uchiyama S. Sciatica caused by cervical and thoracic spinal cord compression. *Spine (Phila Pa 1976)*, **24** : 1265-1267, 1999.
19. Cho HL, Lee SH, Kim JS. Thoracic disk herniation manifesting as sciatica-like pain—two case reports. *Neurol Med Chir (Tokyo)*, **51** : 67-71, 2011.
20. Balagué F, Fankhauser H, Rosazza A, *et al.* Unusual presentation of thoracic disc herniation. *Clin Rheumatol*, **8** : 269-273, 1989.
21. Lyu RK, Chang HS, Tang LM, *et al.* Thoracic disc herniation mimicking acute lumbar disc disease. *Spine (Phila Pa 1976)*, **24** : 416-418, 1999.

22. Mori K, Kasahara T, Mimura T, *et al.* Prevalence, distribution, and morphology of thoracic ossification of the yellow ligament in Japanese : results of CT-based cross-sectional study. *Spine (Phila Pa 1976)*, **38** : E1216-1222, 2014.
23. Moon BJ, Kuh SU, Kim S, *et al.* Prevalence, distribution, and significance of incidental thoracic ossification of the ligamentum flavum in Korean patients with back or leg pain : MR-based cross sectional study. *J Korean Neurosurg Soc*, **58** : 112-118, 2015.
24. Guo JJ, Luk KD, Karppinen J, *et al.* Prevalence, distribution, and morphology of ossification of the ligamentum flavum : a population study of one thousand seven hundred thirty-six magnetic resonance imaging scans. *Spine (Phila Pa 1976)*, **35** : 51-56, 2010.
25. Caesar RE, Kaplan GW. The incidence of the cremasteric reflex in normal boys. *J Urol*, **152** : 779-780, 1994.
26. Schwarz GM, Hirtler L. The cremasteric reflex and its muscle—a paragon of ongoing scientific discussion : a systematic review. *Clin Anat*, **30** : 498-507, 2017.
27. Maigne JY, Ayrat X, Guérin-Surville H. Frequency and size of ossifications in the caudal attachments of the ligamentum flavum of the thoracic spine. Role of rotatory strains in their development. An anatomic study of 121 spines. *Surg Radiol Anat*, **14** : 119-124, 1992.
28. Tsukamoto N, Maeda T, Miura H, *et al.* Repetitive tensile stress to rat caudal vertebrae inducing cartilage formation in the spinal ligaments : a possible role of mechanical stress in the development of ossification of the spinal ligaments. *J Neurosurg Spine*, **5** : 234-242, 2006.
29. Laudner K, Lynall R, Williams JG, *et al.* Thoracolumbar range of motion in baseball pitchers and position players. *Int J Sports Phys Ther*, **8** : 777-783, 2014.