

Case report

<https://doi.org/10.6065/apem.2142100.050>
Ann Pediatr Endocrinol Metab 2022;27:315-319



Adrenocortical carcinoma and a sporadic *MEN1* mutation in a 3-year-old girl: a case report

Sung Eun Kim¹,
Na Yeong Lee¹,
Won Kyoung Cho¹,
Jisook Yim²,
Jae Wook Lee¹,
Myungshin Kim²,
Jae Hee Chung³,
Min Ho Jung¹,
Byung-Kyu Suh¹,
Moon Bae Ahn¹

¹Department of Pediatrics, College of Medicine, The Catholic University of Korea, Seoul, Korea

²Department of Laboratory Medicine, College of Medicine, The Catholic University of Korea, Seoul, Korea

³Department of Surgery, College of Medicine, The Catholic University of Korea, Seoul, Korea

Childhood adrenocortical carcinoma (ACC) is a rare disease that is mostly linked to familial cancer syndrome. Although the prevalence of ACC is extremely low in children, it is clinically important to diagnose ACC early because age and tumor stage are closely related to prognosis. From this perspective, understanding the underlying genetics and possible symptoms of ACC is crucial in managing ACC with familial cancer syndromes. In this report, we present the case of a 3-year-old girl who initially presented with symptoms of precocious puberty and was later found to have ACC by imaging analysis. On genetic analysis, the patient was found to have a *MEN1* gene mutation. *MEN1* mutations are found in patients with multiple endocrine neoplasia type 1 (MEN1), usually precipitating multiple endocrine tumors, including pituitary adenoma, parathyroid hyperplasia, and adrenal tumors. Although *MEN1* mutation is usually inherited in an autosomal dominant manner, neither of the patient's parents had the same mutation, making hers a case of sporadic *MEN1* mutation with initial presentation of ACC. The clinical course and further investigations of this patient are discussed in detail in this report.

Keywords: Adrenocortical carcinoma, Adrenal gland neoplasm, Multiple endocrine neoplasia, Precocious puberty

Highlights

- Multiple endocrine neoplasia type 1 is a rare syndrome involving multiple endocrine organs. Clinical importance of this hereditary syndrome is addressed through this case report, a first report of childhood adrenocortical carcinoma with MEN1 mutation in Korea.

Introduction

Multiple endocrine neoplasia type 1 (MEN1), first identified in the 1900s, is a rare, hereditary syndrome characterized by multiple endocrine and non-endocrine tumors.¹⁾ Genetically, MEN1 is inherited in an autosomal dominant manner, showing a high degree of penetrance. By inactivating mutations in the tumor suppressor gene *MEN1*, this syndrome manifests multiple endocrine problems such as parathyroid hyperplasia, pituitary adenoma, and tumors that originate from the pancreas and adrenal glands. By age 40 years, almost 90% of patients with MEN1 develop parathyroid hyperplasia and/or tumors, 40% have pituitary adenomas, and 70%–80% develop tumors that originate from the pancreas or gastrointestinal organs.²⁾ Data of young patients with MEN1 are limited since this syndrome is rare and manifests mainly in adults. A cohort study of 924 young patients with MEN1 reported that 17% developed MEN1-associated tumors before 21 years of age, mostly diagnosed after 10 years of age with increasing disease penetrance.³⁾ Among them, only 2 patients had adrenal tumors, with very low disease penetrance in the adrenal gland in children.

Received: 3 May, 2021
Revised: 1 June, 2021
Accepted: 22 June, 2021

Address for correspondence:

Moon Bae Ahn
Department of Pediatrics, College of Medicine, The Catholic University of Korea, 222 Banpo-daero, Seocho-gu, Seoul 06591, Korea
Email: mbahn@catholic.ac.kr
<https://orcid.org/0000-0003-1108-2788>

This is an Open Access article distributed under the terms of the Creative Commons Attribution Non-Commercial License (<http://creativecommons.org/licenses/by-nc/4.0>) which permits unrestricted non-commercial use, distribution, and reproduction in any medium, provided the original work is properly cited.

ISSN: 2287-1012(Print)
ISSN: 2287-1292(Online)

With regard to adrenal tumors, including adrenocortical carcinoma (ACC), approximately 80%–90% of children with adrenal tumors have hyperfunctioning adrenal glands, producing excess sex and steroid hormones such as cortisol, aldosterone, and testosterone.⁴⁾ Patients with ACC commonly have cushingoid features such as central obesity and a moon face. Due to excess testosterone, female patients with ACC may experience virilization with ambiguous genitalia and hirsutism. Patients seldom have hypertension with increased aldosterone level. Sometimes, tumors are detected due to increased size, causing abdominal pain by occupying the peritoneal space. Adrenal tumors are usually detected by ultrasonography, computed tomography (CT), or magnetic resonance imaging (MRI), although the final diagnosis of ACC can only be made on biopsy. ACC tends to occur in several familial cancer syndromes, and specific gene mutations in *TP53*, *MEN1*, *PRKARIA*, and *APC* are well-known causes of ACC.⁵⁾ The *TP53* (on chromosome 17p13.1) mutation is responsible for 50%–80% of ACC in children.⁶⁾ In southern Brazil, children with this mutation have a 15-fold increased incidence of childhood adrenocortical tumors.⁷⁾

A relatively low incidence rate has been reported in adrenocortical tumors (<40%) compared to other endocrine organ tumors in MEN1.²⁾ Among adrenal tumors in MEN1 patients, ACC is rarer in children; however, early detection of ACC is important because it is characterized by aggressive malignancy. Approximately 10% of MEN1 patients have adrenocortical tumors, and only 14% of these adrenocortical tumors are malignant.

To date, there have been 15 cases of MEN1 in Korea, among which only one study reported MEN1 in a child.⁸⁾ The current case report describes a 3-year-old girl who presented with precocious puberty due to functional ACC. Upon genetic investigation, although the patient was found to have a *MEN1* gene defect, neither of her parents had the same mutation. In this case report, the clinical course of the 3-year-old patient with *de novo MEN1* mutation is presented, and the significance of the findings are discussed.

Case report

A 3-year-old girl visited the endocrinologic outpatient clinic in our pediatric department with a chief complaint of precocious puberty. She had acne, early developmental pubic hair, and her voice had started to deepen 3 months before the initial visit. She was born at a gestational age of 40 weeks, weighing 3.5 kg, and had no perinatal problems. The patient experienced no other medical issues before her initial visit to the hospital. The patient's parents also had no medical issues. Heights of her father and mother were 177 cm and 168 cm, respectively.

Anthropometric and physical examinations were performed during the first visit. The patient's blood pressure and heart rate were within the normal reference range. The patient's height was 109.3 cm (>97th percentile, +3.12 standard deviation [SD]) and body weight was 21.2 kg (>97th percentile, +3.95 SD).⁹⁾ The acneiform eruption was in the forehead area. Although the patient did not present with breast budding, there were several strands of pubic hair observed. The patient had suspiciously ambiguous genitalia with clitoral enlargement (Prader grade 2). The vagina was observed, and there was no palpable testis in the genitalia. No palpable mass was observed in the abdomen.

Hormonal and chromosomal studies were conducted to evaluate precocious puberty and ambiguous genitalia. Although biochemical assessment revealed normal electrolytes, the patient had pronounced elevation of adrenal androgens

Table 1. Changes in adrenal hormones level before and after surgery of adrenocortical carcinoma

Adrenal hormones	Reference	Preoperative	Postoperative (postop. date #13)
Aldosterone (pg/mL)	30–350	446.88	207.24
Cortisol	3–21	5.75	12.74
DHEA-S (μg/dL)	5–57	1469.99	7.67
Androstenedione (ng/mL)	0.08–0.5	>10.10	0.11
Estradiol (pg/mL)	<15	34.33	13.88
Testosterone (ng/mL)	0.03–0.1	3.22	0.03

DHEA-S, dehydroepiandrosterone-sulfate.

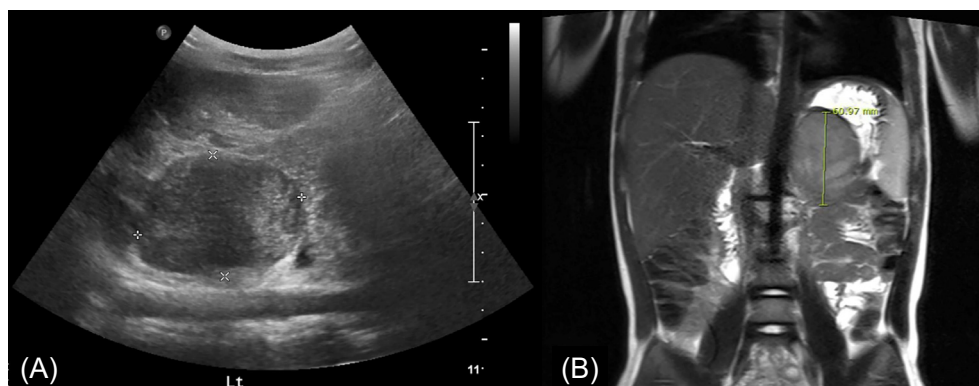


Fig. 1. A well circumscribed, poorly heterogeneously enhancing mass in the left adrenal gland was noted on abdominal ultrasonogram (A) and magnetic resonance imaging (B).

(Table 1). Serum testosterone was 3.22 ng/mL (reference range [RR], 0.02–0.1 ng/mL) and serum dehydroepiandrosterone-sulfate (DHEA-S) was 1,469 µg/dL (RR, <65 µg/dL). Elevated levels of serum 17-hydroxyprogesterone (17-OHP) (4.11 ng/mL; RR, 0.03–0.9 ng/mL) and serum androstenedione (>10.10 ng/mL; RR, <0.42 ng/mL) were also observed. Conversely, follicle-stimulating hormone, luteinizing hormone, adrenocorticotrophic hormone, and cortisol levels were within the normal range with respect to sex and age. Chromosome analysis revealed a normal female karyotype, i.e., 46,XX.

Radiologic findings showed advanced precocious puberty. Her bone age was 11 years, preceding her chronological age by nearly 8 years. Abdominal sonography revealed a mass-like lesion in the left adrenal gland (Fig. 1A), and MRI showed a 6.1×5.3×4.4-cm, well circumscribed, and heterogeneously enhancing mass in the left adrenal gland (Fig. 1B). Evaluation of metastasis using positron emission tomography-CT was performed, and no definite metastasis was found. At this point, a provisional diagnosis of ACC or adenoma was made.

After investigating metastasis, laparoscopic resection of the left adrenal gland with the tumor mass was performed. The resected mass was an encapsulated round mass measuring 6.0×5.5×4.4 cm in dimension and weighing 85.4 g (Fig. 2). The tumor cells in the specimen had low-grade nuclear atypia and low mitotic activity (1/10 high-power fields). Necrosis and capsular invasion were absent; however, venous invasion was present (>4 foci). A low-grade oncocytic variant of ACC was confirmed by pathologists. According to the Lin-Weiss-Bisceglia criteria, venous invasion of the oncocytic variant is a major criterion; therefore, the tumor was diagnosed as a malignant carcinoma.¹⁰ Two weeks after resecting the adrenal tumor, the patient's serum testosterone, DHEA-S, 17-OHP, and androstenedione levels decreased dramatically to within the normal range (Table 1). The patient was referred to a pediatric oncologist for postsurgical treatment. The patient did not undergo postoperative chemotherapy for recurrence since no metastatic features were found and was followed up by endocrinologists, oncologists, and pediatric surgeons.

To determine the genetic etiology of ACC, targeted next generation sequencing was performed to identify genetic defects.

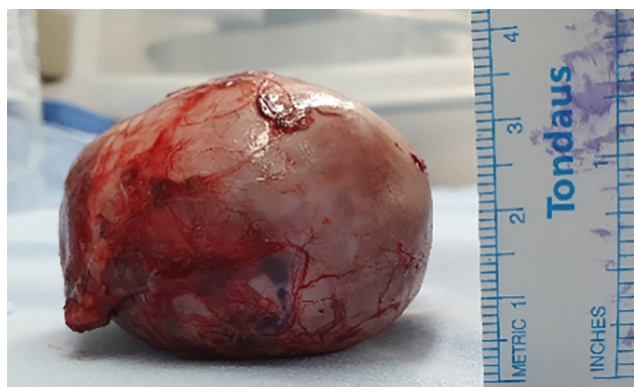

Fig. 2. Gross appearance of the resected mass.

Therefore, a genetic counseling session was conducted with the parents. Informed consent was obtained from the patient's parents, and genetic analyses were conducted. The molecular analyses revealed a heterozygous form of c.1298_1299delinsG (NM_000244.3) that led to the p.(Pro433Argfs*17), a novel frameshift mutation of *MEN1*. The gene mutation was confirmed by Sanger sequencing and presumed to be a likely pathogenic variant according to the American College of Medical Genetics and Genomics (ACMG) guidelines.¹¹ This form of mutation has not been previously reported in the literature. Neither of the patient's parents had the same gene mutation, suggesting that the patient's mutation was a sporadic, *de novo* mutation in *MEN1*.

Discussion

In this case report, we presented a 3-year-old girl with an atypical case of precocious puberty with virilization and advanced bone age, with no breast development. Abdominal imaging revealed a functioning mass in the left adrenal gland, which was later confirmed to be ACC by biopsy. Signs of virilization disappeared within one month after resecting the tumor. Through genetic evaluation to determine the etiology of ACC in this pediatric patient, a genetic mutation in *MEN1* was found, and it was a likely pathogenic variant. This mutation was not inherited from the patient's parents and was thus a *de novo* case.

Functioning ACC should be resected surgically, and complete resection is important for a favorable prognosis.¹² Owing to their highly malignant and invasive nature, many ACCs tend to recur within one year of tumor resection. Regular follow-ups with adrenal hormone tests and imaging studies for recurrence surveillance should be performed, usually every three months for the first year with interval increase thereafter.¹³ When ACC recurs, repetitive surgical resection is performed if possible, and adjuvant chemotherapy is usually administered.¹⁴ Previous studies have suggested the following favorable prognostic factors for ACC in children: age, <4 years; tumor size <10 cm; virilization alone; tumor volume <200 cm³; and early tumor stage with no metastasis.^{15,16} Patients younger than 4 years show remarkably favorable prognosis and do not require post-surgical chemotherapy.¹⁵ Fortunately, the present 3-year-old patient had features that were mostly favorable. Early diagnosis of ACC, before the age of 4 years, was crucial because ACC rapidly progresses and invades other organs. After complete excision of the mass, the patient did not undergo chemotherapy for remnant disease, and hormone levels were monitored regularly for surveillance of recurrence.

The gene mutation detected in this patient, however, indicated that ACC is not only a single sporadic disease but an abnormality of the endocrine physiology. Other endocrine diseases may manifest later in life. Regarding the clinical course of *MEN1*, this patient requires regular check-ups with a particular focus on the parathyroid gland, pituitary gland, pancreas, and other endocrine organs, including the adrenal

gland. Surveillance of neoplasms in nonendocrine organs, especially in the gastrointestinal tract, should be maintained for the rest of the patient's life. According to a surveillance guideline for MEN1 patients and carriers published in 2019,¹¹ parathyroid function (serum calcium and parathyroid hormone) should be checked annually until the age of 8 years. Anterior pituitary function (prolactin and insulin-like growth factor) should be checked till until age 5 years, with MRI performed every 3 years. Generally, adrenal tumors are not in the surveillance category unless patients have a functioning tumor or tumor size larger than 1 cm. Therefore, the present patient should follow the surveillance guidelines for ACC.

During our search on PubMed.gov, we found only five cases of childhood ACC reported in Korea. Among them, 3 cases reported treatment modalities and prognoses of ACC.^{14,17,18} Another was about virilizing ACC in Turner syndrome with a *TP53* gene mutation, and the last was a case of virilizing adrenocortical oncocytoma with borderline malignancy potential based on the Lin-Weiss-Bisceglia criteria.^{19,20} None of these previous cases had *MEN1* mutation, which makes the present case the first report of childhood ACC with *MEN1* mutation in Korea. In this case, *MEN1* mutation was a frameshift mutation that was not previously reported in the population. According to the ACMG guidelines,¹¹ this gene mutation is likely pathogenic for ACC in this child, although the exact penetrance and expressivity of the mutation need further investigation. Unlike other hereditary transmitted cases previously discussed, *MEN1* mutation was sporadic in this case, and the finding was discordant with the well-known inheritance mode of *MEN1*, i.e., that *MEN1* is usually inherited in an autosomal dominant manner. Further investigations of the patient's family may be needed to identify hereditary traits of *MEN1*.

In conclusion, early diagnosis of ACC in children is of great importance because intervention at an early stage leads to a favorable prognosis, thereby increasing the overall survival rate. Pediatric endocrinologists should collaborate with pathologists, surgeons, geneticists, and oncologists to efficiently manage these patients. This multidisciplinary approach could provide optimal results for children with ACC. Due to the *MEN1* mutation, the patient may experience other endocrinologic problems in the future, which warrants regular follow-ups. Endocrinologists should keep track of hormonal surveillance before puberty, during puberty, and even after adolescence. With recent advancements in genetic evaluation tools, genetic etiologies of ACC can be readily found. These tools should be actively utilized for better understanding and proper management of childhood ACC. Future studies that discuss the clinical aspects of genetically errant ACC will provide more clues for understanding the pathophysiology of childhood ACC in clinical fields.

Ethical statement

Informed consent was obtained from the patient's parents,

and genetic analyses were conducted.

Notes

Conflicts of interest: No potential conflict of interest relevant to this article was reported.

Funding: This study received no specific grant from any funding agency in the public, commercial, or not-for-profit sectors.

Author contribution: Conceptualization: KSE, MBA; Data curation: KSE, MBA; Formal analysis: KSE, MBA, WKC; Methodology: KSE; Project administration: KSE; Visualization: KSE; Writing - original draft: KSE; Writing - review & editing: MBA, NYL, JY, JWL, MK, JHJ, MHJ, BS

ORCID

Sung Eun Kim: 0000-0002-1598-3500
 Na Yeong Lee: 0000-0002-2402-9321
 Won Kyoung Cho: 0000-0003-0918-0565
 Jisook Yim: 0000-0002-9745-0731
 Jae Wook Lee: 0000-0002-0735-0287
 Myungshin Kim: 0000-0001-8632-0168
 Jae Hee Chung: 0000-0002-5866-119X
 Min Ho Jung: 0000-0001-5188-7041
 Byung-Kyu Suh: 0000-0003-1971-0232
 Moon Bae Ahn: 0000-0003-1108-2788

References

1. Kamilaris CDC, Stratakis CA. Multiple endocrine neoplasia type 1 (MEN1): an update and the significance of early genetic and clinical diagnosis. *Front Endocrinol (Lausanne)* 2019;10:339.
2. Thakker RV, Newey PJ, Walls GV, Bilezikian J, Dralle H, Ebeling PR, et al. Clinical practice guidelines for multiple endocrine neoplasia type 1 (MEN1). *J Clin Endocrinol Metab* 2012;97:2990-3011.
3. Goudet P, Dalac A, Le Bras M, Cardot-Bauters C, Niccoli P, Levy-Bohbot N, et al. MEN1 disease occurring before 21 years old: a 160-patient cohort study from the Groupe d'étude des Tumeurs Endocrines. *J Clin Endocrinol Metab* 2015;100:1568-77.
4. Gupta N, Rivera M, Novotny P, Rodriguez V, Bancos I, Lteif A. Adrenocortical carcinoma in children: a clinicopathological analysis of 41 patients at the Mayo Clinic from 1950 to 2017. *Horm Res Paediatr* 2018;90:8-18.
5. Ribeiro RC, Pinto EM, Zambetti GP. Familial predisposition to adrenocortical tumors: clinical and biological features and management strategies. *Best Pract Res Clin Endocrinol Metab* 2010;24:477-90.
6. Raymond VM, Else T, Everett JN, Long JM, Gruber SB, Hammer GD. Prevalence of germline TP53 mutations in a prospective series of unselected patients with adrenocortical carcinoma. *J Clin Endocrinol Metab* 2013;98:E119-25.

7. Custodio G, Parise GA, Kiesel Filho N, Komechen H, Sabbaga CC, Rosati R, et al. Impact of neonatal screening and surveillance for the TP53 R337H mutation on early detection of childhood adrenocortical tumors. *J Clin Oncol* 2013;31:2619-26.
8. Kwon EB, Jeong HR, Shim YS, Lee HS, Hwang JS. Multiple Endocrine neoplasia type 1 presenting as hypoglycemia due to insulinoma. *J Korean Med Sci* 2016;31:1003-6.
9. Kim JH, Yun S, Hwang SS, Shim JO, Chae HW, Lee YJ, et al. The 2017 Korean National Growth Charts for children and adolescents: development, improvement, and prospects. *Korean J Pediatr* 2018;61:135-49.
10. Wong DD, Spagnolo DV, Bisceglia M, Havlat M, McCallum D, Platten MA. Oncocytic adrenocortical neoplasms--a clinicopathologic study of 13 new cases emphasizing the importance of their recognition. *Hum Pathol* 2011;42:489-99.
11. Richards S, Aziz N, Bale S, Bick D, Das S, Gastier-Foster J, et al. Standards and guidelines for the interpretation of sequence variants: a joint consensus recommendation of the American College of Medical Genetics and Genomics and the Association for Molecular Pathology. *Genet Med* 2015;17:405-24.
12. Redlich A, Boxberger N, Strugala D, Fruhwald MC, Leuschner I, Kropf S, et al. Systemic treatment of adrenocortical carcinoma in children: data from the German GPOH-MET 97 trial. *Klin Padiatr* 2012;224:366-71.
13. Brondani VB, Fragoso M. Pediatric adrenocortical tumor - review and management update. *Curr Opin Endocrinol Diabetes Obes* 2020;27:177-86.
14. Hah JO. Intensive chemotherapy with autologous PBSCT for advanced adrenocortical carcinoma in a child. *J Pediatr Hematol Oncol* 2008;30:332-4.
15. Teinturier C, Pauchard MS, Brugieres L, Landais P, Chaussain JL, Bougneres PF. Clinical and prognostic aspects of adrenocortical neoplasms in childhood. *Med Pediatr Oncol* 1999;32:106-11.
16. McAteer JP, Huaco JA, Gow KW. Predictors of survival in pediatric adrenocortical carcinoma: a Surveillance, Epidemiology, and End Results (SEER) program study. *J Pediatr Surg* 2013;48:1025-31.
17. Kwon A, Choi Y, Jung JW, Suh J, Kim HS. Using etomidate in a 2-month-old infant with cushing syndrome due to adrenocortical carcinoma. *J Clin Res Pediatr Endocrinol* 2022;14:102-6.
18. Kim MS, Yang EJ, Cho DH, Hwang PH, Lee DY. Virilizing adrenocortical carcinoma advancing to central precocious puberty after surgery. *Korean J Fam Med* 2015;36:150-3.
19. Ko JH, Lee HS, Hong J, Hwang JS. Virilizing adrenocortical carcinoma in a child with Turner syndrome and somatic TP53 gene mutation. *Eur J Pediatr* 2010;169:501-4.
20. Lim YJ, Lee SM, Shin JH, Koh HC, Lee YH. Virilizing adrenocortical oncocytoma in a child: a case report. *J Korean Med Sci* 2010;25:1077-9.