

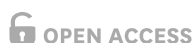Clinical Article



Posterior Facetectomy with Fusion Using a Pedicle Screw for Parallel-shaped Cervical Foraminal Stenosis

Jae yeon Park ¹, Il Choi ¹, Hae min Chon², Jung Hee Kim², Su bum Lee², and Jin Hoon Park²

¹Department of Neurological Surgery, Hallym University Dongtan Sacred Heart Hospital, Hwaseong, Korea
²Department of Neurological Surgery, Asan Medical Center, University of Ulsan College of Medicine, Seoul, Korea



Received: Mar 1, 2020
Revised: Jul 13, 2020
Accepted: Jul 31, 2020

Address for correspondence:

Il Choi

Department of Neurological Surgery, Hallym University Dongtan Sacred Heart Hospital, 7 Keunjaebong-gil, Hwaseong 18450, Korea.
E-mail: heycai79@gmail.com



Jin Hoon Park

Department of Neurological Surgery, Asan Medical Center, University of Ulsan College of Medicine, 88 Olympic-ro 43-gil, Songpa-gu, Seoul 05505, Korea.
E-mail: jhpark@amc.seoul.kr

Copyright © 2020 Korean Neurotraumatology Society

This is an Open Access article distributed under the terms of the Creative Commons Attribution Non-Commercial License (<https://creativecommons.org/licenses/by-nc/4.0/>) which permits unrestricted non-commercial use, distribution, and reproduction in any medium, provided the original work is properly cited.

ORCID iDs

Jae yeon Park 
<https://orcid.org/0000-0002-7052-8025>
Il Choi 
<https://orcid.org/0000-0003-0120-6564>

Conflict of Interest

The authors have no financial conflicts of interest.

ABSTRACT

Objective: To assess the efficacy and safety of posterior facetectomy with fusion using pedicle screw (PF using FPS) for severe cervical foraminal stenosis of parallel shape.
Methods: Patients (n=8) with 1- or 2-level parallel-shaped cervical foraminal stenosis who underwent posterior facetectomy with fusion using cervical pedicle screw between March 2012 and August 2016 were enrolled. Patients were followed up immediately postoperatively and at 1, 3, 6, and 12 months postoperatively. We assessed arm and neck pains and clinical outcomes using a numeric rating scale (NRS) and neck disability index (NDI). We determined cervical Cobb's and segmental angles by radiological evaluations. We identified screw breach as a neurovascular complication.
Results: Neck and arm pains were significantly reduced postoperatively (neck visual analog scale [VAS]: 4.9±3.7 [preoperative] to 0.4±1.1 [final follow-up]; arm VAS: 9.0±0.8 to 0.4±1.1). Cobb's angle for cervical sagittal alignment improved from 11.1±8.4 to 17.0±5.9. Segmental angle of index surgery was maintained (3.4±7.0–4.9±5.6). NDI was also remained from 36.1±26.3 to 13.8±8.4. There are no injuries to the vertebral arteries and neural tissues because of screw insertion.
Conclusion: PF using FPS is a practical treatment option for parallel-shaped cervical foraminal stenosis.

Keywords: Spinal disease; Pedicle screw; Spinal stenosis

INTRODUCTION

Anterior cervical discectomy and fusion (ACDF) and posterior decompression with or without fusion are good options for cervical foraminal stenosis (FS). Although cervical posterior foraminotomy without fusion is a surgical option for the treatment of mild or moderate cervical FS, it is not recommended for the treatment of severe cervical FS, wherein the nerve root is compressed across the entire path of the cervical foramen.^{5,7,8,13,14,23,25} ACDF or posterior facetectomy with fusion are reportedly the two surgical options when presented with compression of the entire foraminal path by bony spur as observed in the axial computed tomography (CT) scan.^{4,7}

We previously showed the efficacy and safety of placing a large series of cervical pedicle screws (CPSs) in patients with severe pathology of the cervical spine.^{3,6,12,15,16,17,19-21,24} To date, there are no reports regarding the treatment of severe cervical FS by PF using FPS. In this study, we demonstrate the efficacy and safety of posterior facetectomy with fusion using pedicle screw (PF using FPS) to treat parallel-shaped severe cervical FS.

MATERIALS AND METHODS

Patient population and inclusion criteria

In this study, we enrolled patients with 1- or 2-level parallel-shaped cervical FS who underwent posterior facetectomy with fusion using a CPS between March 2012 and June 2014. Patients with cervical myelopathy, cervical soft disc herniation, severe cardiovascular, pulmonary, or cerebrovascular comorbidity, and anticoagulant treatment history (warfarin or clopidogrel) were excluded from this study. The inclusion criteria were as follows: 1) patients with radiculopathy caused by bony hypertrophy through the cervical foramen and those who failed >2 months of non-operative treatment; 2) the narrowed foramen on the axial CT scan was parallel-shaped, not V-shaped, and regarded as narrow through the entire path of the foramen (**FIGURE 1**)⁷ and 3) the follow-up duration was >12 months and the surgical level was 1 or 2. All patients underwent preoperative CT, magnetic resonance imaging (MRI), and X-ray examination.

Surgical methods

All patients underwent preoperative CT (1-mm slices) with angiography. Pedicle screw insertion with a freehand technique was primarily considered if the outer diameter of the cervical pedicle was >3.0 mm on the axial CT scan. Patients were placed in the prone position, and Gardner-Wells tongs were applied with 3 or 5 pounds of traction to achieve a maximally horizontal head position. Motor evoked potential monitoring was used throughout the procedure. The entry point of the screw was determined by the notch level in the sagittal plane and was medial to the lateral border of the superior articular process

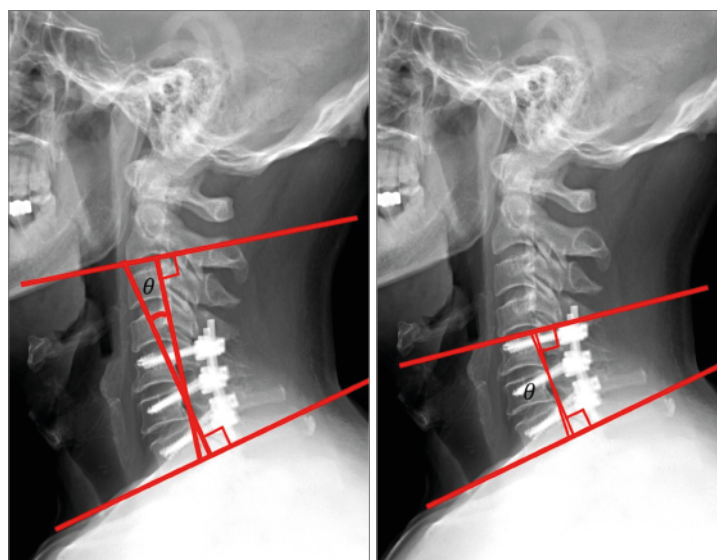


FIGURE 1. A lateral cervical X-ray image in the neutral position showing the Cobb's angle measurement between the lower borders of the C2 and C7 bodies.

by one-quarter of its width in the axial plane. However, the C7 vertebra was moved more medially and closer to the one-half width point of the superior articular process in the axial plane. A small pilot hole was made at the predetermined entry point with a 1.8-mm diameter match head-type burr. A 2.5-mm diameter, curved pedicle probe was slowly inserted vertically to the global lamina plane with a medial trajectory through the cortical hole, and the tip was placed at the thick medial cortical pedicle wall. Then, the tip of the pedicle probe was pushed medially in an upward and downward direction to locate the cancellous channel of the pedicle. When the cancellous channel was found, the probe was inserted at a depth of approximately 30 mm using a medially directed force. After forming a track with the curved probe, a ball tip probe palpation was performed. Next, a straight pedicle probe (2.5-mm diameter) was inserted to widen and straighten the. During the insertion of the curved and straight pedicle probe, the entry point was shifted more medially than the originally planned entry point. Moreover, the cancellous screw trajectory, including the cortical entrance, was wider. This process also eased the subsequent ball tip probe insertion, tapping, and screw placement. The depth of the ball tip probe was measured, and after tapping with a 3.5-mm diameter tap, a screw was inserted. The screw diameter was selected based on the preoperative CT measurements from the axial images. We used vertex pedicle screws (Medtronic Sofamor Danek, Memphis, TN, USA) that were 28–30 mm in length and 3.5–4.0 mm in diameter. During the ball tip probe palpation, the CPS procedure was abandoned upon screw malpositioning, and lateral mass screw insertion was performed. The rate of lateral mass screw conversion during surgery was analyzed. A more detailed technical description of our technique is described in a previously published article.^{17,20)}

After CPS, wide facetectomy was performed to decompress the entire path of the nerve root. After cutting the inferior articular process with an osteotome, the superior articular process was drilled with a 3.0-mm match head type burr and 1- and 2-mm Kerrison rongeur. After completely removing the tip of the superior articular process and identifying the lateral dura margin and origin of the nerve root, we regraded complete decompression (**FIGURE 2**). Further ligament flavectomy was not performed, and redundancy of soft tissue was identified by palpation with a number 4 Penfield. Cancellous bone was exposed by drilling the posterior

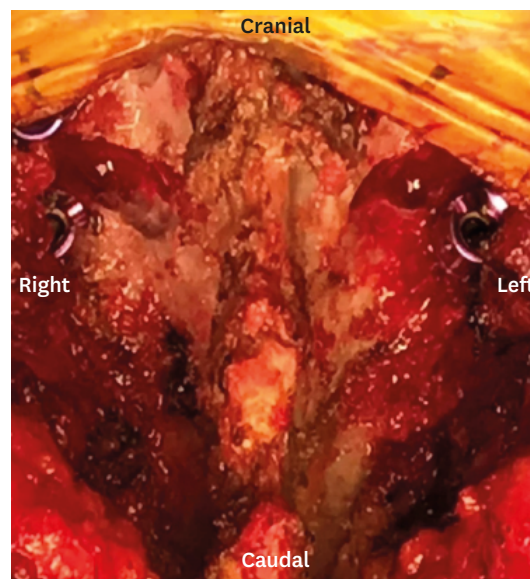


FIGURE 2. Intraoperative image showing total facetectomy and cervical pedicle insertion via the posterior approach.

surface of the lateral mass and inside the facet joint with a 3.0-mm match head type burr. Allograft bone chips (TBI Inc., San Rafael, CA, USA) were used for postero-lateral fusion, which included onlay bone graft on the decorticated lateral mass and inside the facet joint.¹⁷⁾ As shown in **FIGURE 3B**, postoperative CT scan was performed to check for screw accuracy and optimal foraminal decompression in all patients.

Assessment of outcomes

All patients were advised to wear a soft collar for 4 weeks after the operation and were followed up at 1, 3, 6, and 12 months postoperatively. We assessed clinical outcomes such as changes in the arm pain numeric rating scale (NRS), neck pain NRS, and neck disability index (NDI).

Radiological fusion was deemed to have occurred if stability was observed on a dynamic view (the motion between the adjacent spinous processes between the fusion segment was <2 mm). The accuracy of CPS and lateral mass screw conversion rate were analyzed using postoperative CT scan in patients who underwent the posterior approach. The breach rate was analyzed based on both the sagittal and axial planes. In the axial plane, lateral wall perforation was classified into the following three grades: 1) grade 1: perforation into the VA foramen with the external edge of the screw deviating out of the lateral pedicle but not violating the largest diameter of the VA foramen; 2) grade 2: the screw deviates laterally into the largest diameter of the VA foramen, but without complete occlusion; and 3) grade 3: complete occlusion of VA foramen.^{20,22)}

We reviewed a series of lateral cervical X-rays in the neutral position and measured the Cobb angle between the lower borders of the C2 and C7 bodies to determine cervical sagittal alignment. Moreover, we obtained the segmental Cobb's angle and the inter-spinous distance of the index surgery level to determine postoperative subsidence (**FIGURE 1**).

Statistical analysis

The SPSS 18.0 software (SPSS Inc., Chicago, IL, USA) was used for statistical analysis. We used the Shapiro-Wilk normality test to investigate whether the numerical (continuous) variables that we use in our analysis followed a normal distribution. To investigate differences

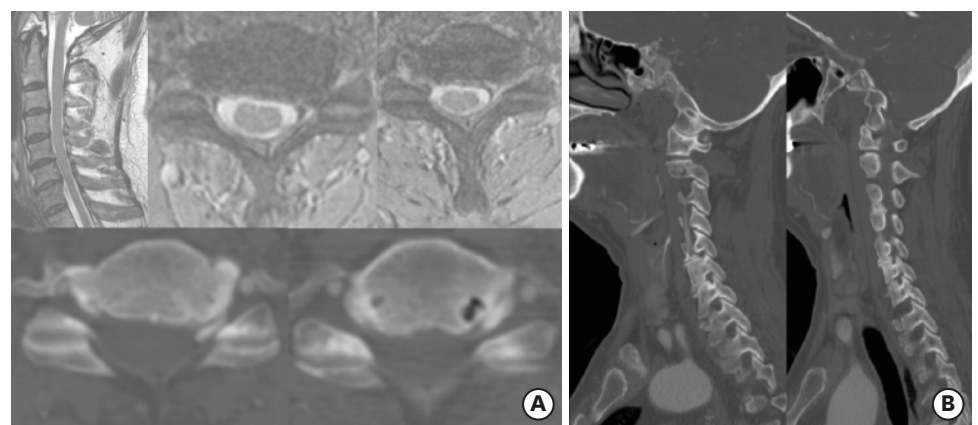


FIGURE 3. (A) 70-year-old male patient complained of severe left-side arm pain (numeric rating scale: 9) despite 6 months of medication treatment. Preoperative magnetic resonance imaging and CT scan show left parallel-shaped foraminal stenosis at the C5-6 and C6-7 levels. (B) Post-operative 1-year CT scan shows correct screw position and extensive decompression on the same level consistent with the successful surgical outcome. CT: computed tomography.

at different times, we used “repeated measure ANOVA” when the dependent variable was following the normal distribution or the equivalent non-parametric test “Friedman test” when the dependent variable was not following the normal distribution. Furthermore, we used “Multiple Comparisons of Means with Tukey Contrasts” to further investigate the variables that showed significant difference at different times. And the summarized characteristics of the study patients are presented as mean±standard deviation (SD) for numerical (continuous) variables or as counts of each category and percentage in case of categorical variables. Furthermore, we used the paired “Wilcoxon signed-rank test” to investigate differences among the pre-operative NDI and post-operative NDI scores

RESULTS

Patient characteristics

Finally, a total of 8 patients were enrolled. The demographic and characteristics of the study patients are summarized in **TABLES 1 & 2**. Seven of the 8 patients (87.5%) who underwent the posterior approach were men and a mean age of the total patients was 57.6±13.7 year. The follow-up duration was 28.6±7.5 months. The patients' surgical levels were C4-6 (n=1, 12.5%), C4-7 (n=1, 12.5%), C5-6 (n=1, 12.5%), C5-7 (n=2, 25%), and C6-7 (n=3, 37.5%). The proportion of patients who underwent 2- and 1-level fusion was 50% (n=4) and 50% (n=4), respectively.

Clinical outcomes

The preoperative visual analog scale (VAS) score for arm pain was 9.0±0.8. The VAS score for arm pain at final follow-up was 0.4±1.1 (28.6±7.5 months). The preoperative VAS score for neck pain was 4.9±3.7. The VAS score for neck pain at final follow-up was 0.4±1.1. The preoperative VAS score for arm pain was 9.0±0.8, which declined over time, with a final follow-up mean±SD of 0.4±1.1 (**TABLE 2**). This decline over time was statistically significant based on the “Friedman test” (chi-squared=16.555; *p*<0.05). The pre-operative NDI score was 36.1, and it improved to 13.8 at the final follow-up. “Wilcoxon signed-rank test” showed that this improvement was statistically significant (*V*=27, *p*<0.05). Thus, we observed improvements in the arm and neck pain after surgery, and this improvement was maintained for at least 1 year (**FIGURE 4**).

Radiologic outcomes

The pre-operative mean baseline Cobb's angle was 11.1°±8.4°. The Cobb's angle at final follow-up was 17.0°±5.9°. The pre-operative mean baseline Cobb's angle was 11.1°±8.4°, which improved (increased) over time, with a final follow-up mean±SD of 17.0°±5.9° (**TABLE 2**). This increase over time was statistically significant based on the “repeated measure ANOVA test” (*F*=2.862; *p*<0.05). The preoperative segmental angle of the index surgery level was 3.4°±7.0°. The segmental angle at final follow-up was 4.9°±5.6° at the final follow-up. The preoperative segmental angle of the index surgery level was 3.4°±7.0°, which increased over time, with a final follow-up mean±SD of 4.9°±5.6° (**TABLE 2**). This increase in time was not statistically significant based on the “Friedman test” (chi-squared=1.2637; *p*>0.05) showed. The

TABLE 1. Demographic of study group (posterior cervical fusion with wide facetectomy and pedicle screw fixation)

Enrolled patients	Values (n=8)
Sex (male:female)	7:1
Age	57.6±13.7

TABLE 2. Clinical characteristics of study group (posterior cervical fusion with wide facetectomy and pedicle screw fixation)

F/U duration	Values (28.6±7.5)
Operation level	
C4-5 and C5-6	1 (12.5)
C4-5 and C5-6 and C6-7	1 (12.5)
C5-6	1 (12.5)
C5-6 and C6-7	2 (25.0)
C6-7	3 (37.5)
# of surgical level	
1 level	4 (50.0)
2 level	3 (37.5)
3 level	1 (12.5)
Preoperative Cobb's angle	
Postoperative Cobb's angle (1 month)	11.1±8.4
Postoperative Cobb's angle (3 months)	9.0±4.2
Postoperative Cobb's angle (6 months)	12.4±6.2
Postoperative Cobb's angle (12 months)	10.8±3.5
Cobb's angle at last follow-up	12.4±5.3
	17.0±5.9
Preoperative segmental angle	
Postoperative segmental angle (1 month)	3.4±7.0
Postoperative segmental angle (3 months)	3.5±4.2
Postoperative segmental angle (6 months)	5.3±6.1
Postoperative segmental angle (1 year)	3.8±3.6
Segmental angle at last follow-up	5.3±6.4
	4.9±5.6
Preoperative arm VAS	
Postoperative arm VAS (1 month)	9.0±0.8
Postoperative arm VAS (3 months)	0.8±1.5
Postoperative arm VAS (6 months)	0.8±1.5
Postoperative arm VAS (12 months)	0.5±1.2
Last follow-up arm VAS	0.6±1.0
	0.4±1.1
Preoperative neck pain VAS	
Postoperative neck pain VAS (1 month)	4.9±3.7
Postoperative neck pain VAS (3 months)	3.0±3.4
Postoperative neck pain VAS (6 months)	1.6±1.9
Postoperative neck pain VAS (12 months)	0.7±1.0
Last follow-up neck pain VAS	0.3±0.8
	0.4±1.1
Last X-ray inter-spinous distance	
	0.4±0.3
Fusion bridge	
Yes	7 (87.5)
No	1 (12.5)
Complication	
Yes	3 (37.5)
No	5 (62.5)
Dysphagia	
Yes	0 (0.0)
No	1 (100.0)
pre-NDI	36.1±26.3
post-NDI	13.8±8.4

Data are presented as number (%) or mean±standard deviation.
 F/U: follow-up, VAS: visual analog scale, NDI: neck disability index.

Cobb's and segmental angles were well maintained for at least 1 year after PF using FPS. To determine fusion, we measured the distance between the interspinous process using lateral cervical X-rays, and it was found to be 0.4±0.3 mm. Postoperative CT scan showed a solid bony fusion bridge in 7/8 cases (87.5%). The results of the “Multiple Comparisons of Means with Tukey Contrasts” tests for the “VAS score for neck pain,” “VAS score for arm pain,” “baseline Cobb's angle,” and “segmental angle” are presented in **FIGURE 4**, which show how these variables differed over time.

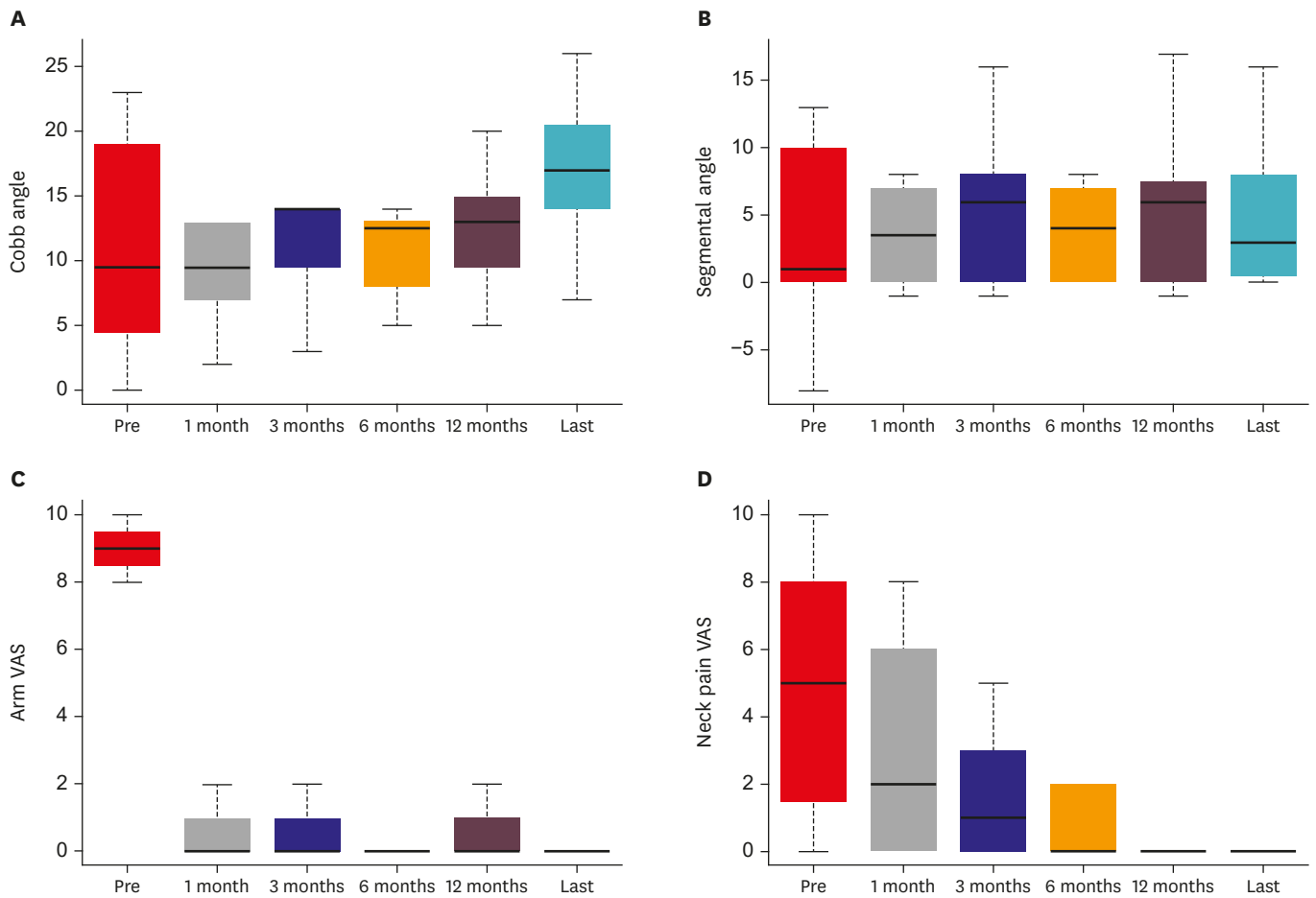


FIGURE 4. Clinical outcome after the operation and during the follow-up at 1, 3, 6, and 12 months postoperatively. (A) Cobb's angle. (B) Segmental angle. (C) Arm VAS. (D) Neck VAS. VAS: visual analog scale.

The safety and accuracy of pedicle screw fixation

TABLE 2 shows the accuracy of the free-hand pedicle screw. We performed 42 pedicle screw insertions. Postoperative CT scan revealed a breach in 0 cases (Grade I, 1 medical wall violation; Grade 4, 4 lateral wall violation). Based on the surgical levels, we observed violations in 0/4 cases in C4, 0/10 cases in C5, 0/16 cases in C6 and 0/12 in C7. The accuracy rate of insertion was 100% (42/42). We did not observe any injuries to the vertebral arteries and neural tissues because of screw insertion (**TABLE 3**).

TABLE 3. The safety and accuracy of pedicle screw fixation

Surgery level	Planned CPS	Lateral mass screw conversion	Actual CPS insertion	Breach	Lateral mass screw conversion rate	Accuracy rate
C4	4	0	4	0		
C5	10	0	10	0		
C6	16	0	16	0	0%	100%
C7	12	0	12	0		
Total	42	0	42	0		

CPS: cervical pedicle screw.

Case presentation

A 70-year-old male patient complained of severe left-side arm pain (NRS 9) despite 6 months of medication treatment. Preoperative MRI and CT scan show left parallel-shaped FS at C5-6 and C6-7 levels (**FIGURE 3A**). Patients underwent posterior facetectomy with fusion using a pedicle screw at C5-6 and C6-7 levels. After operation, arm VAS was improved from 9 to 3 postoperatively and 0 at the final follow-up. NDI also improved from 48 to 22. Post-operative 1-year CT scan shows correct screw position and extensive decompression on the same levels consistent with the successful surgical outcome (**FIGURE 3B**).

DISCUSSION

Our study demonstrated that the segmental angle of the surgical index level and whole Cobb's angle are maintained for at least 1 year after PF using FPS. We also showed that arm and neck pains improved after surgery.

Although decompressive surgery such as a posterior cervical foraminotomy is the preferred surgical option for cervical FS, this minimally invasive surgical option is not considered for the treatment of FS with advanced stage degeneration. The recommended surgical options for this situation include ACDF with uncinated process removal or posterior cervical fusion and wide decompression through facet resection.^{4,7,8)} However, additional uncinated process removal during ACDF is associated with higher incidences of subsidence despite similar fusion rates.^{18,19)}

Previous studies have established the biomechanical advantage of CPS. However, because of concerns of neurovascular complications, the use of CPS is controversial.^{2,11)} We previously showed the safety and efficacy of the CPS, if a surgeon stringently observed five safety steps during the procedure, which are as follows: 1) planning the screw entry point using the preoperative CT scan; 2) ensure sufficient medial angle for screw insertion through the use of a curved pedicle probe; 3) detect pedicle breach with a ball tip probe; 4) convert to a lateral mass screw insertion method upon breach; and 5) optimally interpret the intraoperative AP X-ray images after screw insertion. We did not encounter any neurovascular complications by observing these five safety steps from the beginning of CPS.^{10,17,20)} Therefore, although the use of CPS in the degenerative cervical disease is controversial, we have preferred to use CPS, instead of lateral mass screw, by observing the five safety steps, even in degenerative spinal disease.^{1,9,17)}

Moreover, CPS is more beneficial than the lateral mass screw when we decompress the foramen through wide facetectomy. Sometimes, a screw tip or thread of a lateral mass screw may be exposed during the resection of the superior and inferior articular processes (**FIGURE 5**). The use of a lateral mass screw is limited when combined with wide facetectomy in cases of smaller bone and screw engagement because it offers lower stability during primary and after cyclic loading. Besides, a fusion bed around the lateral mass, which is regarded as an important bone graft recipient site, may be smaller because the area is occupied by the head of a lateral mass screw.^{17,23)} We regard that a sufficient healthy surface of the bone graft recipient and biomechanical stability during bone fusion are critical factors to connect the remaining superior-inferior articular process after decompression through a bony fusion. We previously showed a complete fusion rate only by using an onlay allograft bone in FS.¹⁷⁾

We think that the ACDF is standard surgery in degenerative cervical FS accompanying hard disc. The most useful case of this technic is that the patients are not able to be undergo the

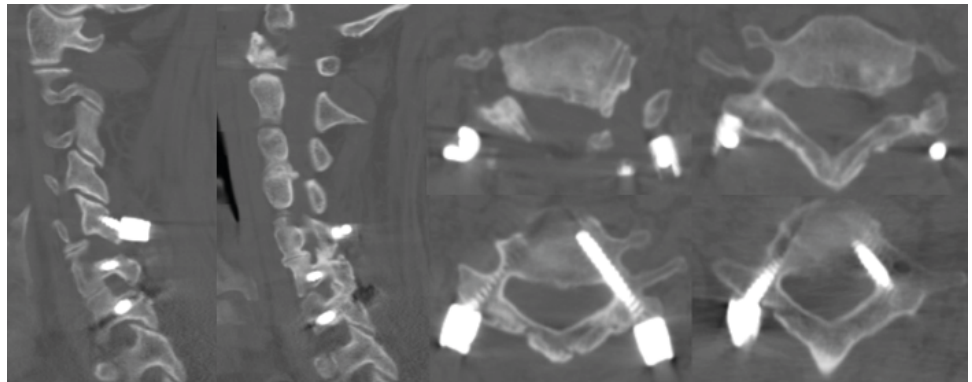


FIGURE 5. An illustration shows an exposed screw tip or thread of a lateral mass screw during the resection of the superior and inferior articular processes.

ACDF, for example, who previously underwent anterior approach neck surgery especially. We wrote this article for proving as an alternative of previous anterior approach surgery, for its usefulness and safeness of posterior approach pedicle screw.

The limitations of our study include 1) the small size of the retrospective study cohort and 2) absence of control group in the case series. In our next study, we plan to compare the clinical and radiologic outcomes between ACDF and PF using FPS.

CONCLUSION

Posterior facetectomy with fusion using the CPS is a practical treatment option for cervical FS.

REFERENCES

1. Abumi K. Cervical spondylotic myelopathy: posterior decompression and pedicle screw fixation. *Eur Spine J* 24 Suppl 2:186-196, 2015
[PUBMED](#) | [CROSSREF](#)
2. Abumi K, Ito M, Sudo H. Reconstruction of the subaxial cervical spine using pedicle screw instrumentation. *Spine* 37:E349-E356, 2012
[PUBMED](#) | [CROSSREF](#)
3. Chon H, Park JH. Cervical vertebral body fracture with ankylosing spondylitis treated with cervical pedicle screw: a fracture body overlapping reduction technique. *J Clin Neurosci* 41:150-153, 2017
[PUBMED](#) | [CROSSREF](#)
4. Dodwad SJ, Dodwad SN, Prasarn ML, Savage JW, Patel AA, Hsu WK. Posterior cervical foraminotomy: indications, technique, and outcomes. *Clin Spine Surg* 29:177-185, 2016
[PUBMED](#) | [CROSSREF](#)
5. Fessler RG, Khoo LT. Minimally invasive cervical microendoscopic foraminotomy: an initial clinical experience. *Neurosurgery* 51 Suppl:S37-S45, 2002
[PUBMED](#) | [CROSSREF](#)
6. Gu BS, Choi SJ, Yoo B, Han KH, Park JK, Lee YS, et al. An incidental finding of a radiopaque pill following cervical spinal surgery in a Parkinson's disease patient. *Korean J Spine* 12:153-155, 2015
[PUBMED](#) | [CROSSREF](#)
7. Gu BS, Park JH, Seong HY, Jung SK, Roh SW. Feasibility of posterior cervical foraminotomy in cervical foraminal stenosis: prediction of surgical outcomes by the foraminal shape on preoperative computed tomography. *Spine* 42:E267-E271, 2017
[PUBMED](#) | [CROSSREF](#)

8. Gutman G, Rosenzweig DH, Golan JD. The surgical treatment of cervical radiculopathy: meta-analysis of randomized controlled trials. *Spine* 43:E365-E372, 2018
[PUBMED](#) | [CROSSREF](#)
9. Hasegawa K, Hirano T, Shimoda H, Homma T, Morita O. Indications for cervical pedicle screw instrumentation in nontraumatic lesions. *Spine* 33:2284-2289, 2008
[PUBMED](#) | [CROSSREF](#)
10. Heo Y, Lee SB, Lee BJ, Jeong SK, Rhim SC, Roh SW, et al. The learning curve of subaxial cervical pedicle screw placement: how can we avoid neurovascular complications in the initial period? *Oper Neurosurg (Hagerstown)* 17:603-607, 2019
[PUBMED](#) | [CROSSREF](#)
11. Johnston TL, Karaikovic EE, Lautenschlager EP, Marcu D. Cervical pedicle screws vs. lateral mass screws: uniplanar fatigue analysis and residual pullout strengths. *Spine J* 6:667-672, 2006
[PUBMED](#) | [CROSSREF](#)
12. Jung YG, Jung SK, Lee BJ, Lee S, Jeong SK, Kim M, et al. The Ssubaxial cervical pedicle screw for cervical spine diseases: the review of technical developments and complication avoidance. *Neurol Med Chir (Tokyo)* 60:231-243, 2020
[PUBMED](#) | [CROSSREF](#)
13. Kang MS, Choi KC, Lee CD, Shin YH, Hur SM, Lee SH. Effective cervical decompression by the posterior cervical foraminotomy without discectomy. *J Spinal Disord Tech* 27:271-276, 2014
[PUBMED](#) | [CROSSREF](#)
14. Kerry G, Hammer A, Ruedinger C, Ranaie G, Steiner HH. Microsurgical posterior cervical foraminotomy: a study of 181 cases. *Br J Neurosurg* 31:39-44, 2017
[PUBMED](#) | [CROSSREF](#)
15. Kim HB, Lee MK, Lee YS, Sohn JY, Jung SK, Park JH. An assessment of the medial angle of inserted subaxial cervical pedicle screw during surgery: practical use of preoperative CT scanning and intraoperative X-rays. *Neurol Med Chir (Tokyo)* 57:159-165, 2017
[PUBMED](#) | [CROSSREF](#)
16. Kim MW, Lee SB, Park JH. Cervical spondyloptosis successfully treated with only posterior short segment fusion using cervical pedicle screw fixation. *Neurol Med Chir (Tokyo)* 59:33-38, 2019
[PUBMED](#) | [CROSSREF](#)
17. Lee JK, Jung SK, Lee YS, Jeon SR, Roh SW, Rhim SC, et al. Analysis of the fusion and graft resorption rates, as measured by computed tomography, 1 year after posterior cervical fusion using a cervical pedicle screw. *World Neurosurg* 99:171-178, 2017
[PUBMED](#) | [CROSSREF](#)
18. Lee S, Park JH. Minimally invasive cervical pedicle screw placement with a freehand technique through the posterolateral approach using a tubular retractor: a technical note. *Oper Neurosurg (Hagerstown)* 17:E166-E172, 2019
[PUBMED](#) | [CROSSREF](#)
19. Lee S, Seo J, Lee MK, Jeon SR, Roh SW, Rhim SC, et al. Widening of the safe trajectory range during subaxial cervical pedicle screw placement: advantages of a curved pedicle probe and laterally located starting point without creating a funnel-shaped hole. *J Neurosurg Spine* 27:150-157, 2017
[PUBMED](#) | [CROSSREF](#)
20. Park JH, Jeon SR, Roh SW, Kim JH, Rhim SC. The safety and accuracy of freehand pedicle screw placement in the subaxial cervical spine: a series of 45 consecutive patients. *Spine* 39:280-285, 2014
[PUBMED](#) | [CROSSREF](#)
21. Park JH, Roh SW, Rhim SC. A single-stage posterior approach with open reduction and pedicle screw fixation in subaxial cervical facet dislocations. *J Neurosurg Spine* 23:35-41, 2015
[PUBMED](#) | [CROSSREF](#)
22. Rho YJ, Choe WJ. Double crush syndrome caused by cervical spondylosis and vertebral artery loop. *Eur Spine J* 28:292-296, 2019
[PUBMED](#) | [CROSSREF](#)
23. Roh SW, Kim DH, Cardoso AC, Fessler RG. Endoscopic foraminotomy using MED system in cadaveric specimens. *Spine* 25:260-264, 2000
[PUBMED](#) | [CROSSREF](#)
24. Yoon SD, Lee JY, Lee IS, Moon SM, Cho BM, Park SH, et al. Cervical pedicle screw placement in sawbone models and unstable cervical traumatic lesions by using para-articular mini-laminotomy: a novice neurosurgeon's experience. *Korean J Neurotrauma* 9:106-113, 2013
[CROSSREF](#)
25. Zeidman SM, Ducker TB. Posterior cervical laminoforaminotomy for radiculopathy: review of 172 cases. *Neurosurgery* 33:356-362, 1993
[PUBMED](#) | [CROSSREF](#)