

Clinical characteristics of rheumatic syndromes associated with checkpoint inhibitors therapy

Marie Kostine ¹, Marie-Elise Truchetet¹ and Thierry Schaeffer¹

Abstract

Compared with conventional cancer therapies, the spectrum of toxicities observed with checkpoint inhibitors is unique and can affect any organ system. Arthralgia and myalgia were by far the most commonly reported rheumatic immune-related adverse events in clinical trials, and there is now a growing number of case series and reports describing clinical features of *de novo* rheumatic immune-related adverse events, which will be the focus of this review. Some patients develop genuine classic rheumatic and musculoskeletal diseases, but a number of rheumatic immune-related adverse events mimic rheumatic and musculoskeletal diseases with atypical features, mainly polymyalgia rheumatica, rheumatoid arthritis and myositis, as well as several systemic conditions, including sicca syndrome, vasculitis, sarcoidosis, systemic sclerosis and lupus.

Key words: checkpoint inhibitors, immune-related adverse events, rheumatic and musculoskeletal diseases

Rheumatology key messages

- Polymyalgia-rheumatica and rheumatoid-arthritis-like syndromes are frequent with checkpoint inhibitors therapy.
- Myositis is a potentially life-threatening complication.
- Other systemic manifestations, including sicca syndrome, vasculitis, sarcoidosis, systemic sclerosis and lupus, are described.

Introduction

Although the concept of immunotherapy in cancer is far from new, the monoclonal antibodies ‘checkpoint inhibitors’ (CPI) targeting CTLA-4 or PD-1/PD-L1 pathway clearly marked a turning point in the success of this approach [1]. By enhancing antitumour T-cell activity, some unprecedented long-lasting tumour responses were observed in patients with unresectable or metastatic disease [2]. The clinical value of these CPI, as single agent or in combination, is being investigated in various solid tumours and hematological malignancies, and their use is expanding rapidly. As anticipated, the T-cell activation induced by such therapies promotes inflammatory side effects, known as immune-related adverse events (irAEs). Compared with conventional cancer therapies, this spectrum of toxicities is unique and can affect any organ system, with a particular tropism for the

gastrointestinal tract, endocrine glands, skin and liver [3]. Arthralgia and myalgia were by far the most commonly reported rheumatic irAEs in clinical trials, with a prevalence ranging from 1% to 43% and from 2% to 21%, respectively [4]. To date, a growing number of case series and reports is describing clinical features of *de novo* rheumatic irAEs, which will be the focus of this review. Of note, some of them have the appearance of classic rheumatic and musculoskeletal diseases (RMDs) and others mimic RMDs, therefore representing potentially new clinical variants.

Rheumatic manifestations

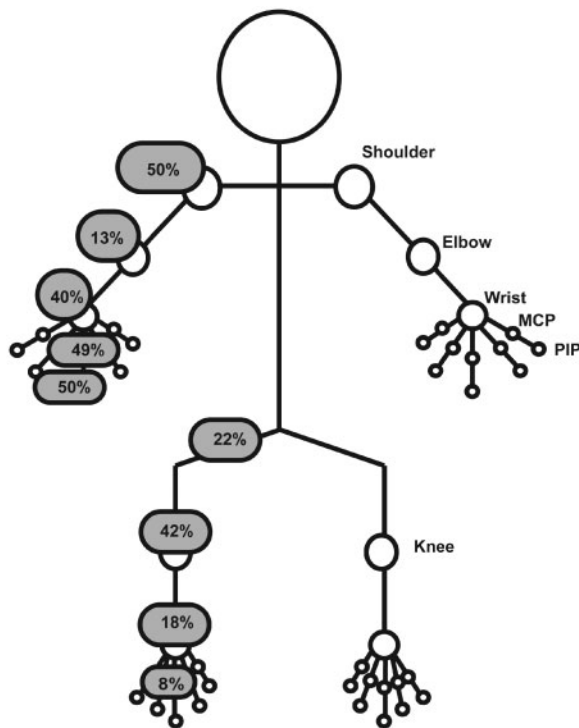
While the two major clinical entities observed are PMR-like syndromes [5–7] and RA-like syndromes [8–10], the broad spectrum of rheumatic irAEs includes arthralgia [11], monoarthritis and oligoarthritis [12], polyarthritis [13, 14], PsA [15–17], reactive arthritis [8], RS3PE [18–20], tenosynovitis [21], enthesitis [22], non-inflammatory musculoskeletal conditions [6] and osteoarthritis [11]. These are all the clinical patterns found in the literature regarding rheumatic irAEs, in addition to arthritis or inflammatory arthritis, which are the terms often used [8, 23, 24].

¹Department of Rheumatology, Bordeaux University Hospital, Bordeaux, France

Submitted 29 March 2019; accepted 31 May 2019

Correspondence to: Marie Kostine, Department of Rheumatology, Bordeaux University Hospital, Place Amélie Raba Léon, 33000 Bordeaux, France. E-mail: marie.kostine@chu-bordeaux.fr

Fig. 1 Frequency and type of joints involvement in patients experiencing rheumatic irAEs with CPI therapy



CPI: checkpoint inhibitors; irAEs: immune-related adverse events.

The joints involved most frequently are the shoulders, MCP and PIP joints of the hands (around 50%), followed by the knees and wrists (40%). The hips, elbows, ankles and feet are also affected in some patients, as described in Fig. 1 (unpublished personal data).

Except for osteoarthritis cases, synovial fluid analysis revealed a clear inflammatory reaction with predominant polymorphonuclear cells [23, 25, 26] but lymphocytic component is also described [27]. When reported, inflammatory markers are elevated for two-thirds of patients with a median CRP value of 58 mg/l (from 6 to 332 mg/l). Importantly, the search for antibodies is negative for a large proportion of patients or with isolated ANA positivity >1/160. This striking preponderance of seronegative diseases is observed by several groups, which is an important message for clinicians [4–8, 10–12, 23, 24]. Indeed, only a few patients are tested positive for RF and/or anti-CCP antibodies [28]. Plain radiographs are inconsistently reported and often considered as normal, but osteoarthritis lesions, joint space narrowing and erosions may be visualized [23, 29]. Ultrasound data available in the literature include mostly the presence of synovitis (31%), tenosynovitis (24%) or bursitis (15%), also frequently reported with PET-CT or MRI, as illustrated in Fig. 2.

Overall, on the basis of case series and case reports, around 20% of patients fulfilled classification criteria of

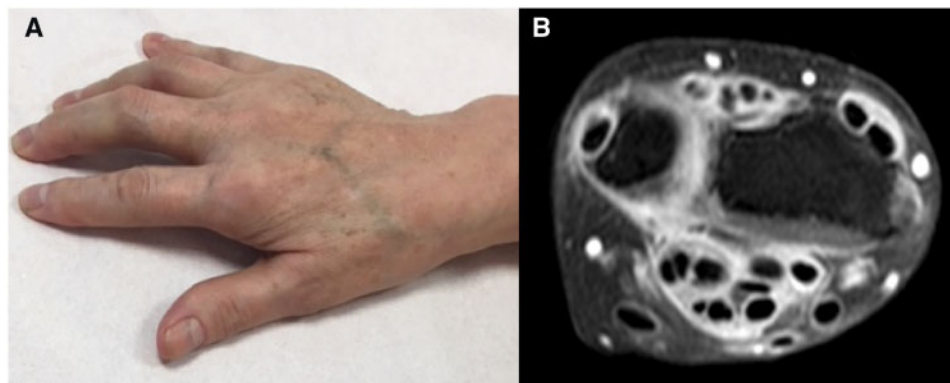
RA (55/271) or PMR (11/52). This percentage is higher (55%) for PsA (6/11). Rheumatologists should be aware that patients might present with atypical features, such as PMR clinical phenotype with no increase of inflammatory markers or RA-like symptoms without autoantibodies.

Myositis

Several cases of myositis have been reported as a potentially life-threatening complication in patients treated with CPI, presenting with remarkably homogeneous and unique clinicopathologic features (Fig. 3) [30–32]. Symptoms onset is dominated by acute or subacute myalgia (38%) and proximal muscle weakness (50%) including some patients presenting with dropped head syndrome. Furthermore, up to 25% of patients may present with oculomotor (ptosis/diplopia) and/or bulbar (dysphagia/dysarthria) symptoms. Dyspnoea should alert on a possible concurrent myocarditis, which is frequently reported as critical complication [33]. Therefore, cardiac evaluation is needed in all patients presenting with CPI-induced myositis, including troponin, electrocardiography and echocardiogram if myocarditis is suspected. Associated myasthenia gravis is also frequently encountered (15%) and should be considered with weakness, diplopia or bulbar symptoms [32, 34, 35]. Most described cases have been associated with the presence of anti-acetylcholine receptor antibodies and decremental response was sometimes found on electromyogram. Finally, fatigue is reported in 7% of patients presenting with myositis and typical skin rash of dermatomyositis is described in few patients [36, 37].

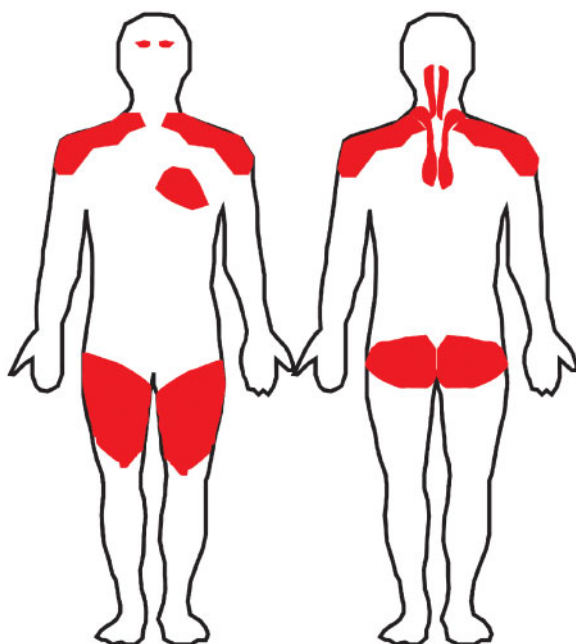
A strong increase in creatine kinase levels is reported in almost all patients presenting with myositis, with a median of 2650 UI/l (ranging from 335 to 20 270 UI/l). Of note, creatine kinase levels are usually within the normal range in patients presenting with myalgia [32, 38]. Myositis-associated autoantibodies are mostly negative, with the exception of rare case reports with positive ANA, anti-striated antibodies, anti-PM/Scl, anti-SM, anti-TIF1gamma, aPL-7, aPL12, anti-Jo1 or anti-signal recognition part [24, 32, 39, 40]. Of interest, anti-acetylcholine receptor and anti-striated muscle antibodies were detected in serum samples obtained prior to CPI therapy and associated with the development of myositis in thymoma patients [41]. Myopathic pattern is usually found on electrodiagnostic studies and musculature enhancement observed on MRI. Fasciitis is also reported on MRI findings [23, 42, 43]. Skeletal muscle biopsy is often performed and reveals variable degrees of inflammatory and necrotic changes [30].

Importantly, because of the frequent limb-girdle myalgia and weakness that may mimic PMR-like conditions, a high index of myositis suspicion is needed among rheumatologists with a low threshold for creatine kinase dosage in the diagnostic work-up of rheumatic irAEs. Furthermore, it is noteworthy to mention that median exposure time to CPI is usually shorter for myositis than for other rheumatic

FIG. 2 CPI-induced tenosynovitis

(A) Clinical presentation and (B) MRI findings on T1-SPIR weighted sequence with gadolinium-enhanced tenosynovitis. CPI: checkpoint inhibitors; SPIR: spectral presaturation with inversion recovery.

FIG. 3 Distribution of muscle involvement in patients experiencing CPI-induced myositis: limb-girdle, cervical, eyes and heart



CPI: checkpoint inhibitors.

irAEs, with symptoms' onset occurring during the first month of treatment in half of the cases.

Sicca syndrome

Clinical characteristics of sicca syndrome described with CPI include mostly dry mouth, in almost 80%, dry eyes being reported in half of cases and associated arthralgia in around 10% [5, 7, 8, 10, 44–46]. Parotid swelling and painful parotid gland are both reported in one patient and

neurological symptoms occurred in three patients (two with paresthesia, one reported as neuro-Sjögren) [47]. Of note, severe salivary hypofunction was documented by scintigraphy in two cases [10].

Only one case report mentioned a hypergammaglobulinaemia and one a normal serum protein electrophoresis; the data is missing for the others. Some, but not all, patients tested positive for ANA, SSA and/or SSB and/or RF.

The largest series including histopathological data of 20 patients experiencing sicca syndrome related to ICI has been published recently [48]. Interestingly, it showed a predominant T-cell infiltrate, composed mainly of CD3⁺ T cells with a slight predominance of CD4⁺ over CD8⁺ T cells, distinct from what is observed in classical Sjögren's syndrome with mainly CD20⁺ B cells and variable germinal centre formation.

Vasculitis

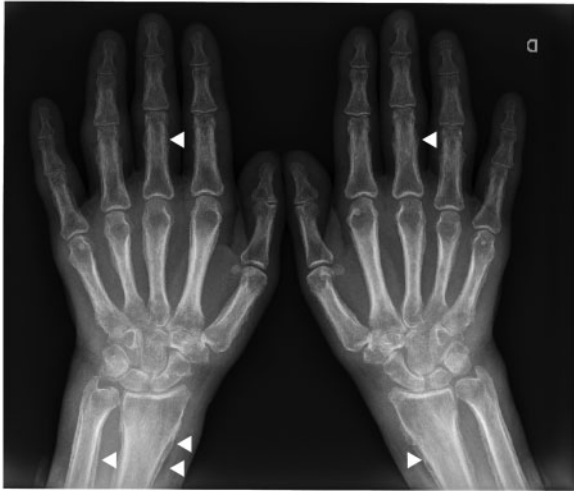Patients experiencing CPI-induced vasculitis presented with various clinical manifestations, including arthralgia, arthritis, myalgia, purpura, digital necrosis, fever, fatigue and abdominal pain. The corresponding diagnosis are cutaneous leucocytoclastic vasculitis [49], acral vasculitis [10, 50, 51], granulomatosis with polyangiitis [52], eosinophilic granulomatosis with polyangiitis [53], cryoglobulinemic vasculitis [44], giant cell arthritis [54–56] and a large proportion of cases are reported as vasculitis [7, 57, 58].

Acute phase reactants accompany symptoms' onset in one-third of patients. The search for ANA, ANCA, cryoglobulin and RF is often requested but rarely positive. Whenever possible, biopsy (i.e. skin, temporal artery) is performed and was contributive in all but one case.

Other systemic manifestations

In the last two years, the broad spectrum of irAEs is rapidly expanding, with descriptions of other various systemic manifestations.

Fig. 4 Representative image of periostitis in a patient developing hypertrophic osteoarthropathy after CPI onset



CPI: checkpoint inhibitors.

Sarcoidosis or sarcoid-like reactions are commonly described [59, 60]. Up to 25% of patients might be asymptomatic, the diagnosis being suspected on imaging (usually PET-CT with new hilar lymphadenopathy or pulmonary nodules), then documented on biopsy with noncaseating epithelioid granuloma or granulomatous reaction in all but one case. In such situations, biopsy is worthwhile in order to distinguish this phenomenon from progressive stage-4 cancer disease and to not discontinue CPI treatment. Other symptoms include frequent cutaneous manifestations (nodules, rash), cough/dyspnea and arthralgia/arthritis. Uveitis, parotiditis, hypercalcemia and neurological symptoms are rarely reported [61, 62]. Of note, serum angiotensin I-converting enzyme level might be elevated or normal.

Some patients experienced systemic sclerosis [7] or scleroderma-like reaction [63–65], all presenting with skin thickening but only one with associated recent Raynaud phenomenon. None tested positive for specific autoantibodies.

Subacute cutaneous lupus erythematosus with typical erythematous eruption on trunk and/or limbs are described [66–68], as well as systemic lupus erythematosus with high titre of ANA and positivity of either anti-dsDNA or anti-SSA/SSB [66, 69]. One patient experienced CPI-induced lupus nephritis [70] and one developed Jaccoud arthropathy [71].

Differential diagnoses

In the context of advanced cancer, metastases should always be considered as a differential diagnosis of rheumatic irAEs, notably in the case of localized articular symptoms or the lack of improvement with adequate treatment

[72]. Recently, non-malignant resorptive lesions (shoulder, hand and clavicle) and rapid bone loss leading to multiple fractures with vertebral compression have also been described under CPI treatment, making the differential diagnosis with metastases even more challenging and raising the question of the potential influence of immune activation on bone metabolism [73].

In lung cancer patients, paraneoplastic syndromes such as hypertrophic osteoarthropathy occurring after CPI-onset while not present or asymptomatic at cancer diagnosis have also recently been noticed. Patients usually presented with inflammatory pain in extremities, swollen joints (with non-inflammatory synovial fluid analysis) and nail clubbing. Plain radiographs show periostitis, as illustrated with Fig. 4.

Finally, in case of fatigue and diffuse pain or weakness, central adrenal insufficiency should be suspected as it is a possible immune-related complication of CPI [74]. The diagnosis can be challenging, confirmed by the low dosage of cortisol and low Adreno CorticoTrophic Hormone. The presence of associated hypotension and hyponatremia may help to suspect an underlying endocrinopathy.

Conclusion

Rheumatic, musculoskeletal and systemic irAEs represent a new clinical entity within the field, as numbers of patients presenting with rheumatic irAE do not fulfil the traditional classification criteria of RMDs. On the other hand, it seems that some patients develop genuine classic RMDs, with possible influence of immunogenetic framework [75]. Owing to the rapid development and dissemination of CPI therapy, rheumatologists should be aware of the wide spectrum of rheumatic irAEs, with their respective clinical characteristics.

Funding: This paper was published as part of a supplement funded by an educational grant from BMS.

Disclosure statement: The authors have declared no conflicts of interest.

References

- 1 Wei SC, Duffy CR, Allison JP. Fundamental mechanisms of immune checkpoint blockade therapy. *Cancer Discov* 2018;8:1069–86.
- 2 Wolchok JD, Chiarion-Sileni V, Gonzalez R *et al*. Overall survival with combined nivolumab and ipilimumab in advanced melanoma. *N Engl J Med* 2017;377:1345–56.
- 3 Postow MA, Sidlow R, Hellmann MD. Immune-related adverse events associated with immune checkpoint blockade. *N Engl J Med* 2018;378:158–68.
- 4 Cappelli LC, Gutierrez AK, Bingham CO, Shah AA. Rheumatic and musculoskeletal immune-related adverse events due to immune checkpoint inhibitors: a systematic review of the literature. *Arthritis Care Res* 2017;69:1751–63.

- 5 Calabrese C, Kirchner E, Kontzias K, Velcheti V, Calabrese LH. Rheumatic immune-related adverse events of checkpoint therapy for cancer: case series of a new nosological entity. *RMD Open* 2017;3:e000412.
- 6 Kostine M, Rouxel L, Barnetche T *et al.* Rheumatic disorders associated with immune checkpoint inhibitors in patients with cancer-clinical aspects and relationship with tumour response: a single-centre prospective cohort study. *Ann Rheum Dis* 2018;77:393-8.
- 7 Richter MD, Crowson C, Kottschade LA *et al.* Rheumatic syndromes associated with immune checkpoint inhibitors: a single-center cohort of sixty-one patients. *Arthritis Rheumatol* 2019;71:468-75.
- 8 Cappelli LC, Gutierrez AK, Baer AN *et al.* Inflammatory arthritis and sicca syndrome induced by nivolumab and ipilimumab. *Ann Rheum Dis* 2017;76:43-50.
- 9 Le Burel S, Champiat S, Mateus C *et al.* Prevalence of immune-related systemic adverse events in patients treated with anti-Programmed cell Death 1/anti-Programmed cell Death-Ligand 1 agents: a single-centre pharmacovigilance database analysis. *Eur J Cancer* 2017;82:34-44.
- 10 Narváez J, Juárez-López P, LLuch J *et al.* Rheumatic immune-related adverse events in patients on anti-PD-1 inhibitors: fasciitis with myositis syndrome as a new complication of immunotherapy. *Autoimmun Rev* 2018;17:1040-5.
- 11 Buder-Bakhaya K, Benesova K, Schulz C *et al.* Characterization of arthralgia induced by PD-1 antibody treatment in patients with metastasized cutaneous malignancies. *Cancer Immunol Immunother* 2018;67:175-82.
- 12 Leipe J, Christ LA, Arnoldi AP *et al.* Characteristics and treatment of new-onset arthritis after checkpoint inhibitor therapy. *RMD Open* 2018;4:e000714.
- 13 Lidar M, Giat E, Garelick D *et al.* Rheumatic manifestations among cancer patients treated with immune checkpoint inhibitors. *Autoimmun Rev* 2018;17:284-9.
- 14 Kim ST, Tayar J, Trinh VA *et al.* Successful treatment of arthritis induced by checkpoint inhibitors with tocilizumab: a case series. *Ann Rheum Dis* 2017;76:2061-4.
- 15 Law-Ping-Man S, Martin A, Briens E, Tisseau L, Safa G. Psoriasis and psoriatic arthritis induced by nivolumab in a patient with advanced lung cancer. *Rheumatology* 2016;55:2087-9.
- 16 Elosua-González M, Pampín-Franco A, Mazzucchelli-Esteban R *et al.* A case of de novo palmoplantar psoriasis with psoriatic arthritis and autoimmune hypothyroidism after receiving nivolumab therapy. *Dermatol Online J* 2017;23:8.
- 17 Sपालidis K, Kosmidis C, Michalopoulos N *et al.* Psoriatic arthritis due to nivolumab administration a case report and review of the literature. *Respir Med Case Rep* 2018;23:182-7.
- 18 Amini-Adle M, Piperno M, Tordo J *et al.* Remitting seronegative symmetrical synovitis with pitting edema (RS3PE) associated with partial melanoma response under anti-CTLA-4 and anti-PD-1 combination. *Arthritis Rheumatol* 2018;70:1358.
- 19 Gauci M-L, Baroudjian B, Laly P *et al.* Remitting seronegative symmetrical synovitis with pitting edema (RS3PE) syndrome induced by nivolumab. *Semin Arthritis Rheum* 2017;47:281-7.
- 20 Ngo L, Miller E, Valen P, Gertner E. Nivolumab induced remitting seronegative symmetrical synovitis with pitting edema in a patient with melanoma: a case report. *J Med Case Rep* 2018;12:48.
- 21 Chan MMK, Kefford RF, Carlino M, Clements A, Manolios N. Arthritis and tenosynovitis associated with the anti-PD1 antibody pembrolizumab in metastatic melanoma. *J Immunother* 2015;38:37-9.
- 22 Inamo J, Kaneko Y, Takeuchi T. Inflammatory tenosynovitis and enthesitis induced by immune checkpoint inhibitor treatment. *Clin Rheumatol* 2018;37:1107-10.
- 23 Mooradian MJ, Nasrallah M, Gainor JF *et al.* Musculoskeletal rheumatic complications of immune checkpoint inhibitor therapy: a single center experience. *Semin Arthritis Rheum* 2019;48:1127-32.
- 24 Mitchell EL, Lau PKH, Khoo C *et al.* Rheumatic immune-related adverse events secondary to anti-programmed death-1 antibodies and preliminary analysis on the impact of corticosteroids on anti-tumour response: a case series. *Eur J Cancer* 2018;105:88-102.
- 25 Spathas N, Economopoulou P, Cheila M *et al.* Inflammatory arthritis induced by pembrolizumab in a patient with head and neck squamous cell carcinoma. *Front Oncol* 2018;8:409.
- 26 Kuswanto WF, MacFarlane LA, Gedmintas L *et al.* Rheumatologic symptoms in oncologic patients on PD-1 inhibitors. *Semin Arthritis Rheum* 2018;47:907-10.
- 27 Dasanu CA, Jen T, Skulski R. Late-onset pericardial tamponade, bilateral pleural effusions and recurrent immune monoarthritis induced by ipilimumab use for metastatic melanoma. *J Oncol Pharm Pract* 2017;23:231-4.
- 28 Belkhir R, Burel SL, Dunogean L *et al.* Rheumatoid arthritis and polymyalgia rheumatica occurring after immune checkpoint inhibitor treatment. *Ann Rheum Dis* 2017;76:1747-50.
- 29 Haikal A, Borba E, Khaja T, Doolittle G, Schmidt P. Nivolumab-induced new-onset seronegative rheumatoid arthritis in a patient with advanced metastatic melanoma: a case report and literature review. *Avicenna J Med* 2018;8:34-6.
- 30 Touat M, Maisonobe T, Knauss S *et al.* Immune checkpoint inhibitor-related myositis and myocarditis in patients with cancer. *Neurology* 2018;91:e985-94.
- 31 Shah M, Tayar JH, Abdel-Wahab N, Suarez-Almazor ME. Myositis as an adverse event of immune checkpoint blockade for cancer therapy. *Semin Arthritis Rheum* 2019;48:736-40.
- 32 Moreira A, Loquai C, Pföhler C *et al.* Myositis and neuromuscular side-effects induced by immune checkpoint inhibitors. *Eur J Cancer* 2019;106:12-23.
- 33 Moslehi JJ, Salem J-E, Sosman JA, Lebrun-Vignes B, Johnson DB. Increased reporting of fatal immune checkpoint inhibitor-associated myocarditis. *Lancet* 2018;391:933.
- 34 Gonzalez NL, Puwanant A, Lu A, Marks SM, Živković SA. Myasthenia triggered by immune checkpoint inhibitors:

- new case and literature review. *Neuromuscul Disord* 2017;27:266–8.
- 35 Suzuki S, Ishikawa N, Konoeda F *et al*. Nivolumab-related myasthenia gravis with myositis and myocarditis in Japan. *Neurology* 2017;89:1127–34.
 - 36 Kudo F, Watanabe Y, Iwai Y *et al*. Advanced lung adenocarcinoma with nivolumab-associated dermatomyositis. *Intern Med* 2018;57:2217–21.
 - 37 Sheik Ali S, Goddard AL, Luke JJ *et al*. Drug-associated dermatomyositis following ipilimumab therapy: a novel immune-mediated adverse event associated with cytotoxic T-lymphocyte antigen 4 blockade. *JAMA Dermatol* 2015;151:195–9.
 - 38 Zimmer L, Goldinger SM, Hofmann L *et al*. Neurological, respiratory, musculoskeletal, cardiac and ocular side-effects of anti-PD-1 therapy. *Eur J Cancer* 2016;60:210–25.
 - 39 Liewluck T, Kao JC, Mauermann ML. PD-1 Inhibitor-associated myopathies: emerging Immune-mediated Myopathies. *J Immunother* 2018;41:208–11.
 - 40 Bilen MA, Subudhi SK, Gao J *et al*. Acute rhabdomyolysis with severe polymyositis following ipilimumab-nivolumab treatment in a cancer patient with elevated anti-striated muscle antibody. *J Immunother Cancer* 2016;4:36.
 - 41 Mammen AL, Rajan A, Pak K *et al*. Pre-existing antiacetylcholine receptor autoantibodies and B cell lymphopenia are associated with the development of myositis in patients with thymoma treated with avelumab, an immune checkpoint inhibitor targeting programmed death-ligand 1. *Ann Rheum Dis* 2019;78:150–2.
 - 42 Parker MJ, Roberts ME, Lorigan PC, du Plessis DG, Chinoy H. Autoimmune fasciitis triggered by the anti-programmed cell death-1 monoclonal antibody nivolumab. *BMJ Case Rep* 2018;2018;doi:10.1136/bcr-2017-223249.
 - 43 Khoja L, Maurice C, Chappell M *et al*. Eosinophilic fasciitis and acute encephalopathy toxicity from pembrolizumab treatment of a patient with metastatic melanoma. *Cancer Immunol Res* 2016;4:175–8.
 - 44 Le Burel S, Champiat S, Routier E *et al*. Onset of connective tissue disease following anti-PD1/PD-L1 cancer immunotherapy. *Ann Rheum Dis* 2018;77:468–70.
 - 45 Takahashi S, Chieko X, Sakai T, Hirose S, Nakamura M. Nivolumab-induced sialadenitis. *Respirol Case Rep* 2018;6:e00322.
 - 46 Teyssonneau D, Cousin S, Italiano A. Gougerot-Sjogren-like syndrome under PD-1 inhibitor treatment. *Ann Oncol* 2017;28:3108.
 - 47 Ghosn J, Vicino A, Michielin O *et al*. A severe case of neuro-Sjögren's syndrome induced by pembrolizumab. *J Immunother Cancer* 2018;6:110.
 - 48 Warner BM, Baer AN, Lipson EJ *et al*. Sicca syndrome associated with immune checkpoint inhibitor therapy. *Oncologist* 2019;doi:10.1634/theoncologist.2018-0823.
 - 49 Tomelleri A, Campochiaro C, De Luca G, Cavalli G, Dagna L. Anti-PD1 therapy-associated cutaneous leucocytoclastic vasculitis: a case series. *Eur J Intern Med* 2018;57:e11–2.
 - 50 Comont T, Sibaud V, Mourey L, Cougoul P, Beyne-Rauzy O. Immune checkpoint inhibitor-related acral vasculitis. *J Immunother Cancer* 2018;6:120.
 - 51 Padda A, Schioppa E, Sovich J *et al*. Ipilimumab induced digital vasculitis. *J Immunother Cancer* 2018;6:12.
 - 52 van den Brom RRH, Abdulahad WH, Rutgers A *et al*. Rapid granulomatosis with polyangiitis induced by immune checkpoint inhibition. *Rheumatology* 2016;55:1143–5.
 - 53 Roger A, Groh M, Lorillon G *et al*. Eosinophilic granulomatosis with polyangiitis (Churg-Strauss) induced by immune checkpoint inhibitors. *Ann Rheum Dis* 2018;doi:10.1136/annrheumdis-2018/213857.
 - 54 Goldstein BL, Gedmintas L, Todd DJ. Drug-associated polymyalgia rheumatica/giant cell arteritis occurring in two patients after treatment with ipilimumab, an antagonist of ctla-4. *Arthritis Rheumatol* 2014;66:768–9.
 - 55 Hid Cadena R, Abdulahad WH, Hospers GAP *et al*. Checks and balances in autoimmune vasculitis. *Front Immunol* 2018;9:315.
 - 56 Micaily I, Chernoff M. An unknown reaction to pembrolizumab: giant cell arteritis. *Ann Oncol* 2017;28:2621–2.
 - 57 Kang A, Yuen M, Lee DJ. Nivolumab-induced systemic vasculitis. *JAAD Case Rep* 2018;4:606–8.
 - 58 Tsukamoto J, Monteiro M, Vale S *et al*. Thromboembolic events related to treatment with checkpoint inhibitors: report of two cases. *Case Rep Oncol* 2018;11:648–53.
 - 59 Firwana B, Ravilla R, Raval M, Hutchins L, Mahmoud F. Sarcoidosis-like syndrome and lymphadenopathy due to checkpoint inhibitors. *J Oncol Pharm Pract* 2017;23:620–4.
 - 60 Lomax AJ, McGuire HM, McNeil C *et al*. Immunotherapy-induced sarcoidosis in patients with melanoma treated with PD-1 checkpoint inhibitors: case series and immunophenotypic analysis. *Int J Rheum Dis* 2017;20:1277–85.
 - 61 Dunn-Pirio AM, Shah S, Eckstein C. Neurosarcoidosis following immune checkpoint inhibition. *Case Rep Oncol* 2018;11:521–6.
 - 62 Tan I, Malinzak M, Salama AKS. Delayed onset of neuro-sarcoidosis after concurrent ipilimumab/nivolumab therapy. *J Immunother Cancer* 2018;6:77.
 - 63 Tjarks BJ, Kerkvliet AM, Jassim AD, Bleeker JS. Scleroderma-like skin changes induced by checkpoint inhibitor therapy. *J Cutan Pathol* 2018;45:615–8.
 - 64 Shenoy N, Esplin B, Barbosa N *et al*. Pembrolizumab induced severe sclerodermoid reaction. *Ann Oncol* 2017;28:432–3.
 - 65 Barbosa NS, Wetter DA, Wieland CN *et al*. Scleroderma induced by pembrolizumab: a case series. *Mayo Clin Proc* 2017;92:1158–63.
 - 66 Michot J-M, Fusellier M, Champiat S *et al*. Drug-induced lupus erythematosus following immunotherapy with anti-programmed death-(ligand) 1. *Ann Rheum Dis* 2019;78:e67.
 - 67 Zitouni NB, Arnault J-P, Dadban A *et al*. Subacute cutaneous lupus erythematosus induced by nivolumab: two case reports and a literature review. *Melanoma Res* 2019;29:212–5.
 - 68 Liu RC, Sebaratnam DF, Jackett L, Kao S, Lowe PM. Subacute cutaneous lupus erythematosus

- induced by nivolumab. *Australas J Dermatol* 2018;59:e152–4.
- 69 de Chabot G, Justeau G, Pinquié F *et al.* [Unexpected adverse events of immunotherapies in non-small cell lung cancer: about 2 cases]. *Rev Pneumol Clin* 2017;73:326–30.
- 70 Fadel F, El Karoui K, Knebelmann B. Anti-CTLA4 antibody-induced lupus nephritis. *N Engl J Med* 2009;361:211–2.
- 71 de Velasco G, Bermas B, Choueiri TK. Autoimmune arthropathy and uveitis as complications of programmed death 1 inhibitor treatment. *Arthritis Rheumatol* 2016;68:556–7.
- 72 Albayda J, Bingham CO, Shah AA, Kelly RJ, Cappelli L. Metastatic joint involvement or inflammatory arthritis? A conundrum with immune checkpoint inhibitor-related adverse events. *Rheumatology* 2018;57:760–2.
- 73 Moseley KF, Naidoo J, Bingham CO *et al.* Immune-related adverse events with immune checkpoint inhibitors affecting the skeleton: a seminal case series. *J Immunother Cancer* 2018;6:104.
- 74 Nagasaka M, Abdallah N, Samantray J, Sukari A. Is this really just 'fatigue'? A case series of immune-related central adrenal insufficiency secondary to immune checkpoint inhibitors. *Clin Case Rep* 2018;6:1278–81.
- 75 van der Vlist M, Kuball J, Radstake TRD, Meyaard L. Immune checkpoints and rheumatic diseases: what can cancer immunotherapy teach us? *Nat Rev Rheumatol* 2016;12:593–604.