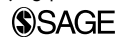

Magnetic resonance venography to assess thrombus resolution with edoxaban monotherapy versus parenteral anticoagulation/warfarin for symptomatic deep vein thrombosis: A multicenter feasibility study

Vascular Medicine
2016, Vol. 21(4) 361–368
© The Author(s) 2016



Reprints and permissions:
sagepub.co.uk/journalsPermissions.nav
DOI: 10.1177/1358863X16645853
vmj.sagepub.com



Gregory Piazza¹, Venkatesh Mani², Samuel Z Goldhaber¹, Michael A Grosso³, Michele Mercuri³, Hans J Lanz³, Steven Schussler³, Ching Hsu³, Amy Chinigo³, Bruce Ritchie⁴, Venkatesh Nadar⁵, Kevin Cannon⁶, John Pullman⁷, Mauricio Concha⁸, Marlin Schul⁹ and Zahi A Fayad²; for the edoxaban Thrombus Reduction Imaging Study (eTRIS) Investigators

Abstract

The feasibility of magnetic resonance venography (MRV) for measuring change in thrombus volume with a novel anticoagulation regimen versus standard anticoagulation in patients with symptomatic deep vein thrombosis (DVT) has not been assessed. Our aim was to study the feasibility of MRV to measure change in thrombus volume in patients with acute symptomatic objectively confirmed proximal DVT in an open-label multicenter trial (edoxaban Thrombus Reduction Imaging Study, eTRIS). We randomized patients in a 2:1 allocation ratio to edoxaban 90 mg/day for 10 days followed by 60 mg/day versus parenteral anticoagulation bridging to warfarin for 3 months. The primary efficacy outcome was a surrogate end point of the relative change in MRV-quantified thrombus volume from baseline to Day 14–21. A total of 85 eligible patients from 26 study sites were randomized to edoxaban monotherapy ($n=56$) versus parenteral anticoagulation as a ‘bridge’ to warfarin ($n=29$). The mean relative change in MRV-quantified thrombus volume from baseline to Day 14–21 was similar in patients treated with edoxaban and parenteral anticoagulation as a ‘bridge’ to warfarin (–50.1% vs –58.9%; 95% confidence interval of treatment difference, –12.7%, 30.2%). However, thrombus extension was observed in eight patients in the edoxaban monotherapy group and in none in the warfarin group. Rates of recurrent venous thromboembolism (3.6% vs 3.6%, $p=0.45$) and clinically relevant non-major bleeding (5.4% vs 7.1%, $p=0.34$) were also similar. No major bleeds occurred in either on-treatment group during the study period. In conclusion, MRV can assess change in thrombus volume in patients with acute DVT randomized to two different anticoagulant regimens.

ClinicalTrials.gov Identifier: NCT01662908

Investigational New Drug (IND) Application: Edoxaban IND # 63266

Keywords

anticoagulation, deep vein thrombosis, edoxaban, magnetic resonance, MRV, venous thromboembolism eTRIS

Introduction

Magnetic resonance venography (MRV) has diagnostic accuracy equivalent or superior to venous ultrasonography for acute deep vein thrombosis (DVT).^{1–5} MRV allows for more accurate determination of thrombus volume and is not limited by edema or depth of venous segments. MRV with direct thrombus imaging has the additional advantages of more precise differentiation of acute versus chronic DVT⁶ and more accurate detection of changes in thrombus volume over time.⁷ In acute DVT trials comparing anticoagulation regimens, the extent of thrombus volume reduction over time has not been evaluated using MRV.

We conducted this multicenter randomized controlled trial to evaluate the feasibility of MRV as a thrombus

¹Cardiovascular Division, Department of Medicine, Brigham and Women’s Hospital, Harvard Medical School, Boston, MA, USA

²Translational and Molecular Imaging Institute, Icahn School of Medicine at Mount Sinai, New York, NY, USA

³Daiichi Sankyo Pharma Development, Edison, NJ, USA

⁴Division of Hematology, Department of Medicine, University of Alberta, Edmonton, AB, Canada

⁵Lewin and Nadar Cardiology Associates, Camp Hill, PA, USA

⁶Wilmington Health, Wilmington, NC, USA

⁷St James Healthcare, Butte, MT, USA

⁸Intercoastal Medical Group, Sarasota, FL, USA

⁹Lafayette Regional Vein and Laser Center, Lafayette, IN, USA

Corresponding author:

Gregory Piazza, Cardiovascular Division, Brigham and Women’s Hospital, 75 Francis St, Boston, MA 02115, USA.

Email: gpiazza@partners.org

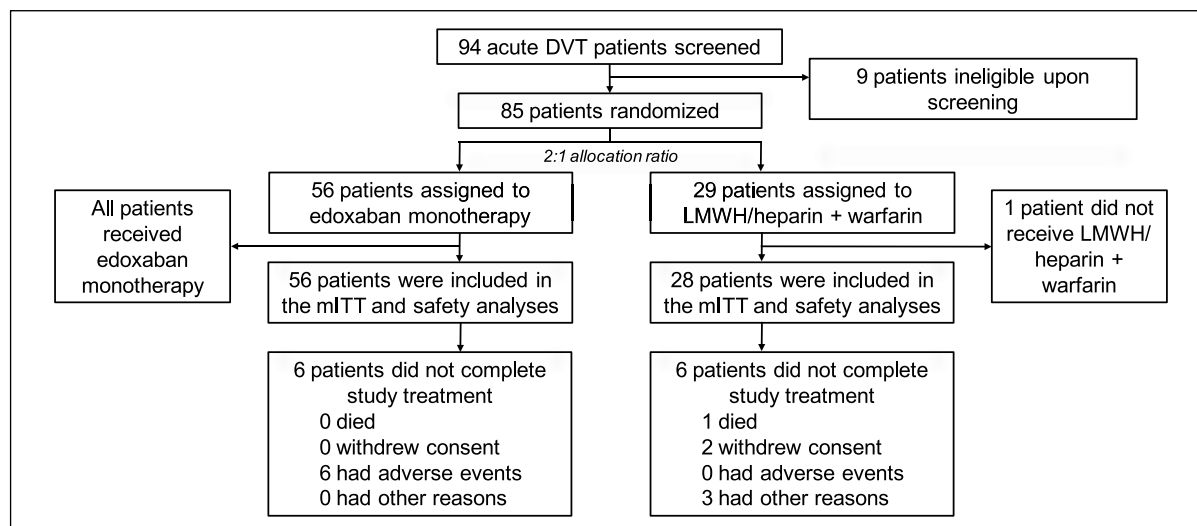


Figure 1. Flow of patients through each stage of the trial. (DVT, deep vein thrombosis; LMWH, low-molecular weight heparin; mITT, modified intention-to-treat.)

imaging tool and to assess the relative change in thrombus volume with MRV in patients with acute DVT treated with either oral monotherapy with edoxaban versus parenteral heparin as a ‘bridge’ to oral anticoagulation with warfarin.

Methods

Study design

The study was a randomized, open-label, parallel-group, active-control, multicenter trial. From September 2012 to January 2014, we screened 94 patients with acute DVT (Figure 1). Study patients were enrolled at 26 sites across the USA, including urban, non-urban, teaching, and non-teaching hospitals. Institutional Review Board approval was obtained at all sites. All index DVT and all recurrent DVT, bleeding, major adverse cardiac events, death, and hepatic events were evaluated via a centralized, blinded adjudication process.

Study population

Eligible patients were required to have acute, symptomatic DVT involving the popliteal, femoral, or iliac vein (Supplementary material). Symptom onset could be no longer than 1 week prior to randomization. Diagnosis of DVT required one of the following: a non-compressible vein on ultrasonography, an intraluminal filling defect on contrast venography, or an intraluminal filling defect on contrast-enhanced computed tomography (CT). Patients diagnosed with concomitant pulmonary embolism (PE) at the time of randomization were excluded (Supplementary material).

Up to 48 hours of LMWH or unfractionated heparin and/or a single dose of warfarin were permitted prior to randomization. Patients with greater than 48 hours of anticoagulation prior to potential randomization were excluded. Patients were randomized with a web-based system in a 2:1 allocation

ratio to either edoxaban monotherapy or a parenteral anticoagulant ‘bridge’ of LMWH or unfractionated heparin to warfarin. Written informed consent was obtained from each study patient.

Enrollment was planned to continue until 90 patients were randomized across both treatment groups. Owing to slow enrollment, the study was discontinued by the sponsor after 85 patients had been randomized.

Anticoagulation

Subjects randomized to the edoxaban monotherapy arm received edoxaban 90 mg once daily for 10 days (± 2 days) followed by 60 mg once daily for approximately 90 days. After randomization, patients assigned to edoxaban monotherapy were stratified by need for dose reduction (body weight ≤ 60 kg or creatinine clearance (CrCL) between ≥ 30 ml/min and ≤ 50 ml/min). Patients stratified to the dose reduction arm received 45 mg once daily for 10 days followed by 30 mg once daily for a total of approximately 90 days. The study protocol allowed for concomitant aspirin use up to 100 mg daily.

For patients randomized to parenteral anticoagulation as a ‘bridge’ to oral anticoagulation with warfarin, parenteral anticoagulation with open-label subcutaneous enoxaparin (1 mg/kg twice daily or 1.5 mg/kg once daily) or intravenous unfractionated heparin was administered as soon as possible after randomization for at least 5 days. Open-label warfarin was started approximately at the same time as enoxaparin or unfractionated heparin. As soon as an international normalized ratio (INR) ≥ 2 was achieved on two consecutive days or a single INR > 3 was achieved, parenteral anticoagulation was stopped, and warfarin was continued to maintain the INR target range of 2.0–3.0.

Magnetic resonance venography

The study mandated two MRV examinations. The first study was performed within 36 hours after randomization,

and the second was performed between days 14 and 21 after randomization. All images were analyzed by a Core Imaging Laboratory (Translational and Molecular Imaging Institute, Icahn School of Medicine at Mount Sinai, New York, NY, USA).

For each imaging time point, bilateral lower extremity and lower pelvis MRV with contrast was performed in a single examination of approximately 60 minutes.⁸ For subjects with normal renal function (creatinine clearance > 60 ml/min), a dose of 0.03 mmol/kg (0.12 ml/kg) Ablavar[®] (gadofosveset trisodium; Lantheus Medical Imaging, North Billerica, MA, USA) was injected at a rate of 2 ml/second.⁹ Ablavar is a blood pool contrast agent with favorable properties for venous imaging.

After acquiring scout and time-of-flight images to identify the arterial vasculature, three dimensional (3D) T1-weighted gradient echo images (GRE; VIBE, LAVA) were acquired before and after the injection of Ablavar to estimate thrombus volume. Thrombus volume was assessed utilizing contrast-enhanced MRV images after the contrast agent circulated for 5 minutes to ensure a steady state in the blood pool. To determine locations and extent of thrombus, pre- and post-contrast 3D gradient echo sequences were acquired from: (1) the mid-calf to above the knee, (2) above the knee to the thigh and lower pelvis, and (3) thigh and lower pelvis to abdomen.

Image analysis (Supplementary material) was performed on a dedicated workstation (Apple Mac Pro[®] with OsiriX MD) by two treatment-blinded experienced image analysts. Baseline and follow-up MRV images were compared for each subject for the following venous segments: external iliac, common femoral, superficial femoral, deep femoral, popliteal, anterior tibial, posterior tibial, gastrocnemius, and peroneal veins.

For MRV images, analysts traced 3D curved multiplanar reconstructions, using contours following the centerline of each venous segment, and produced 1 mm axial slices perpendicular to the curved path. Analysts then manually segmented regions of interest corresponding to the thrombus. Thrombus volume was calculated by multiplying the area of interest (thrombus) by the slice thickness (1 mm) using a custom MATLAB (Mathworks Inc., Natick, MA, USA) script. Total thrombus volume in each subject was calculated by adding the thrombus volumes in each vessel.

The eTRIS-DVT total score was calculated as the sum of the individual modified Oral Direct Factor Xa Inhibitor Deep Vein Thrombosis (ODIXa-DVT) vessel score for vessels in which thrombus was present. The ODIXa-DVT score is a validated method for calculating thrombus burden based on the finding of non-compressibility on venous ultrasonography in prespecified venous segments.¹⁰ The eTRIS volumetric DVT total score was calculated as the product of the thrombus volume in the vessel and the modified ODIXa-DVT score for that vessel.

Clinical follow-up

Clinical follow-up visits were performed on post-randomization Day 10 ± 2, Day 14–21, Day 45 ± 4, Day 90 ± 7, and

Day 120 ± 7 (30 days post-study drug completion). All subjects who permanently stopped taking the study drug were expected to have a follow-up visit 30 days later. Overall, 82 of the 85 patients randomized (96.5%) completed the 30-day follow-up visit. Study subjects were evaluated for recurrent DVT, PE, bleeding, myocardial infarction (MI), stroke, systemic embolic events, hepatic events, and death, as well as any other adverse event.

Outcomes

The primary efficacy outcome was a surrogate end point of the relative change in thrombus volume assessed by MRV from baseline to Day 14–21. Secondary efficacy outcomes included recurrence of venous thromboembolism (VTE), defined as a composite of adjudicated recurrent DVT, PE, or VTE-related death (Supplementary material), and change from baseline to Day 14–21 in the presence or absence of thrombus by venous segment as detected by MRV. A reduction in thrombotic burden was defined as any decrease in thrombus volume on MRV and no adjudicated recurrent VTE.

The primary safety outcome was clinically relevant bleeding (International Society on Thrombosis and Haemostasis major or clinically relevant non-major bleeding) (Supplementary material).¹¹ All other overt bleeding not meeting criteria for major or clinically relevant non-major bleeding was classified as nuisance bleeding. All bleeding events were adjudicated by a Clinical Endpoints Committee blinded to treatment allocation.

Statistical analysis

The total intended sample size of approximately 90 subjects (60 in the edoxaban group, 30 in the parenteral anticoagulant ‘bridge’ to warfarin group) was chosen based on study feasibility, rather than on statistical considerations. To collect more information of relative thrombus volume change by MRV in the edoxaban treatment group, a 2:1 randomization allocation ratio was used.

Results for continuous variables were compared to baseline using a paired *t*-test or Wilcoxon signed rank test. For two-group comparisons, a two-sample *t*-test or Wilcoxon rank sum was used for continuous data, and Fisher’s exact test was used for binary data. All *p*-values were two-sided, and a *p*-value of < 0.05 was considered statistically significant.

The primary efficacy analysis was based on the modified intention-to-treat (mITT) analysis set: all randomized subjects who received at least one dose of randomized study drug. The primary safety analysis (on-treatment) was performed using the safety analysis set: all randomized subjects who received at least one dose of randomized study drug according to the treatment actually received. Data analyses were performed using software SAS Version 8.2 (SAS Institute, Cary, NC, USA).

The relative change of thrombus volume from baseline was calculated as the difference between Day 14–21 and baseline measurements divided by the baseline

Table 1. Demographic and baseline characteristics.

Variable	Edoxaban <i>n</i> = 56	LMWH or unfractionated heparin/warfarin <i>n</i> = 28
Mean age ± SD, years	55.6 ± 14.1	53.1 ± 12
Male, <i>n</i> (%)	41 (73.2)	21 (75)
Race, <i>n</i> (%)		
Caucasian	43 (76.8)	21 (92.9)
Black	11 (19.6)	2 (7.1)
Other	2 (3.6)	0 (0)
Met criteria for dose reduction at randomization, <i>n</i> (%)	2 (3.6)	2 (7.1)
Weight ≤ 60 kg	1 (1.8)	1 (3.6)
CrCl ≥ 30 to ≤ 50 ml/min	1 (1.8)	1 (3.6)
Pulmonary disease, <i>n</i> (%)	16 (28.6)	7 (25)
Recent bone fracture, <i>n</i> (%)	14 (25)	6 (21.4)
Active tobacco use, <i>n</i> (%)	12 (21.4)	5 (17.9)
History of cancer, <i>n</i> (%)	10 (17.9)	3 (10.7)
Cardiovascular disease, <i>n</i> (%)	9 (16.1)	4 (14.3)
Concomitant antiplatelet therapy, <i>n</i> (%)	9 (16.1)	1 (3.6)
Liver disease, <i>n</i> (%)	7 (12.5)	4 (14.3)
Renal disease, <i>n</i> (%)	6 (10.7)	1 (3.6)
P-gp inhibitors requiring edoxaban dose reduction, <i>n</i> (%)	2 (3.6)	0 (0)

LMWH, low-molecular weight heparin; SD, standard deviation; CrCl, creatinine clearance; P-gp, P-glycoprotein.

measurement, then multiplied by 100. The relative change from baseline was summarized within each group and compared by providing the treatment difference and a 95% confidence interval (CI) of the difference. The relative change from baseline (MRV measurement) at Day 14–21 was also analyzed using an analysis of covariance (ANCOVA) model with treatment group and stratum as factors and baseline measurement as a covariate. The composite of recurrent DVT, PE, or VTE-related death was summarized by treatment, and a 95% CI was generated for the difference between the two groups for the mITT analysis set.

Of a total trial population of 85 patients, 56 were randomized to edoxaban monotherapy and 29 to a parenteral anticoagulant ‘bridge’ (with unfractionated heparin or LMWH) to warfarin (Figure 1). One patient randomized to parenteral anticoagulation as a ‘bridge’ to warfarin did not receive the assigned therapy due to withdrawal of consent.

Seven individuals in the edoxaban monotherapy group and two in the warfarin group did not have a Day 14–21 MRV assessment (resulting in 49 in the edoxaban group and 26 in the parenteral anticoagulant ‘bridge’ to warfarin group). Three patients (one in the edoxaban monotherapy group and two in the parenteral anticoagulant ‘bridge’ to warfarin group) no longer had visible thrombus at the time of the baseline MRV, despite having DVT visualized on compression venous ultrasound at the time of diagnosis (all index DVTs were adjudicated by a blinded reviewer). Therefore, the primary MRV variable was reported for 72 subjects in total (48 in the edoxaban monotherapy group and 24 in the parenteral anticoagulant ‘bridge’ to warfarin group) for the mITT and per protocol analyses.

Results

Baseline demographics and clinical characteristics

Mean age was 55.6 years in the edoxaban monotherapy group and 53.1 years in the parenteral anticoagulant ‘bridge’ to warfarin group (Table 1). Among patients randomized to edoxaban monotherapy, two patients (3.6%) met criteria for the prespecified dose reduction. Two additional patients (3.6%) in the edoxaban monotherapy group required post-randomization dose reduction because of concomitant P-glycoprotein (P-gp) inhibitor administration.

DVT was unprovoked (idiopathic) in 52% of patients randomized to edoxaban monotherapy and in 64% of those assigned to LMWH or unfractionated heparin as a ‘bridge’ to warfarin (Table 2). The mean time from symptom onset to randomization was similar in the two groups (4.7 days vs 4.8 days). Anticoagulation was started within 48 hours of randomization in nearly 90% of patients in both groups.

Mean and median times within the therapeutic range for the INR in patients assigned to LMWH or unfractionated heparin as a ‘bridge’ to oral anticoagulation with warfarin were 60.9% and 64.5%, respectively.

MRV-determined change in thrombus volume

Baseline mean total thrombus volume measured by MRV was smaller in the edoxaban monotherapy group compared with the parenteral anticoagulant ‘bridge’ to warfarin group (6994 cm³ vs 12,683 cm³). The least squares mean change in thrombus volume from baseline to Day 14–21 was

Table 2. Clinical characteristics of deep vein thrombosis (DVT).

Variable	Edoxaban <i>n</i> = 56	LMWH or unfractionated heparin/warfarin <i>n</i> = 28
Provoked DVT, <i>n</i> (%)	27 (48.2)	10 (35.7)
Unprovoked DVT, <i>n</i> (%)	29 (51.8)	18 (64.3)
Mean days between onset of symptoms and randomization ± SD	4.7 ± 1.9	4.8 ± 1.8
Anticoagulation started within 48 hours of randomization, <i>n</i> (%)	51 (91.1)	25 (89.3)

LMWH, low-molecular weight heparin; SD, standard deviation.

Table 3. Change in thrombus volume as measured by magnetic resonance venography (MRV) based on modified intention-to-treat analysis.

	Edoxaban (<i>n</i> = 48)			LMWH or unfractionated heparin/warfarin (<i>n</i> = 24)		
	Baseline	Day 14–21	% change	Baseline	Day 14–21	% change
Mean total thrombus volume ± SD, mm ³	6994.0 ± 9053.6	4055.5 ± 6796.8	−46.6 ± 45.53	12,683.1 ± 13,572.1	7952.9 ± 11,413.4	−51.4 ± 33.0
Least squares (geometric) mean change (95% CI)			−50.1 (−76.0, −24.3)			−58.9 (−87.1, −30.8)
Difference between the means (95% CI)						8.8 (−12.7, 30.2)

LMWH, low-molecular weight heparin; SD, standard deviation; CI, confidence interval.

−50.1% for the edoxaban monotherapy group and −58.9% for the warfarin group, with a difference in means of 8.8% (95% confidence interval (CI), −12.7, 30.2) in the mITT analysis (Table 3). An example of MRV-assessed thrombus volume reduction of 60% from baseline to follow-up in a patient with acute DVT treated with edoxaban monotherapy is shown in Figure 2. There was no difference in the change in thrombus volume between the mITT and the per protocol analyses. In the mITT analysis, thrombus volume decreased from baseline to Day 14–21 in 81.6% of patients in the edoxaban monotherapy group and in 92.3% in the warfarin group (Table 4). Thrombus extension was observed in eight patients in the edoxaban monotherapy group and in none in the warfarin group. Of note, in six of these eight patients, the initial DVTs were very small at baseline (< 0.05 cm³) with relatively small changes in absolute volume at Day 14–21.

We performed a reproducibility analysis limited to the three highest-enrolling centers and found no difference in the primary efficacy end point.

Secondary efficacy outcomes

Decreased thrombotic burden, defined as any decrease in thrombus volume on MRV and no adjudicated recurrent VTE, was observed in 81.6% of patients in the edoxaban monotherapy group and 88.5% of patients in the warfarin group (Table 4). Three patients (6.3%) in the edoxaban monotherapy group and two (8.3%) in the warfarin group had resolution of the entire thrombus volume. The mean change in the eTRIS-DVT total score from baseline to Day 14–21 was identical in both treatment groups (−0.8). The mean percent change in the eTRIS volumetric DVT total score from baseline to Day 14–21 was −42.1% in the edoxaban monotherapy group and −40.3% in the warfarin group.

In the mITT analysis, adjudicated recurrent VTE occurred in two patients in the edoxaban monotherapy group (3.6%) and in one patient in the warfarin group (3.6%). In the edoxaban monotherapy group, one patient suffered a non-fatal PE, and one developed a new DVT. One patient in the warfarin group suffered a non-fatal PE.

Safety outcomes

Adjudicated bleeding events during the on-treatment period occurred in 17.9% of patients in the edoxaban monotherapy group and 17.9% in the warfarin group (Table 5). Major or clinically relevant non-major bleeding occurred in 5.4% of patients in the edoxaban monotherapy group and 7.1% in the warfarin group. No serious adverse events were attributed to edoxaban. However, one warfarin patient suffered a fatal subdural hematoma on Day 76. Adjudicated clinically relevant non-major or nuisance bleeding events in the initial 10 days of treatment were more common for patients in the edoxaban monotherapy group (*n* = 7) than for those in the parenteral anticoagulant ‘bridge’ to warfarin group (*n* = 2) (12.5% vs 7.1%).

One patient in the edoxaban monotherapy group suffered non-fatal MI, and another suffered a non-fatal stroke. The non-fatal MI occurred in an 82-year-old man with known coronary artery disease, obesity, hypertension, hypercholesterolemia, diabetes, peripheral artery disease, aortic stenosis, renal artery stenosis, chronic iron deficiency anemia, and heart failure on Day 4 of edoxaban therapy. The acute ischemic stroke occurred in a 63-year-old man with widely metastatic pancreatic cancer on Day 22 of edoxaban therapy, and was not in the setting of atrial fibrillation.

Discussion

Our aim was to evaluate the feasibility of MRV for comparing change in thrombus volume between an oral regimen of

once daily edoxaban 90 mg for 10 days followed by 60 mg versus conventional anticoagulation with a parenteral anticoagulant as a 'bridge' to warfarin. Overall thrombus volume regression was similar in both groups. However, a subset of patients in the edoxaban monotherapy group

(16.7%) experienced an increase in thrombus volume on follow-up MRV. This observation suggests that initial parenteral anticoagulation may be important for treatment with edoxaban. In the HOKUSAI-VTE trial, parenteral anticoagulation followed by oral edoxaban¹² was shown to have

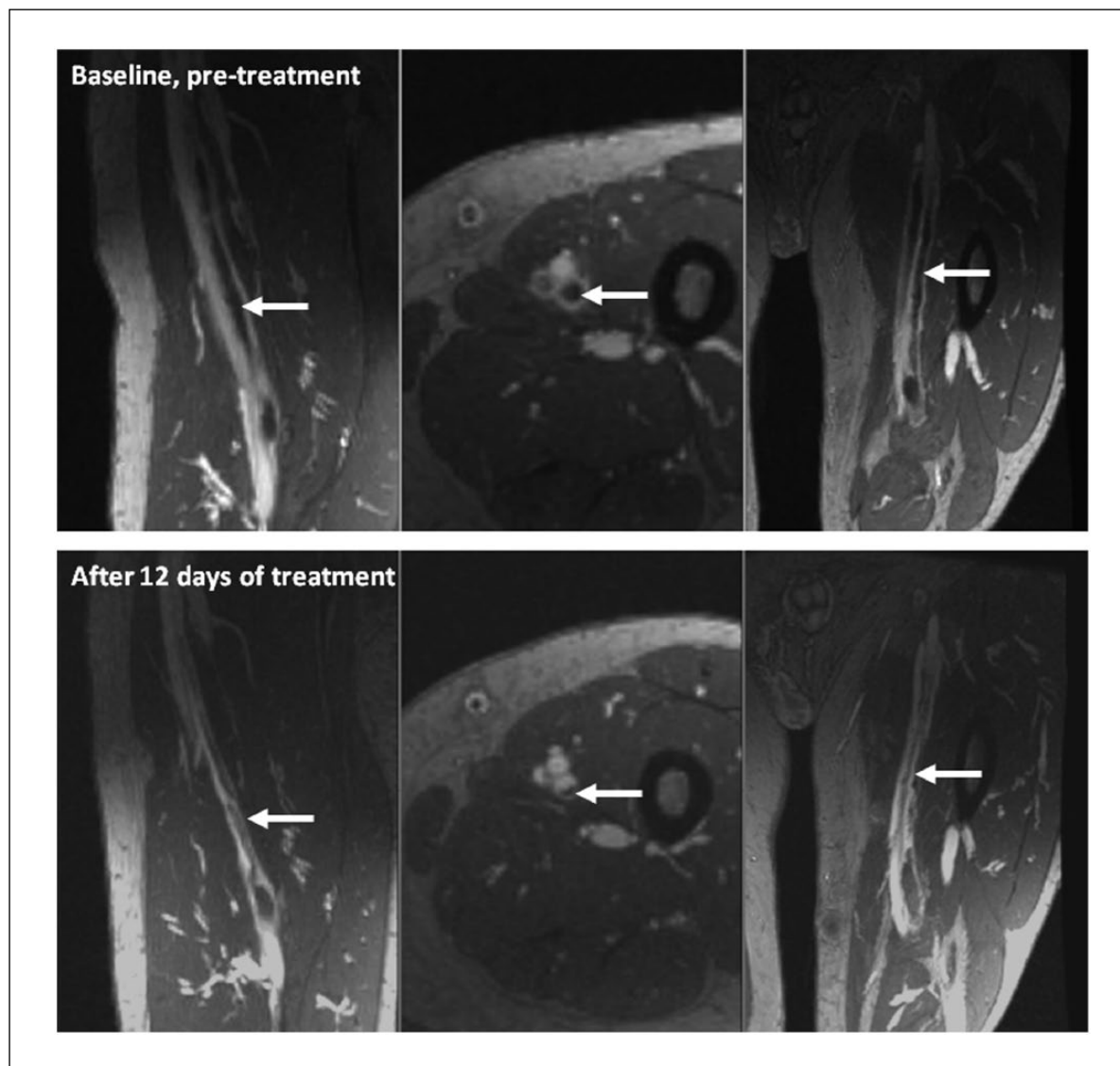


Figure 2. Thrombus volume reduction of 60% from baseline to follow-up as measured by magnetic resonance venography (MRV) in a patient with acute deep vein thrombosis (arrows) randomized to treatment with edoxaban.

Table 4. Thrombotic burden as measured by magnetic resonance venography (MRV) in the modified intention-to-treat analysis.

	Edoxaban (n = 56)	LMWH or unfractionated heparin/warfarin (n = 28)
Freedom from adjudicated recurrent VTE, n (%)	54 (96.4)	27 (96.4)
Improvement in thrombus volume ^a , n (%)	40 (81.6)	24 (92.3)
Improved thrombotic burden ^b , n (%)	40 (81.6)	23 (88.5)
Thrombus extension ^c , n (%)	8 (16.7)	0 (0)

LMWH, low-molecular weight heparin; VTE, venous thromboembolism; MRV, magnetic resonance venography.

^aImprovement in thrombus volume and thrombotic burden is based on number of subjects with MRV assessment at baseline and Day 14–21; n = 48 for the edoxaban monotherapy group and n = 24 for the parenteral anticoagulant 'bridge' to warfarin group.

^bImproved thrombotic burden = any improvement in thrombus volume as measured by MRV and no adjudicated recurrent VTE (deep vein thrombosis, non-fatal pulmonary embolism, or VTE-related death). Based on number of subjects with MRV assessment at baseline and Day 14–21, n = 48 for the edoxaban monotherapy group and n = 24 for the parenteral anticoagulant 'bridge' to warfarin group.

^cBased on number of subjects with MRV assessment at baseline and Day 14–21, n = 48 for the edoxaban monotherapy group and n = 24 for the parenteral anticoagulant 'bridge' to warfarin group.

Table 5. Adjudicated bleeding events in the safety analysis during the on-treatment period.^a

	Edoxaban (n = 56)	LMWH or unfractionated heparin/warfarin (n = 28)
Adjudicated confirmed bleeding events, n (%)	10 (17.9)	5 (17.9)
Major or clinically relevant non-major bleeding, n (%)	3 (5.4)	2 (7.1)
Major bleeding, n (%)	0 (0)	0 (0)
Fatal bleeding, n (%)	0 (0)	0 (0)
Intracranial hemorrhage, n (%)	0 (0)	0 (0)
Clinically relevant non-major bleeding, n (%)	3 (5.4)	2 (7.1)
Nuisance bleeding, n (%)	9 (16.1)	3 (10.7)

LMWH, low-molecular weight heparin.

^aThe median duration of treatment was 91 days and 88.5 days in the edoxaban monotherapy and the parenteral anticoagulant 'bridge' to warfarin groups, respectively. The median duration of study drug exposure was 90.5 days and 86 days in the edoxaban monotherapy and the parenteral anticoagulant 'bridge' to warfarin groups, respectively.

similar efficacy and improved safety compared with parenteral anticoagulant as a 'bridge' to warfarin for the treatment of acute DVT.

MRV is a reproducible and quantitative tool for assessment of changes in lower extremity venous thrombus volume.⁷ We believe this is the first study to evaluate change in thrombus volume with MRV in this patient population. Compared with venous ultrasound, MRV provides a more comprehensive and contiguous assessment of the presence of thrombus as well as volumetric analysis. Unlike conventional venography, MRV is non-invasive. Compared with CT venography, MRV avoids ionizing radiation and iodinated contrast. Thus, MRV shows promise as a research tool. Advanced non-contrast and non-gadolinium-based MRI techniques hold promise as research tools for thrombus imaging and clinical diagnosis of DVT.^{13,14}

Limitations

Our study had limitations. Fifteen percent of patients did not have a complete set of MRV examinations performed within the Day 14–21 interval. This incomplete follow-up may compromise the primary efficacy outcome analysis and interpretation. Our study stopped short of the planned 90-patient enrollment due to slow patient accrual. Lack of statistical power may have impacted our ability to detect a difference, in either direction, in thrombus volume as assessed by MRV as well as clinical outcomes. Despite randomization, the two study groups demonstrated important differences, most notably in baseline thrombus volume. The difference in initial thrombus burden may have biased our analysis of the change in thrombus volume.

Strengths

Our study had certain strengths. We utilized quantitative MRV as a clinical research tool among many different types of study sites. We evaluated a novel oral monotherapy dosing regimen for edoxaban in a rigorous randomized controlled trial setting for the treatment of acute symptomatic DVT. Finally, we obtained clinical follow-up in 96.5% of study patients.

Conclusions

MRV can assess change in thrombus volume in patients randomized to two different anticoagulant regimens. The

subset of patients in the edoxaban monotherapy group that experienced an increase in thrombus volume on follow-up MRV suggests that initial parenteral anticoagulation may be important for treatment with edoxaban.

Declaration of conflicting interests

Dr Piazza receives research grant support from Daiichi Sankyo, EKOS, a BTG International Group company, Bristol Myers Squibb, and Janssen. Dr Mani receives consulting fees from Tursiop Inc. and research grant support from Novartis AG and Daiichi Sankyo. Dr Goldhaber receives research grant support from Daiichi Sankyo, EKOS, a BTG International Group company, Bristol Myers Squibb, and Janssen. Drs Grosso, Mercuri, Lanz, Hsu, and Chinigo and Mr Schussler receive salary from Daiichi Sankyo. Drs Ritchie, Nadar, Cannon, Pullman, Concha, Schul, and Fayad receive research grant support from Daiichi Sankyo.

Funding

The authors disclosed receipt of the following financial support for the research, authorship, and/or publication of this article: research grant from Daiichi Sankyo.

Role of sponsor

The sponsor of the study had no role in the data interpretation. GP, VM, SZG, and ZAF had full access to the data and had the final responsibility for the decision to submit for publication.

Supplementary material

The supplementary material is available at <http://vmj.sagepub.com>

References

1. Abdalla G, Fawzi Matuk R, Venugopal V, et al. The diagnostic accuracy of magnetic resonance venography in the detection of deep venous thrombosis: A systematic review and meta-analysis. *Clin Radiol* 2015; 70: 858–871.
2. Enden T, Storås TH, Negard A, et al. Visualization of deep veins and detection of deep vein thrombosis (DVT) with balanced turbo field echo (b-TFE) and contrast-enhanced T1 fast field echo (CE-FFE) using a blood pool agent (BPA). *J Magn Reson Imaging* 2010; 31: 416–424.
3. Kluge A, Mueller C, Strunk J, et al. Experience in 207 combined MRI examinations for acute pulmonary embolism and deep vein thrombosis. *AJR Am J Roentgenol* 2006; 186: 1686–1696.
4. Ono A, Murase K, Taniguchi T, et al. Deep venous thrombosis: Diagnostic value of non-contrast-enhanced

- MR venography using electrocardiography-triggered three-dimensional half-Fourier FSE. *Magn Reson Med* 2010; 64: 88–97.
5. Sampson FC, Goodacre SW, Thomas SM, et al. The accuracy of MRI in diagnosis of suspected deep vein thrombosis: Systematic review and meta-analysis. *Eur Radiol* 2007; 17: 175–181.
 6. Tan M, Mol GC, van Rooden CJ, et al. Magnetic resonance direct thrombus imaging differentiates acute recurrent ipsilateral deep vein thrombosis from residual thrombosis. *Blood* 2014; 124: 623–627.
 7. Westerbeek RE, Van Rooden CJ, Tan M, et al. Magnetic resonance direct thrombus imaging of the evolution of acute deep vein thrombosis of the leg. *J Thromb Haemost* 2008; 6: 1087–1092.
 8. Mani V, Alie N, Ramachandran S, et al. A multicenter MRI protocol for the evaluation and quantification of deep vein thrombosis. *J Vis Exp* 2015; (100): e52761.
 9. Partovi S, Aschwanden M, Staub D, et al. Gadofosveset enhanced MR phlebography for detecting pelvic and deep vein leg thrombosis. *Vasa* 2011; 40: 315–319.
 10. Agnelli G, Gallus A, Goldhaber SZ, et al. Treatment of proximal deep-vein thrombosis with the oral direct factor Xa inhibitor rivaroxaban (BAY 59–7939): The ODIXa-DVT (Oral Direct Factor Xa Inhibitor BAY 59–7939 in Patients With Acute Symptomatic Deep-Vein Thrombosis) study. *Circulation* 2007; 116: 180–187.
 11. Schulman S, Kearon C. Definition of major bleeding in clinical investigations of antihemostatic medicinal products in non-surgical patients. *J Thromb Haemost* 2005; 3: 692–694.
 12. Buller HR, Decousus H, Grosso MA, et al. Edoxaban versus warfarin for the treatment of symptomatic venous thromboembolism. *N Engl J Med* 2013; 369: 1406–1415.
 13. Temme S, Grapentin C, Quast C, et al. Noninvasive imaging of early venous thrombosis by ¹⁹F magnetic resonance imaging with targeted perfluorocarbon nanoemulsions. *Circulation* 2015; 131: 1405–1414.
 14. Treitl KM, Treitl M, Kooijman-Kurfuerst H, et al. Three-dimensional black-blood T1-weighted turbo spin-echo techniques for the diagnosis of deep vein thrombosis in comparison with contrast-enhanced magnetic resonance imaging: A pilot study. *Invest Radiol* 2015; 50: 401–408.