

# Graft choice for anatomic anterior cruciate ligament reconstruction

## The comparison between thin autograft and thick hybrid graft. An observational study

Hongtao Xu, MD<sup>a</sup>, Weiwei Lin, MD<sup>b</sup>, Guorong Jin, MD<sup>a</sup>, Dongmei Xin, MD<sup>c</sup>, Jian Zhang, MD<sup>d</sup>, Kai Kang, MD<sup>a</sup>, Jiangtao Dong, MD<sup>a,\*</sup>, Shijun Gao, MD<sup>a</sup>, Baicheng Chen, MD<sup>a</sup>

### Abstract

Great controversy over the graft choice has been lasted now. This study compared the second-look evaluation and clinical outcomes of anatomic anterior cruciate ligament reconstruction (ACL-R) using a thin autograft versus a thick hybrid graft.

Seventy-six patients with complete follow-up data were categorized into the autograft group (N=34) and hybrid group (N=42). The Lysholm score, Tegner activity level, International Knee Documentation Committee (IKDC) Knee Evaluation Form, and KT-1000 test were performed before and at follow-up. Results were compared, and further comparisons were made for grafts thicker than 8.5 mm.

The hybrid graft was thicker than the autograft ( $9.10 \pm 0.52$  vs  $8.57 \pm 0.48$  mm,  $P < .001$ ). The KT-1000 test, subjective evaluation, and activity level scores increased significantly between pre- and postoperation for all patients ( $P < .001$ ). No significant differences were, however, found between the 2 groups. Only grafts thicker than 8.5 mm were selected from the autograft (N=14) and hybrid (N=34) groups, the Lysholm, IKDC, and KT-1000 test scores were significantly superior for the autograft than the hybrid graft ( $P = .021$ ,  $P = .005$ , and  $P = .024$ , respectively).

For anatomic ACL-R, a pure autograft is superior to a hybrid graft of the same diameter. The purity of the autograft was more important than the size, and augmenting allografts may be unnecessary.

**Abbreviations:** ACL = anterior cruciate ligament, ACL-R = anatomic anterior cruciate ligament reconstruction, IKDC = International Knee Documentation Committee, MRI = magnetic resonance imaging, ROM = range of motion, STG = semitendinosus tendon-gracilis tendon.

**Keywords:** allograft, anterior cruciate ligament reconstruction, autograft, hybrid graft

### 1. Background

The anterior cruciate ligament (ACL) is an important ligament in the knee that plays a key role in knee joint stability and competitive sports performance.<sup>[1]</sup> There are approximately 200,000 patients with ACL injuries each year in the United States,

and more than half of these patients underwent surgical repair or reconstruction.<sup>[2]</sup> Anatomic ACL reconstruction (ACL-R) has been considered a satisfactory surgical procedure in sports medicine, and the autograft has been commonly used for ACL-R in the past.<sup>[3–5]</sup> An autograft is associated with earlier incorporation and tendon-bone healing, as well as reduced immunological rejection after transplantation. In addition, there is no risk of disease transmission.<sup>[6]</sup> In clinical practice, the semitendinosus tendon-gracilis (STG) autograft is typically harvested from the operated knee, and sometimes the surgeon must add 1 or 2 allografts to the autograft because the autograft diameter is insufficient. The hybrid graft is created by mixing 2 different sources of grafts together which could suit for ACL-R.

Anatomic ACL-R should not be defined as simply drilling 2 tunnels in the femur and 2 tunnels in the tibia to simulate the 2 functional bundles of the ACL, but rather should focus on re-establishing the functional and synergetic roles of the bundles.<sup>[7]</sup> Van et al defined it as the functional restoration of the ACL to its native dimensions, collagen orientation, and insertion sites.<sup>[8]</sup> Moreover, the ACL-R should be individualized to restore the insertion site to at least 60% to 80% of the cross-sectional area.<sup>[9]</sup> A hybrid graft could create a thicker diameter than most autografts, which is important for achieving the above ratios. A hybrid graft, however, cannot eliminate the risk of infection. Furthermore, the greatest concern is that the vascularization and speed of biological changes in the tendon-bone interface of the 2 different sources grafts may be inconsistent and incompatible. It

Editor: Leonardo Roever.

HX, WL, and GJ contributed equally to the study.

*Ethics approval and consent to participate:* The ethical approval was not necessary, because this study was a retrospective study. Patient consent was not required due to the retrospective nature of the study.

*Availability of data and materials:* The datasets supporting the conclusions of this article are included within the article.

The authors have no funding and conflicts of interest to disclose.

<sup>a</sup>The Third Hospital of Hebei Medical University, <sup>b</sup>The Second Hospital of Hebei Medical University, Hebei, <sup>c</sup>Ri Zhao Hospital of TCM, <sup>d</sup>People's Hospital of Ri Zhao, Rizhao, Shandong, People's Republic of China.

\* Correspondence: Jiangtao Dong, The Third Hospital of Hebei Medical University, No. 139, Ziqiang Road, Shijiazhuang 050000, Hebei, People's Republic of China (e-mail: hbsydongjiangtao@sina.com).

Copyright © 2018 the Author(s). Published by Wolters Kluwer Health, Inc. This is an open access article distributed under the Creative Commons Attribution-NoDerivatives License 4.0, which allows for redistribution, commercial and non-commercial, as long as it is passed along unchanged and in whole, with credit to the author.

Medicine (2018) 97:30(e11597)

Received: 16 June 2017 / Accepted: 25 June 2018

<http://dx.doi.org/10.1097/MD.00000000000011597>

**Table 1**

**Graft harvest and augmentation or not.**

Harvest STG diameter, mm	Augmentation or not	Type of graft	Number of patients	Diameter of the different groups, mm	Diameter of the autograft in hybrid, mm
<8	Augmentation	Hybrid graft	42	9.10±0.52	7.25±0.35 mm
≥8	No	Autograft	34	8.57±0.48	

STG = semitendinosus tendon-gracilis tendon.

is unclear that the augmented allograft is ideal for restoring the function and stabilization of the knee.

Thus, this study sought to compare the results of ACL-R between patients who received either a thin autograft or a thick hybrid graft. All patients underwent a follow-up medical examination a minimum of 2 years postoperatively.

**2. Materials and methods**

**2.1. Participants**

This retrospective study was conducted with the approval of the ethics committee of our hospital. From June 2013 to September 2014, 85 patients underwent ACL-R in our institute. According to the inclusion and exclusion criteria, 76 of these patients who had complete clinical follow-up data were included. All operations in our institute were performed by senior surgeons who had at least 10 years of experience in arthroscopic reconstruction. Patients underwent anatomic ACL-R, and the femoral and tibial fixation devices used were suspension fixation and compression screw fixation, respectively. The inclusion criteria were unilateral ACL rupture, preoperative magnetic resonance imaging (MRI) that confirmed the ACL rupture, and positive anterior drawer test and Lachman test. The exclusion criteria were ACL tear combined with multiple-ligament tear, contralateral knee ligament rupture or bilateral ACL-R, previous ACL surgery or ACL revision, ACL tear combined with fracture or avulsion fracture, and lost to clinical follow-up.


**2.2. Study procedures**

The data were collected from the resident’s admission note, physical examination, preoperative MRI records, operation

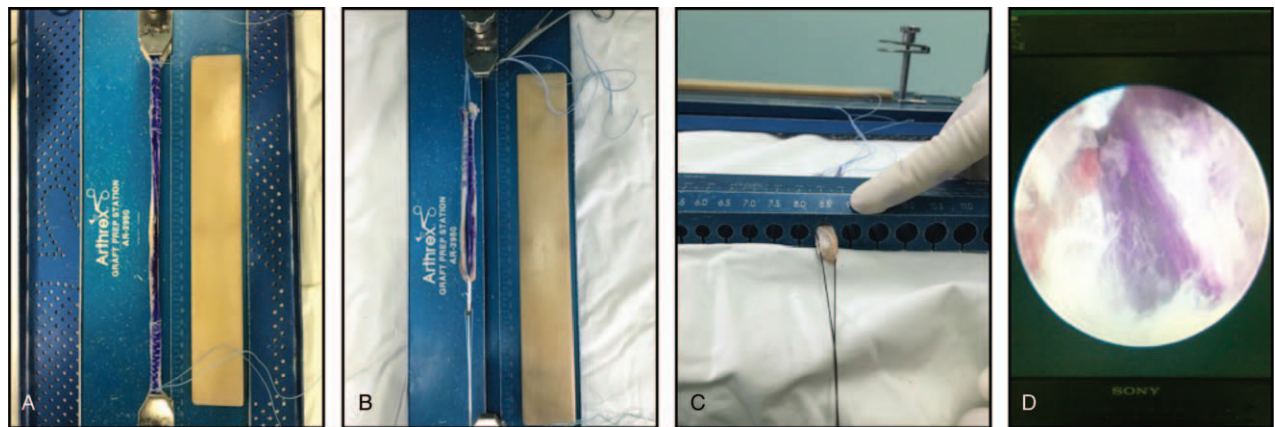
records, and records of pre- and postoperative functional scores. Patients were evaluated using the Lysholm score, Tegner activity level, International Knee Documentation Committee (IKDC) Knee Evaluation Form, and KT-1000 test before the operation. At follow-up, 76 patients returned to our institute to complete the same examination and evaluation as performed preoperatively. The patients were divided into 2 groups based on whether only autografts were used or allografts were added to create a hybrid graft. The graft size was confirmed from the operation records and the clinical results were compared between the 2 groups. Data from patients with a graft size >8.5 mm<sup>[10,11]</sup> were then selected from each group for further analysis.

**2.3. Surgical technique**

A routine arthroscopic examination was performed to confirm the ACL rupture. The meniscus tear was treated with a partial meniscectomy or FasT-Fix suture. The remnant ACL fibers were debrided to identify the anatomic footprint and the drilling points. A tendon stripper was then used to harvest the STG tendon through a 2.5-cm oblique incision. After the soft tissue was cleaned out, the length and diameter measurements were obtained by using a graft sizer. Generally, only the combined diameter of the STG tendon was <8 mm; an allograft was added for augmentation (Table 1). However, if the patient refused the allograft, the augmentation was not performed (Fig. 1). The allograft was harvested from tibialis anterior tendons that received an irradiation dose of 2.5 Mrad before being distributed to our institution. Based on the measurements of the length of the insertions and the height of the intercondylar notch, the surgeon made the decision of augmenting allografts (Fig. 2A). The 2 free



**Figure 1.** The autograft was measured and sutured.



**Figure 2.** The hybrid graft was prepared and observed under arthroscopy: A, The augmentation of the allograft was marked in blue. B, The hybrid graft was sutured. C, The hybrid graft diameter was measured. D, The hybrid graft under an arthroscope.

ends of the autografts and allografts were braided with No. 2 Ethibond Excel Polyethylene nonabsorbable sutures (Fig. 2B).

The tibial tunnel drilling point was located by using a guide apparatus. And the tunnel was established by using a bone drill with the same diameter. Then, the femoral tunnel was created through the anteromedial-portal approach, from the inside to the outside. The same size bone drill sheathed the guide pin, which was located at the center of the femoral footprint. After broadening the tunnels, the graft was pulled into these tunnels. The femoral side was fixed with an EndoButton (Smith & Nephew Endoscopy, Andover, MA). Then a BioComposite interference screw (Arthrex, Naples, FL) was used for compressed fixation on the tibial side. Concurrent with the manual maximum tension on the graft, a maximum posterior force was loaded on the tibia. It was important to minimize graft laxity in the early stage after the operation.

#### 2.4. Postoperative treatment and rehabilitation

During the first 24 hours postoperatively, an ice pack was used to prevent swelling every 4 to 6 hours. All patients received injections of cefazolin sodium pentahydrate every 6 hours during the first 24 hours.

In our institution, all postoperative patients were referred to a rehabilitation medicine center where they could receive a normalized ACL rehabilitation program. A long hinged brace fastened the operated limb. Weight bearing was forbidden, but range of motion (ROM) exercises were allowed 2 days after the operation. Approximately 2 weeks later, the patients were permitted to walk with the help of 2 canes. In the next 6 weeks, the operative knee flexion progressed to full ROM and weight-bearing walking was allowed as tolerated with. Full weight bearing walking and mobilization without brace protection were permitted at 12 weeks. Patients could participate in controlled sports activities after 6 months and contact sports after 12 months.

#### 2.5. Follow-up

At follow-up, 76 patients were re-examined with the KT-1000 test, Lysholm score, Tegner activity level, and IKDC. The mean follow-up period was 28.9 months (range, 22–30 months). Physical examination by the surgeon remained an indispensable

part of the assessments. If the surgeon was unsatisfied with the examination result, MRI scans (3.0-T, Verio; Siemens, Germany) were performed to assess the morphology of the graft.

#### 2.6. Statistical analysis

Data were analyzed by using SPSS software for Windows (version 21.0; Chicago, IL). Independent samples *t* tests, Chi-squared tests, and Mann-Whitney tests were used to compare the baseline characteristics of the 2 groups. Data with a normal distribution and homogeneity of variance were compared using an independent samples *t* test or Mann-Whitney test, and dichotomous variables were compared using a Chi-squared test. The graft size between the 2 groups was compared with the Mann-Whitney test. The preoperative versus follow-up scores of the KT-1000 test, subjective evaluation, and activity level were compared with the Wilcoxon signed-rank test; comparisons between the 2 groups were evaluated with the Mann-Whitney test. The significance level was set at  $P < .05$ .

### 3. Results

#### 3.1. Demographic analysis

Seventy-six patients who underwent ACL-R were analyzed in this study. Patient demographic data are listed in Table 2. There were 21 men and 13 women in the autograft group (age:  $35.32 \pm 9.87$  years) and 31 men and 11 women in the hybrid graft group (age:  $35.93 \pm 9.65$  years). No significant difference was found in the sex distribution between the groups ( $P = .261$ ). There were 34 patients (44.7%) received an autograft and 42 (55.3%) received a hybrid allograft. There were 32 (42.1%) medial meniscus tears and 28 (36.8%) lateral meniscus tears. The associated injury was confirmed and no significant difference was observed in injury type between the 2 groups ( $P = .466$ ). The graft size was, however, significantly different between the 2 groups ( $P < .001$ ).

The mean body mass index was  $25.91 \pm 3.43 \text{ kg/m}^2$  in the autograft group and  $25.72 \pm 3.36 \text{ kg/m}^2$  in the hybrid group ( $P = .808$ ). The injury to operation intervals of the autograft and hybrid groups were  $2.13 \pm 1.85$  and  $2.38 \pm 2.34$  months ( $P = .408$ ), respectively. The follow-up times were  $27.02 \pm 1.88$  months (autograft) and  $26.84 \pm 1.83$  months (hybrid) ( $P = .467$ ). The graft size of the autograft was thinner than that of the hybrid

**Table 2**  
Demographic characteristics and intraoperative data.

	Autograft		Hybrid		P
		95% CI		95% CI	
Age, mean ± SD, y <sup>a</sup>	35.32 ± 9.87	31.88–38.77	35.93 ± 9.65	32.92–38.94	.789
Sex, men/women, n <sup>b</sup>	21/13		31/11		.261
BMI, mean ± SD, kg/m <sup>2a</sup>	25.91 ± 3.43	24.71–27.11	25.72 ± 3.36	24.67–26.77	.808
Alcohol use, n	1		2		
Tobacco use, n	0		1		
Injury to operation interval, mean ± SD, mo <sup>c</sup>	2.13 ± 1.85	1.49–2.78	2.38 ± 2.34	1.66–3.11	.639
Type of injury, n					.408
Sprain or fall	28		29		
Sports injury	3		7		
Traffic accident	3		6		
Meniscus injury, n <sup>b</sup>					.466
MM	13		19		
LM	14		14		
MM and LM	0		0		
Cartilage injury	5		8		
Graft size, mean ± SD, mm <sup>c</sup>	8.57 ± 0.48	8.41–8.74	9.10 ± 0.52	8.93–9.26	<.001*
Follow-up, mean ± SD, mo <sup>c</sup>	27.02 ± 1.88	26.36–27.67	26.84 ± 1.83	26.27–27.41	.467

BMI = body mass index, CI = confidence interval, LM = lateral meniscus, MM = medial meniscus.

<sup>a</sup>Independent Samples *t* test.

<sup>b</sup>Chi-squared test.

<sup>c</sup>Mann-Whitney test.

\* Statistically significant.

graft (8.57 ± 0.48 vs 9.10 ± 0.52 mm, *P* < .001) (Tables 1 and 2) because most STG autografts were not thick enough, an allograft was added to create a thick hybrid graft.

**3.2. Data analysis**

We compared the KT-1000 test, subjective evaluation, and activity level scores between the 2 groups. For all patients, significant differences were observed between the preoperative and postoperative scores of all these evaluation (*P* < .001). However, when comparing the 2 groups, including the preoperative values, postoperative results, and change between pre- and postoperation, no significant differences were found (Table 3).

Only patients whose graft size was >8.5 mm were selected for the subsequent analyses. Fourteen (41.2%) patients were included from the autograft group and 34 (81.0%) from the hybrid group. The Lysholm scores were 95.28 ± 2.61 [95% confidence interval (CI), 93.78–96.80] in the autograft group and 92.85 ± 3.50 (95% CI, 91.63–94.07) in the hybrid group

(*P* = .021). Likewise, the IKDC in the autograft group was 92.07 ± 3.25 (95% CI, 90.20–93.95), which significantly higher than that in the hybrid group (87.79 ± 4.87, 95% CI, 86.10–89.49) (*P* = .005). The Tegner activity level score in the hybrid group was, however, 5.88 ± 1.09 (95% CI, 5.50–6.26), which is nonsignificantly lower than that in the autograft group (6.21 ± 0.89, 95% CI, 5.70–6.73) (*P* = .427) (Table 4). Finally, the KT-1000 test score in the autograft group was 1.67 ± 0.40 (95% CI, 1.44–1.91), which is significantly lower than that in the hybrid graft group (2.11 ± 0.61, 95% CI, 1.89–2.32) (*P* = .024) (Table 4).

**4. Discussion**

It is important to find whether the graft purity or graft diameter should be considered first when performing anatomic ACL-R. This study has 2 notable findings. First, even though the hybrid grafts were significantly thicker than the autografts, which means that the hybrid group achieved better occupancy of the cross-sectional area for anatomic ACL-R, the comparison results showed that the subjective evaluation, activity level scores, and

**Table 3**  
KT-1000 test, subjective evaluation, and activity level scores before and after surgery.

	Lysholm			Tegner			IKDC			KT-1000		
	Mean ± SD (95% CI)		P <sup>a</sup>	Mean ± SD (95% CI)		P <sup>a</sup>	Mean ± SD (95% CI)		P <sup>a</sup>	Mean ± SD (95% CI), mm		P <sup>a</sup>
	Pre-op	Post-op		Pre-op	Post-op		Pre-op	Post-op		Pre-op	Post-op	
Autograft	64.94 ± 14.39 (59.92–69.97)	88.74 ± 6.65 (86.42–91.06)	<.001*	1.56 ± 0.89 (1.25–1.87)	5.17 ± 1.22 (4.75–5.60)	<.001*	47.74 ± 10.04 (47.34–51.24)	85.65 ± 6.37 (83.43–87.87)	<.001*	8.60 ± 2.28 (7.81–9.40)	2.69 ± 1.22 (2.26–3.11)	<.001*
Hybrid	65.76 ± 17.82 (60.21–71.31)	90.57 ± 5.84 (88.75–92.39)	<.001*	1.64 ± 0.88 (1.37–1.92)	5.45 ± 1.35 (5.03–5.87)	<.001*	48.90 ± 10.59 (45.61–52.20)	86.12 ± 5.81 (84.31–87.93)	<.001*	8.77 ± 2.54 (7.98–9.56)	2.46 ± 0.97 (2.15–2.76)	<.001*
P <sup>b</sup>	.235	.229		.749	.316		.541	.707		.750	.555	

CI = confidence interval, IKDC = international knee documentation committee knee evaluation form, post-op = postoperative, pre-op = preoperative.

<sup>a</sup>Wilcoxon signed ranks test.

<sup>b</sup>Mann-Whitney test.

\* Statistically significant.



**Table 4**  
**Comparison of KT-1000 test, subjective evaluation, and activity level scores after surgery for graft sizes above 8.5 mm.**

	Graft size (>8.5 mm) n	Lysholm		Tegner		IKDC		KT-1000	
		Mean ± SD	95% CI	Mean ± SD	95% CI	Mean ± SD	95% CI	Mean ± SD, mm	95% CI
Autograft	14	95.28 ± 2.61	93.78–96.80	6.21 ± 0.89	5.70–6.73	92.07 ± 3.25	90.20–93.95	1.67 ± 0.40	1.44–1.91
Hybrid	34	92.85 ± 3.50	91.63–94.07	5.88 ± 1.09	5.50–6.26	87.79 ± 4.87	86.10–89.49	2.11 ± 0.61	1.89–2.32
<i>P</i> <sup>a</sup>		.021*		.427		.005*		.024*	

CI = confidence interval, IKDC = the international knee documentation committee knee evaluation form.

<sup>a</sup> Mann-Whitney test.

\* Statistically significant.

KT-1000 test of postoperative function were not significantly different between the 2 groups. Second, when only the graft sizes larger than 8.5 mm were selected, the clinical outcomes were significantly superior in the autograft group. Only the Tegner activity level scores showed no significant difference between the groups. These findings suggest the importance of restoring the insertion site to at least 60% to 80% of the cross-sectional area during anatomic ACL-R.<sup>[9]</sup> Using an augmented allograft to increase the diameter and restore occupancy, however, might not be beneficial for restoring function and stabilization. In other words, the purity of the graft might play a more critical role in vascularization and the tendon-bone biological repair process.

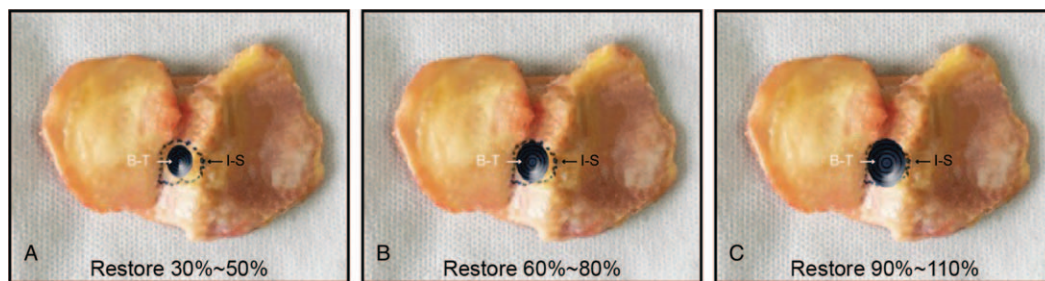
Anatomic ACL-R is defined as the modus operandi that should restore the primary native dimensions, insertion sites, and collagen orientation.<sup>[8]</sup> Therefore, the size of the autografts and the cross-sectional area should be predicted by MRI scans.<sup>[12]</sup> Furthermore, the insertion site size can be confirmed intra-operatively. Meanwhile, the proportion of the cross-sectional area should be calculated formulaically.<sup>[9]</sup> To achieve this required standard, the graft diameter should be no less than 8.5 mm. Thus, if the autograft diameter is less than the requirement, the surgeon must augment with an allograft. However, according to the definition of anatomic ACL-R and the borderline of the insertion site, the graft diameter cannot increase without boundaries or limits (Fig. 3).

In our study, a comparison of patients whose graft size >8.5 mm revealed that the autograft was superior in the subjective and objective evaluations to the hybrid graft. Thus, it seems that the purity of the graft source was more important than the rate of cross-sectional area. Moreover, many studies<sup>[13,14]</sup> have evaluated allografts and consider them biomechanically acceptable. But few studies have investigated the functional and clinical outcomes with long-term follow-up. The hybrid graft aims to create a suitable-sized graft that is similar to the native size. Alvarez-Pinzon et al<sup>[15]</sup> proposed that autograft provide an ideal graft to stabilize the knee. Nevertheless, hybridization was a matter of

necessity for the desired graft size and postoperative stability, especially when difficulties were encountered when harvesting adequate autograft tissue or iatrogenic injury to the hamstring tendons occurred.

In contrast, our study found that the thick hybrid graft provided no improvement in clinical evaluation compared with the thin autografts. It is likely that autografts were preferentially chosen to decrease the chance of a growth disturbance.<sup>[16]</sup> Meanwhile, the Tegner scores had no statistically significant differences in any between-group comparisons. It is likely because the Tegner evaluation assesses the patient’s activity level and most patients in our institution performed no strenuous or high-intensity exercises. Moreover, patients underwent a more conservative rehabilitation treatment process. Even though the patients were allowed to participate in further controlled sports activities or contact sports by their surgeons, postoperative psychogenic conditions still prevented them from confidently moving the operated knee joint. Thus, the Tegner scores of both groups increased significantly, but most patients had not regained their desired activity level.

Considerable controversy exists regarding the appropriate graft choice for patients undergoing ACL-R, and allografts pretreated with high-dose irradiation should be avoided.<sup>[17]</sup> Many studies have compared different resources for grafts. Burrus et al<sup>[18]</sup> reported that autograft hamstring ACL grafts have a lower failure rate than allograft-autograft hybrid hamstring grafts. Li et al<sup>[19]</sup> designed a prospective randomized controlled trial comparing autografts,  $\gamma$ -irradiated allografts, and hybrid grafts. The objective and subjective clinical outcomes were similar to our results, in that all had satisfactory results without significant differences between graft types. Significant differences were, however, observed between graft types using the KT-1000 test. The measurements were 2.1 ± 1.6 and 2.0 ± 1.5 mm in the autograft and hybrid graft groups, respectively, compared with 3.5 ± 1.2 mm in the  $\gamma$ -irradiated allograft group (*P* = .025), demonstrating that the  $\gamma$ -irradiated allograft provided poorer



**Figure 3.** The relative relationship between the bone tunnel diameter and the insertion site. A, Restoration of the insertion site that does not reach the standard for anatomic anterior cruciate ligament reconstruction (ACL-R). B, Anatomic ACL-R with restoration of the insertion site to at least 60% to 80% of the cross-sectional area. C, Restoration beyond the borderline of the insertion site. B-T = bone tunnel, I-S = insertion site.

results. A recent meta-analysis of 19 studies concluded that autografts are superior to irradiated allografts in measures of function and stability, with no significant differences between autografts and nonirradiated allografts.<sup>[20]</sup> Therefore, evidence shows that hybrid grafts using irradiated allografts are suboptimal for improving function and stability.

Remodeling is essential to ACL-R for both tendon autografts and allografts.<sup>[21]</sup> There are 4 stages in the tendon-bone healing process: inflammation of the reconstructed graft, fresh proliferation, matrix synthesis, and remodeling. Previous studies reported that a fibrous scar tissue layer formed at the interface, but the natural tendon-bone healing was not efficient.<sup>[22,23]</sup> Furthermore, in the allograft-autograft hybrid, the speed of cell death within the graft, blood flow to the graft, and revascularization of the tendon graft might not be synchronized. Terauchi et al<sup>[24]</sup> used magnetic resonance angiography to evaluate the maturation stage of the autograft and reported that revascularization occurred in the femoral and tibial bone tunnels 2 months postoperatively. It was not until 6 months after the operation that the blood flow subsequently decreased. Ge et al<sup>[25]</sup> reported that the autograft tendons exhibited superior remodeling compared with allograft tendons in the bone tunnel. No statistically significant differences were, however, observed in tendon-bone healing between them postoperatively. Therefore, the healing process of the 2 different sources of grafts in the hybrid would not be tightly synchronized.

A few studies have compared the clinical outcomes between ACL-R using hamstring autografts and tibialis anterior allografts,<sup>[26,27]</sup> and fewer have compared the synovial membrane coverage of second-look arthroscopy.<sup>[27,28]</sup> Yoon and Lee<sup>[29]</sup> described the second-look arthroscopic results of synovial coverage after ACL-R: the hamstring autograft showed better outcomes than the tibialis allograft. Yoo et al<sup>[30]</sup> similarly found no statistically significant difference in functional outcomes between hamstring autografts and tibialis allografts. Second-look arthroscopy, however, revealed that hamstring autografts achieved better synovial coverage. This finding may be because the autografts experienced less immunorejection than allografts. Li et al<sup>[31]</sup> also found that allografts exhibited inferior graft remodeling and maturity than autografts after ACL-R. Thus, the hybrid graft consisting of 2 pieces may not provide complete synovial coverage.

Previous studies demonstrated that the increasing failure rates could be increased if the hamstring tendon autograft diameters are <8 mm.<sup>[32,33]</sup> Some other studies, however, reported that there was no correlation between graft size and failure rate.<sup>[16]</sup> Spragg et al<sup>[34]</sup> found that within the range of 7.0 to 9.0 mm, the likelihood of requiring revision was 0.82 times lower for every 0.5-mm incremental increase in graft diameter. Thus, hamstring tendon graft diameter is 1 factor that may influence the likelihood of success. Unfortunately, Astur et al<sup>[35]</sup> reported a significant decrease in graft diameter after at least 1 year of follow-up. The risk of rerupture was theoretically further increased with the decrease in the diameter of the graft that occurs as time progresses postoperatively, and a quadruple hamstring graft was found to decrease in diameter by a mean of 25.3% from the time of ACL-R until reassessment.<sup>[35]</sup> Our research found that the graft diameter in the autograft group ( $8.57 \pm 0.48$  mm) was significantly thinner than that in the hybrid graft group ( $9.10 \pm 0.52$  mm) ( $P < .001$ ) (Tables 1 and 2). No significant differences were, however, found in the results of the KT-1000 test, subjective evaluation, and activity level between the 2 groups (Table 3). This reveals that the hybrid graft did not provide significant benefits, even though its

diameter had been increased by augmenting allografts. Based on the effect of anisotropy on the incremental formation of the graft source and its microstructural evolution, the 2 parts of a reconstructed graft could not become perfectly integrated.

In our study, we found that when only the patients whose graft size >8.5 mm were selected, the clinical outcomes were significantly superior in the autograft group than those in the hybrid group (Table 4). This result reveals that the purity of the autograft played a more important role than the size of the augmented allografts. The actual diameter of the hybrid graft that acted postoperatively might not be thicker than the autograft. McRae et al.<sup>[36]</sup> conducted a randomized controlled trial to evaluate whether ACL-R using a hamstring tendon autograft results in better patient quality of life if the graft is harvested from the leg contralateral to the ACL rupture compared with the ipsilateral leg. They concluded that there did not appear to be any measurable drawback or benefit to using an STG graft from the unaffected limb. Therefore, autografts were used for anatomic ACL-R, and they restored the insertion site to at least 60% to 80% of the cross-sectional area. If the graft diameter harvested from the ipsilateral knee was not thick enough, the graft can be obtained from the hamstring tendon of the contralateral knee instead of using an allograft.

#### 4.1. Limitations

This study has several limitations. First, it examined patients from a single institution, and a larger multicenter study is needed. Therefore, these results may not be generalizable. Second, second-look estimation using arthroscopy should be performed for the hybrid graft reconstruction. Third, longer-term follow-up is essential to explore the biologic behavior of the tendon-bone healing of the graft parts from different sources. Moreover, the sex factor plays an influence role in the postoperative rehabilitation, which might lead different levels of sports participation.<sup>[37,38]</sup> Meanwhile, the revision rate might be increased by the use degree of reconstructed knee and contralateral knee. So a further research on the relativity between sex and ACL-R is needed. Fourth, the structure and morphology of the autograft, allograft, and hybrid graft should be examined using scanning electron microscopy, which can investigate the microstructural evolution postoperatively. Finally, the donor-site complications should be examined.

#### 5. Conclusion

The graft diameter is one of the factors that may influence the likelihood of success of anatomic ACL-R, and it is also a key method of restoring the insertion site to at least 60% to 80% of the cross-sectional area. A pure autograft, however, provides superior results on the KT-1000 test and subjective evaluation compared with a hybrid graft of the same diameter. Patients undergoing anatomic ACL-R should ideally receive an autograft, even if it requires harvesting the hamstring tendon autograft from the contralateral knee.

#### Author contributions

HX, WL, and GJ conceived the design of the study. GJ and KK performed the research. DX and JZ analyzed the data. JD, SG, and BC contributed new methods or models. HX wrote the article. All authors have read and approved the content of the final manuscript.

**Conceptualization:** Hongtao Xu, Jiangtao Dong.  
**Data curation:** Guorong Jin.  
**Formal analysis:** Hongtao Xu, Weiwei Lin, Dongmei Xin, Jian Zhang.  
**Investigation:** Guorong Jin.  
**Methodology:** Weiwei Lin, Kai Kang.  
**Project administration:** Hongtao Xu, Jiangtao Dong, Baicheng Chen.  
**Resources:** Jiangtao Dong.  
**Software:** Weiwei Lin.  
**Supervision:** Jiangtao Dong, Shijun Gao, Baicheng Chen.  
**Writing – original draft:** Hongtao Xu, Guorong Jin.  
**Writing – review and editing:** Weiwei Lin, Kai Kang.

**References**

[1] Wang H, Fleischli JE, Zheng NN. Transtibial versus anteromedial portal technique in single-bundle anterior cruciate ligament reconstruction: outcomes of knee joint kinematics during walking. *Am J Sports Med* 2013;41:1847–56.  
 [2] Mall NA, Chalmers PN, Moric M, et al. Incidence and trends of anterior cruciate ligament reconstruction in the United States. *Am J Sports Med* 2014;42:2363–70.  
 [3] Chalmers PN, Mall NA, Yanke AB, et al. Contemporary anterior cruciate ligament outcomes: does technique really matter? *Oper Tech Sports Med* 2013;21:55–63.  
 [4] Sun K, Tian S, Zhang J, et al. Anterior cruciate ligament reconstruction with BPTB autograft, irradiated versus non-irradiated allograft: a prospective randomized clinical study. *Knee Surg Sports Traumatol Arthrosc* 2009;17:464–74.  
 [5] Sun K, Zhang J, Wang Y, et al. Arthroscopic reconstruction of the anterior cruciate ligament with hamstring tendon autograft and fresh-frozen allograft: a prospective, randomized controlled study. *Am J Sports Med* 2011;39:1430–8.  
 [6] Mardani-Kivi M, Karimi-Mobarakeh M, Keyhani S, et al. Hamstring tendon autograft versus fresh-frozen tibialis posterior allograft in primary arthroscopic anterior cruciate ligament reconstruction: a retrospective cohort study with three to six years follow-up. *Int Orthop* 2016;40:1905–11.  
 [7] Fu FH, Araujo PH, Lin A. Double-bundle ACL reconstruction with use of a single tibial tunnel: a technique or an anatomic concept? *J Bone Joint Surg Am* 2011;93:e121.  
 [8] Van Eck CF, Schreiber VM, Mejia HA, et al. Anatomic anterior cruciate ligament reconstruction: a systematic review of surgical techniques and reporting of surgical data. *Arthroscopy* 2010;26:S2–12.  
 [9] Fu FH, Van Eck CF, Tashman S, et al. Anatomic anterior cruciate ligament reconstruction: a changing paradigm. *Knee Surg Sports Traumatol Arthrosc* 2015;23:640–8.  
 [10] Snaebjörnsson T, Hamrin SE, Ayeni OR, et al. Graft diameter as a predictor for revision anterior cruciate ligament reconstruction and KOOS and EQ-5D values: a cohort study from the Swedish National Knee Ligament Register based on 2240 patients. *Am J Sports Med* 2017;45:2092–7.  
 [11] Steiner M. Editorial commentary: Size does matter-anterior cruciate ligament graft diameter affects biomechanical and clinical outcomes. *Arthroscopy* 2017;33:1014–5.  
 [12] Zakko P, van Eck CF, Guenther D, et al. Can we predict the size of frequently used autografts in ACL reconstruction? *Knee Surg Sports Traumatol Arthrosc* 2015;25:3704–10.  
 [13] Haut Donahue TL, Howell SM, Hull ML, et al. A biomechanical evaluation of anterior and posterior tibialis tendons as suitable single-loop anterior cruciate ligament grafts. *Arthroscopy* 2002;18:589–97.  
 [14] Pearsall AW4th, Hollis JM, Russell GVJr, et al. A biomechanical comparison of three lower extremity tendons for ligamentous reconstruction about the knee. *Arthroscopy* 2003;19:1091–6.  
 [15] Alvarez-Pinzon AM, Barksdale L, Krill MK, et al. Hybrid graft anterior cruciate ligament reconstruction: a predictable graft for knee stabilization. *Orthopedics* 2015;38:e473–6.  
 [16] Pinheiro LfJr, De Andrade MA, Teixeira LE, et al. Intra-operative four-stranded hamstring tendon graft diameter evaluation. *Knee Surg Sports Traumatol Arthrosc* 2011;19:811–5.  
 [17] Verma NN. Editorial commentary: anterior cruciate ligament reconstruction: auto or allo? *Arthroscopy* 2016;32:164.

[18] Burrus MT, Werner BC, Crow AJ, et al. Increased failure rates after anterior cruciate ligament reconstruction with soft-tissue autograft-allograft hybrid grafts. *Arthroscopy* 2015;31:2342–51.  
 [19] Li J, Wang J, Li Y, et al. A prospective randomized study of anterior cruciate ligament reconstruction with autograft,  $\gamma$ -irradiated allograft, and hybrid graft. *Arthroscopy* 2015;31:1296–302.  
 [20] Zeng C, Gao SG, Li H, et al. Autograft versus allograft in anterior cruciate ligament reconstruction: a meta-analysis of randomized controlled trials and systematic review of overlapping systematic reviews. *Arthroscopy* 2015;32:153.e18–63.e18.  
 [21] Unterhauser FN, Bail HJ, Höher J, et al. Endoligamentous revascularization of an anterior cruciate ligament graft. *Clin Orthop Relat Res* 2003;414:276–88.  
 [22] Gulotta LV, Kovacevic D, Ying L, et al. Augmentation of tendon-to-bone healing with a magnesium-based bone adhesive. *Am J Sports Med* 2008;36:1290–7.  
 [23] Kobayashi M, Nakagawa Y, Suzuki T, et al. A retrospective review of bone tunnel enlargement after anterior cruciate ligament reconstruction with hamstring tendons fixed with a metal round cannulated interference screw in the femur. *Arthroscopy* 2006;22:1093–9.  
 [24] Terauchi R, Arai Y, Hara K, et al. Magnetic resonance angiography evaluation of the bone tunnel and graft following ACL reconstruction with a hamstring tendon autograft. *Knee Surg Sports Traumatol Arthrosc* 2016;24:169–75.  
 [25] Ge Y, Li H, Tao H, et al. Comparison of tendon-bone healing between autografts and allografts after anterior cruciate ligament reconstruction using magnetic resonance imaging. *Knee Surg Sports Traumatol Arthrosc* 2015;23:954–60.  
 [26] Lawhorn KW, Howell SM, Traina SM, et al. The effect of graft tissue on anterior cruciate ligament outcomes: a multicenter, prospective, randomized controlled trial comparing autograft hamstrings with fresh-frozen anterior tibialis allograft. *Arthroscopy* 2012;28:1079–86.  
 [27] Lee JH, Bae DK, Song SJ, et al. Comparison of clinical results and second-look arthroscopy findings after arthroscopic anterior cruciate ligament reconstruction using 3 different types of grafts. *Arthroscopy* 2010;26:41–9.  
 [28] Yang JH, Yoon JR, Jeong HI, et al. Second-look arthroscopic assessment of arthroscopic single-bundle posterior cruciate ligament reconstruction: comparison of mixed graft versus Achilles tendon allograft. *Am J Sports Med* 2012;40:2052–60.  
 [29] Yoon KH, Lee JH. Paper 193: Clinical results after arthroscopic ACL reconstruction using bone-patellar tendon-bone allograft, tibialis anterior tendon allograft and hamstring tendon autograft. *Arthroscopy* 2012;28:e448–9.  
 [30] Yoo SH, Song EK, Shin YR, et al. Comparison of clinical outcomes and second-look arthroscopic findings after ACL reconstruction using a hamstring autograft or a tibialis allograft. *Knee Surg Sports Traumatol Arthrosc* 2017;25:1290–7.  
 [31] Li H, Tao H, Cho S, et al. Difference in graft maturity of the reconstructed anterior cruciate ligament 2 years postoperatively: a comparison between autografts and allografts in young men using clinical and 3.0-T magnetic resonance imaging evaluation. *Am J Sports Med* 2012;40:1519–26.  
 [32] Magnussen RA, Lawrence JT, West RL, et al. Graft size and patient age are predictors of early revision after anterior cruciate ligament reconstruction with hamstring autograft. *Arthroscopy* 2012;28:526–31.  
 [33] Mariscalco MW, Flanigan DC, Mitchell J, et al. The influence of hamstring autograft size on patient-reported outcomes and risk of revision after anterior cruciate ligament reconstruction: a Multicenter Orthopaedic Outcomes Network (MOON) cohort study. *Arthroscopy* 2013;29:1948–53.  
 [34] Spragg L, Chen J, Mirzayan R, et al. The effect of autologous hamstring graft diameter on the likelihood for revision of anterior cruciate ligament reconstruction. *Am J Sports Med* 2016;44:1475–81.  
 [35] Astur DC, Arliani GG, Debieux P, et al. Intraarticular hamstring graft diameter decreases with continuing knee growth after ACL reconstruction with open physes. *Knee Surg Sports Traumatol Arthrosc* 2016;24:792–5.  
 [36] McRae S, Leiter J, McCormack R, et al. Ipsilateral versus contralateral hamstring grafts in anterior cruciate ligament reconstruction: a prospective randomized trial. *Am J Sports Med* 2013;41:2492–9.  
 [37] Kaeding CC, Pedroza AD, Reinke EK, et al. Risk factors and predictors of subsequent ACL injury in either knee after ACL reconstruction: prospective analysis of 2488 primary ACL reconstructions from the MOON cohort. *Am J Sports Med* 2015;43:1583–90.  
 [38] Maletis GB, Inacio MC, Funahashi TT. Risk factors associated with revision and contralateral anterior cruciate ligament reconstructions in the Kaiser Permanente ACLR registry. *Am J Sports Med* 2015;43:641–7.