

“In-Round” Labral Repair After Acetabular Recession Using Intermittent Traction



Nathan W. Skelley, M.D., William K. Conaway, B.A., and Scott D. Martin, M.D.

Abstract: The prevalence of hip arthroscopy has increased exponentially with the advent of arthroscopic labral repair techniques for femoroacetabular impingement. The goal of arthroscopic labral repair is to re-create the anatomic suction seal of the labrum against the femoral head. This important anatomic relationship has been demonstrated in several biomechanical studies. Performing the acetabular recession and evaluating the congruity of labral repairs during surgery is difficult with the application of traction distracting the femoral head from the chondrolabral junction. Additionally, prolonged traction risks nerve injury during hip arthroscopy. The purpose of this technique article is to describe a method of using traction only for central compartment work, and releasing the traction to allow the femoral head to reduce the labrum to its anatomic position for acetabular recession, anchor placement, and suture fixation. In this manner, the presented technique prevents an “out-of-round” or everted repair. This technique re-creates the native anatomy and biomechanics of the hip after acetabular recession and labral repair while decreasing traction time.

Arthroscopic techniques have become a popular method for treating numerous musculoskeletal joint conditions throughout the body. The hip joint presents unique anatomic challenges that make arthroscopy especially demanding. Burman first attempted this procedure in 1931 and famously remarked that “[it is] manifestly impossible to insert a needle between the head of the femur and the acetabulum.”¹ Later on it became clear that distraction of the joint with traction afforded access to the central compartment.² Use of traction allowed for the first arthroscopic descriptions of labral pathology³ and the subsequent classification of these tears.⁴ Ganz et al. described femoroacetabular impingement in 2003, and the correlation between FAI and labral pathology was later established.^{5,6} Traction has been a critical

component to the development of hip arthroscopy and the treatment of labral pathology.

The use of hip arthroscopy has increased exponentially with the advent of several labral repair techniques. Although short-term outcomes of both labral debridement and repair have been favorable, the longevity of symptomatic relief by labral repair is superior.⁷⁻⁹ It has been proposed that the difference in outcomes between debridement and repair is a result of the restoration of both native anatomy and biomechanics achieved by restoring the articular congruity. The goal of this repair is to preserve the anatomic suction seal of the labrum against the femoral head. Evaluating the congruity of this repair is difficult, with the application of traction distracting the femoral head from the chondrolabral interface. Various techniques from using looped sutures to vertical mattress sutures have been used to reattach the labrum to the acetabular rim. Although these techniques effectively fix the tissue, they run the risk of altering the shape and vacuum seal of the labrum if not congruent with the femoral head. These types of repairs could adversely affect outcomes.

Hip arthroscopy and the associated traction places the lower extremity for risk of neurologic complications. Several studies have previously described the risk of neurologic complications associated with hip arthroscopy and traction.^{1,10-13} Some nerve injuries can be related to portal placement such as the sciatic and lateral femoral cutaneous nerves, but traction is another common

From the Department of Orthopaedic Surgery, Massachusetts General Hospital—Harvard Medical School, Boston, Massachusetts, U.S.A.

The authors report that they have no conflicts of interest in the authorship and publication of this article. Full ICMJE author disclosure forms are available for this article online, as [supplementary material](#).

Received April 4, 2017; accepted June 29, 2017.

Address correspondence to Nathan W. Skelley, M.D., 175 Cambridge Street, Boston, MA 02114, U.S.A. E-mail: nskelley@mgh.harvard.edu

© 2017 by the Arthroscopy Association of North America. Published by Elsevier. This is an open access article under the CC BY-NC-ND license (<http://creativecommons.org/licenses/by-nc-nd/4.0/>).

2212-6287/17507

<http://dx.doi.org/10.1016/j.eats.2017.06.061>

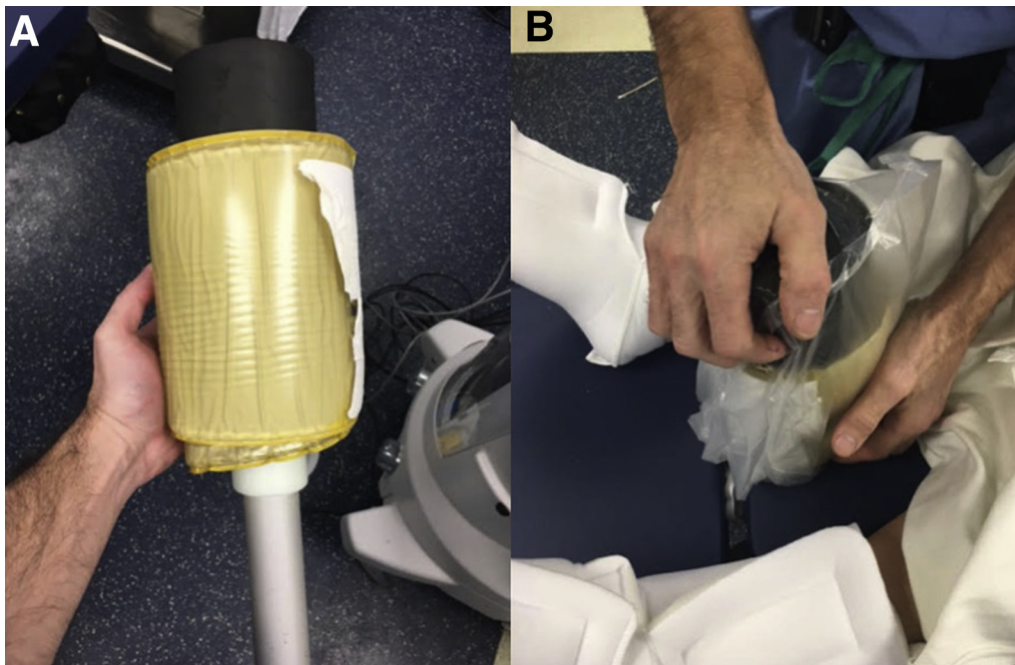


Fig 1. (A) The standard perineal post is wrapped with a viscoelastic polymer surgical pad that completely encompasses the post. The pad is secured with a piece of silk tape. (B) The entire construct is placed in a plastic bag for cleanliness and placed in the surgical table prior to patient positioning around the post.

etiology related to nerve injuries involving the sciatic, femoral, and pudendal nerves. The purpose of this technique article is to describe our method for using traction only for central compartment work, and releasing the traction to allow the femoral head to reduce the labrum to its anatomic position for acetabular recession, anchor placement, and suture fixation. This technique re-creates the native anatomy and biomechanics of the hip after acetabular recession and labral repair while decreasing traction time.

Surgical Technique

Arthroscopic labral repair surgery is indicated for patients with a symptomatic labral tear who have failed conservative management. The “in-round” repair technique can be used for all labral repairs, and there are no contraindications to this specific technique that would not also be a contraindication to hip arthroscopy for labral repair in general.

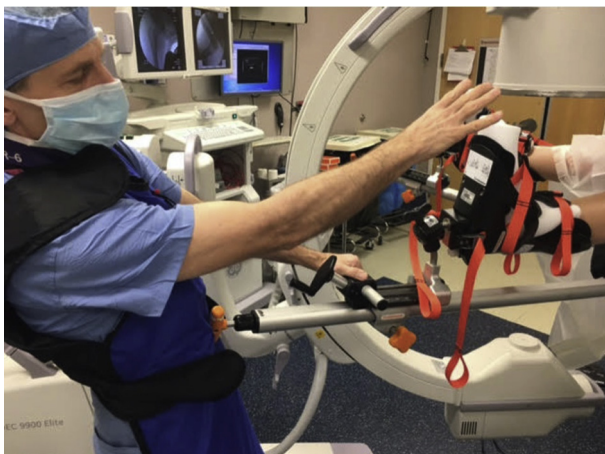

Fig 2. The treating surgeon briefly uses gross and fine traction for prior to the start of the surgery to confirm joint position and fluoroscopic access during the case. This traction typically lasts less than 2 minutes.

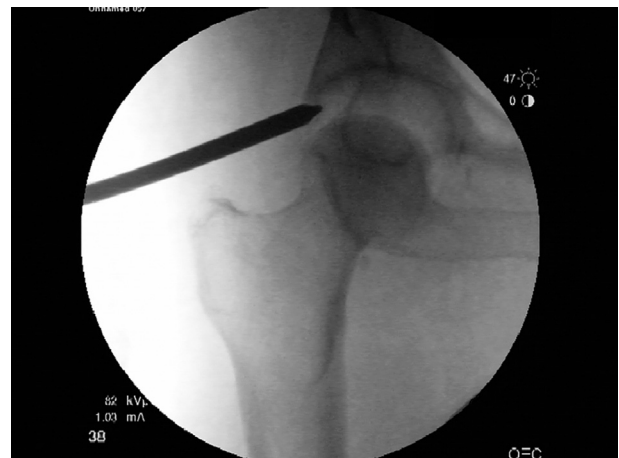

Fig 3. This cannula has been placed over a nitinol wire to gain access to the joint through the anterolateral portal. The needle placement, subsequent nitinol wire shuttling, and cannula placement are all performed using fluoroscopic assistance.

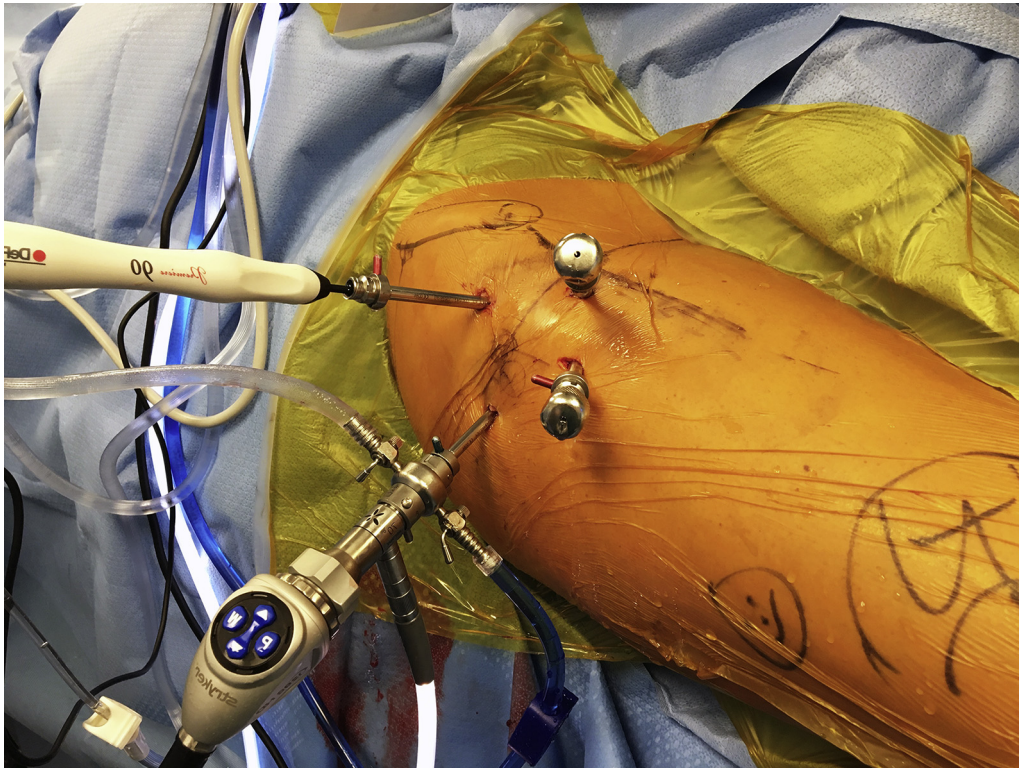


Fig 4. This image demonstrates the portal orientation for our hip arthroscopy technique. The camera is viewing through the anterolateral portal, the electrocautery device is in the Dienst portal, the direct anterior portal is most anterior, and the mid-anterior portal is most distal on the leg. The head is to the upper left of the image and the operative foot is to the lower right.

Preoperative Patient Positioning

The patient is placed under a general anesthetic and positioned on a hip traction specific table (Advanced Supine Hip Positioning System; Smith & Nephew, Andover, MA). The standard perineal post is wrapped

with a viscoelastic surgical pad (Knee Crutch Action Pad Medium; Universal Medical, Hagerstown, MD) (Fig 1). The pad and post are then put in a plastic bag for cleanliness and placed in the surgical table. The feet

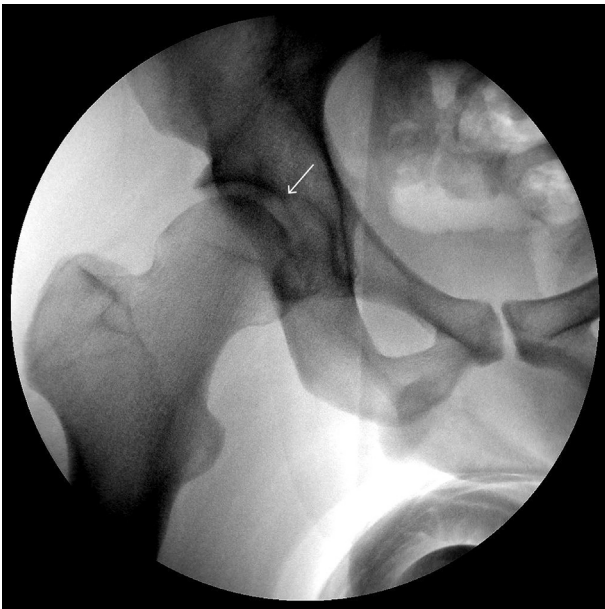

Fig 5. This fluoroscopic image of the hip demonstrates the crossover point with the white arrow.

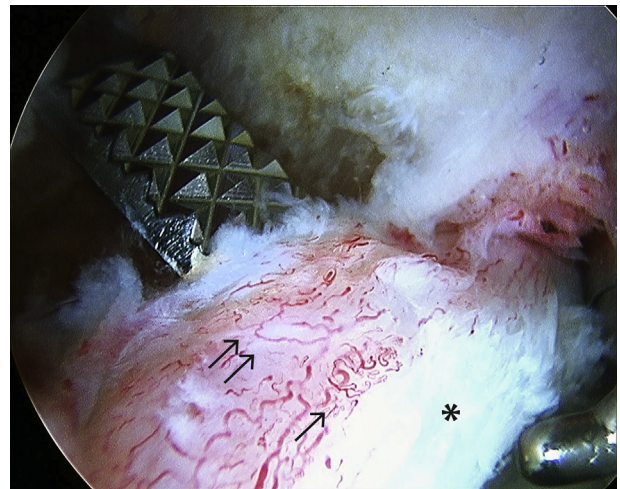


Fig 6. This arthroscopic image demonstrates the knife rasp instrument being used to lift the capsule while preserving the vascular blood supply to the labrum noted by the double black arrows. The labral junction is preserved with this technique demonstrated by the single black arrow. The probe in the lower right corner of the image demonstrates the intra-articular space of the joint. (*, labrum.)

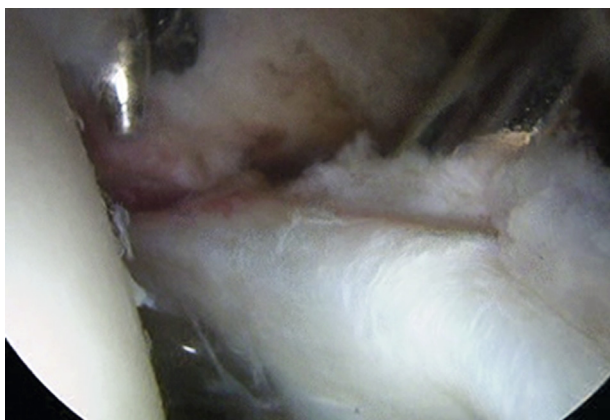

Fig 7. The arthroscopic burr is placed between the labrum and bone and is used to recess the acetabular rim on the reverse setting to prevent damage to the labrum. The femoral head is on the left side of the image.

are secured in the provided distraction boots associated with the table. Paralysis status is confirmed with anesthesia prior to beginning traction. The nonoperative leg is positioned under gross traction first at approximately a 45° angle from the bed. The operative leg is placed with the patella facing directly upward and the hip pushed into valgus by the post. Preoperative images are then obtained with traction to confirm that the joint can be accessed with the current position (Fig 2). After fluoroscopic confirmation, traction is released for sterile preparation and draping. Similarly, for femoroacetabular impingement cases, further imaging in hip flexion, abduction, and external rotation may be obtained without traction.

The surgical procedure begins using traction to distract the joint for assessment of a positive vacuum

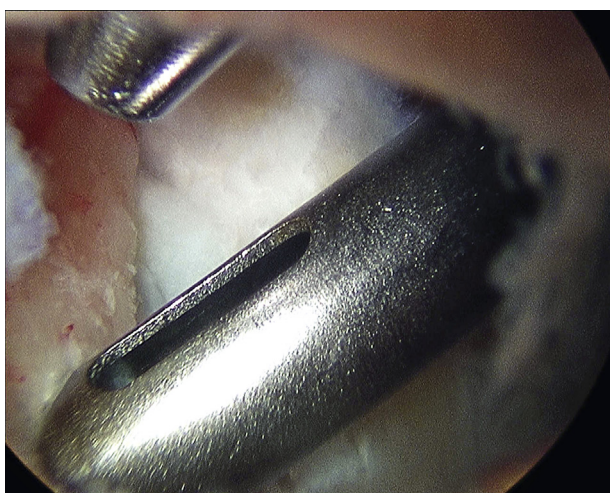


Fig 8. This arthroscopic image demonstrates placement of the anchor guide for inserting suture-anchors. The mid-anterior portal is used for this step to obtain the appropriate angle so that the anchor is placed in bone and does not violate the intra-articular cartilage.

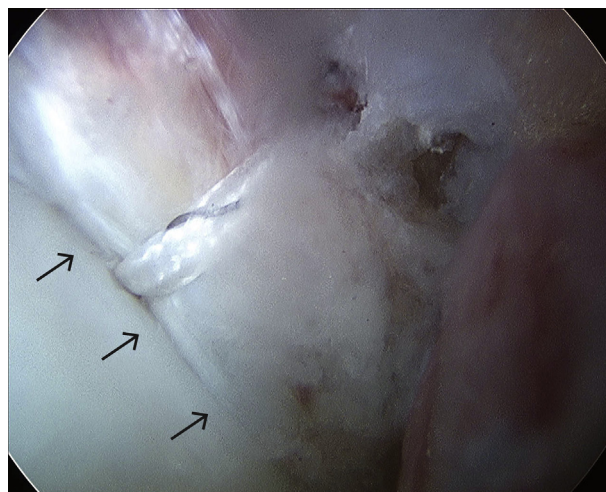


Fig 9. The arthroscopic knot has been placed behind the labrum in this view. The arrows demonstrate the final in-round repair between the cartilage surface and labrum.

sign. We use a previously described technique for gaining access to the joint.¹⁴ Our presented surgical technique uses traction for access to the joint and work in the central compartment only. We ask the operating room staff to record on a white board or scrub table the number of turns of traction applied and removed throughout the procedure to keep an accurate account of the amount of traction used (Video 1).

Arthroscopic Portal Placement

The anterolateral portal is created first using a 17-gauge cannulated needle and then nitinol wire shuttle, followed by a 5.5-mm obturator and cannula (Fig 3). A 70° arthroscope is then inserted into the joint. All other portals are established under direct arthroscopic view (Fig 4).

Acetabular Rim Recession

Full traction to achieve >9 mm of distraction is achieved to fully inspect the labral tear and any other central compartment pathology that may be present such as chondral injury. Once the pathology has been inspected, the anterior point of the crossover sign is identified by fluoroscopy (Fig 5). Using either a knife rasp or radioablation with high fluid flow, an incision is made in the capsule 3 to 5 mm above the capsulolabral junction taking care to avoid the blood supply that lies at this junction. A knife rasp is used to separate the labrum from the acetabular rim, being careful not to violate the chondrolabral junction (Fig 6). During this process, full traction is maintained to visualize the chondrolabral junction and confirm that it has not been violated. Next the acetabular rim is recessed using a 4-mm round abrader through the Dienst portal. The abrader should be used on reverse so that it can bump up against the back of the labrum without grasping and

Table 1. Pearls and Pitfalls of Intermittent Hip Traction

Pearls	Pitfalls
In young patients, a 4-mm round abradar can be used in the <i>reverse</i> mode only, directly up against the labrum without destroying the tissue.	In older patients, the labrum may not be able to withstand direct contact with the abradar, even in the reverse mode.
Several turns of traction should be left on while recessing the acetabular rim so that the labrum will not be caught between the femoral head and abradar	Excessive recession of the acetabular rim can result in an out-of-round repair.
While leg traction is being released in order to move the labrum back to the newly recessed rim for fixation, the sutures should be lightly tensioned to avoid trapping them in the joint.	An attentive nursing staff is required for the success of this procedure.
Using the scrub table or a white board in the operation theater can help the team to record traction times and the amount of traction applied or removed.	Without proper recording and management of fluids used, traction time, and traction amount, the risk for complications increases.
Use the midanterior portal to place anchors in a safe zone. Additionally, fluoroscopy can be used to confirm anchor placement and angle.	If other portals are used or the angle is not correct, the surgeon risks drilling into the acetabulum cartilage or out the outer cortex without fixation.

destroying the tissue. Most traction can be released during this process but 1 to 2 turns should be kept on to avoid pressing the labrum between the abradar and the femoral head (Fig 7). Removal of bone from the acetabular rim will inherently change the shape of the labrum after it is fixed and excessive recession will result in an out-of-round repair.

Labral Fixation

After recession of the acetabulum, traction can be fully released for the placement of 2.3-mm osteoraptor suture anchors (Smith & Nephew) approximately 1 mm apart (Fig 8). Sutures are shuttled using the Dienst or anterior portal through the chondrolabral complex with a 17-gauge needle and chia suture relay under full traction. This process is repeated if a mattress suture configuration is desired. Sutures are retrieved through the midanterior portal. While viewing through the anterolateral portal, traction is slowly released as sutures are being simultaneously tensioned. This avoids pulling the sutures inside the central compartment and trapping them in the reduced joint. The first knot of the suture can be tied but not tightened with a minimal amount of traction remaining. The knot is placed above the joint in the capsular recess and the final tie down is performed with traction fully released (Fig 9). Releasing traction and allowing the femoral head to concentrically reduce brings the labrum up against the femoral

head in an in-round fashion. If the knot is tied with significant traction still applied, the surgeon risks creating an out-of-round repair in which the labrum does not conform to the femoral head and therefore does not function as a seal. If the final tie down is performed without the femoral head fully reduced, the labrum may become everted, which will also affect its ability to seal the joint. This technique reconstitutes the natural footprint and hoop stresses of the labrum to the newly recessed rim. We believe this technique helps tension the labral repair to better contour to the anatomy of the femoral head and thereby improve the suction seal associated with the hip joint (Table 1, Video 1).

Peripheral Compartment Inspection

Pathology in the peripheral compartment should be addressed with the joint under no traction and flexed to 45°. From this position the labral seal should be inspected to ensure a tight contour between the labrum and femoral head. If the surgeon needs access to the central compartment again, the circulating nurse can again apply gross and fine traction as necessary. This process dramatically decreases the traction time for our cases as we are only using traction for the critical portions of the repair. This intermittent traction is accomplished with constant communication between the operating surgeon and the circulating nurse to either add or remove traction (Video 1).

Rehabilitation

Postoperatively, for 6 weeks, patients are encouraged to use crutch assistance and lightly weight bear on the operative leg with the knee locked in extension to decrease forces across the hip. No braces or formal

Table 2. Advantages and Disadvantages of Intermittent Hip Traction

Advantages	Disadvantages
Preserving the chondrolabral junction during acetabular recession allows greater contouring while maintaining native hip anatomy.	The femoral head is close to the burr during acetabular recession, and the surgeon must control the burr movement during recession.
The femoral head in the acetabulum helps reduce the labrum in an anatomic position for an "in-round" repair.	There is decreased space to move and visualize the acetabulum during repair with traction off.
Intermittent traction is noninvasive treatment.	Constant communication between the surgeon and circulating nurse limits the nurse's ability to do other OR activities.
Avoids prolonged traction because traction is only used at necessary times.	More difficult to accurately measure total traction time.
Padded post limits pressure contact.	

physical therapies are used during this period. At 6 weeks, patients may use a stationary bike with no resistance. At 10 weeks, they may use an elliptical trainer on low resistance or swim with a paddle board. After 4 months, patients can begin lower extremity strengthening with short-arc leg presses and hamstring curls. Patients are allowed to then layer in activities with the goal of returning to normal function at 6 months postoperatively.

Discussion

Clinical outcomes of labral repair are promising, but the optimal surgical technique has yet to be determined.^{9,13,15,16} The use of intermittent traction during hip arthroscopy allows for a reproducible repair of the labrum while restoring the natural biomechanics of the labral seal. When the femoral head is concentrically reduced before the final tie down, the labrum is brought against the head in an in-round fashion and the labral seal is reinstated. This seal and the in-round nature of the repair can be inspected from the peripheral compartment. By releasing traction fully before the final tie down of each suture and effectively sealing the labrum against the femoral head, eversion of the labrum is avoided at the time of tie-down. With this technique, in our experience, it is not possible to accidentally overtension the suture and subsequently evert the labrum. The in-round and noneverted labrum best restores the natural anatomy of the joint. Restoration of the hip's partial vacuum can also avoid poor postoperative outcomes such as micro-instability and may help prevent the development of hip osteoarthritis (Table 2).^{17,18}

The use of intermittent traction may also be beneficial from the standpoint of nerve-related injuries. Previous reports on nerve complications associated with hip arthroscopy have been limited by case series and retrospective reviews. In a 2013 systematic review of 92 studies, evaluating more than 6,000 patients undergoing hip arthroscopies, nerve injuries accounted for only 87 (1.4%) of the described complications.¹⁹ Of these cases, 34 (40%) were related to the pudendal nerve and 18 (21%) affected the lateral femoral cutaneous nerve. Some surgeons believe, however, that this prevalence of nerve complications may be underreported.

In 2014, Dippmann et al. reviewed a series of 52 patients undergoing hip arthroscopy and found that almost half of patients (46%) reported symptoms of nerve dysfunction within the first 6 weeks after surgery. At 1 year postoperatively, 18% continued to report symptoms.¹² This figure is much higher than other reports that place the rate of nerve complications between 1% and 5%.^{10,11,20} Dippmann et al. also found that there was no difference in traction time between the group of patients with nerve complications and those without nerve complications

suggesting that time of traction may not be the only variable related to nerve injuries. The nerve complications associated with hip arthroscopy are likely multifactorial depending on patient anatomy, body habitus, positioning level of flexion, and the amount of traction in addition to the time duration of traction. For example, a cadaveric model has demonstrated that hip flexion up to 45° and increasing traction up to 40 kg increases pudendal nerve compression.²¹

The treating physician in the presented technique has been aware of this discrepancy in nerve injury reporting in the literature and has been following his patients for this complication. He has been using the described technique with the padded post since 2006 and performed more than 1,000 hip arthroscopy cases requiring traction. In this series, he has not had any episodes of pudendal nerve injury in the postoperative period using the described padded post and intermittent traction technique.

In summary, hip arthroscopy is a safe and effective treatment for numerous hip pathologies and conditions. Creating an anatomic in-round labral repair has been an important advancement in the treatment of many hip arthroscopy patients. Similarly, perineal nerve complications are some of the most common issues related to hip arthroscopy. The intermittent traction technique described in this article may benefit other surgeons in limiting the amount and severity of nerve complications associated with hip arthroscopy while simultaneously improving the quality of an in-round anatomic labral repair.

References

1. Burman MS. Arthroscopy or the direct visualization of joints: An experimental cadaver study. 1931. *Clin Orthop* 2001;390:5-9.
2. Eriksson E, Sebik A. Arthroscopy and arthroscopic surgery in a gas versus a fluid medium. *Orthop Clin North Am* 1982;13:293-298.
3. Suzuki S, Awaya G, Okada Y, Maekawa M, Ikeda T, Tada H. Arthroscopic diagnosis of ruptured acetabular labrum. *Acta Orthop Scand* 1986;57:513-515.
4. Kelly BT, Weiland DE, Schenker ML, Philippon MJ. Arthroscopic labral repair in the hip: Surgical technique and review of the literature. *Arthroscopy* 2005;21:1496-1504.
5. Myers SR, Eijer H, Ganz R. Anterior femoroacetabular impingement after periacetabular osteotomy. *Clin Orthop* 1999;363:93-99.
6. Peelle MW, Della Rocca GJ, Maloney WJ, Curry MC, Clohisy JC. Acetabular and femoral radiographic abnormalities associated with labral tears. *Clin Orthop* 2005;441:327-333.
7. Espinosa N, Rothenfluh DA, Beck M, Ganz R, Leunig M. Treatment of femoro-acetabular impingement: Preliminary results of labral refixation. *J Bone Joint Surg Am* 2006;88:925-935.

8. Philippon MJ, Peixoto LP, Goljan P. Acetabular labral tears: Debridement, repair, reconstruction. *Oper Tech Sports Med* 2012;20:281-286.
9. Redmond JM, El Bitar YF, Gupta A, Stake CE, Vemula SP, Domb BG. Arthroscopic acetabuloplasty and labral refixation without labral detachment. *Am J Sports Med* 2015;43:105-112.
10. Byrd JWT, Jones KS. Arthroscopic management of femoroacetabular impingement in athletes. *Am J Sports Med* 2011;39:7S-13S (suppl).
11. Clarke MT, Arora A, Villar RN. Hip arthroscopy: Complications in 1054 cases. *Clin Orthop* 2003;406:84-88.
12. Dippmann C, Thorborg K, Kraemer O, Winge S, Hölmich P. Symptoms of nerve dysfunction after hip arthroscopy: An under-reported complication? *Arthroscopy* 2014;30:202-207.
13. Fry R, Domb B. Labral base refixation in the hip: Rationale and technique for an anatomic approach to labral repair. *Arthroscopy* 2010;26:S81-S89 (9 suppl).
14. Alpaugh K, Shin SR, Martin SD. Intra-articular fluid distension for initial portal placement during hip arthroscopy: The "femoral head drop" technique. *Arthrosc Tech* 2015;4:e23-e27.
15. Jackson TJ, Hammarstedt JE, Vemula SP, Domb BG. Acetabular labral base repair versus circumferential suture repair: A matched-paired comparison of clinical outcomes. *Arthroscopy* 2015;31:1716-1721.
16. Jackson TJ, Hanypsiak B, Stake CE, Lindner D, El Bitar YF, Domb BG. Arthroscopic labral base repair in the hip: Clinical results of a described technique. *Arthroscopy* 2014;30:208-213.
17. Philippon MJ, Faucet SC, Briggs KK. Arthroscopic hip labral repair. *Arthrosc Tech* 2013;2:e73-e76.
18. Sankar WN, Nevitt M, Parvizi J, Felson DT, Agricola R, Leunig M. Femoroacetabular impingement: Defining the condition and its role in the pathophysiology of osteoarthritis. *J Am Acad Orthop Surg* 2013;21:S7-S15 (suppl 1).
19. Harris JD, McCormick FM, Abrams GD, et al. Complications and reoperations during and after hip arthroscopy: A systematic review of 92 studies and more than 6,000 patients. *Arthroscopy* 2013;29:589-595.
20. Sampson TG. Complications of hip arthroscopy. *Clin Sports Med* 2001;20:831-835.
21. Kocaoğlu H, Başarı K, Akmeşe R, et al. The effect of traction force and hip abduction angle on pudendal nerve compression in hip arthroscopy: A cadaveric model. *Arthroscopy* 2015;31:1974-1980.e6.