

Anterolateral Ligament Reconstruction



A Possible Option in the Therapeutic Arsenal for Persistent Rotatory Instability After ACL Reconstruction

Camilo Partezani Helito,^{*†‡} MD, PhD,
 Adnan Saithna,^{§||} BmedSci(Hons), MBChB, DipSEM, MSc, FRCS(Tr&Orth),
 Marcelo B. Bonadio,[†] MD, Matt Daggett,[¶] DO, MBA, Edoardo Monaco,[#] MD,
 Marco K. Demange,[†] MD, PhD, and Bertrand Sonnerly-Cottet,^{**} MD

Investigation performed at the Department of Orthopedics and Traumatology, Faculty of Medicine, University of São Paulo, São Paulo, Brazil

Keywords: anterior cruciate ligament; anterolateral ligament; pivot shift; rotatory instability

The results of anterior cruciate ligament reconstruction (ACLR) are widely recognized to be satisfactory on the basis of outcome measures such as the International Knee Documentation Committee (IKDC) and Lysholm scores.⁵ However, there is moderate variation among several series of different techniques. For example, Hussein et al¹⁶ showed a range of residual pivot, from 7% to 33%, depending on the technique used. Furthermore, up to 30% of patients in contemporary series can still experience persistent instability,^{19,21} and only 65% to 83% can return to the preinjury level of sport.^{2,16,20,28} The pathophysiology of these important outcomes is multifactorial and may include nonanatomic graft orientation,

meniscal deficiency, bone morphology, poor neuromuscular control, and (of particular recent interest) concomitant injury to the anterolateral structures of the knee.^{6,11,12,32}

Systematic reviews have demonstrated that for those patients with high preoperative grades of pivot shift, the rate of residual pivot shift is significantly lower when a lateral extra-articular tenodesis is performed in addition to ACLR.^{18,28} In addition, Rezende et al³¹ showed that patients with combined reconstructions were more likely to demonstrate improved stability based on the pivot-shift test. Even though controversy still exists regarding the biomechanical role of the anterolateral ligament (ALL),^{1,26} these clinical results are consistent with cadaveric sectioning studies that indicate an important role for the ALL in controlling the pivot-shift phenomenon.^{3,24,30,36,39} It has therefore been suggested that when high grades of pivot shift are detected preoperatively, an unrecognized injury to the ALL should be considered because isolated ACLR may fail to restore normal knee stability.^{9,17}

Although lateral extra-articular procedures are associated with improved rates of persistent pivot shift,^{16,34} graft rupture,³⁷ and return to sport³⁷ when performed at the time of ACLR, the role of isolated ALL reconstruction among those patients presenting with persistent instability after isolated ACLR has not, to our knowledge, been previously evaluated. However, this is an important group of patients, not only because of the functional limitations of persistent instability, but also because of the high rates at which this phenomenon is reported to occur and the fact that alternative surgical strategies (revision ACLR or selective reconstruction of the posterolateral bundle) are associated with specific additional complications.²³

The good short-term clinical outcomes from large series of combined anterior cruciate ligament (ACL) and ALL

Address correspondence to Camilo Partezani Helito, MD, PhD, Rua Ovídio Pires de Campos 333, São Paulo, SP 05403-010, Brazil (email: camilo_helito@yahoo.com.br).

[†]Grupo de Joelho, Instituto de Ortopedia e Traumatologia, Hospital das Clínicas HCFMUSP, Faculdade de Medicina, Universidade de São Paulo, São Paulo, Brazil.

[‡]Hospital Sirio Libanês, São Paulo, Brazil.

[§]Medical Technologies and Advanced Materials, Clifton Campus, Nottingham Trent University, Nottingham, UK.

^{||}Renacres Hospital, Lancashire, UK.

[¶]Kansas City University, Kansas City, Missouri, USA.

[#]University of Rome La Sapienza, Rome, Italy.

^{**}Centre Orthopédique Santy, FIFA Medical Centre of Excellence, Groupe Ramsay-Generale de Sante, Hospital Privé Jean Mermoz, Lyon, France.

One or more of the authors declared the following potential conflict of interest or source of funding: E.M., A.S. and B.S.-C. are paid consultants for Arthrex.

Ethical approval for this study was obtained from the University of São Paulo, São Paulo, Brazil.

The Orthopaedic Journal of Sports Medicine, 6(1), 2325967117751348

DOI: 10.1177/2325967117751348

© The Author(s) 2018

This open-access article is published and distributed under the Creative Commons Attribution - NonCommercial - No Derivatives License (<http://creativecommons.org/licenses/by-nc-nd/4.0/>), which permits the noncommercial use, distribution, and reproduction of the article in any medium, provided the original author and source are credited. You may not alter, transform, or build upon this article without the permission of the Author(s). For reprints and permission queries, please visit SAGE's website at <http://www.sagepub.com/journalsPermissions.nav>.

reconstruction^{37,40} have encouraged us to evaluate the role of isolated ALL reconstruction in the management of patients who present with persistent instability despite a technically adequate ACLR and no associated pathology. This case report documents the successful resolution of persistent rotatory instability by ALL reconstruction.

CASE PRESENTATION

A 37-year-old female professional dancer sustained an ACL injury to her right knee in a motorcycle accident in 2011. She underwent subsequent ACLR. At the time of surgery, examination revealed 3+ Lachman and 3+ pivot-shift tests, with no concomitant injuries. The reconstruction was performed with 8-mm-diameter quadrupled hamstring tendons, normally the first choice for women at this age in our country. The femoral tunnel was drilled close to the anteromedial bundle position with an outside-in technique.⁷ The fixation was performed with metal interference screws at 30° of knee flexion.

Postoperatively, the patient participated in standard rehabilitation for ACLR and underwent an uncomplicated recovery. Even though an improvement in instability was noted in activities of daily living, the patient still complained of episodes of giving way with rotational movements, mainly during dance-related jumping and landing exercises. As a result, further rehabilitation was prescribed focusing on quadriceps and gluteal muscle strengthening and proprioception. One year following ACLR, the patient had good core stability and negative Lachman (KT-1000 of 4 mm) and anterior drawer test results but had a residual pivot glide. Despite continued participation in rehabilitation, the patient was unable to perform professional dance activity owing to persistent rotatory instability.

Given the failure of this additional nonoperative treatment at 2 years following ACLR, a surgical procedure was considered. It was noted that the first reconstruction was technically adequate, with an intact graft (Figure 1) and appropriate tunnel positioning (Figure 2). There was no clinical or magnetic resonance imaging evidence of concomitant intra-articular pathology (eg, altered bony morphology, tibial slope, or meniscal/chondral lesions). The surgical options initially proposed were ACL revision or an augmentation of the posterolateral bundle. The patient was counseled regarding the surgical morbidity and possible complications of a revision procedure. In addition, the possibility of performing an isolated reconstruction of the ALL was discussed. It was specifically stated that isolated ALL reconstruction had not previously been reported as a treatment for persistent instability after a technically adequate ACLR but that we had experience of good results of combined ACL and ALL reconstructions for the treatment of patients with high-grade pivot shift. The patient was completely aware and accepted the risks of ALL reconstruction in preference to a revision ACL procedure.

Initially, knee arthroscopy was performed to assess the integrity of the ACL graft and any associated lesions. The ACL graft, though with an imperfect vascularized appearance and minimal laxity, was intact and functional, and no

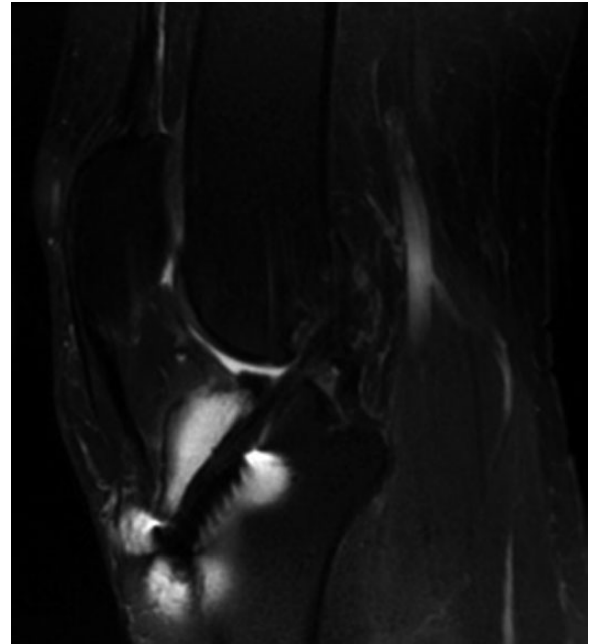


Figure 1. Sagittal magnetic resonance imaging knee view showing the graft (neoligament) after an anterior cruciate ligament reconstruction. Despite the presence of artifacts from previous fixation with metal interference screws, it is possible to visualize the anterior cruciate ligament graft.

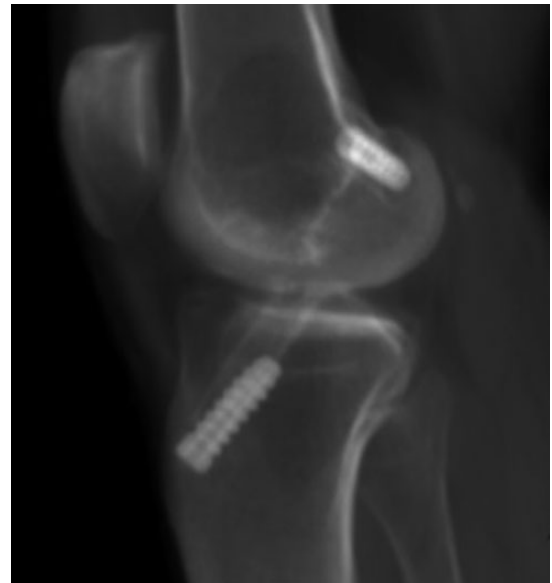

Figure 2. Lateral radiographic knee view showing the anterior cruciate ligament tunnels and the metal screws used for graft fixation. The femoral tunnel was performed close to the anteromedial bundle position.

associated lesions were found. For the ALL reconstruction, a lateral incision was made in line with the iliotibial band, and a femoral tunnel on the posterior border of the lateral epicondyle and a tibial tunnel between the Gerdy tubercle and the fibular head (7 mm distal to the lateral tibial plateau) were

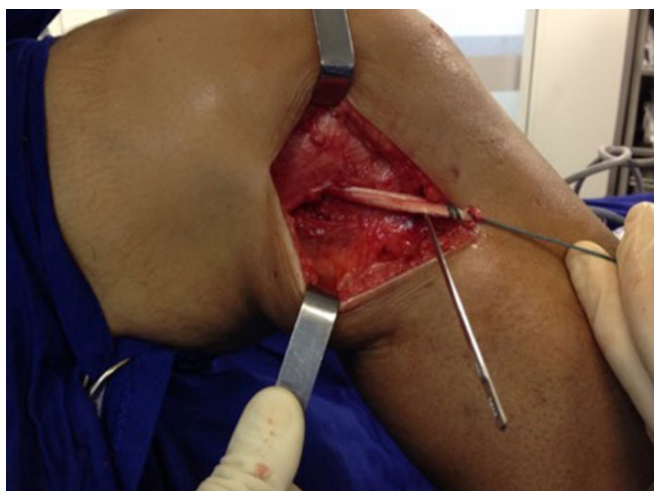

Figure 3. Lateral view of the right knee showing the extra-articular reconstruction of the anterolateral ligament. The graft is already fixed into the femur and is going in an antero-inferior direction until its tibial insertion between the Gerdy tubercle and the fibular head.

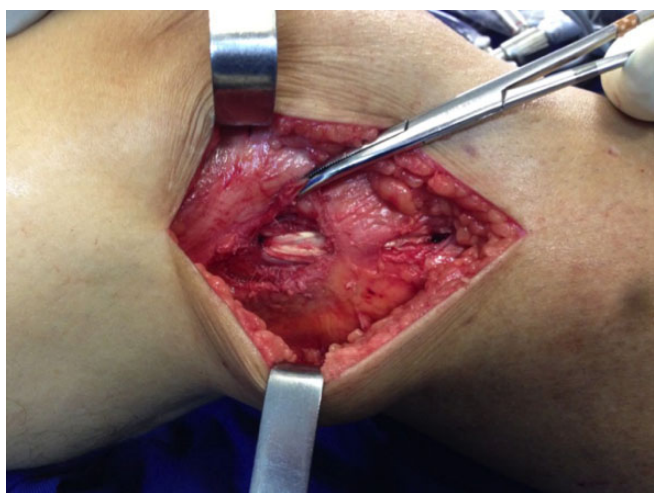

Figure 4. Lateral view of the right knee showing the final appearance of the anterolateral ligament reconstruction, which is already fixed into the femur and tibia, passing under the iliotibial band to respect its anatomic path.

created with a 7-mm drill. An allograft semitendinosus tendon from our institution's tissue bank was used as a graft, and fixation was performed at 30° of flexion and neutral rotation with absorbable 7 × 25-mm interference screws (Smith & Nephew) (Figures 3 and 4). The allograft was chosen because, despite being a low-morbidity solution, we did not want to harvest either the iliotibial band or the contralateral side. After the ALL reconstruction was performed, repeat clinical examination revealed that the preoperative pivot glide had been abolished (see the Video Supplement).

Postoperative rehabilitation comprised immediate range of motion exercises and full weightbearing with a brace

worn while walking for 3 weeks. At 6 weeks postoperatively, the patient stated that the knee was more stable, and at 3 months, she returned to her dance activities without restriction and without subjective complaints of rotational instability. At 4 months after the ALL reconstruction, she was back to her preinjury level of dance participation. At 2 years after reconstruction of the ALL, the patient experienced no further instability and had negative pivot-shift and Lachman test results. The IKDC score increased from 87.4 at 4 years after ACLR to 96.6 at final follow-up after ALL reconstruction.

Informed consent was obtained from the patient for publication, including photographs and video material.

DISCUSSION

This case report demonstrates that isolated ALL reconstruction can be utilized to treat persistent rotatory instability after ACLR. Demonstrating the utility of this strategy is the success of the procedure in abolishing pivot glide and subjective symptoms of instability, while allowing return to the preinjury level of activity. This study highlights 2 further important learning points. The first is that not all patients with a technically adequate ACLR experience complete resolution of rotational instability. Although the pathophysiology of this phenomenon is multifactorial, Inderhaug et al¹⁷ demonstrated that isolated ACLR in patients with concomitant anterolateral injury did not re-establish normal knee kinematics. Second, failure to preoperatively recognize lesions of the anterolateral structures may lead to their missed treatment, potentially resulting in persistent instability with failure to return to sport.

The role of extra-articular procedures in reducing the rate of residual instability after ACLR was demonstrated in 2 recent systematic reviews—both of which concluded that combined procedures were more effective than isolated ACLRs in reducing residual instability among patients with high-grade pivot shift.^{15,34} However, in a recently published series, the specific combined ALL reconstructions were not yet able to totally abolish the postoperative pivot-shift index.³⁸ To our knowledge, the use of ALL reconstruction as an isolated procedure subsequent to previous ACLR for ongoing symptoms of instability has not been described. The excellent outcomes in this case help to establish ALL reconstruction as a potential treatment option for persistent rotatory instability.

In this scenario, the alternative surgical option of performing an extra-articular reconstruction alone, rather than an augmentation or complete revision of the ACL, was an appealing concept because it afforded lower morbidity. In contrast, Buda et al⁴ caused an ACL-intact bundle injury in 2 cases of their series of selective reconstruction for partial ACL tears; furthermore, ACL revision is well recognized to have a higher rate of complications and failure than primary reconstruction.²³ In this particular case, a lateral incision was used to perform the ALL reconstruction, but in our current practice (with the evolution of this technique), the procedure is performed percutaneously, with the graft passed under the iliotibial tract.

We propose that this technique be considered for patients who (1) have persistent rotatory instability, (2) are high-demand patients participating in activities that involve rotational movements of the knee, and (3) have failed conservative treatment. It is crucial, however, to check that the patient is well rehabilitated, that the ACLR is intact, that the graft is well oriented, and that there are no other major abnormalities that could contribute to persistent instability, such as malalignment or chondral injury/meniscal loss.^{25,29} However, it is important to highlight that one of the potential concerns of extra-articular procedures is that they may theoretically overconstrain the knee, thereby increasing pressures in the lateral compartment and predisposing to early degenerative changes—although even the possibility of overconstraint is controversial and a matter of recent literature debate.^{33,35} Long-term studies by Ferretti et al¹⁰ and Marcacci et al²² and a recent systematic review by Devitt et al⁸ did not show any evidence to support an increased risk of osteoarthritis in combined ACL and extra-articular reconstructions. Furthermore, in a recent large multicenter series of combined ACL and ALL reconstruction, Thauinat et al⁴⁰ demonstrated a broadly comparable reoperation rate to isolated ACLR and very few specific complications.

The outcomes of this case report suggest that persistent instability after ACLR be further evaluated as a potentially important indication for subsequent isolated ALL reconstruction. It can also be postulated that if an extra-articular procedure had been performed at the time of the index surgery, this may have precluded reoperation and reduced the time taken to return to the preinjury level of sport. However, the indications for combined reconstructions are not yet clearly defined. It therefore seems logical to identify those patients with injury to the anterolateral structures prior to surgery, and for that reason, the use of imaging evaluation has recently increased in popularity.

Well-defined imaging protocols for the characterization of the anterolateral structures of the knee do not currently exist, but several authors, including Helito et al,^{13,14} Kosy et al,¹⁸ Oshima et al,²⁷ and Van Dyck et al,⁴¹ have attempted to establish normal patterns and ALL abnormalities with magnetic resonance imaging and ultrasound. The goal is to identify patients with preoperative abnormalities on imaging studies in association with a clinical suspicion of injury to the anterolateral structures (based on high-grade pivot shift) to determine which patients are most likely to be at risk of persistent instability if treated with an isolated ACLR. These patients may be more likely to benefit from combined intra- and extra-articular reconstructions than those without evidence of anterolateral injury.

This study brings with it the inherent limitations of all case reports, in that it is difficult to extrapolate the findings to the entire population.

CONCLUSION

This case report shows that isolated ALL reconstruction is a useful potential option for patients with persistent rotatory instability following ACLR. Even with the clinical

success of this case, the multifactorial pathobiomechanics of the pivot shift need to be further understood and evaluated clinically.

A Video Supplement for this article is available at <http://journals.sagepub.com/doi/suppl/10.1177/2325967117751348>.

REFERENCES

1. Amis AA. Anterolateral knee biomechanics. *Knee Surg Sports Traumatol Arthrosc.* 2017;25:1015-1023.
2. Ardern CL, Webster KE, Taylor NF, Feller JA. Return to sport following anterior cruciate ligament reconstruction surgery: a systematic review and meta-analysis of the state of play. *Br J Sports Med.* 2011;45(7):596-606.
3. Bonanzinga T, Signorelli C, Grassi A, et al. Kinematics of ACL and anterolateral ligament: part I. Combined lesion. *Knee Surg Sports Traumatol Arthrosc.* 2017;25(4):1055-1061.
4. Buda R, Ruffilli A, Parma A, et al. Partial ACL tears: anatomic reconstruction versus nonanatomic augmentation surgery. *Orthopedics.* 2013;36(9):e1108-e1113.
5. Chen Y, Chua KH, Sing A, et al. Outcome of single-bundle hamstring anterior cruciate ligament reconstruction using the anteromedial versus the transtibial technique: a systematic review and meta-analysis. *Arthroscopy.* 2015;31(9):1784-1794.
6. Claes S, Vereecke E, Maes M, Victor J, Verdonk P, Bellemans J. Anatomy of the anterolateral ligament of the knee. *J Anat.* 2013;223(4):321-328.
7. Cross MB, Musahl V, Loughlin P, Hammoud S, Suero E, Pearle AD. Anteromedial versus central single-bundle graft position: which anatomic graft position to choose? *Knee Surg Sports Traumatol Arthrosc.* 2012;20:1276-1281.
8. Devitt BM, Bouguennec N, Barfod KW, Porter T, Webster KE, Feller JA. Combined anterior cruciate ligament reconstruction and lateral extra-articular tenodesis does not result in an increased rate of osteoarthritis: a systematic review and best evidence synthesis. *Knee Surg Sports Traumatol Arthrosc.* 2017;25(4):1149-1160.
9. Ferretti A, Monaco E, Fabbri M, Maestri B, De Carli A. Prevalence and classification of injuries of anterolateral complex in acute anterior cruciate ligament tears. *Arthroscopy.* 2017;33(1):147-154.
10. Ferretti A, Monaco E, Ponzio A, et al. Combined intra-articular and extra-articular reconstruction in anterior cruciate ligament deficient knee: 25 years later. *Arthroscopy.* 2016;32(10):2039-2047.
11. Ferretti A, Monaco E, Vadala A. Rotatory instability of the knee after ACL tear and reconstruction. *J Orthop Traumatol.* 2014;15(2):75-79.
12. Helito CP, Demange MK, Bonadio MB, et al. Anatomy and histology of the knee anterolateral ligament. *Orthop J Sports Med.* 2013;1(7):2325967113513546.
13. Helito CP, Helito PV, Costa HP, et al. MRI evaluation of the anterolateral ligament of the knee: assessment in routine 1.5-T scans. *Skeletal Radiol.* 2014;43(10):1421-1427.
14. Helito CP, Helito PV, Costa HP, Demange MK, Bordalo-Rodrigues M. Assessment of the anterolateral ligament of the knee by magnetic resonance imaging in acute injuries of the anterior cruciate ligament. *Arthroscopy.* 2017;33(1):140-146.
15. Hewison CE, Tran MN, Kaniki N, Remtulla A, Bryant D, Getgood AM. Lateral extra-articular tenodesis reduces rotational laxity when combined with anterior cruciate ligament reconstruction: a systematic review of the literature. *Arthroscopy.* 2015;31(10):2022-2034.
16. Hussein M, van Eck CF, Cretnik A, Dinevski D, Fu FH. Prospective randomized clinical evaluation of conventional single-bundle, anatomic single-bundle, and anatomic double-bundle anterior cruciate

- ligament reconstruction: 281 cases with 3- to 5-year follow-up. *Am J Sports Med.* 2012;40(3):512-520.
17. Inderhaug E, Stephen JM, Williams A, Amis AA. Biomechanical comparison of anterolateral procedures combined with anterior cruciate ligament reconstruction. *Am J Sports Med.* 2017;45(2):347-354.
 18. Kosy JD, Mandalia VI, Anaspure R. Characterization of the anatomy of the anterolateral ligament of the knee using magnetic resonance imaging. *Skeletal Radiol.* 2015;44(11):1647-1653.
 19. Kraeutler MJ, Bravman JT, McCarty EC. Bone-patellar tendon-bone autograft versus allograft in outcomes of anterior cruciate ligament reconstruction: a meta-analysis of 5182 patients. *Am J Sports Med.* 2013;41(10):2439-2448.
 20. Lai CC, Ardern CL, Feller JA, Webster KE. Eighty-three per cent of elite athletes return to preinjury sport after anterior cruciate ligament reconstruction: a systematic review with meta-analysis of return to sport rates, graft rupture rates and performance outcomes. *Br J Sports Med.* 2018;52(2):128-138.
 21. Li X, Xu CP, Song JQ, Jiang N, Yu B. Single-bundle versus double-bundle anterior cruciate ligament reconstruction: an up-to-date meta-analysis. *Int Orthop.* 2013;37(2):213-226.
 22. Marcacci M, Zaffagnini S, Giordano G, Iacono F, Presti ML. Anterior cruciate ligament reconstruction associated with extra-articular tenodesis: a prospective clinical and radiographic evaluation with 10- to 13-year follow-up. *Am J Sports Med.* 2009;37(4):707-714.
 23. Mayr R, Rosenberger R, Agraharam D, Smekal V, El Attal R. Revision anterior cruciate ligament reconstruction: an update. *Arch Orthop Trauma Surg.* 2012;132(9):1299-1313.
 24. Monaco E, Ferretti A, Labianca L, et al. Navigated knee kinematics after cutting of the ACL and its secondary restraint. *Knee Surg Sports Traumatol Arthrosc.* 2012;20(5):870-877.
 25. Musahl V, Ayeni OR, Citak M, Irrgang JJ, Pearle AD, Wickiewicz TL. The influence of bony morphology on the magnitude of the pivot shift. *Knee Surg Sports Traumatol Arthrosc.* 2010;18:1232-1238.
 26. Noyes FR, Huser LE, Jurgensmeier D, Walsh J, Levy MS. Is an anterolateral ligament reconstruction required in ACL-reconstructed knees with associated injury to the anterolateral structures? *Am J Sports Med.* 2017;45(5):1018-1027.
 27. Oshima T, Nakase J, Numata H, Takata Y, Tsuchiya H. Ultrasonography imaging of the anterolateral ligament using real-time virtual sonography. *Knee.* 2016;23(2):198-202.
 28. Piefer JW, Pflugner TR, Hwang MD, Lubowitz JH. Anterior cruciate ligament femoral footprint anatomy: systematic review of the 21st century literature. *Arthroscopy.* 2012;28(6):872-881.
 29. Rahnama-Azar AA, Abebe ES, Johnson P, et al. Increased lateral tibial slope predicts high-grade rotatory knee laxity pre-operatively in ACL reconstruction. *Knee Surg Sports Traumatol Arthrosc.* 2017;25(4):1170-1176.
 30. Rasmussen MT, Nitri M, Williams BT, et al. An in vitro robotic assessment of the anterolateral ligament, part 1: secondary role of the anterolateral ligament in the setting of an anterior cruciate ligament injury. *Am J Sports Med.* 2016;44(3):585-592.
 31. Rezende FC, de Moraes VY, Martimbianco AL, Luzo MV, da Silveira Franciozi CE, Belloti JC. Does combined intra- and extraarticular ACL reconstruction improve function and stability? A meta-analysis. *Clin Orthop Relat Res.* 2015;473(8):2609-2618.
 32. Runer A, Birkmaier S, Pamminger M, et al. The anterolateral ligament of the knee: a dissection study. *Knee.* 2016;23(1):8-12.
 33. Schon JM, Moatshe G, Brady AW, et al. Anatomic anterolateral ligament reconstruction of the knee leads to overconstraint at any fixation angle. *Am J Sports Med.* 2016;44(10):2546-2556.
 34. Song GY, Hong L, Zhang H, Zhang J, Li Y, Feng H. Clinical outcomes of combined lateral extra-articular tenodesis and intra-articular anterior cruciate ligament reconstruction in addressing high-grade pivot-shift phenomenon. *Arthroscopy.* 2016;32(5):898-905.
 35. Sonney-Cottet B, Daggett M, Helito CP, et al. Anatomic anterolateral ligament reconstruction leads to overconstraint at any fixation angle: letter to the editor. *Am J Sports Med.* 2016;44(10):NP57-NP58.
 36. Sonnerly-Cottet B, Lutz C, Daggett M, et al. The involvement of the anterolateral ligament in rotational control of the knee. *Am J Sports Med.* 2016;44(5):1209-1214.
 37. Sonnerly-Cottet B, Saithna A, Cavalier M, et al. Anterolateral ligament reconstruction is associated with significantly reduced ACL graft rupture rates at a minimum follow up of 2 years: a prospective comparative study of 502 patients from the SANTI Study Group. *Am J Sports Med.* 2017;45(7):1547-1557.
 38. Sonnerly-Cottet B, Thauinat M, Freychet B, Pupim BH, Murphy CG, Claes S. Outcome of a combined anterior cruciate ligament and anterolateral ligament reconstruction technique with a minimum 2-year follow-up. *Am J Sports Med.* 2015;43:1598-1605.
 39. Spencer L, Burkhart TA, Tran MN, et al. Biomechanical analysis of simulated clinical testing and reconstruction of the anterolateral ligament of the knee. *Am J Sports Med.* 2015;43(9):2189-2197.
 40. Thauinat M, Clowez G, Saithna A, et al. Reoperation rates after combined anterior cruciate ligament and anterolateral ligament reconstruction: a series of 548 patients from the SANTI Study Group with a minimum follow-up of 2 years. *Am J Sports Med.* 2017;45(11):2569-2577.
 41. Van Dyck P, Clockaerts S, Vanhoenacker FM, et al. Anterolateral ligament abnormalities in patients with acute anterior cruciate ligament rupture are associated with lateral meniscal and osseous injuries. *Eur Radiol.* 2016;26(10):3383-3391.