

CASE REPORT

Augmentation of Narrow Anterior Alveolar Ridge Using Autogenous Block Onlay Graft in a Pediatric Patient: A Case Report

Meghna Bhandary¹, Amitha M Hegde², Rajmohan Shetty³, Preethesh Shetty⁴

ABSTRACT

Tooth loss due to trauma often triggers residual alveolar resorption to a greater degree in the sagittal direction leading to atrophy. However, in a pediatric patient, if this defect is left untreated, it can cause further atrophy leading to collapse of the arch. In the maxillary anterior area, this is also of esthetic concern. Hence, it is viable to reconstruct the alveolar defects and restore the alveolar anatomy with superior quality of bone while the patient is still in growing phase to avoid any structural and dental malformation, as well as to provide a more novel treatment like dental implant at a later stage when growth ceases. Modes for successfully augmenting the bone are diverse. Among these, barrier membrane with guided bone regeneration, distraction osteogenesis, and bone block graft is ubiquitous. The current case report deals with the management of horizontal atrophic anterior maxillary region using autologous block bone graft harvested from mandibular symphysis, to augment the alveolar ridge and aid in esthetic and functional restoration of alveolar anatomy by restoring the defect with the bone of superior quality as well as preparing the site for receiving implant prosthesis in future when growth ceases.

Keywords: Autologous bone grafting, Esthetics, Maxillary atrophy, Missing teeth, Ridge augmentation.

International Journal of Clinical Pediatric Dentistry (2021): 10.5005/jp-journals-10005-1931

INTRODUCTION

Traumatic tooth loss is frequently encountered in pediatric patients. It often leads to alveolar resorption. There can be two possible reasons for this. First, it could be due to the avulsion of bone substance during an accident. Second, as resorption of the alveolar crests that happen subsequently following intraosseous stimulation of PDL.¹ If these alveolar defects are left untreated, it can cause further bone loss and atrophy of the ridges leading to collapse of the arch therefore, restoration of these defects is of utmost importance to limit further destruction of alveolar bone, thereby providing more comprehensive treatment in the near future.² Removable partial denture remains the treatment of choice to replace the missing anterior teeth but the fact that it adds onto the residual alveolar resorption,³ has shifted the focus of treatment modality to other alternatives. One such widely used treatment option includes dental implant but implant placement is usually restricted to patients with completed craniofacial growth.⁴ It must be delayed until the age of 15 years for girls and 18 years for boys⁵ except in severe cases of ectodermal dysplasia.⁴ However, one of the main prerequisites for dental implant placement being adequate bone in the traumatized area⁵ also necessitates the augmentation of alveolar bone using reconstructive procedures aiding in structural and functional restoration.

Various methods using varied bone grafting materials have been employed in literature for reconstructing deficient ridges, namely autogenous grafts, bone substitutes, and membrane techniques. However, by far autogenous grafts have remained the "gold standard" in repairing atrophied alveolar and bone defects.⁶ This is because there is less risk of graft rejection and their excellent osteoinductive properties.

Moreover, experimental studies have shown that when placed as block onlay grafts, intramembranous bone grafts are more advantageous as they show better volume steadiness and

¹⁻³Department of Pediatric and Preventive Dentistry, AB Shetty Memorial Institute of Dental Sciences, Deralakatte, Mangaluru, Karnataka, India

⁴Department of Conservative Dentistry and Endodontics, AB Shetty Memorial Institute of Dental Sciences, Deralakatte, Mangaluru, Karnataka, India

Corresponding Author: Amitha M Hegde, Department of Pediatric and Preventive Dentistry, AB Shetty Memorial Institute of Dental Sciences, Deralakatte, Mangaluru, Karnataka, India, Phone: +91 9844083245, e-mail: amipedo9@gmail.com

How to cite this article: Bhandary M, Hegde AM, Shetty R, *et al.* Augmentation of Narrow Anterior Alveolar Ridge Using Autogenous Block Onlay Graft in a Pediatric Patient: A Case Report. *Int J Clin Pediatr Dent* 2021;14(2):311-314.

Source of support: Nil

Conflict of interest: None

also cause less postoperative resorption when compared with endochondral bone obtained from the iliac crest.^{6,7} This article presents a case report showing block onlay grafts extracted from mandibular symphysis used for augmenting the alveolar ridge to reconstruct the alveolar anatomy and improve esthetics as well as facilitate adequate bone density with superior bone quality for implant prosthesis in the future.

CASE DESCRIPTION

A 12-year-old boy reported to the Department of Pediatric and Preventive Dentistry, AB Shetty Memorial Institute of Dental Sciences with the chief complaint of missing teeth and depression in the front teeth area during a fall from a bicycle 2 years ago and wanted an esthetic restoration for the same. Clinical examination

revealed missing 11 and 12 associated with horizontal alveolar atrophy causing a wide depression on the side of the missing teeth (Fig. 1), confirmed radiographically (Ortho Pantomogram) (Fig. 2). On bone mapping, the width of the bone was only 4 mm which indicates severe bone resorption following trauma. Considering the huge amount of resorption undergone due to trauma; we decided to augment the ridge horizontally to restore alveolar anatomy after discussing with patient and his parents so as to provide a comprehensive treatment in the near future.

Surgical Technique

The surgical procedure was performed under local anesthesia (2% lignocaine hydrochloride with epinephrine 1:200,000) as an outpatient procedure. At the recipient site, horizontal incision was placed at the mucogingival junction extending from 13 to 21 and a full-thickness mucoperiosteal flap was elevated to unveil the size of the defect. The bone surfaces were set free from the residual periosteal and muscle fibers (Fig. 3). The width of the alveolar bone in bucco-palatal direction was knife-edged and height was noted to be 11 mm.

The donor site was exposed after outlining the length of bone loss at the recipient site. The vestibular incision was placed 1 cm beyond the mucogingival junction extending to each distal region of the canines, the vertical relieving incision was placed anterior and above the mental foramen, between canine and premolar then full-thickness mucoperiosteal flap was raised toward the base of mandible (Fig. 4). Next, the dimensions of the grafts to be extracted

were decided according to the defect size using a sterile paper template. Templates were placed at the chin area, 5 mm beneath.

The root tips of mandibular anterior teeth as seen on radiographs. Using a round bur outline of the graft were plotted by placing osteotomy marks. Next, the template was removed and with the help of a fissurotomy bur, these osteotomy marks were joined using a surgical handpiece with copious saline irrigation. Lastly, a periosteal elevator and flat bone chisel were employed to disengage the graft from surrounding bone and harvest bone blocks. Before adopting the autogenous graft, the recipient site underlying bone was prepared by decortication and perforation to speed up the revascularization and improve graft survival.

Block graft was then stabilized onto the recipient site using a titanium screw of 1 mm diameter and 6 mm length. On the recipient site, a pilot hole was drilled passing through the graft. This was mainly done to enlarge the site and allow the placement of titanium fixation screw without resistance (Fig. 5). After fixation of the block graft, platelet-rich fibrin membrane prepared by using centrifuging machine (Fig. 6) and hydroxyapatite bone grafting material was placed around the autogenous bone graft to fill up the remaining gaps.

A collagen membrane was used to hold the graft material in place for guided bone regeneration. A mucoperiosteal flap was relieved at its base to mobilize the flap as well as facilitate coverage of bone graft without any pressure. Interrupted sutures were placed and periopack was given. The patient was put on analgesics, antibiotics, and antimicrobial mouth rinse for 1 week

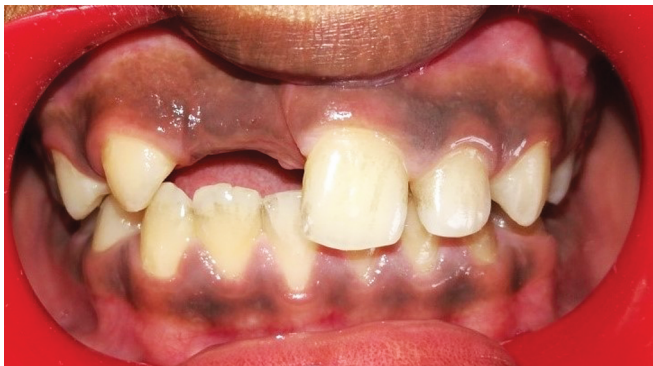

Fig. 1: Preoperative intraoral view showing horizontal alveolar atrophy

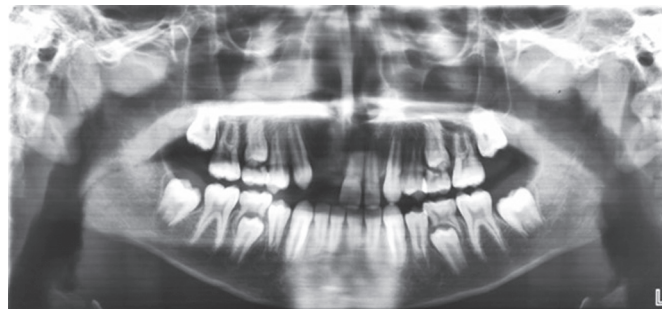


Fig. 2: Preoperative orthopantomogram

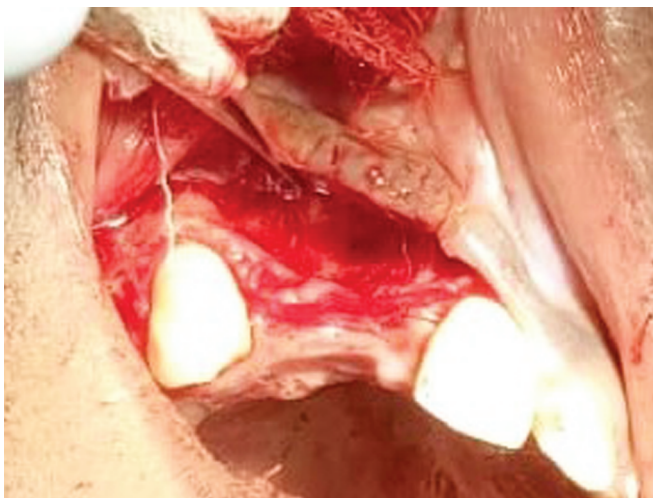


Fig. 3: Mucoperiosteal flap raised to unveil the bone at the recipient site

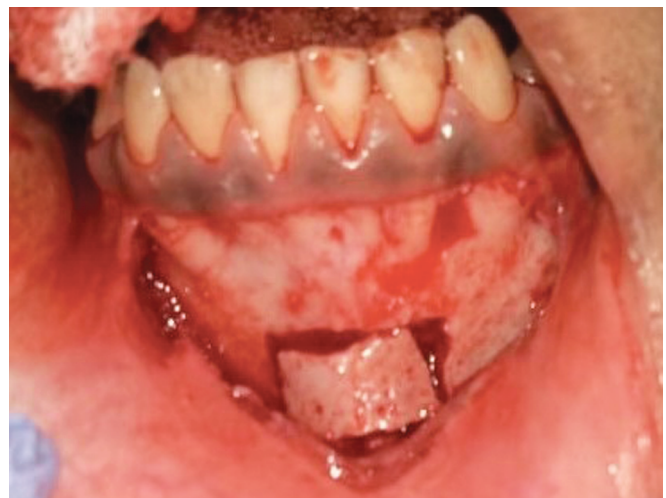

Fig. 4: Removal of block graft from mandibular symphysis

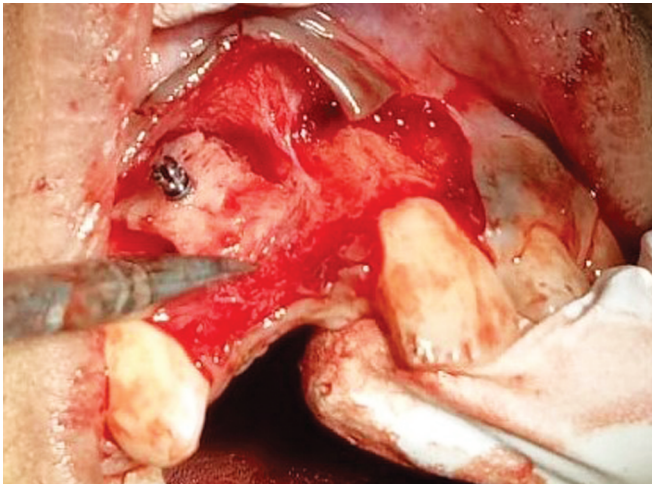


Fig. 5: Block graft stabilized at the recipient site using titanium screws




Fig. 6: Platelet-rich fibrin membrane

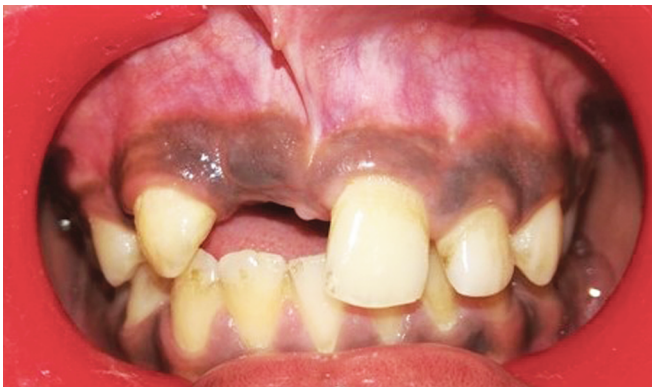

Fig. 7: Postoperative intraoral view

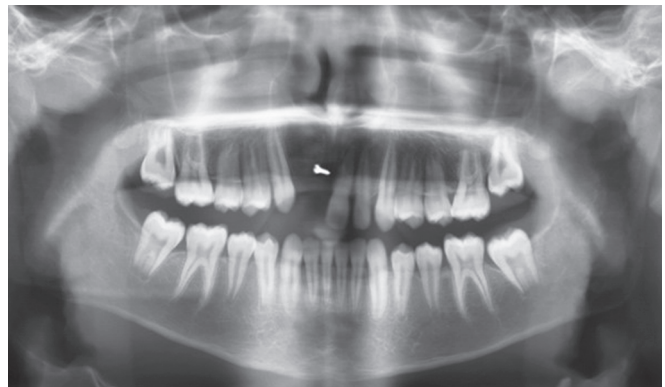

Fig. 8: Postoperative orthopantomogram

and recalled after 1 week for suture removal. Groper's appliance was delivered to temporarily restore esthetics and functions by replacing missing 11 and 12.

Clinical examination after 8 months revealed uneventful healing and repair of the bone defect by augmenting the alveolar ridge, thereby increasing the bucco-palatal dimension (Fig. 7). Radiological (OPG) examination showed integration of graft at the recipient site with minimal graft resorption (Fig. 8) indicating new bone formation, thereby leading to an increase in the bone density and restoring alveolar anatomy.

DISCUSSION

Loss of incisors and canines often tends to cause considerable loss of alveolar bone, chiefly in sagittal dimensions. Therefore, it is imperative to augment both hard and soft tissues to attain a functional restoration. Initial clinical investigation revealed that bone grafts yield a viable alternative for the reestablishment of alveolar defects before dental implant placement.⁸ In-depth clinical and radiological examination is required to rule out the extent of bone loss first, and then strategize a suitable bone augmentation procedure. Several bone grafting techniques are accessible for reconstructing the deficiencies of alveolar ridges, namely autografts, allografts, and xenografts. Autogenous bone grafts are advocated in bone augmentation procedures because of their osteogenic and osteoinductive potential.⁹ Autologous grafting techniques such as compressed particulate cancellous bone and

marrow, corticocancellous blocks, and cortical grafts have been used successfully to restore alveolar defects.⁹ Mandibular grafts are intramembranous in source exhibit increased revascularization and healing than endochondral bone grafts.⁹ Since they are cortical bone in nature, they show little resorption and excellent incorporation on the recipient site.⁶ Intraoral grafts require less surgical and analgesia time since the donor as well as the recipient site are from the same operating field, thereby offering reduced morbidity in graft extraction when compared with extraoral donor sites. Block graft is associated with minimal resorption and requires the usage of an overlying membrane only when the sizes of the graft are inadequate. The outcome of mandibular block grafts recognized in the literature is advantageous and appreciable regardless of certain restrictions like the patient's postoperative temporary neurosensory and functional disturbances.⁹ Block graft is extracted from different anatomical regions such as mandibular symphysis, body, and ramus, therefore, resulting in altered graft morphology and volume.⁹ Hence, thorough anatomical and clinical evaluation is required for the selection of site, to get the superlative volume and form of bone that have a close similarity with the defect morphology. Advantages of mandibular symphysis over other grafts include easy access, availability of greater quantities of bone above other intraoral sites, low morbidity, minimal discomfort, and no cutaneous scar. They can hence be proficiently utilized for alveolar ridge augmentation to correct the atrophic alveolar defects.

CONCLUSION

Traumatic injuries are unavoidable in pediatric patients and any deviation from the normal appearance due to these injuries can have an adverse effect on their personality. Atrophy of alveolar ridges in a growing patient may lead to structural malformation therefore it is imperative to correct these structural defects to maintain the arch integrity and cause uniform growth. In such cases, bone grafting procedures may be considered as an alternative for augmenting the atrophic alveolar ridges.^{10,11} This procedure can act as an important predictor of success for future surgical phases leading to successful and esthetic results. Bone grafting procedures not only help augment the atrophic alveolar ridge and aid in esthetic and functional restoration of alveolar anatomy, but it also helps establish adequate bone density providing the site with superior bone quality. In the case presented above, bone grafting procedure was shown to successfully augment the narrow anterior alveolar ridge at the trauma site, repairing the bony depression and preparing it for receiving implant prosthesis in future.

CLINICAL SIGNIFICANCE

In a pediatric patient, it is imperative to treat trauma-induced alveolar deformity before growth ceases, as any delay can further worsen the skeletal and dental malformation. Hence, a comprehensive treatment approach should be considered to achieve esthetic as well as functional restoration.

REFERENCES

- Oikarinen KS, Sándor GK, Kainulainen VT, et al. Augmentation of the narrow traumatized anterior alveolar ridge to facilitate dental implant placement. *Dent Traumatol* 2003;19(1):19–29. DOI: 10.1034/j.1600-9657.2003.00125.x.
- Souza FÁ, Bassi AP, ARAnegA AM, et al. Reconstruction of maxillary ridge atrophy caused by dentoalveolar trauma, using autogenous block bone graft harvested from chin: a case report. *J Osseointegrat* 2014;6(2):21–27.
- Ozan O, Orhan K, Aksoy S, et al. The effect of removable partial dentures on alveolar bone resorption: a retrospective study with cone-beam computed tomography. *J Prosthodont: Implant, Esthetic Reconstruct Dentis* 2013;22(1):42–48. DOI: 10.1111/j.1532-849X.2012.00877.x.
- Mishra SK, Chowdhary N, Chowdhary R. Dental implants in growing children. *J Indian Soc Pedodont Prevent Dentis* 2013;31(1):3. DOI: 10.4103/0970-4388.112392.
- Oesterle LJ, Cronin Jr RJ, Ranly DM. Maxillary implants and the growing patient. *Int J Oral Maxillofac Implants* 1993;8(4):377–387.
- Pikos MA. Mandibular block autografts for alveolar ridge augmentation. *Atlas Oral Maxillofac Surg Clin N Am* 2005;13(2):91–107. DOI: 10.1016/j.cxom.2005.05.003.
- Triplett RG, Schow SR. Autologous bone grafts and endosseous implants: complementary techniques. *J Oral Maxillofac Surg* 1996;54(4):486–494. DOI: 10.1016/s0278-2391(96)90126-3.
- Misch CM, Misch CE, Resnik RR, et al. Reconstruction of maxillary alveolar defects with mandibular symphysis grafts for dental implants: a preliminary procedural report. *Int J Oral Maxillofac Implan* 1992;7(3):360–366.
- Harshakumar K, Varghese NM, Ravichandran R, et al. Alveolar ridge augmentation using autogenous block bone grafts harvested from mandibular ramus to facilitate implant placement: a case report. *Int J Scienti Study* 2014;2(1):46–50.
- Chiapasco M, Abati S, Romeo E, et al. Clinical outcome of autogenous bone blocks or guided bone regeneration with e-PTFE membranes for the reconstruction of narrow edentulous ridges. *Clin Oral Implants Res* 1999;10(4):278–288. DOI: 10.1034/j.1600-0501.1999.100404.x.
- Thilander B, Ödman J, Gröteborg K, et al. Osseointegrated implants in adolescents. An alternative in replacing missing teeth? *Eur J Orthod* 1994;16(2):84–95. DOI: 10.1093/ejo/16.2.84.