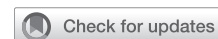

See Article page 557.



## Commentary: Has anyone seen the conductor? Use of phase contrast computed tomography to identify the atrioventricular conduction axis in complex congenital heart lesions

Mohamed F. Algham, MD

The proximity of the conduction system to critical areas of repair is a bane of congenital cardiac surgery. In the normally developed heart, there is good understanding of the location of the conduction system relative to intracardiac landmarks; despite this, heart block remains an important complication. In malformed hearts, variations in the conduction pathway further compound the risk of heart block and add complexity to surgical repair. This is not trivial in neonatal and small patients—transvenous pacing is not an option and placing an epicardial lead system with a generator in such small patients is fraught with wound dehiscence, infection, lead complications, and a lifetime commitment to generator exchanges.<sup>1</sup> The best strategy to avoiding heart block is prevention through sound understanding of the anatomy of the conduction system in congenital lesions.

In this issue of *JTCVS Open*, Wada and colleagues<sup>2</sup> advance our knowledge of the anatomy of the conduction pathway in patients with complex congenital lesions. The authors use phase-contrast computed tomography (PCCT) to identify the conduction pathway in 5 postmortem

From the Department of Surgery, Pediatric Cardiothoracic Surgery, University of Rochester School of Medicine and Dentistry, Rochester, NY.

Disclosures: The author reported no conflicts of interest.

The *Journal* policy requires editors and reviewers to disclose conflicts of interest and to decline handling or reviewing manuscripts for which they may have a conflict of interest. The editors and reviewers of this article have no conflicts of interest.


Received for publication Oct 13, 2021; revisions received Oct 13, 2021; accepted for publication Oct 22, 2021; available ahead of print Nov 11, 2021.

Address for reprints: Mohamed F. Algham, MD, Division of Cardiac Surgery, Department of Surgery, University of Rochester School of Medicine and Dentistry, 601 Elmwood Ave, Box Surg/Cardiac, Rochester, NY 14642 (E-mail: [mohamed\\_algham@urmc.rochester.edu](mailto:mohamed_algham@urmc.rochester.edu)).

*JTCVS Open* 2021;8:561-2  
2666-2736

Copyright © 2021 The Author(s). Published by Elsevier Inc. on behalf of The American Association for Thoracic Surgery. This is an open access article under the CC BY-NC-ND license (<http://creativecommons.org/licenses/by-nc-nd/4.0/>).

<https://doi.org/10.1016/j.xjon.2021.10.047>



Mohamed F. Algham, MD

### CENTRAL MESSAGE

The use of phase contrast computed tomography as a research tool allows for identification of specialized myocardial conduction tissue in complex congenital lesions.

specimens of tricuspid atresia—4 with normally related great vessels and 1 with transposition. The authors present beautiful computer-generated images to demonstrate the variability in location of the atrioventricular conduction axis (AVCA) relative to the position of the aortic and pulmonary valves. However, this variation appears to be a function of the transposition of the great vessels, as the AVCA is relatively constant in its relationship to the central fibrous body and is more intimately related to the right trigone. These findings suggest that, when operating on patients with tricuspid atresia, the right trigone is an ideal landmark to identify the AVCA, and one should be cognizant of variation in its location relative to the semilunar valves.

The authors confirm our current understanding of the AVCA's relationship relative to the central fibrous body; but, they were not able to delineate its course within bulboventricular foramen. This is an important limitation, particularly in tricuspid atresia—our understanding is that it is inferior and posterior to the defect. Other limitations include the small sample size; no control specimens; and localization of the AVCA may have been impacted by edema and contracture of the postmortem specimens. These limitations afford an opportunity for future investigation. Indeed, an important highlight of this report is the ability of PCCT to identify subtle soft-tissue differences to localize specialized myocardial conduction tissue. While its use clinically is not practical due to the high-dose radiation, PCCT is an exciting research tool that allows for in situ

analysis of the conduction system using whole human heart specimens.<sup>3</sup> This will further our understanding of the anatomic relationships between specialized myocardial tissue relative to high-risk areas of surgical repair. It would be interesting to corroborate the current findings using control specimens and to study complex congenital lesions prone to variations in central fibrous body development and complex ventricular septal defects.

I commend the authors on their work and look forward to their future reports.

## References

1. Wilhelm BJ, Thöne M, El-Scheich T, Livert D, Angelico R, Osswald B. Complications and risk assessment of 25 years in pediatric pacing. *Ann Thorac Surg.* 2015;100:147-53.
2. Wada Y, Matsuhisa H, Oshima Y, Yoshimura N. Identification of the atrioventricular conduction axis and its positional relationship with anatomical landmarks of a heart with tricuspid atresia. *J Thorac Cardiovasc Surg Open.* 2021;8:557-60.
3. Shinohara G, Morita K, Hoshino M, Ko Y, Tsukube T, Kaneko Y, et al. Three dimensional visualization of human cardiac conduction tissue in whole heart specimens by high-resolution phase-contrast CT imaging using synchrotron radiation. *World J Pediatr Congenit Heart Surg.* 2016;7:700-5.