



Since January 2020 Elsevier has created a COVID-19 resource centre with free information in English and Mandarin on the novel coronavirus COVID-19. The COVID-19 resource centre is hosted on Elsevier Connect, the company's public news and information website.

Elsevier hereby grants permission to make all its COVID-19-related research that is available on the COVID-19 resource centre - including this research content - immediately available in PubMed Central and other publicly funded repositories, such as the WHO COVID database with rights for unrestricted research re-use and analyses in any form or by any means with acknowledgement of the original source. These permissions are granted for free by Elsevier for as long as the COVID-19 resource centre remains active.



COVID-19 and thrombotic microangiopathies

Nishant R. Tiwari^{a,*}, Sanat Phatak^b, Vivek R. Sharma^c, Sanjay K. Agarwal^d

^a Department of Internal Medicine, Byramjee Jeejeebhoy Government Medical College, Pune, India

^b Department of Medicine and Diabetes Unit, King Edward Memorial Hospital and Research Center, Pune, India

^c Division of Hematology and Oncology, University of Louisville, Louisville, KY, United States

^d Department of Nephrology, All India Institute of Medical Sciences, New Delhi, India

ARTICLE INFO

Keywords:

COVID-19
SARS-CoV-2
Thrombosis
Thrombotic microangiopathy
C5 inhibition
Vascular injury

ABSTRACT

Severe COVID-19 can manifest as multiorgan dysfunction with pulmonary involvement being the most common and prominent. As more reports emerge in the literature, it appears that an exaggerated immune response in the form of unfettered complement activation and a cytokine storm may be a key driver of the widespread organ injury seen in this disease. In addition, these patients are also known to be hypercoagulable with a high rate of thrombosis and a higher-than-expected failure rate of anticoagulation. While macrovascular thrombosis is common in these individuals, the frequent finding of extensive microvascular thromboses in several series and case reports, raises the possibility of thrombotic microangiopathy (TMA) as being a contributing factor in the thrombotic and multi-organ complications of the disease. If this is correct, rapidly identifying a TMA and treating the underlying pathophysiology may allow for better outcomes in these critically ill patients. To further explore this, we reviewed the published literature on COVID-19, looking for reports describing TMA-like presentations. We summarize our findings here along with a discussion about presentation, pathophysiology, and a suggested treatment algorithm.

1. Introduction

The novel coronavirus disease – 2019 (COVID-19) pandemic has grown exponentially since December 2019. With more than 100 million cases around the globe and more than 2 million fatalities at the time of writing, it has emerged as a public health emergency [1]. The severe acute respiratory syndrome-corona virus-2 (SARS-CoV-2), a virus belonging to the *coronaviridae* family (A group of positive-sense, single-stranded RNA viruses), is responsible for COVID-19 related illnesses [2]. While the disease was initially thought to be limited to the respiratory tract, soon it was realized to be a multisystem disease, especially when severe - causing coagulopathy, renal failure, hepatic dysfunction, arrhythmias, and heart failure [3]. Severe disease is more common in the elderly and in those with comorbidities like diabetes mellitus (DM), hypertension, chronic obstructive pulmonary disease (COPD), coronary artery disease and chronic kidney disease [4].

Although the pathophysiology may not yet be entirely understood, it appears that glycoprotein spikes on the surface of SARS-CoV-2 engage angiotensin-converting enzyme-2 (ACE-2) receptors on human cells,

including the respiratory epithelium, macrophages, and cardiac myocytes [5]. Receptor engagement leads to virus entry, replication and cell lysis, initiating an inflammatory process with the release of pro-inflammatory cytokines, including interleukins (IL-6, IL-1, IL-7, IL-8, etc.), various glycoproteins (G-CSF, GM-CSF, FGF, VEGF, etc.) and acute phase reactants (procalcitonin, C-Reactive Protein, fibrinogen, etc.) In some patients, a state of ‘systemic’ inflammation with an exuberant cytokine storm ensues, triggering the coagulopathy associated with COVID-19 [5]. In severe cases, endothelial injury and the presence of antiphospholipid antibodies further compound the situation– developing into a state of widespread thromboses [6,7].

Recent publications have addressed possible mechanisms for thromboses in COVID-19 patients and suggested interventions beyond standard anticoagulation such as activated protein C (APC), plasminogen activator inhibitor – 1 (PAI-1) antagonists, tissue plasminogen activator (t-PA), and other anti-thrombotic therapies [8,9]. While venous and arterial thrombotic events have been reported widely in COVID-19, microvascular thromboses have mostly been described in autopsy case series on histopathologic exam of affected tissues. Many of

* Corresponding author at: Department of Internal Medicine, Byramjee Jeejeebhoy Government Medical College, Pune Zip Code – 411001, India.

E-mail address: dr.nishant.tiwari.1996@gmail.com (N.R. Tiwari).

¹ Permanent Address of the corresponding author: Behind Pramila Lawns, Mumbai Agra Road, Pimpalgaon Baswant, District – Nashik, State – Maharashtra, Country – India, Zip Code – 422209.

<https://doi.org/10.1016/j.thromres.2021.04.012>

Received 27 February 2021; Received in revised form 4 April 2021; Accepted 7 April 2021

Available online 20 April 2021

0049-3848/© 2021 Elsevier Ltd. All rights reserved.

these patients do poorly despite therapeutic anticoagulation and a more nuanced approach is therefore necessary- to consider and address possible additional pathophysiologic processes that may be contributing to microvascular thromboses, such as complement dysregulation. We reviewed the current published literature on thrombotic microangiopathies (TMAs) in patients with COVID-19 by performing searches through PubMed/MEDLINE and Google Scholar databases. We employed the search phrases – “COVID-19 AND Microvascular Thrombosis”, “COVID-19 AND Thrombotic Microangiopathy”, “COVID-19 AND Thrombotic Thrombocytopenic Purpura”, “COVID-19 Autopsy Reports”, “COVID-19 AND Thrombosis”, “COVID-19 AND Complement System”, “COVID-19 AND C5 inhibition”, “COVID-19 AND atypical HUS”, “COVID-19 AND Acute Kidney Injury.” While writing this narrative review, we included references which met either the criteria for the diagnosis of TMA, had laboratory features suggestive of a presence of a TMA or had autopsy reports suggestive of thrombi in the microvasculature. We present our findings here along with a discussion of the presentation, pathophysiology, and a potential therapeutic algorithm for such patients.

2. Infections and TMA

Thrombotic microangiopathies (TMA) are a group of disorders characterized by the presence of thrombocytopenia, microangiopathic hemolytic anemia (MAHA), and end-organ capillary thromboses [10]. While the literature widely describes hemolytic uremic syndrome (HUS) as a complication of some bacterial infections, reports of virus-associated TMAs are also available [11]. The mechanisms in TMAs associated with viral infections remain unclear: direct endothelial injury, acquired inhibitors to ADAMTS13 (a disintegrin and metalloproteinase with a thrombospondin type 1 motif, member 13) protein, and the presence of lupus anticoagulants appear to be a few probable mechanisms [11].

Capillary thromboses in organs like the lungs, heart, and kidneys have been reported in autopsy series/studies of COVID-19 patients [12,13]. Presence of platelet-fibrin thrombi in these organs and signs of end-organ damage lend support to the hypothesis that COVID-19 can be associated with TMA and warrant a thorough evaluation of possible pathomechanisms and novel therapeutic options in COVID-19 related illnesses.

3. COVID-19 and thrombosis

Severe infections are known to cause hematological derangements such as disseminated intravascular coagulation (DIC) or sepsis-induced coagulopathy (SIC) due to systemic inflammation [14]. Initial data from China described deranged coagulation parameters in COVID-19 patients with elevated D-dimer and fibrinogen being the most common. A significantly elevated D-dimer (> six times the upper limit of normal) was associated with disease severity (mechanical ventilator requirement, mortality) [3,4]. There are reports of venous thromboembolism (VTE) in COVID-19 patients across many prospective and retrospective studies. Notably, many patients developed VTE despite receiving prophylactic dose anticoagulation implying a severe hypercoagulable state [15,16]. Screening for deep vein thrombosis (DVT) in critically ill COVID-19 patients showed a high prevalence of 79% [17].

4. Potential mechanisms of TMAs in COVID-19

Until more data on TMA in COVID-19 are available, potential mechanisms are extrapolated from other TMAs reported in the context of preceding infections: catastrophic antiphospholipid syndrome (CAPS), TMA secondary to infections, and complement mediated TMA [10]. Pathogenic mechanisms akin to all these have been demonstrated in critically ill COVID-19 patients. Cases of thrombotic thrombocytopenic purpura (TTP) like syndrome due to auto-antibodies to ADAMTS-

13 have been sporadically reported in COVID-19 patients but appear to be very uncommon compared to the other forms of TMA.

Reminiscent of CAPS, studies have shown the presence of anti-phospholipid antibodies (especially lupus anticoagulants) to be associated with prolonged activated partial thromboplastin time (aPTT) in COVID-19, especially in critically ill patients [18–20]. The antibodies are associated with serious thrombotic events [6,7]. In other infections, the appearance of anti-phospholipid antibodies increase risk for CAPS [21]. It will be interesting to study clinical implications of a de-novo appearance of antiphospholipid antibodies during the course of the COVID-19 illness.

Uncontrolled complement activation is the cornerstone of the pathogenesis of infection associated TMA and complement mediated TMA [22,23]. Mutations of the regulators of the complement pathway are known to cause familial and sporadic forms of complement mediated TMA. These mutations include but are not limited to those in complement factor H (CFH), membrane cofactor protein (MCP) and complement factor I (CFI). Gain-of-function mutations in the genes encoding two components of the alternative pathway C3 convertase, C3 and complement factor B have also been reported. In the setting of triggers and conditions associated with enhanced complement activation (Infection, pregnancy), these deficiencies are likely to get unmasked and manifest as complement mediated TMA [22].

The alternative complement pathway has been shown to be a contributing factor in the pathogenesis of COVID-19 related illnesses and may predispose to COVID-19 associated TMAs [24]. Microvascular thrombosis in skin and lungs associated with deposition of membrane attack complex (MAC, C5b-9), C4d, and mannan-binding lectin serine peptidase 2 (MASP-2) in the microvasculature on autopsy ($n = 5$), supports complement-mediated endothelial damage as being one of the potential mechanisms in the pathogenesis of COVID-19 related illnesses [24]. Review of classic as well as recent literature on the *influenza virus* and the viruses of the *coronaviridae* family also suggests a strong association between complement activation and severity of illness, advocating inhibition of terminal complement inhibition as a potential therapeutic option [25].

Finally, Bilgin et al., in their recent publication, coined a term called ‘Inflammatory Thrombosis with Immune Endothelitis (ITIE)’ for COVID-19 related hyperinflammatory pro-thrombotic state [26]. Endothelitis disrupts the integrity of the vascular endothelium, which leads to release of substances like VEGF, PDGF, among others [27,28]. The release of these substances in turn causes activation of the coagulation cascade at the site, further adding to the above possible mechanisms of thrombosis. The authors specifically coined this new terminology to highlight the fact that anti-cytokine therapies are not helpful in such patients and that other targets, as suggested by the name, should be sought.

Fig. 1 demonstrates the proposed pathways in the development of TMA in COVID-19 patients.

5. Evidence for TMAs in COVID-19

Marked elevation of LDH and D-dimers and presence of thrombi in the microcirculation despite being on anticoagulation suggests an unmet need for further exploration of the causes of systemic disease in SARS-CoV-2 infected patients, and to think of TMA as a possible and potentially treatable cause. A prospective observational study demonstrated a significantly elevated lactate dehydrogenase (LDH) in COVID-19 patients with acute kidney injury (AKI) as compared to those with normal renal function ($p < 0.0001$). While most patients in this study had features suggestive of acute tubular necrosis (ATN) secondary to ischemia or rhabdomyolysis, etiology of AKI was uncertain in about 13% of patients. Interestingly, they had a rapid rise in serum creatinine without any signs of hemodynamic instability; they also had urinalysis suggestive of acute tubular injury (ATI) in 11 patients and overt proteinuria indicative of glomerular injury in 3 patients. Whether this was due to infection of renal tubular/glomerular epithelial cells by SARS-CoV-2 or

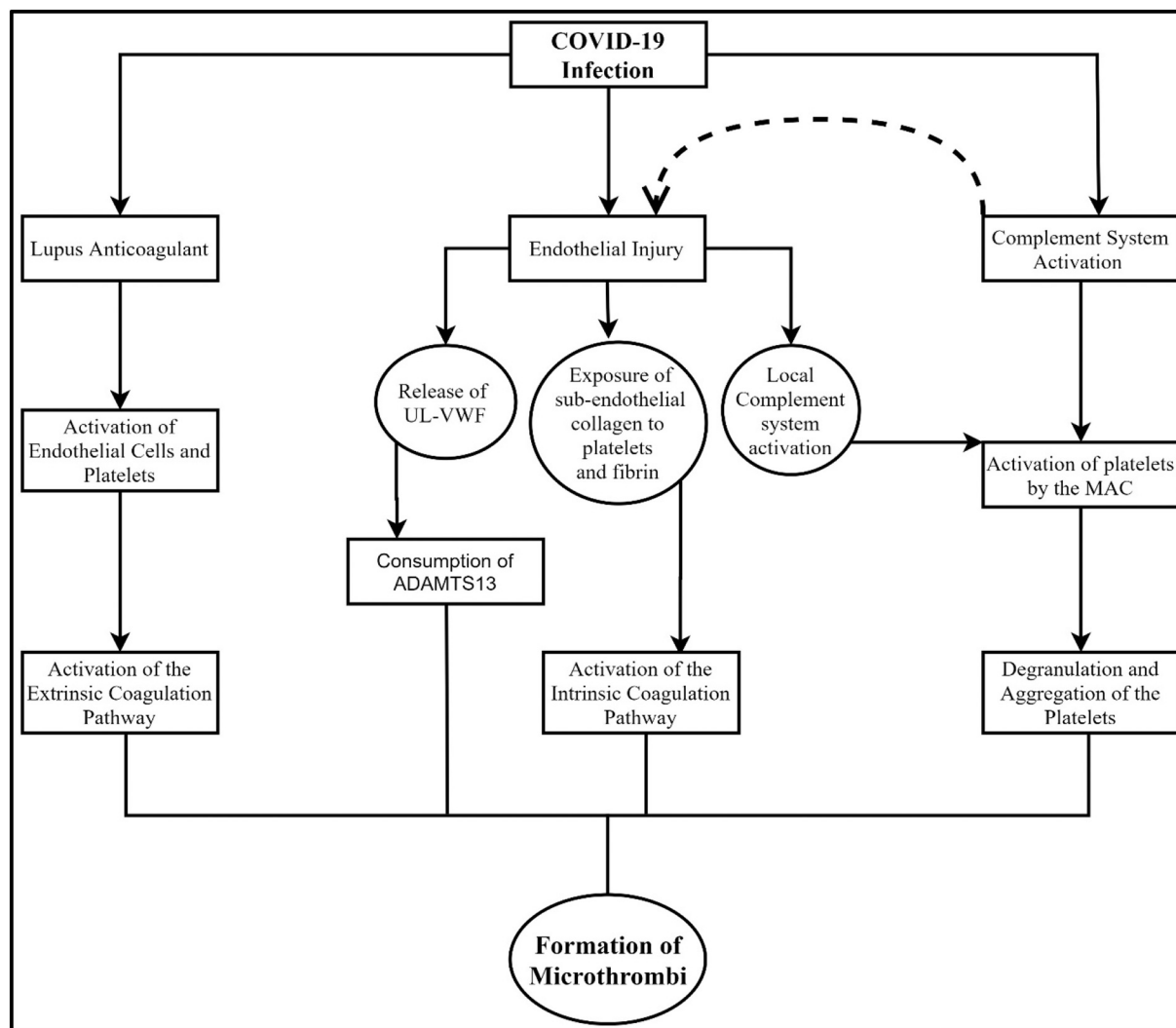


Fig. 1. Potential mechanisms of the development of TMA in COVID-19 patients (MAC – Membrane attack complex, UL-VWF – Ultra large von-Willebrand factor).

by some other mechanism remained unclear [29]. One of the possible mechanisms is microvascular thrombosis due to TMA, evident by elevated D-dimer and LDH; however, the study did not look at biopsies of these patients, making this conclusion speculative. An autopsy study from China looked at the kidney histopathology in 26 patients with COVID-19 related illnesses that succumbed to the disease. The most common findings in this series on light microscopy were proximal tubular necrosis and erythrocyte aggregates obstructing the lumen of the capillaries. Although this study did not record TMA in any of its subjects, there were reports of fibrin thrombi in glomeruli of at least three patients. All three of these patients had anemia, an elevated D-dimer (at least > four times of standard upper limit), and thrombocytopenia. Of note, in 20/26 patients where the D-dimer and platelet counts were reported, 14/20 (70%) patients had thrombocytopenia, and 20/20 (100%) of the patients had elevated D-dimers [30].

Most of the literature published until the writing of this paper reports microvascular thrombosis in the lungs as a predominant syndrome of TMA in COVID-19 patients. An autopsy series in patients dying from COVID-19 related illness demonstrated the presence of microthrombi in pulmonary circulation [31]. These findings of TMA -evident by widespread capillary thrombosis- were corroborated in another autopsy series in a different ethnic group (African-American patients) [32]. Pulmonary microthromboses seem to be relatively specific to COVID-19 and widespread: it was nine times as prevalent in COVID-19 patients

compared to H1N1 patients ($P < 0.001$) [13]. An autopsy study from Italy showed platelet-fibrin thrombi to be present in the pulmonary capillaries in nearly all patients (87% of the 38 cases) [12]. That said, it is not clear from the published reports if all patients with organ microthrombosis had clinically overt TMA. Only one of seven autopsies demonstrating platelet rich-fibrin thrombi in organ microvasculature mentioned typical features suggestive of TMA (fragmented RBCs, mesangiolytic). This analysis however was limited by a lack of key laboratory parameters like the platelet count, renal function tests, and ADAMTS13 levels [33]. Similarly, in another study only eight of 21 demonstrated findings suggestive of TMA (Three patients – systemic TMA, five patients – Pulmonary TMA) [34]. A collated comparison of patients who had TMA like features with those who had microthrombosis alone may shed further light on how to distinguish them clinically.

The pattern that appears to be emerging from reports so far seems to point to a complement mediated disorder as the predominant form of TMA associated with COVID-19 infection. In a case series of ten COVID-19 patients who underwent kidney biopsy, two patients had light and electron microscopic features suggestive of a TMA. One of them had already been described in the literature [35], the other patient was treated with gemcitabine and radiation for cervical squamous cell cancer [36]. There is an established association between gemcitabine and TMA [37]; however, given the appearance of TMA after SARS-CoV-2

infection – COVID-19 could have acted as a second hit unmasking the underlying complement defect. A single case report of biopsy-proven renal TMA described a patient with a rapidly deteriorating renal function having thrombocytopenia and MAHA. This patient also had a low plasma factor H complement antigen, an elevated C3b, and C5b-9 components of the complement, suggesting activation of the alternate pathway of the complement system [35].

While a TTP like TMA has been described in COVID-19, the reports are few and far in between. Albiol et al. described acquired TTP in a patient with COVID-19 infection due to inhibitor to the ADAMTS13 [38]. RNA virus infections have previously been associated with acquired ADAMTS13 deficiency [11]. Another case report of a COVID-19 patient had acquired inhibitor to ADAMTS13 in the absence of any other risk factors for the development of acquired-TTP – implicating the concurrent SARS-CoV-2 infection as the most likely cause [39]. A third case report of TTP associated with COVID-19 was also along similar lines in that the patient suffered many complications, including a stroke, a major bleeding episode, and widespread microvascular thromboses and had an acquired inhibitor to ADAMTS13 [40]. The relative paucity of TTP like TMA in COVID-19 patients suggests that it is an uncommon phenomenon that needs to be considered and addressed if present but is unlikely to be encountered in the vast majority of patients. While more evidence-based data is desired on the incidence of TTP in COVID-19 patients, the scarcity of published reports makes it difficult to extrapolate these findings into the more ‘real-world’ scenario. Current available recommendations are consensus guidelines based on the opinion of experts in the field upon interpretation of the available literature.

TMA in COVID-19 could also occur from direct viral toxicity to vascular endothelium. A case series of three patients with SARS-CoV-2 infection demonstrated infection of capillary endothelium by the virus and histopathological changes suggestive of endothelitis in organs such as the intestines, lungs, and the kidneys. Remarkably, their findings also suggested a direct role of the SARS-CoV-2 virus in causing vasculopathy in the microcirculation [41]. A case series that studied the neuroimaging findings of the patients with severe COVID-19 related illnesses found changes consistent with a TMA in the cerebral cortex on CT/MRI [42]. Of course, the mechanism of the TMA in this series could not be determined based on the reported data.

The data presented above, although far from conclusive, does support the hypothesis of the presence of TMA in COVID-19 associated illnesses. Whether this is in fact predominantly due to complement-mediated damage or some other mechanism remains to be elucidated.

Typically, the constellation of anemia, thrombocytopenia, and schistocytes on the peripheral blood smear is enough to establish the diagnosis of TMA. In general, TMAs are a syndrome of capillary and arteriolar thrombosis that can be attributable to a variety of causes. There are at least nine categories of TMA described in the literature; however, the common ones, outside of DIC, are typically one of these three – TTP, Shiga toxin mediated TMA or complement mediated TMA. The definitive diagnosis of any of the above requires testing that may not always be readily available. These include, ADAMTS13 activity and inhibitor assay for TTP, next generation DNA sequencing and ex-vivo deposition of C5b-9 by patient’s serum on cultured endothelial cells for complement mediated TMA [43]. Failure of early institution of treatment can translate into a higher mortality and possible end-organ damage [10]. Kidney biopsy is not commonly done in suspected TMA patients as it is invasive, and it does not differentiate between the syndromes of TMA in the acute setting.

The challenge lies in identifying the etiology and instituting the appropriate treatment [10]. Based on the published studies/registries data, scoring systems like ‘PLASMIC score,’ ‘French score,’ and ‘Bentley score’ predict severe ADAMTS13 deficiency (TTP) with high sensitivities and specificities, which help in early treatment with therapeutic plasma exchange (TPE) [44]. Based on the above scoring systems, in patients where the probability of TTP is low, depending on the clinical features, alternative differentials like Shiga toxin mediated TMA, complement

mediated TMA, etc. can be considered, and cause-specific treatment can be given. Based on the review of limited literature on COVID-19 associated TMAs and standard practice in the treatment of TMAs, we suggest an algorithm for the management of TMAs in COVID-19 patients (Fig. 2). We acknowledge that the data is limited, and this algorithm may need to be modified as the evidence emerges; at the same time, the algorithm might be helpful to the clinicians in making complex treatment decisions.

6. Therapeutic options for TMA in COVID-19

The treatment of TMAs, in general, hinges upon four modalities – plasma exchange, immunosuppression, monoclonal antibodies, and whenever possible – management of the underlying cause [10]. Till the beginning of the last decade, plasma exchange, in addition to immunosuppression, was considered as the only option for the treatment of TMAs. However, with the arrival of effective therapy in the form of terminal complement inhibitors for complement-mediated TMA and Caplacizumab for TTP, making a specific diagnosis of the type of TMA has become important [46,47]. Lack of specific treatment for COVID-19 infection, higher mortality in TMAs associated with COVID-19 and availability of effective therapies for the TMAs, make a strong case for exploring the potential treatment options in this specific group of patients. While the anti-coagulants like LMWH and rivaroxaban form cornerstone for treatment of and prophylaxis for venous thromboembolism, their efficacy in the management or prevention of TMAs is debatable [48,49]. At this point, the evidence supports the use of anti-coagulants in critically ill COVID-19 patients for prevention of large-vessel thrombosis, however, their role in preventing TMAs is unclear and unelucidated [50]. To date, limited evidence in the form of case reports/series is available for the treatment of TMAs associated with COVID-19. Following are the different treatment options in such patients:

A) Corticosteroids

Traditionally, corticosteroids were used in combination with plasma exchange for the treatment of a spectrum of disorders, then called – TTP-HUS [51]. Currently, they are the agents of choice to achieve rapid immunosuppression in patients with TTP and some cases of acquired aHUS [22,51]. Mechanisms of their action in patients with TMA are as follows,

1. Suppression of acquired inhibitors to the ADAMTS13 (acquired TTP) and anti-factor-H antibody (acquired aHUS) [52].
2. Limitation of the endothelial inflammation, by attenuating the production of cytokines and decreasing the expression of adhesion molecules [53].
3. Increasing the activity of endothelium-derived nitric oxide synthase (eNOS) and thereby enhancing the synthesis and release of nitric oxide (NO). Platelet aggregation and leukocyte adhesion are inhibited by NO, blunting a pathway for thrombosis and inflammation [54].
4. Inhibition of the activation and amplification of the alternate complement pathway [55].

More than the cytopathic effects of the SARS-CoV-2, a substantial part of the pathology of COVID-19 related illnesses results from the overreaction of the immune system to the virus. It is evident by an increase in levels of cytokines (IL-1, IL-6), inflammatory markers (Procalcitonin, C-reactive protein), and acute phase reactants (Ferritin, fibrinogen). Their increased levels are associated with a poorer prognosis in COVID-19 patients [56,57].

Preliminary report from a large, multi-centric, randomized controlled trial (RCT) compared the effect of adding dexamethasone (6 mg/day) to standard of care on 28-day mortality in patients hospitalized

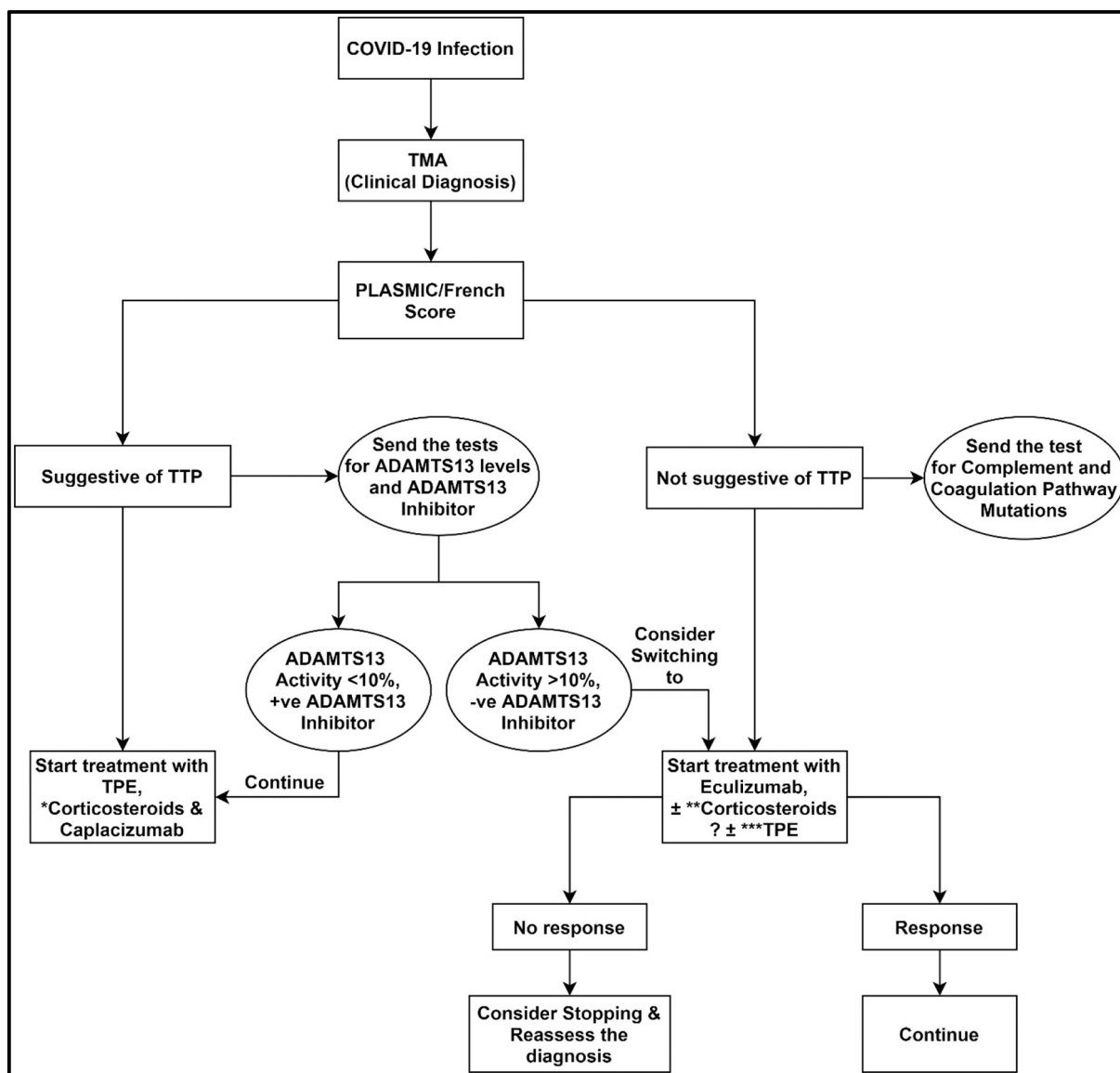


Fig. 2. Suggested algorithm for the management of TMAs in COVID-19 patients.

* It is better to avoid the use of rituximab upfront together with corticosteroids to avoid superadded immunosuppression.

** Corticosteroids have proven efficacy in decreasing the mortality in selected groups of COVID-19 patients [45]. So, might be helpful in the setting of TMA as well.

*** TPE is currently being tested in multiple studies for the treatment of severe COVID-19 related illnesses. It also has some efficacy in complement mediated TMA. (TPE – Therapeutic plasma exchange, TTP – Thrombotic thrombocytopenic purpura).

with COVID-19 related illness. The dexamethasone addition group had significantly lowered 28-day mortality in patients requiring respiratory support [45]. Another small (n = 84), partially randomized, open-label trial showed that IV Methylprednisolone significantly lowered the risk of the need for non-invasive ventilation, intensive care unit (ICU) admission, and death [58].

All three of the acquired-TTP cases in COVID-19 reported in the literature were treated with the standard dose of methylprednisolone (1 mg/kg/day) in addition to plasma exchange [38–40]. A small, multi-center, open-label trial found higher dose methylprednisolone (10 mg/kg/day) to be superior to the standard dose in terms of achieving complete remission in acute phase of idiopathic TTP [59]. However, the administration of a higher dose is debatable, given the absence of robust evidence. Some experts recommend the administration of rituximab in addition to the standard dose of methylprednisolone if additional immunosuppression is warranted [60].

All things considered, corticosteroids appear to have a promising role

in COVID-19 related illnesses and especially so if there is severe disease or an association with a syndrome of TMA.

B) Terminal complement inhibitors and other anti-complement therapies

The association between the over-activated complement system and a variety of viral infections is well established in animal models. Widespread deposition of the MAC (C5b-9) was seen on the pneumocytes and bronchiolar epithelial cells in autopsy in a MERS-CoV infected patient, suggesting the role of the complement system. The hypothesis was also supported by the elevated serum levels of C5a, indicating systemic terminal complement pathway activation [61]. Elevated serum levels of C5a in patients with severe H1N1 infection also corroborates the role of an overactive complement system in its pathogenesis [62]. Preclinical studies of anti-complement molecules administered to animals infected with MERS-CoV, H1N1, H5N1, etc. resulting in less severe

clinicopathological manifestations, further adds to the existing evidence [63–65]. A mouse model, with C3 protein gene knockout (–/–), when infected with SARS-CoV, exhibited less severe symptoms and histological changes in the lungs [66]. A C3 gene knockout study, in mice infected with H1N1 or H5N1 influenza A virus, on the other hand, provided contradictory results, in that, the mice with C3 (–/–) had a more severe and fatal disease than the wild-type mice [64]. These studies highlight the complexities at which the complement system operates in viral infections.

Eculizumab, a human monoclonal antibody binding to the complement protein C5, has proven to be a path-breaking discovery in the treatment of paroxysmal nocturnal hemoglobinuria and aHUS [47]. It inhibits the terminal complement pathway but preserves the functions of early components like C3a/C3b. Because of this property, the functions such as opsonization of viruses and enhancement of B and T-cell immune responses against viruses are preserved. At the same time, the detrimental effects of complement system due to its overactivation secondary to viral infection are blunted [67].

A small case series ($n = 4$) from Italy, in which the patients were given eculizumab for severe COVID-19 associated acute respiratory distress syndrome (ARDS) demonstrated marked clinical improvement with a substantial decrease in the mean C-reactive protein (CRP) levels (from 14.6 mg/dL to 3.5 mg/dL) [68]. Multiple ongoing trials are evaluating the effectiveness and safety of eculizumab in patients with severe COVID-19 infection (NCT04346797, NCT04355494, NCT04288713) [69]. A case report of a 71-year-old male having severe COVID-19 related illness treated with a complement C3 inhibitor AMY-101 showed a dramatic response in terms of both – improved clinical status and normalization of the laboratory parameters such as LDH and CRP [70]. There is an ongoing phase II RCT assessing the efficacy and safety of AMY-101 in seriously ill COVID-19 patients (NCT04395456) [69].

Anti-complement therapy seems to have a promising role not only in TMA associated with COVID-19, but also in other severe COVID-19 infection-related complications like ARDS and cytokine storm. However, caution should be exercised while administering C3 inhibitors, as they almost completely paralyze the complement system and may result in more severe disease, as shown by a few animal studies on other viruses [64]. Results of ongoing randomized controlled trials with these drugs will better inform us on how best to use them.

C) Plasma exchange

Despite gaps in the understanding of the pathophysiology, TPE has shown benefit in the management of almost all types of TMA by replacing the defective/deficient proteins (ADAMTS13, complement, etc.) with a functional one [71]. TPE has established efficacy in the treatment of TMA in multiple RCTs, with the most robust improvements being demonstrated in patients with TTP [72]. All three patients reported in the literature having acquired TTP associated with COVID-19 responded well to treatment with TPE [38–40]. As such, the use of TPE in patients with COVID-19 who have also been clinically diagnosed with a TMA should be considered standard, just as it would be in patients without COVID-19. Some unique concerns that come up regarding TPE in patients with COVID-19 however include the question of whether it may have deleterious effects by removing any anti-SARS-CoV-2 antibodies that may be in circulation. This has not been proven or reported in any studies of TPE in COVID-19 so far, but the theoretical concern could be addressed to some extent by administering COVID convalescent plasma (CCP) in between TPE sessions although the limited availability of this product may preclude prolonged use. Ongoing randomized trials of TPE in COVID-19 patients may provide clearer answers to these questions.

Besides its use in COVID-19 patients with TMA, the empiric deployment of TPE in severe COVID-19 in general, without documented TMA, has also suggested clinical benefit, presumably by removing

inflammatory cytokines like IL-1, IL-6, GCSF, TNF and other deleterious elements [73,74]. Whether TPE may also be beneficial in patients with severe COVID-19 is in fact the subject of ongoing RCTs (NCT04374539, NCT04441996) [69]. A question that arises in the context of using TPE to primarily remove inflammatory cytokines is whether FFP needs to be used for replacement or whether albumin would be the more appropriate product. While no definitive recommendations can be made at this time, the above-mentioned clinical trials may provide some answers. These studies are looking at the full spectrum of replacement product options from a 70/30 albumin/plasma mix to all albumin or all plasma. If the effectiveness of TPE in severe COVID-19 is proven to be significant in the RCTs – it will substantially strengthen the existing evidence suggesting its use in critically ill COVID-19 patients.

D) COVID convalescent plasma (CCP)

Treatment with convalescent plasma infusion is currently being tested in RCTs for the treatment of severe COVID-19 related illnesses (NCT04348656, NCT04340050). A systematic review of small, uncontrolled studies and case series concluded that treatment with convalescent plasma in COVID-19 patients reduced the mortality and was associated with better clinical outcomes [75]. Convalescent plasma treatment is thought to act by multiple mechanisms in COVID-19 related illnesses:

1. Neutralizing antibodies to the virus particle help in reducing the viral load [76].
2. Anti-inflammatory cytokines, antibodies against autoantibodies, cytokines, and inflammatory cytokines function to modulate the immune system, improving the detrimental effects of cytokine storm [77].

Theoretically, it would make sense to use CCP instead of FFP or albumin in patients with COVID-19 who need TPE for a TMA like presentation because that would have the dual benefit of addressing the TMA as well as providing neutralizing antibodies against SARS-CoV-2. In reality however, the limited supply of CCP at the present time would generally preclude such use due to the large volume needed for TPE.

E) Immunosuppressants

While corticosteroids are an important part of treating severe COVID-19 infection, patients with certain TMAs like TTP may need more aggressive immunosuppression with additional agents. Concurrent use of targeted immunosuppressants and corticosteroids puts patients at a significantly higher risk for infection and related complications. Rituximab is one of the commonly used immunosuppressants in the treatment of acquired-TTP. Lack of robust clinical data on the effect of immunosuppression by targeted molecules on COVID-19 patients further complicates the situation. Anecdotal cases of severe disease in patients on rituximab have been published [78]. The ASH recommends balancing the risk-benefit while administering standard dose rituximab to patients with active COVID-19 infection [79]. In that regard, a novel targeted therapy described in the next section may be of value in delaying initiation of rituximab until after recovery from acute COVID-19.

F) Caplacizumab

Caplacizumab is a bivalent, humanized immunoglobulin fragment used in the treatment of TTP. It binds to the A1 domain of the VWF, intercepting its interaction with the platelet glycoprotein Ib-IX-V receptor. By doing so, it blunts a pathway to microvascular thrombosis [80]. The efficacy of Caplacizumab in the management of acute and refractory TTP is well established, and it is now FDA approved for the treatment of TTP [81] and was also included in the ISTH guidelines in

2020 for the management of this disease. The drug gains particular importance in the management of COVID-19 associated TTP as it is not an immunosuppressant [80]. The American society of hematology (ASH) recommends its use in conjugation with TPE and corticosteroids if the patient has TTP in the setting of an active COVID-19 infection [79].

7. Conclusion

The published global literature in the wake of the COVID-19 pandemic clearly points to thrombotic complications as a major cause of morbidity and mortality seen in severely affected patients, leading to near universal use of prophylactic or therapeutic doses of anti-coagulation in such cases. The ineffectiveness of conventional anti-coagulation in preventing thrombotic complications in a sizeable portion suggests additional mechanisms such as TMA. These seem to be present in nearly a third of the patients and would not be expected to respond to plain anticoagulation. We therefore propose a rational stepwise approach to these patients that involves definitive assessment for the presence of a TMA which if found can be characterized and accordingly addressed. Even though data pertaining to this are still relatively limited, we believe this is a potentially useful strategy in critically ill patients, especially since targeted interventions addressing specific underlying pathophysiology such as complement mediated or other TMAs are now available.

Funding

This research did not receive any specific grant from funding agencies in the public, commercial, or not-for-profit sectors.

Declaration of competing interest

The authors declare that they have no known competing financial interests or personal relationships that could have appeared to influence the work reported in this paper.

Acknowledgements

We are deeply grateful to Dr. Giuseppe Remuzzi for his valuable suggestions in improvement of this manuscript at every stage.

References

- [1] Weekly operational update on COVID-19 - 22. <https://www.who.int/publications/m/item/weekly-operational-update-on-covid-19-22-february-2021>, February 2021. (Accessed 24 February 2021).
- [2] F. Wu, S. Zhao, B. Yu, et al., A new coronavirus associated with human respiratory disease in China, *Nature* (2020), <https://doi.org/10.1038/s41586-020-2008-3>. Published online.
- [3] C. Huang, Y. Wang, X. Li, et al., Clinical features of patients infected with 2019 novel coronavirus in Wuhan, China, *Lancet*. 395 (2020) 497–506, [https://doi.org/10.1016/S0140-6736\(20\)30183-5](https://doi.org/10.1016/S0140-6736(20)30183-5).
- [4] D. Wang, B. Hu, C. Hu, et al., Clinical characteristics of 138 hospitalized patients with 2019 novel coronavirus-infected pneumonia in Wuhan, China, *JAMA - J Am Med Assoc.* 323 (11) (2020) 1061–1069, <https://doi.org/10.1001/jama.2020.1585>.
- [5] W. Cao, T. Li, COVID-19: towards understanding of pathogenesis, *Cell Res.* 30 (5) (2020) 367–369, <https://doi.org/10.1038/s41422-020-0327-4>.
- [6] Y. Zhang, M. Xiao, S. Zhang, et al., Coagulopathy and antiphospholipid antibodies in patients with covid-19, *N. Engl. J. Med.* 382 (17) (2020), E38, <https://doi.org/10.1056/NEJMc2007575>.
- [7] R. Beyrouti, M.E. Adams, L. Benjamin, et al., Characteristics of ischaemic stroke associated with COVID-19, *J. Neurol. Neurosurg. Psychiatry* 91 (8) (2020), <https://doi.org/10.1136/jnnp-2020-323586>.
- [8] S. Ahmed, O. Zimba, A.Y. Gasparyan, Thrombosis in coronavirus disease 2019 (COVID-19) through the prism of Virchow's triad, *Clin. Rheumatol.* 39 (9) (2020) 2529–2543, <https://doi.org/10.1007/s10067-020-05275-1>.
- [9] N. Kipshidze, G. Dangas, C.J. White, et al., Viral coagulopathy in patients with COVID-19: treatment and care, *Clin. Appl. Thromb.* 26 (2020), <https://doi.org/10.1177/1076029620936776>.
- [10] J.N. George, C.M. Nester, Syndromes of thrombotic microangiopathy, *N. Engl. J. Med.* 371 (7) (2014) 654–666, <https://doi.org/10.1056/nejmra1312353>.
- [11] R.L. da Silva, Viral-associated thrombotic microangiopathies, *Hematol. Oncol. Stem. Cell Ther.* 4 (2) (2011) 51–59, <https://doi.org/10.5144/1658-3876.2011.51>.
- [12] L. Carsana, A. Sonzogni, A. Nasr, et al., Pulmonary post-mortem findings in a series of COVID-19 cases from northern Italy: a two-centre descriptive study, *Lancet Infect. Dis.* (2020), [https://doi.org/10.1016/S1473-3099\(20\)30434-5](https://doi.org/10.1016/S1473-3099(20)30434-5). Published online.
- [13] M. Ackermann, S.E. Verleden, M. Kuehnel, et al., Pulmonary vascular endothelialitis, thrombosis, and angiogenesis in Covid-19, *N. Engl. J. Med.* 383 (2) (2020) 120–128, <https://doi.org/10.1056/NEJMoa2015432>.
- [14] E.C.M. van Gorp, C. Suharti, H. ten Cate, et al., Review: infectious diseases and coagulation disorders, *J. Infect. Dis.* 180 (1) (1999) 176–186, <https://doi.org/10.1086/314829>.
- [15] F.A. Klok, M.J.H.A. Kruip, N.J.M. van der Meer, et al., Confirmation of the high cumulative incidence of thrombotic complications in critically ill ICU patients with COVID-19: an updated analysis, *Thromb. Res.* 191 (April) (2020) 148–150, <https://doi.org/10.1016/j.thromres.2020.04.041>.
- [16] J.A. Hippensteel, E.L. Burnham, S.E. Jolley, Prevalence of venous thromboembolism in critically ill patients with COVID-19, *Br. J. Haematol.* 190 (3) (2020), <https://doi.org/10.1111/bjh.16908>.
- [17] J. Nahum, T. Morichau-Beauchant, F. Daviaud, et al., Venous thrombosis among critically ill patients with coronavirus disease 2019 (COVID-19), *JAMA Netw. Open* 3 (5) (2020), e2010478, <https://doi.org/10.1001/jamanetworkopen.2020.10478>.
- [18] L. Bowles, S. Platton, N. Yartey, et al., Lupus anticoagulant and abnormal coagulation tests in patients with Covid-19, *N. Engl. J. Med.* 383 (3) (2020) 288–290, <https://doi.org/10.1056/NEJMc2013656>.
- [19] I. Harzallah, A. Deblieux, B. Drénou, Lupus anticoagulant is frequent in patients with Covid-19, *J. Thromb. Haemost.* 18 (8) (2020), <https://doi.org/10.1111/jth.14867>.
- [20] J. Helms, C. Tacquard, F. Severac, et al., High risk of thrombosis in patients with severe SARS-CoV-2 infection: a multicenter prospective cohort study, *Intensive Care Med.* 46 (6) (2020) 1089–1098, <https://doi.org/10.1007/s00134-020-06062-x>.
- [21] R. Cervera, S. Bucciarelli, M.A. Plasín, et al., Catastrophic antiphospholipid syndrome (CAPS): descriptive analysis of a series of 280 patients from the “CAPS Registry.”, *J. Autoimmun.* 32 (3–4) (2009) 240–245, <https://doi.org/10.1016/j.jaut.2009.02.008>.
- [22] M. Noris, G. Remuzzi, Atypical hemolytic-uremic syndrome, *N. Engl. J. Med.* 361 (17) (2009) 1676–1687, <https://doi.org/10.1056/NEJMra0902814>.
- [23] A. Joseph, A. Cointe, P. Mariani Kurkdjian, C. Rafat, A. Hertig, Shiga toxin-associated hemolytic uremic syndrome: a narrative review, *Toxins (Basel)* 12 (2) (2020), <https://doi.org/10.3390/toxins12020067>.
- [24] C. Magro, J.J. Mulvey, D. Berlin, et al., Complement associated microvascular injury and thrombosis in the pathogenesis of severe COVID-19 infection: a report of five cases, *Transl. Res.* 220 (2020), <https://doi.org/10.1016/j.trsl.2020.04.007>.
- [25] M. Noris, A. Benigni, G. Remuzzi, The case of complement activation in COVID-19 multiorgan impact, *Kidney Int.* 98 (2) (2020) 314–322, <https://doi.org/10.1016/j.kint.2020.05.013>.
- [26] E. Bilgin, A.I. Ertenli, Proposal of a new nomenclature for the underlying pathogenetic mechanism of severe Coronavirus Disease-19: “Inflammatory Thrombosis with Immune Endotheliitis—ITIE.”, *Rheumatol. Int.* 41 (3) (2021) 679–680, <https://doi.org/10.1007/s00296-020-04768-1>.
- [27] A.B. Pine, M.L. Meizlish, G. Goshua, et al., Circulating markers of angiogenesis and endotheliopathy in COVID-19, *Pulm. Circ.* 10 (4) (2020), <https://doi.org/10.1177/2045894020966547>.
- [28] L.A. Teuwen, V. Geldhof, A. Pasut, P. Carmeliet, COVID-19: the vasculature unleashed, *Nat. Rev. Immunol.* 20 (7) (2020) 389–391, <https://doi.org/10.1038/s41577-020-0343-0>.
- [29] Mohamed MM, Lukitsch I, Torres-Ortiz AE, et al. Acute kidney injury associated with coronavirus disease 2019 in Urban New Orleans. *Kidney* 360. 2020;1(7):10.34067/KID.0002652020. doi:10.34067/kid.0002652020.
- [30] H. Su, M. Yang, C. Wan, et al., Renal histopathological analysis of 26 postmortem findings of patients with COVID-19 in China, *Kidney Int.* (2020), <https://doi.org/10.1016/j.kint.2020.04.003>. Published online.
- [31] S. Fox, A. Akmatbekov, J. Harbert, G. Li, J.Q. Brown, Heide R. Vander, Pulmonary and Cardiac Pathology in Covid-19: The First Autopsy Series From New Orleans. *medRxiv*, Published online April 10, 2020, <https://doi.org/10.1101/2020.04.06.20050575>, 2020.04.06.20050575.
- [32] S.E. Fox, A. Akmatbekov, J.L. Harbert, G. Li, J. Quincy Brown, R.S. Vander Heide, Pulmonary and cardiac pathology in African American patients with COVID-19: an autopsy series from New Orleans, *Lancet Respir. Med.* 8 (7) (2020), [https://doi.org/10.1016/S2213-2600\(20\)30243-5](https://doi.org/10.1016/S2213-2600(20)30243-5).
- [33] A.V. Rapkiewicz, X. Mai, S.E. Carsons, et al., Megakaryocytes and platelet-fibrin thrombi characterize multi-organ thrombosis at autopsy in COVID-19: a case series, *Eclinicalmedicine.* (2020) 24, <https://doi.org/10.1016/j.eclinm.2020.100434>.
- [34] T. Menter, J.D. Haslbauer, R. Nienhold, et al., Post-mortem examination of COVID19 patients reveals diffuse alveolar damage with severe capillary congestion and variegated findings of lungs and other organs suggesting vascular dysfunction, *Histopathology* (2020), <https://doi.org/10.1111/his.14134>. Published online August 1.
- [35] K.D. Jhaveri, L.R. Meir, Suyin Flores Chang B, et al. thrombotic microangiopathy in patient with COVID-19, *Kidney Int.* 98 (2020) 509–512, <https://doi.org/10.1093/cid/ciaa248>.
- [36] P. Sharma, N. Uppal, R. Wanchoo, et al., COVID-19-associated kidney injury: a case series of kidney biopsy findings, *J. Am. Soc. Nephrol.* (2020), <https://doi.org/10.1681/ASN.2020050699>. Published online. ASN.2020050699.

- [37] F. Daviet, F. Rouby, P. Poullin, et al., Thrombotic microangiopathy associated with gemcitabine use: presentation and outcome in a national French retrospective cohort, *Br. J. Clin. Pharmacol.* 85 (2) (2019) 403–412, <https://doi.org/10.1111/bcp.13808>.
- [38] N. Albiol, R. Awol, R. Martino, Autoimmune thrombotic thrombocytopenic purpura (TTP) associated with COVID-19, *Ann. Hematol.* 99 (7) (2020) 1673–1674, <https://doi.org/10.1007/s00277-020-04097-0>.
- [39] F. Hindilerden, I. Yonal-Hindilerden, E. Akar, K. Kart-Yasar, Covid-19 associated autoimmune thrombotic thrombocytopenic purpura: report of a case, *Thromb. Res.* 195 (2020) 136–138, <https://doi.org/10.1016/j.thromres.2020.07.005>.
- [40] M. Capecchi, C. Mocellin, C. Abbruzzese, I. Mancini, D. Prati, F. Peyvandi, Dramatic presentation of acquired TTP associated with COVID-19, *Haematologica* (2020), <https://doi.org/10.3324/haematol.2020.262345>. Published online. <https://doi.org/10.3324/haematol.2020.262345>.
- [41] Z. Varga, A.J. Flammer, P. Steiger, et al., Endothelial cell infection and endotheliitis in COVID-19, *Lancet.* 395 (10234) (2020) 1417–1418, [https://doi.org/10.1016/S0140-6736\(20\)30937-5](https://doi.org/10.1016/S0140-6736(20)30937-5).
- [42] P. Nicholson, L. Alshafai, T. Krings, Neuroimaging findings in patients with COVID-19, *Am. J. Neuroradiol.* 41 (8) (2020), <https://doi.org/10.3174/AJNR.A6630>.
- [43] M. Galbusera, M. Noris, S. Gastoldi, et al., An ex vivo test of complement activation on endothelium for individualized eculizumab therapy in hemolytic uremic syndrome, *Am. J. Kidney Dis.* 74 (1) (2019) 56–72, <https://doi.org/10.1053/j.ajkd.2018.11.012>.
- [44] T. Chiasakul, A. Cuker, Clinical and laboratory diagnosis of TTP: an integrated approach, *Hematol (United States)*. 2018 (1) (2018) 530–538, <https://doi.org/10.1182/asheducation-2018.1.530>.
- [45] P. Horby, W.S. Lim, et al., RECOVERY Collaborative Group, Dexamethasone in hospitalized patients with Covid-19 - preliminary report, *N. Engl. J. Med.* (2020), <https://doi.org/10.1056/NEJMoa2021436>. Published online July 17.
- [46] V. Brocklebank, K.M. Wood, D. Kavanagh, Thrombotic microangiopathy and the kidney, *Clin. J. Am. Soc. Nephrol.* 13 (2) (2018) 300–317, <https://doi.org/10.2215/CJN.00620117>.
- [47] C.M. Legendre, C. Licht, P. Muus, et al., Terminal complement inhibitor eculizumab in atypical hemolytic-uremic syndrome, *N. Engl. J. Med.* 368 (23) (2013) 2169–2181, <https://doi.org/10.1056/NEJMoa1208981>.
- [48] S. Sciascia, J. Yazdany, M. Dall'Era, et al., Anticoagulation in patients with concomitant lupus nephritis and thrombotic microangiopathy: a multicentre cohort study, *Ann. Rheum. Dis.* 78 (7) (2019) 1004–1006, <https://doi.org/10.1136/annrheumdis-2018-214559>.
- [49] R.S. Go, J.L. Winters, L. Leung, et al., Thrombotic Microangiopathy care pathway: a consensus statement for the Mayo Clinic complement alternative pathway-thrombotic Microangiopathy (CAP-TMA) disease-oriented group, *Mayo Clin. Proc.* 91 (9) (2016) 1189–1211, <https://doi.org/10.1016/j.mayocp.2016.05.015>.
- [50] J.S. Rico-Mesa, D. Rosas, A. Ahmadian-Tehrani, A. White, A.S. Anderson, R. Chilton, The role of anticoagulation in COVID-19-induced hypercoagulability, *Curr. Cardiol. Rep.* 22 (7) (2020), <https://doi.org/10.1007/s11886-020-01328-8>.
- [51] W.R. Bell, P.M. Ness, T.S. Kieckler, H.G. Braine, Improved survival in thrombotic thrombocytopenic purpura-hemolytic uremic syndrome: clinical experience in 108 patients, *N. Engl. J. Med.* 325 (6) (1991) 398–403, <https://doi.org/10.1056/NEJM199108083250605>.
- [52] K. Dane, S. Chaturvedi, Beyond plasma exchange: novel therapies for thrombotic thrombocytopenic purpura, *Hematol (United States)*. 2018 (1) (2018) 539–547, <https://doi.org/10.1182/asheducation-2018.1.539>.
- [53] K.A. Zielińska, Moortel L. Van, G. Opendakker, K. De Bosscher, P.E. Van den Steen, Endothelial response to glucocorticoids in inflammatory diseases, *Front. Immunol.* 7 (DEC) (2016), <https://doi.org/10.3389/fimmu.2016.00592>.
- [54] J.M. Weiler, B.D. Packard, Methylprednisolone inhibits the alternative and amplification pathways of complement, *Infect. Immun.* 38 (1) (1982) 122–126, <https://doi.org/10.1128/iai.38.1.122-126.1982>.
- [55] F.P. Limbourg, Z. Huang, J.-C. Plumier, et al., Rapid nontranscriptional activation of endothelial nitric oxide synthase mediates increased cerebral blood flow and stroke protection by corticosteroids, *J. Clin. Invest.* 110 (11) (2002) 1729–1738, <https://doi.org/10.1172/jci15481>.
- [56] Q. Ruan, K. Yang, W. Wang, L. Jiang, J. Song, Clinical predictors of mortality due to COVID-19 based on an analysis of data of 150 patients from Wuhan, China, *Intensive Care Med.* 46 (5) (2020) 846–848, <https://doi.org/10.1007/s00134-020-05991-x>.
- [57] C. Qin, L. Zhou, Z. Hu, et al., Dysregulation of immune response in patients with COVID-19 in Wuhan, China, *Clin. Infect. Dis.* 71 (15) (2020), <https://doi.org/10.1093/cid/ciaa248>.
- [58] L. Corral, A. Bahamonde, F.A. delas Revillas, et al., GLUCOCOVID: A Controlled Trial of Methylprednisolone in Adults Hospitalized With COVID-19 Pneumonia. *medRxiv*, Published online June 18, 2020, <https://doi.org/10.1101/2020.06.17.20133579>, 2020.06.17.20133579.
- [59] C.L. Balduini, L. Gugliotta, M. Luppi, et al., High versus standard dose methylprednisolone in the acute phase of idiopathic thrombotic thrombocytopenic purpura: a randomized study, *Ann. Hematol.* 89 (6) (2010) 591–596, <https://doi.org/10.1007/s00277-009-0877-5>.
- [60] B.S. Joly, P. Coppo, A. Veyradier, Thrombotic thrombocytopenic purpura, *Blood.* 129 (21) (2017) 2836–2846, <https://doi.org/10.1182/blood-2016-10-709857>.
- [61] A.M. Zaki, S. Van Boheemen, T.M. Bestebroer, A.D.M.E. Osterhaus, R.A. M. Fouchier, Isolation of a novel coronavirus from a man with pneumonia in Saudi Arabia, *N. Engl. J. Med.* 367 (19) (2012) 1814–1820, <https://doi.org/10.1056/NEJMoa1211721>.
- [62] R. Ohta, Y. Torii, M. Imai, H. Kimura, N. Okada, Y. Ito, Serum concentrations of complement anaphylatoxins and proinflammatory mediators in patients with 2009 H1N1 influenza, *Microbiol. Immunol.* 55 (3) (2011) 191–198, <https://doi.org/10.1111/j.1348-0421.2011.00309.x>.
- [63] Y. Jiang, G. Zhao, N. Song, et al., Blockade of the C5a-C5aR axis alleviates lung damage in hDPP4-transgenic mice infected with MERS-CoV article, *Emerg. Microbes. Infect.* 7 (1) (2018), <https://doi.org/10.1038/s41426-018-0063-8>.
- [64] K.B. O'Brien, T.E. Morrison, D.Y. Dundore, M.T. Heise, S. Schultz-Cherry, A protective role for complement C3 protein during pandemic 2009 H1N1 and H5N1 influenza A virus infection, *PLoS One* 6 (3) (2011), <https://doi.org/10.1371/journal.pone.0017377>.
- [65] S. Sun, G. Zhao, C. Liu, et al., Inhibition of complement activation alleviates acute lung injury induced by highly pathogenic avian influenza H5N1 virus infection, *Am. J. Respir. Cell Mol. Biol.* 49 (2) (2013) 221–230, <https://doi.org/10.1165/rcmb.2012-0428OC>.
- [66] L.E. Gralinski, T.P. Sheahan, T.E. Morrison, et al., Complement activation contributes to severe acute respiratory syndrome coronavirus pathogenesis, *MBio* 9 (5) (2018), <https://doi.org/10.1128/mBio.01753-18>.
- [67] K.A. Stoermer, T.E. Morrison, Complement and viral pathogenesis, *Virology.* 411 (2) (2011) 362–373, <https://doi.org/10.1016/j.virol.2010.12.045>.
- [68] F. Diurno, F.G. Numis, G. Porta, et al., Eculizumab treatment in patients with COVID-19: preliminary results from real life ASL Napoli 2 Nord experience, *Eur. Rev. Med. Pharmacol. Sci.* 24 (7) (2020) 4040–4047, https://doi.org/10.26355/EURREV_202004_20875.
- [69] Home. *ClinicalTrials.gov* (web archive link, 20 September 2020). (Accessed 20 September 2020). <https://clinicaltrials.gov/>.
- [70] S. Mastaglio, A. Ruggeri, A.M. Risitano, et al., The first case of COVID-19 treated with the complement C3 inhibitor AMY-101, *Clin. Immunol.* 215 (2020), <https://doi.org/10.1016/j.clim.2020.108450>.
- [71] J.L. Winters, Plasma exchange in thrombotic microangiopathies (TMAs) other than thrombotic thrombocytopenic purpura (TTP), *Hematology.* 2017 (1) (2017) 632–638, <https://doi.org/10.1182/asheducation-2017.1.632>.
- [72] G.A. Rock, K.H. Shumak, N.A. Buskard, et al., Comparison of plasma exchange with plasma infusion in the treatment of thrombotic thrombocytopenic purpura, *N. Engl. J. Med.* 325 (6) (1991) 393–397, <https://doi.org/10.1056/NEJM199108083250604>.
- [73] F. Khamis, I. Al-Zakwani, S. Al Hashmi, et al., Therapeutic plasma exchange in adults with severe COVID-19 infection, *Int. J. Infect. Dis.* 99 (2020) 214–218, <https://doi.org/10.1016/j.ijid.2020.06.064>.
- [74] B. Gucyetmez, H.K. Atalan, I. Sertdemir, et al., Therapeutic plasma exchange in patients with COVID-19 pneumonia in intensive care unit: a retrospective study, *Crit. Care* 24 (1) (2020) 492, <https://doi.org/10.1186/s13054-020-03215-8>.
- [75] K. Rajendran, K. Narayanasamy, J. Rangarajan, J. Rathinam, M. Natarajan, A. Ramachandran, Convalescent plasma transfusion for the treatment of COVID-19: systematic review, *J. Med. Virol.* (2020), <https://doi.org/10.1002/jmv.25961>. Published online.
- [76] A. Casadevall, M.J. Joyner, L.A. Pirofski, A randomized trial of convalescent plasma for COVID-19 - potentially hopeful signals, *JAMA - J Am Med Assoc.* (2020), <https://doi.org/10.1001/jama.2020.10218>. Published online.
- [77] M. Rojas, Y. Rodríguez, D.M. Monsalve, et al., Convalescent plasma in Covid-19: possible mechanisms of action, *Autoimmun. Rev.* 19 (7) (2020), <https://doi.org/10.1016/j.autrev.2020.102554>.
- [78] P. Guilpain, C. Le Bihan, V. Foulongne, et al., Rituximab for granulomatosis with polyangiitis in the pandemic of covid-19: lessons from a case with severe pneumonia, *Ann. Rheum. Dis.* (2020), <https://doi.org/10.1136/annrheumdis-2020-217549>. Published online.
- [79] COVID-19 and TTP - Hematology.org. <https://www.hematology.org/covid-19/covid-19-and-ttp>. (Accessed 11 August 2020).
- [80] F. Callewaert, J. Roodt, H. Ulrichts, et al., Evaluation of efficacy and safety of the anti-VWF Nanobody ALX-0681 in a preclinical baboon model of acquired thrombotic thrombocytopenic purpura, *Blood.* 120 (17) (2012) 3603–3610, <https://doi.org/10.1182/blood-2012-04-420943>.
- [81] M. Scully, S.R. Cataland, F. Peyvandi, et al., Caplacizumab treatment for acquired thrombotic thrombocytopenic purpura, *N. Engl. J. Med.* 380 (4) (2019) 335–346, <https://doi.org/10.1056/NEJMoa1806311>.