


STANDARD ARTICLE

Patterns of local residual disease and local failure after intensity modulated/image guided radiation therapy for sinonasal tumors in dogs

Valerie J. Poirier^{1,2}  | Ethel S. Y. Koh¹ | Johnson Darko³ | Andre Fleck³ | Christopher Pinard² | David M. Vail⁴

¹School of Veterinary Science, Massey University, Palmerston North, New Zealand

²Department of clinical studies, Ontario Veterinary College, University of Guelph, Guelph, Ontario, Canada

³Department of Medical Physics, Grand River Regional Cancer Centre, Kitchener, Ontario, Canada

⁴School of Veterinary Medicine, University of Wisconsin-Madison, Madison, Wisconsin

Correspondence

Valerie J. Poirier, Mona Campbell Centre for Animal Cancer, Ontario Veterinary College, University of Guelph, 36 College Avenue W, Guelph, Ontario, N1G 1S8, Canada.
 Email: vpoirier@uoguelph.ca

Funding information

Massey University summer student scholarship

Abstract

Background: Most dogs with sinonasal tumors (SNT) treated with radiation therapy (RT) died because of local disease progression.

Hypothesis/Objectives: Our hypothesis is that the majority of local failure and residual disease would occur within the radiation field.

Animals: Twenty-two dogs with SNT treated with RT.

Methods: Retrospective cohort study. Inclusion criteria: dogs with SNT receiving 10 daily fractions of 4.2 Gy with intensity modulated radiation therapy (IMRT)/image guided radiation therapy (IGRT) and follow-up cone beam computed tomography (CBCT). Each CBCT was registered with the original radiation planning CT and the gross tumor volume (GTV) contoured. The GTV was classified as residual (GTVr) or a failure (GTVf). The dose statistic for each GTV was calculated with the original IMRT plan. For GTVf, failures were classified as “in-field,” “marginal,” or “out-field” if at least 95, 20-95, or less than 20% of the volume of failure was within 95% (D95) of the total prescription dose, respectively.

Results: There were 52 follow-up CBCT/CTs. Overall there was a GTVr for 20 dogs and GTVf for 16 dogs. The majority of GTVr volume was within the original GTV. GTVf analysis showed that 75% (12/16) were “in-field,” 19% (3/16) were “marginal” and 6% (1/16) were “out-field.”

Conclusion and Clinical Importance: In-field failures are the main pattern for local recurrence, and there is evidence of radioresistant subvolumes within the GTV.

KEYWORDS

dosimetry, IGRT, IMRT, nasal tumor

Abbreviations: 3D, 3 dimensional; CBCT, cone beam computed tomography; CT, computed tomography; CTV, clinical target volume; GTV, gross tumor volume; GTVf, gross tumor volume failure; GTVr, gross tumor volume residual; Gy, gray; IGRT, image-guided radiation therapy; IMRT, intensity-modulated radiation therapy; PTV, planned target volume; RT, radiation therapy; SNT, canine sinonasal tumors.

1 | INTRODUCTION

Veterinary radiation oncology uses more advanced conformal planning and delivery techniques using intensity-modulated radiation

This is an open access article under the terms of the Creative Commons Attribution-NonCommercial-NoDerivs License, which permits use and distribution in any medium, provided the original work is properly cited, the use is non-commercial and no modifications or adaptations are made.

© 2021 The Authors. *Journal of Veterinary Internal Medicine* published by Wiley Periodicals LLC on behalf of American College of Veterinary Internal Medicine.

therapy (IMRT) and much more precise radiation positioning and delivery with the integration of cone-beam computed tomography (CT) (CBCT) that permits image-guided radiation therapy (IGRT).¹⁻³ Although increased sparing of normal tissue occurs with IMRT/IGRT in the treatment of canine sinonasal tumors (SNT) in dogs, there is no improvement in tumor control or long-term survival.⁴ Regardless of the protocol pursued (definitive, palliative, or stereotactic), median survival times have not improved, ranging from 4.8 to 19.7 months.⁵ Most dogs ultimately die of local disease progression.

ICRU 50⁶ first introduced the concept of gross tumor volume (GTV), clinical target volume (CTV), and planned target volume (PTV). Gross tumor volume is described as the volume that can be seen by eye (or palpation) either on the animal, or with the help of imaging. Clinical target volume is described as a tissue volume that contains a GTV and subclinical microscopic malignant disease, which has to be eliminated. The PTV was further in ICRU 62⁷ and is a geometrical concept introduced for treatment planning and evaluation. It is the recommended tool to shape absorbed-dose distributions to ensure that the prescribed absorbed dose will actually be delivered to all parts of the CTV with a clinically acceptable probability, despite geometrical uncertainties such as organ motion and setup variations. The PTV surrounds the representation of the CTV.

A prerequisite to establishing the appropriate CTV expansion for SNT when using IMRT/IGRT would be to characterize the pattern of local failure after radiation. Local radiotherapy treatment failure can be related either to the radio-resistance of the tumor or a geometric miss of the target tumor treatment volume.⁸ The location (in field, marginal, or out of field) of the progressive tumor in relation to the original treated volume indicates the cause of treatment failure.⁹⁻¹¹ Similarly, determining the dose received to the residual tumor after radiation can help determine if the residual tumor is a radioresistant or underdosed part of the tumor. The response of SNT to radiation is reported in 2 recent publications^{12,13} and reduction of tumor volumes after radiation occurs in most cases. Sinonasal tumor response over the first 9 to 18 months after RT has been reported.^{4,14} No attempts have been made to identify the location of local failure or local residual tumor after RT in comparison to the original treated volume and dose. The aim of this retrospective study was to analyze patterns of local residual tumor and local failure after IMRT/IGRT for SNT in dogs treated at a single institution. Our hypothesis is that because the CTV/PTV expansion practice at our institution is similar to the most aggressive (ie, largest) expansion approach, the great majority of local failure would occur in field.

2 | METHODS

2.1 | Case selection

Dogs receiving IMRT/IGRT for sinonasal tumors from August 2013 to February 2018 at the Animal Cancer Centre of the University of Guelph were retrospectively analyzed. Inclusion criteria included: dogs with histologically confirmed SNT of any histology treated with

IMRT/IGRT with 10 daily fractions of 4.2 Gy on a Monday-Friday schedule to a total prescribed dose of 42 Gy, and at least 1 follow-up CBCT performed in the first 12 months after the initial treatment importable into the Eclipse planning system. As the study used data that were generated during routine treatments, there was no requirement for animal welfare committee approval.

2.2 | Dog and tumor information

Dogs' age, weight, sex, histological diagnosis, results of thoracic and abdominal imaging as well as lymph node status and local tumor stage were recorded. Tumors were staged according to the modified Adams tumor staging system¹⁵: stage 1: confined to 1 nasal passage with no bone involvement beyond the turbinates; stage 2: any bone involvement without evidence of orbit/subcutaneous/submucosal mass; stage 3: orbit involved or nasopharyngeal or subcutaneous or submucosal mass; and stage 4: tumor-associated lysis of the cribriform plate. The recommended follow-up was a CBCT every 3 months after completion of RT. Follow-up information collected included: date of death, cause of death, any follow-up treatment (systemic treatment, additional RT, and use of nonsteroidal anti-inflammatory drugs [NSAID]). Information was collected by review of the medical record or phone interview of the referring veterinarian.

2.3 | Positioning and planning CT

Dogs were routinely immobilized in a vacuum deformable mattress (Vac-LokCIVCO, Orange City, Iowa) and indexed bite block (3M-Express STD Putty ESPE Dental Products, St. Paul, Minnesota) for the planning CT and for each of the radiation treatment sessions. The vacuum deformable mattress was in contact with the ventral thorax and abdomen and the maxillary dentition was in contact with the indexed bite block. All dogs were kept in sternal recumbency with forelimbs extended caudally and elbows extended. A 16-slice helical CT (GE Bright Speed CT scanner, GE Healthcare, Milwaukee, Wisconsin) was used for the scans. All dogs were premedicated with a combination of butorphanol (Torbugesic; Zoetis Canada, Quebec, Canada) or morphine (Baxter Healthcare, Glenview, Illinois) and or acepromazine (Acevet 25; Vetoquinol, Quebec, Canada). Propofol (PropoFlo 28; Zoetis Canada) was used for induction, and isoflurane (IsoFlo; Zoetis Canada) was used for maintenance of general anesthesia. Iopamidol (ISOVUE-300, Bracco Imaging Canada, Montreal, Quebec, Canada) was used as the contrast agent given at a dose of 2 mL/kg (300 mg/mL) with postcontrast scans taken approximately 20 to 60 seconds after IV administration. The effective length of the detector elements in the longitudinal direction was 0.625 mm. Computed tomography were reconstructed with a 2 mm slice thickness and exported to the Eclipse planning system. All dogs had some form of tissue bolus placed over the nose. The bolus was present for the planning CT and for every radiation session.

2.4 | Radiation planning

All plans were generated using the Eclipse Planning System Version 11 or 13 (Varian Medical Systems, Palo Alto, California) and the precontrast CT scan. All dogs had a structure set created and tumors contoured by the same ACVR board certified radiation oncologist (VPO) having at least 7 years' experience at the time of the first dog in this study. The GTV was contoured on CT after contrast in a bone window and consisted of the contrast-enhancing mass, although for 3 dogs, the GTV included fluid in the frontal sinus. The CTV was a 1 cm isotropic expansion confined to the nasal cavity but including the entire nasal bone (unless extra nasal mass was present then the CTV was generated in a case by case basis but usually a minimum of 1 cm) and the frontal sinus fluid if present (except the 3 dogs that had the frontal sinus fluid included in the GTV). Planned target volume isotropic expansion was 1 to 2 mm caudal to the eyes and 3 to 4 mm rostrally to account for pitch variation that was sometimes seen during radiation as the region of interest for matching during the daily CBCT was eye and brain at the level of the PTV. Planned target volume was not cropped for dose reporting. Organs at risk that were routinely contoured on the original plan included both eyes, both ocular lenses, and the brain. By the end of 2016, both lacrimal glands were also contoured routinely. The prescription for all dogs was 42 Gy in 10 4.2 Gy fractions

on a Monday-Friday schedule. Planning objectives for radiation target (PTV) were that D95 = 95% (95% of the PTV volume receives 95% of the prescribed dose) and D50 = 100% (median dose = 100% of the prescribed dose). Volume and dosimetry information for the radiation targets (PTV, CTV, GTV) including mean, median, D95 (dose received by 95% of the volume), D98 (dose received by 98% of the volume), and D2 (dose received by 2% of the volume) were extracted.

2.5 | Radiation treatment

Dogs were anesthetized and positioned for their treatment by radiation therapists. On board kV CBCT imaging using the ix2300 Clinac linear accelerator (Varian Medical Systems, Palo Alto, California) was used for dog alignment to verify target positioning at each radiation session. Cone beam computed tomography settings used the "high quality head" setting with a 2.5 mm slice thickness with an overlap of 2 mm, 384 × 384-pixel field of view and a full-fan bowtie filter. The volume of interest for matching during treatment was brain/eyes at the level of the PTV and the match was confirmed by at least 2 people - either 2 human-trained radiation therapists or a veterinary radiation oncologist and a human-trained radiation therapist.

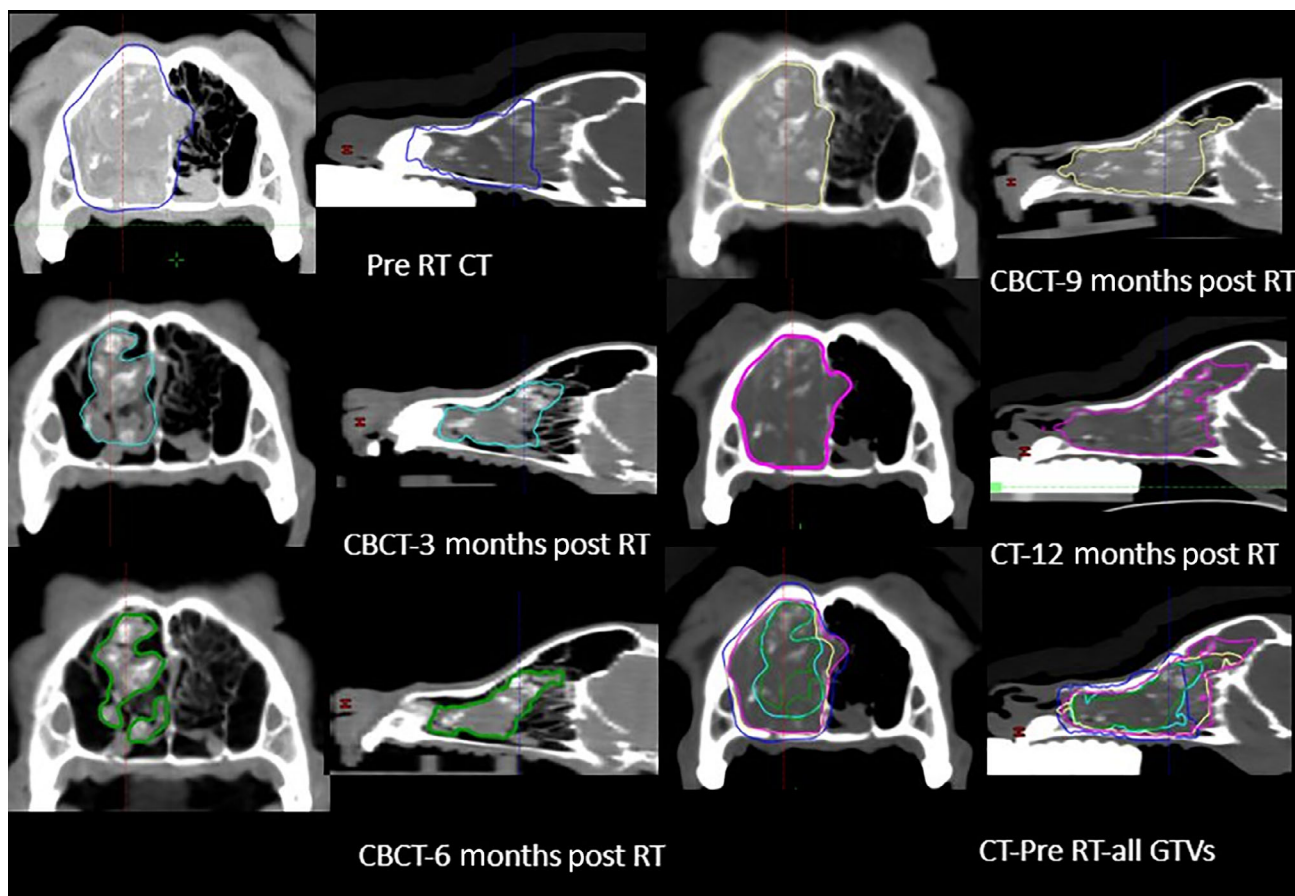


FIGURE 1 Gross tumor volume contouring. An example of the imaging GTV contouring in a dog. Transverse and sagittal images of CT/CBCT at different time point for the same dog. Original GTV is blue, CBCT-3 months GTV is cyan, CBCT-6 months GTV is green, CBCT-9 months GTV is yellow, CBCT-12 months GTV is purple. CT, computed tomography; CBCT, cone beam computed tomography

2.6 | Follow-up CBCT/CT

Each follow-up CBCT were non contrast-enhanced were acquired with the same on-board imaging (kV-CBCT) and with the same protocol as during radiation. The dogs were positioned similarly to the radiation treatment with the indexed bite block but in a nonvacuum deformable mattress and without the dental putty. Each follow-up CBCT were registered using a rigid registration with the original radiation planning CT in the Eclipse planning system. Five dogs had follow-up contrast-enhanced CT scans (instead of a CBCT) with a similar protocol to the RT planning CT.

2.7 | Dosimetry of the GTV

A duplicate “nasal dosimetry” of the original structure set was created in the Eclipse planning system and extra structures (1 GTV per subsequent CBCT/CT) were created retrospectively and contoured for each dog (Figure 1). The GTV were contoured in the axial plane on the

noncontrast CBCT or the contrast-enhanced CT in a bone window once by a single rater and the contours were verified by a single radiation oncologist. Volume of each GTV was obtained. The “nasal dosimetry” structure set was used with the original plan parameters on the original RT planning precontrast CT to generate a dose distribution for the new structure set (Figure 2). For each dog, it was verified that the dose distribution was identical for all the original structures. Using the dose volume histogram for each GTV, the following dosimetric parameters were recorded: median dose, D95, and D98.

2.8 | Response assessment

To determine volumetric changes and disease status, we chose to use the volumetric change recommended by the consensus recommendations for multicenter canine brain tumor clinical trials.¹⁶ To define response; a 65% or greater decrease in GTV from the original GTV was defined as partial response (PR), an increase of 40% or more from the previous GTV on CT or CBCT was defined as progressive disease

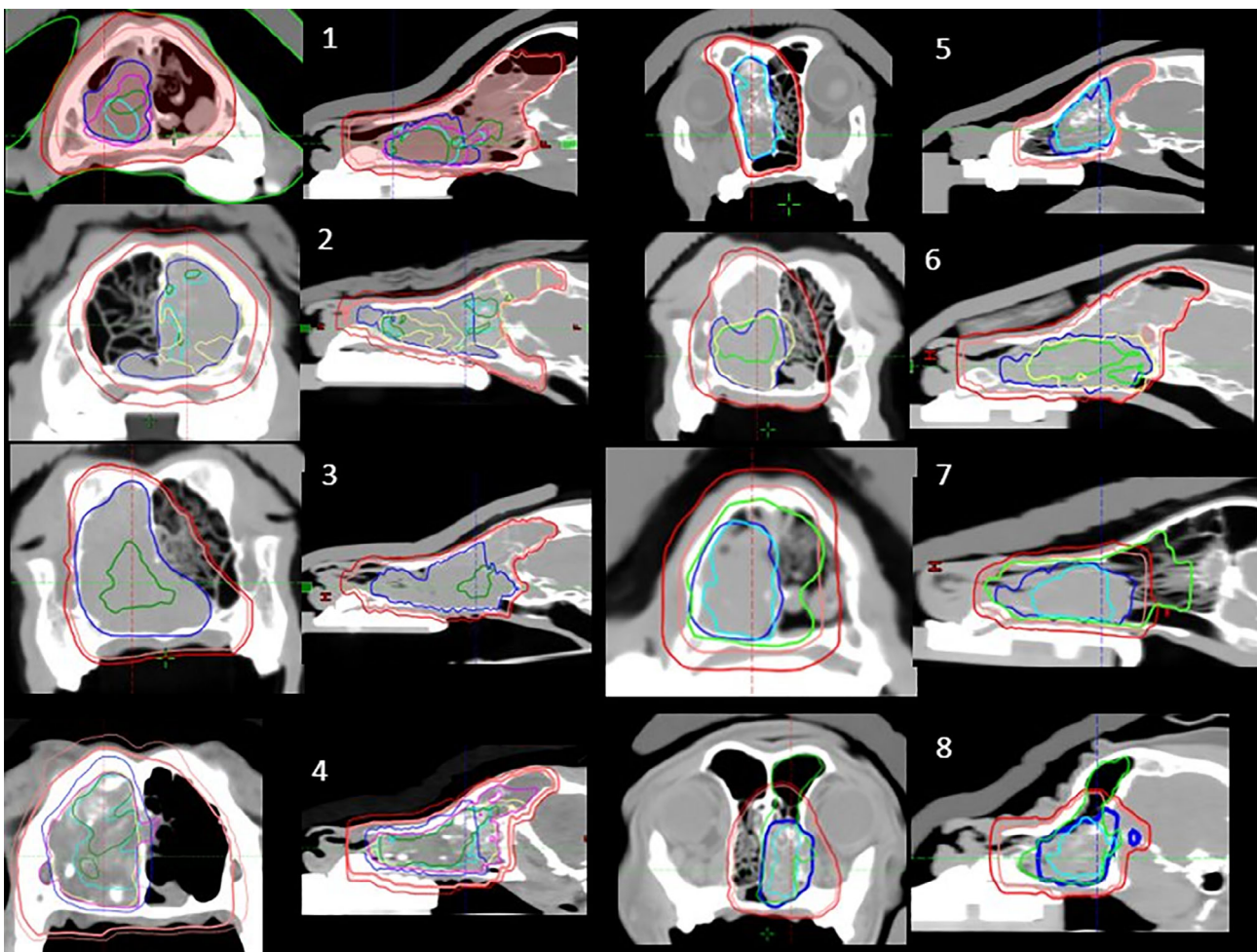


FIGURE 2 Nasal dosimetry structure. Transverse and sagittal CT images of the “nasal dosimetry” structure set from 8 dogs with sinonasal tumors treated with RT. Original GTV is blue, CBCT-3 months GTV is cyan, CBCT-6 months GTV is green, CBCT-9 months GTV is yellow, CBCT-12 or more months GTV is purple. CTV is pink, PTV is red. CT, computed tomography; CBCT, cone beam computed tomography; CTV, clinical target volume; GTV, gross tumor volume; PTV, planned target volume

(PD), and any changes in between a PR and a PD was defined a stable disease (SD). Complete resolution of the GTV defined a complete response (CR).

TABLE 1 Dog characteristics (n = 22)

Age (years)	Median: 10 (6-15)
Weight (kg)	Median: 23.1 (5-51)
Sex	Female spayed n = 8 Male neutered n = 14
Histology	Carcinoma n = 15 (68%) Chondrosarcoma n = 6 (27%) Osteosarcoma n = 1 (5%)
Stage-modified Adams	1 n = 7 (32%) 2 n = 3 (14%) 3 n = 6 (27%) 4 n = 6 (27%)
Gross target volume (cm ³)	Median: 33.4 (2.2-125.7)
Gross target volume (equivalent sphere diameter) (cm)	Median: 4 (1.6-6.2)
Best response on follow-up imaging	Complete response: 2/22 (9%) Partial response: 11/22 (50%) Stable disease: 8/22 (36%) Progressive disease: 1/22 (5%)

2.9 | Pattern of local failure assessment

The GTV was considered residual (GTVr) if it was smaller than the original GTV or the previous CBCT-GTV and located inside the CTV. The GTV was considered a failure (GTVf) if it was larger than the previous GTV on CT/CBCT by at least 40% or located outside the CTV. For GTVf, failures were classified as “in-field,” “marginal,” or “out-field” if at least 95%, 20%-95%, or less than 20% of the volume of failure was within 95% (D95) of the total prescription dose respectively.⁹⁻¹¹

2.10 | Statistical analysis

Descriptive statistics were reported using mean and standard deviation, median, 95% confidence interval (95% CI), and range. Progression-free survival (PFS) was defined from the first RT until progressive disease or death in days. Dog were censored if still

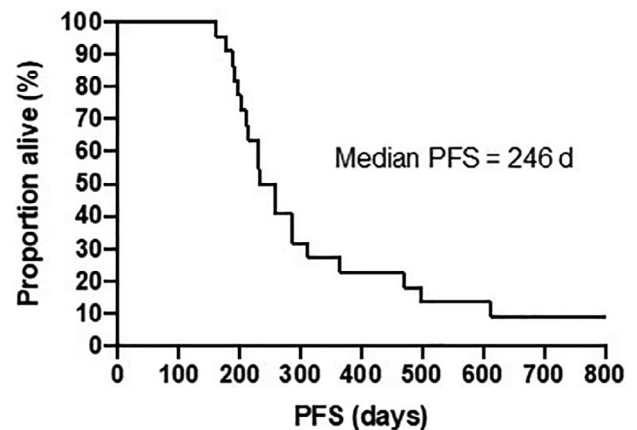


FIGURE 3 Progression-free survival (PFS) in days for all 22 dogs

Radiation target	Volume (cm ³)	D50 (Gy)	D95 (Gy)	D98 (Gy)	D2 (Gy)
GTV					
Mean	41.6	43.6	42	41.6	45
Median	33.4	43.7	42	41.5	44.8
Range	2.2-125.7	41.9-45.0	40.4-44.4	40.1-44.2	43.8-47.6
CTV					
Mean	129.8	43.5	40.9	40.2	45.3
Median	139.8	43.5	40.7	40.0	45.2
Range	17.7-293.2	42.0-44.8	39.2-42.9	38.6-42.4	44.1-47.7
PTV					
Mean	176.6	43.1	39.7	38.7	45.3
Median	190.7	43.0	39.9	38.9	45.1
Range	23.8-450.8	41.7-44.5	38.7-41.1	37.4-40.3	44.1-47.4

TABLE 2 Radiation target volumes and dose statistics associated with a prescription of 10 fractions of 4.2 Gy (total dose 42 Gy) for 22 dogs

Abbreviations: CTV, clinical target volume; D2, dose received by 2% of the volume; D50, dose received by 50% of the volume; D95, dose received by 95% of the volume; D98, dose received by 98% of the volume; GTV, gross target volume; PTV, planned target volume.

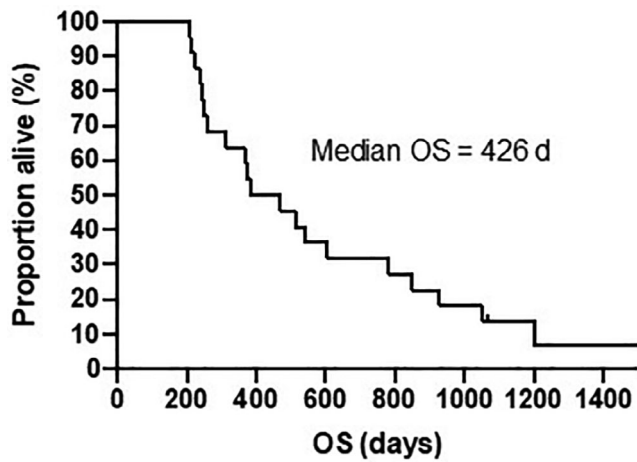


FIGURE 4 Overall survival time (OS) in days for all 22 dogs

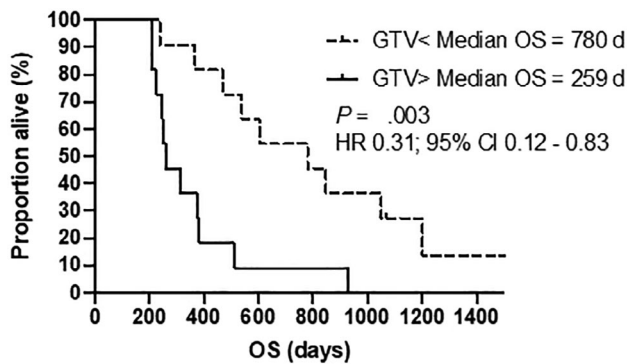


FIGURE 5 Overall survival (OS) for all dogs based on gross tumor volume (GTV) (median: 33.35 cm³ or sphere equivalent diameter: 4 cm). <=less, > = more, HR, hazard ratio; 95% CI, 95% confidence interval

alive without progression. Overall survival (OS) was defined from the first RT until death in days. Dogs were censored if still alive at final follow-up. The Kaplan-Meier method was used to estimate and display the distribution of PFS and OS. Differences between potential prognostic subsets (age, weight, tumor histology, original GTV volume < median vs > median, tumor stage, tumor response, after PD treatment with RT, and after PD treatment with systemic therapy) were compared using the log-rank (Mantel-Cox) test. When multiple groups were compared (eg, response), if an overall difference were noted, individual groups were then analyzed against all others post hoc to identify prognostic groups. All reported *P*-values are 2 sided and *P* < .05 was used to define statistical significance. GraphPad Prism version 8 (GraphPad Software, La Jolla, California) was used for statistical analysis, survival curve and spider plot generation.

3 | RESULTS

During the study period, a total of 43 dogs with sinonasal tumor were treated with IMRT/IGRT. Of these, 22 dogs met the inclusion criteria of this study. Three were golden retrievers, 3 were mixed breed dogs, 2 were west highland white terriers, 2 were schnauzers, 2 were Labradors, and 1 of each: Fox Terrier, Brittany Spaniel, Bearded Collie, Airedale, Jack Russel Terrier, Siberian Husky, Poodle, German Shepherd, Shih Tzu, and Daschund. Study subject characteristics are presented in Table 1. Prior to radiation, all 22 dogs had thoracic radiographs, 19 had an abdominal ultrasound with 2 dogs having an incidental finding of a splenic mass that was surgically removed prior to radiation and both were splenic hematoma. Twenty-one dogs had regional lymph node(s) investigated with fine needle aspirate cytology. Bilateral mandibular and retropharyngeal lymph nodes were sampled

FIGURE 6 Spider plots of GTV volumes after treatment for all dogs. Time 0 GTV was GTV before radiation treatments and all other GTV during follow-up were compared to this GTV. Each line is a dog, each point is an imaging GTV. Dotted line is from last imaging until death. † represents death. For dogs that are alive more than 18 months after RT, the number on the far right represent time of death in months from 1st RT. Underlined number is the censored dog. CR, complete response; GTV, gross tumor volume; PD, progressive disease; PR, partial response; RT, radiation therapy; SD, stable disease

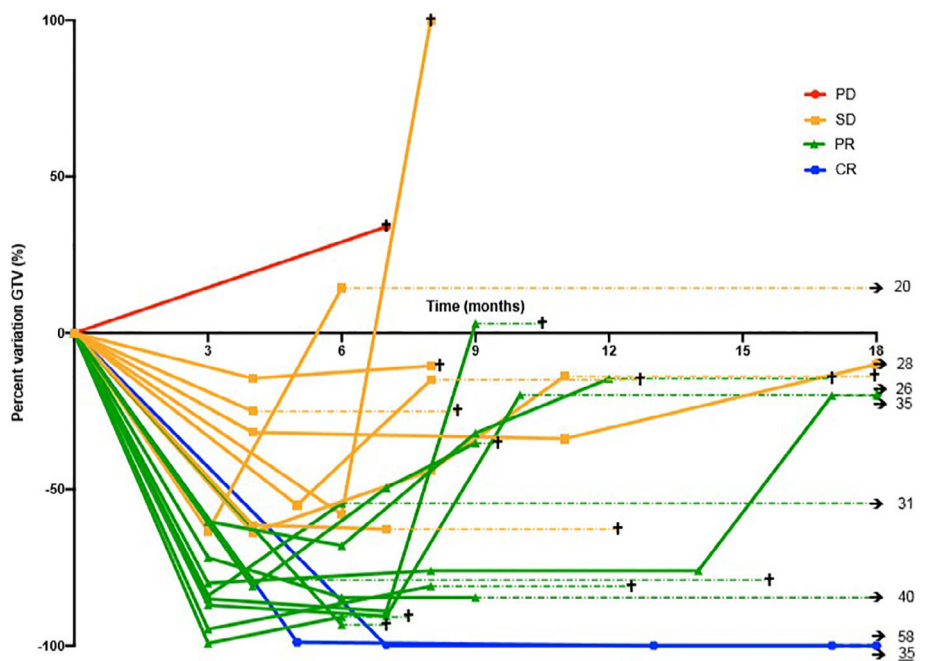


TABLE 3 Dog and tumor characteristics comparisons

Variable	PFS in days	P value (HR)	OS in days	P value (HR)
All cases (N = 22)	246 (95% CI: 202-313)		426 (95% CI: 250-780)	
GTV volume				
Above medium	231	.01	259	.004
Below medium	365	(HR 2.6; 95% CI: 1-6.6)	780	HR 3.2 (95% CI: 1.2-8.5)
Age				
Above median	232	.93	469	.77
Below median	259		383	
Histology				
Chondrosarcoma	300	.17	547	.82
Carcinoma	230		383	
Tumor stage				
1 (N = 7)	287	.18	847	.16
2 (N = 3)	285		512	
3 (N = 6)	261		573	
4 (N = 6)	217		255	
Response ^a				
SD (N = 8)	245		375	
PR (N = 11)	232	CR vs other 0.011	469	CR vs other 0.015
CR (N = 2)	1752	(HR 0.15; 95% CI: 0.05-0.39)	1752	(HR 0.15; 95% CI: 0.06-0.41)
PD (N = 1)	198		209	
Additional RT at progression				
Yes (N = 7)	NA	NA	847	.3
No (N = 15)			366	
Additional systemic Tx at progression				
Yes (N = 6)	NA	NA	379	.18
No (N = 16)			504	

Abbreviations: CR, complete response; HR, hazard ratio; NA, not available; OS, overall survival; PD, progressive disease; PFS, progression-free survival; PR, partial response; RT, radiation therapy; SD, stable disease; TX, treatment.

^aIf a difference found when multiple groups compared, individual groups compared against others, and reported.

in 16 dogs (in 8 dogs-1 or 2 lymph nodes cytology were non-diagnostic), bilateral mandibular lymph nodes were sampled in 2 dogs, the ipsilateral mandibular and retropharyngeal lymph node were sampled in 1 dog and 1 dog only had his ipsilateral mandibular lymph node sampled. Overall, only 1 dog with a nasal carcinoma was suspicious for nodal metastasis (ipsilateral retropharyngeal lymph node) and for this dog, all lymph nodes (bilateral mandibular and retropharyngeal lymph nodes) were treated with radiation. All other dogs did not have regional lymph nodes treated. Seventeen dogs received NSAID during or after RT. Seven dogs received NSAID for less than 2 months, 6 received NSAID for 2 to 6 months and 4 received NSAID for more than 6 months. The majority (15/17) received meloxicam (Metacam, Boehringer Ingelheim, Burlington, Ontario, Canada), 1 received robenacoxib (Onsior, Elanco [Novartis], Mississauga, Ontario, Canada), and 1 received deracoxib (Duramaxx, Elanco, Guelph, Ontario, Canada).

Radiation target volumes and dose statistics are presented in Table 2. Only 1 dog is alive without evidence of progression on CT scan at 35 months after RT and was censored from both analyses at that time point. All other dogs had died and were an event. One dog was euthanized because of pulmonary metastasis at day 210 after RT, 1 dog in complete remission at his last follow-up CBCT (18 months after RT) was euthanized because of age-related quality of life concerns (58 months after RT) whereas all other dogs (86%, 19/22) were euthanized because of confirmed or presumed local disease progression. Overall response rate based on imaging was 59% with 11 dogs achieving PR and 2 dogs achieving a CR. Progression was determined on imaging for 16 dogs (73%). The median PFS was 246 days (95% CI: 202-313 days; range, 178-1752 days) (Figure 3), the median OS was 426 days (95% CI: 250-780 days; range, 210-1752 days) (Figure 4). Six dogs received another course of radiation at PD (5 × 4 Gy [n = 5], 1 × 8 Gy [n = 1]) and 5 dogs received systemic treatment at PD

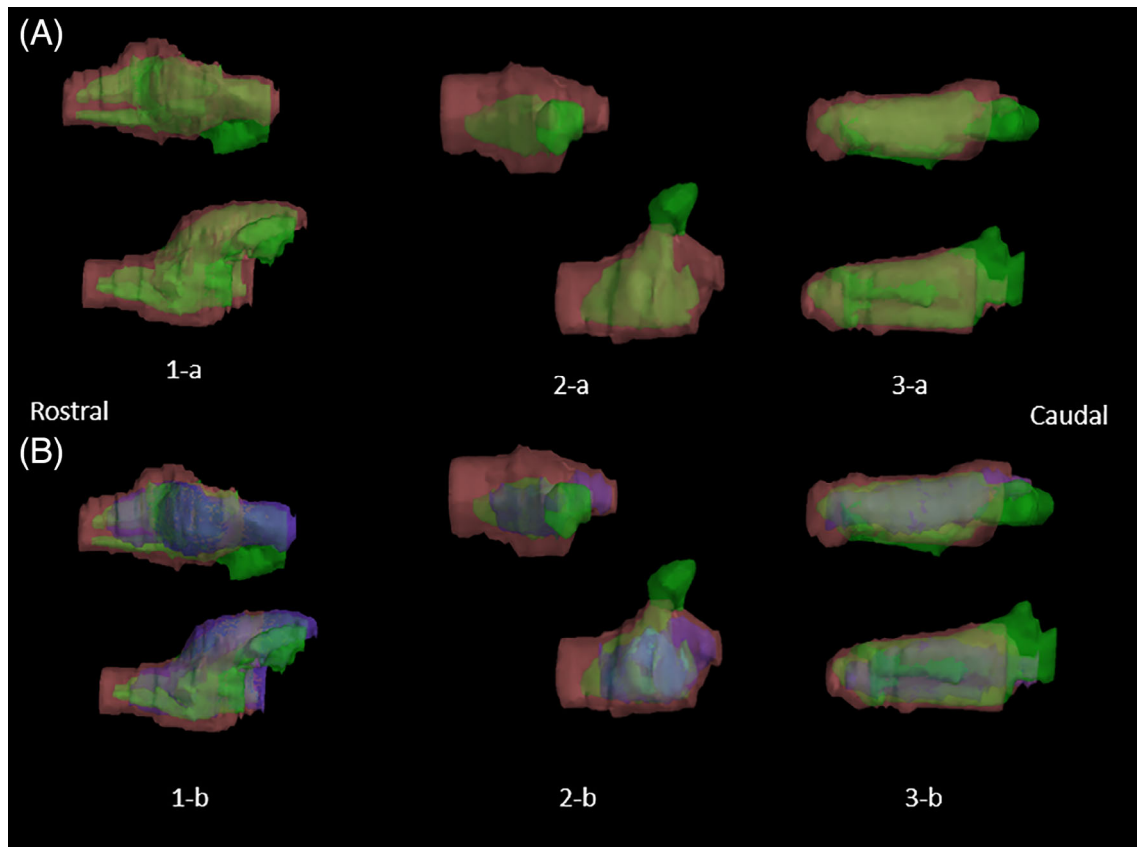


FIGURE 7 Three dimensional (3D) images (dorsal and lateral view) of the GTVf from 3 different dogs (caudal aspect to the left) with marginal failure. A, Green volume is the GTVf and pink volume is CTV. B, The blue volume is the original GTV and was added to the other 2 volumes. CTV, clinical target volume; GTV, gross tumor volume; GTVf, gross tumor volume failure; Figure 8. Dog with out of field recurrence (GTVf) 1-a CT transverse image, 1-b sagittal CT image prior to RT with all CBCT volumes superimposed (blue = original GTV, cyan = CBCT-3 month GTV, green = CBCT-6 months GTV, yellow = CBCT-9 month GTV, pink = CTV, Red = PTV) 2-a/2-b similar CT images at the time of recurrence 9 months after RT. 2-c/2-d 3D images of the GTVf (yellow volume), original GTV (blue volume) and the original CTV (pink volume). CBCT, cone beam computed tomography; CT, computed tomography scan; CTV, clinical target volume; GTV, gross tumor volume; GTVf, gross tumor volume failure; PTV, planned target volume; RT, radiation therapy

(palladia [n = 2], carboplatin [n = 1], carboplatin and palladia [n = 2]). The only variables that were predictive of PFS and OS were response and GTV size before treatment (< median: > median) (Figure 5). Age, weight, tumor histology, and tumor stage were not predictive of difference in PFS or OS and after PD treatment with RT and after PD treatment with systemic therapy were not prognostic for OS (Table 3).

A total of 52 follow-up CBCT/CTs were available for the 22 dogs (Figures 4 & 6). Overall, all dogs had a CBCT within 7 months of RT. Sixteen (72%) had a 3 to 4 months after RT CBCT, 18 (82%) had a 5 to 7 months after RT CBCT, 9 (41%) had a 9 to 10 months after RT CBCT, 5 (23%) had a 12 to 15 months after RT CBCT, and 4 (18%) had CBCT after 15 months.

At the 3 to 4 months CBCT follow-up, 56% (9/16) of the tumors imaged were in PR whereas 44% (7/16) were in SD. The 5 to 7 months CBCT follow-up revealed 6% (1/18) CR, 33% (6/18) PR, 22% (4/18) SD and 39% (7/18) PD. The 9 to 10 months CBCT follow-up showed 12% (1/8) CR, with the remaining 88% (7/8) being PD. Of the 12 to 15 months CBCT, 40% (2/5) were CR, 20% (1/5) were PR,

and 40% (2/5) were PD. Cone beam computed tomography performed at later dates were classified as “other” and 2 had PD at 17- and 20-months after RT whereas the other 3 CBCTs were from the 2 dogs in CR, 1 at 18 months and the other 1 at 17 and 35 months after RT. Overall, we had at least 1 GTVr for 20 dogs (91%) (the dog that achieved a CR and the dog with PD at first CBCT did not have a GTVr) and 1 GTVf for 16 dogs (72%).

The majority of the GTVr was located within the original GTV. The median D95 of GTVr was 99.3% (41.7 Gy) (range, 95.8%-106.2% [40.2-44.6 Gy]), the median D98 was 98.2% (41.2 Gy) (range, 94%-106% [39.5-44.5 Gy]), and the median D50 dose was 102.7% (43.1 Gy) (range, 98.9%-107.1% [41.3-44.5 Gy]).

The dosimetric analysis of the GTVf showed that 75% (12/16) of failures were classified as “in field,” 19% (3/16) of failures were “marginal” (D95 for these GTVf was 62.8% [26.38 Gy], 64.1% [26.92 Gy] and 73.4% [30.82 Gy]) (Figures 2 and 7, dog 7 and 8), and 7% (1/16) of failures were out-field (D95 was 1.8%) (Figure 8). The majority of GTVf were located in the caudal edge of the original GTV and all marginal failure occurred at the caudal aspect of the CTV (Figure 7).

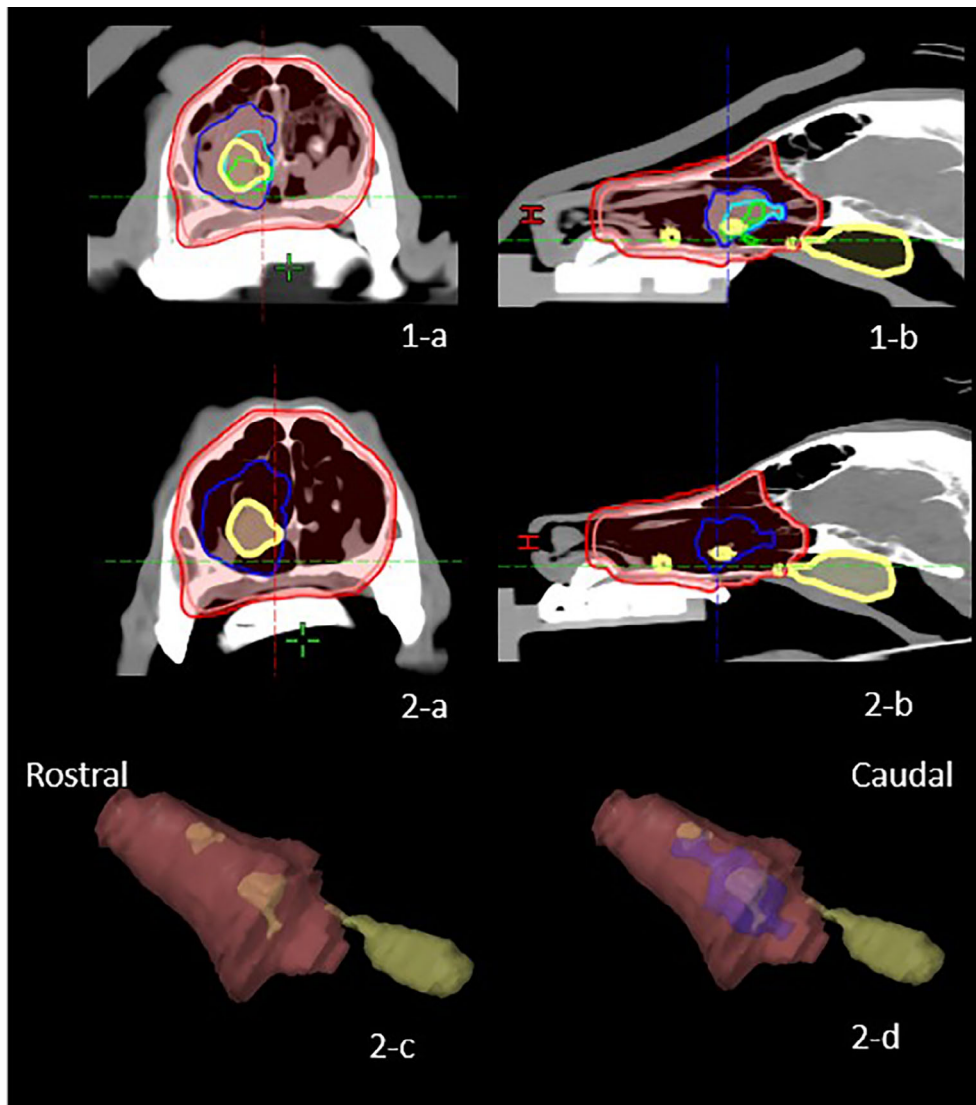


FIGURE 8 Dog with out of field recurrence (GTVf) 1-a CT transverse image, 1-b sagittal CT image prior to RT with all CBCT volumes superimposed (blue = original GTV, cyan = CBCT-3 month GTV, green = CBCT-6 months GTV, yellow = CBCT-9 month GTV, pink = CTV, Red = PTV) 2a/2b similar CT images at the time of recurrence 9 months after RT. 2-c/2-d 3D images of the GTVf (yellow volume), original GTV (blue volume), and the original CTV (pink volume). CBCT, cone beam computed tomography; CT, computed tomography scan; CTV, clinical target volume; GTV, gross tumor volume; GTVf, gross tumor volume failure; PTV, planned target volume; RT, radiation therapy

4 | DISCUSSION

In-field failures are the main patterns for local recurrence in our cohort of dogs with SNT confirming our hypothesis. The PFS of this cohort of dogs with SNT treated with IMRT/IGRT is similar to previous reports using 10 daily fractions of 4.2 Gy and follow-up imaging with a median PFS of 8.2 months (95% CI: 6.8-12 months). The original IMRT/IGRT study of 31 dogs reported a median PFS of 6.5 months (95% CI: 3.4-11.3 months)⁴ and the second report of 22 dogs¹⁴ (that did not include dogs with stage 4) reported a median PFS of 12.5 months and included a cohort of dogs treated with an integrated GTV boost dose to 50 Gy. The majority of progressions in this current cohort were determined based on imaging (16/22 [72%]) and in the majority of the cases, it took some time subjectively in the order of 2 to 3 months from the documented progression on imaging to the return of clinical signs suggesting that PFS based on clinical signs might overestimate the time to progression. Similarly, the median OS: 14.2 months (95% CI: 8.4-28 months), 32% alive at 2 years was similar to previously published cohort with this protocol. The original IMRT/IGRT study had a median

survival of 14 months⁴ (95% CI: 10.3-26 months) and the largest cohort of 40 dogs treated with cobalt 60 and 2-dimensional planning, had a median survival of 19.7 months.¹⁵ However, the large CI indicates the small and highly variable dataset. This current cohort of dogs is a fully mature dataset with no early censored dogs lost to follow-up and all dogs but 1 having a date of death.

Although tumor response was prognostic for PFS and OS, the number of dogs in each category was small. Similarly to another imaging follow-up study, smaller initial GTV volume was associated with more prolonged PFS and OS. The median GTV of the previous study was 40 cm³ whereas ours was 33.5 cm³. None of the other variables that demonstrated to be prognostic including tumor stage, reirradiation, and tumor histology³ were significant in the current cohort study, all of which can be a result of the small data set and low statistical power.

In this cohort of dogs, the GTV residual was mostly located within the original GTV and received an adequate dose of radiation, median D95 was 99.3%, the median D98 was 98.2% and median D50 was 102.7% indicating the presence of radioresistant tumor. The majority (12/16, 75%) of GTV failure were in-field. However, 3 dogs (19%) had

marginal failure indicating that a shrinkage of the CTV margins expansion inside the nasal cavity to less than 1 cm might not be advisable. We had 1 out of field recurrence and the presumed tumor progression was caudal to the CTV but the cranial tip of the GTVf could be tracked to the caudal aspect of the CTV.

The 2 dogs that achieved a long-lasting complete response were both diagnosed early in the course of their disease; 1 had 1 episode of epistaxis and the second 1 started snoring during the night and had the smallest tumors of 2.2 and 9.3 cm³.

The fact that we used noncontrast CBCT in the majority of dogs for follow-up tumor evaluation is a limitation because of the lower quality of the images compared to helical contrast-enhanced CT scan.^{17,18} The fact that noncontrast imaging was used in all but 5 follow-up imaging studies is also a limitation that could have made our GTV larger because of the inability to differentiate fluid versus mass. However, the CBCT was a kV CBCT that has been optimized by our medical physicists and with the air in the nasal passage providing contrast, we feel that it is a reasonable less expensive option that might enable more owners to pursue follow-up imaging. More than 50% (22/43) of the SNT treated had at least 1 follow-up CBCT and 86% (19/22) had >1 CBCT/CT.

In this cohort, a PTV expansion of 2 to 4 mm was used based on the immobilization device (Vak-lock, index bite block) and IGRT with kV CBCT being used. Two millimeter is considered a minimum PTV expansion based on the current veterinary literature.^{19,20} Once again, with a marginal recurrence of almost 20%, shrinking the PTV further would not be recommended pending further evaluation.

Interobserver variability in target contouring is an important consideration in assessing SNTs.²¹ This cohort was contoured by a single radiation oncologist eliminating the interobserver issue but this might limit the external validity of this study. Ideally, a standardized SNT contouring guideline should be developed in veterinary radiation oncology. Looking retrospectively at the original GTV/CTV contours, it is easy to imagine wide intraobserver variability, especially as contrast-enhanced CT scans might not always be sensitive to distinguish tumor versus fluid compared to MRI. To improve visualization of the GTV, MRI can be useful and a pilot study suggested improvement of GTV visualization, especially for stage 4 SNT.²² The use of MRI for target contouring of SNT needs further evaluation.

Target contouring of SNT for SRT techniques have smaller CTV and PTV expansions compared to those used in the current study. As an example, the most recent published study described the GTV as the contrast-enhancing mass on CT, no CTV expansion and a PTV expansion of 3 to 5 mm²³, whereas another paper described no CTV or PTV expansion and the GTV being everything abnormal on CT.²⁴ Finally, another paper described a 1 cm CTV expansion within the nasal cavity and 1 mm bone but did not use a PTV expansion.²⁵

The majority of recurrence being in-field provides evidence of radioresistant tumor volumes within the original GTV. One veterinary study attempted to characterize these subvolumes during radiation with PET-CT while boosting the GTV dose to 50 Gy in a cohort of dogs with SNT.¹⁴ The boost dose was not associated with a superior outcome in this small group of dogs; although, mid-treatment high

3'-deoxy-3'-18F-fluorothymidine (FLT) PET uptake (a marker of proliferation) was indicative of a poorer outcome.

Future studies to identify radioresistant subvolumes may shed light on methods to reduce in field recurrence. The use of radiation boost to increase the dose to the GTV is not new and was evaluated in the early 1990s in SNT in dogs before the technical advances we now apply and induces unacceptable acute adverse effects.²⁶ However, with new technology, further evaluation of GTV or GTVr boost might be useful and is currently being evaluated by several groups. With a marginal failure of close to 20%, it seems prudent to not use smaller than 1 cm CTV expansion within the nasal cavity and depending on the positioning device and positioning verification system used a smaller than 2 mm PTV expansion is not recommended and larger expansion could possibly be required as all marginal failures in this study occurred at the level of the 2 mm PTV expansion.

ACKNOWLEDGMENT

Funding provided partially by a Massey University summer student scholarship. Presented in part as an oral abstract at the Annual Meeting of the American College of Veterinary Radiology, Houston, Texas, October 2018.

CONFLICT OF INTEREST DECLARATION

Authors declare no conflict of interest.

OFF-LABEL ANTIMICROBIAL DECLARATION

Authors declare no off-label use of antimicrobials.

INSTITUTIONAL ANIMAL CARE AND USE COMMITTEE (IACUC) OR OTHER APPROVAL DECLARATION

Authors declare no IACUC or other approval was needed.

HUMAN ETHICS APPROVAL DECLARATION

Authors declare human ethics approval was not needed for this study.

ORCID

Valerie J. Poirier  <https://orcid.org/0000-0002-0170-3934>

REFERENCES

1. Kent MS, Turek MM, Farrelly J. Recent advances in veterinary radiation oncology. *Vet Comp Oncol*. 2018;16(2):167-169.
2. Nolan MW, Gieger TL. Update in veterinary radiation oncology: focus on stereotactic radiation therapy. *Vet Clin North Am Small Anim Pract*. 2019;49(5):933-947.
3. Larue SM, Gordon IK. Radiation oncology. In: Vail DM, Thamm D, Liptak J, eds. *Withrow and MacEwen's Small Animal Clinical Oncology*. St. Louis, Missouri: Elsevier Health Sciences; 2019:215-218.
4. Lawrence JA, Forrest LJ, Turek MM, et al. Proof of principle of ocular sparing in dogs with sinonasal tumors treated with intensity-modulated radiation therapy. *Vet Radio Ultrasound*. 2010;51(5):561-570.
5. Mortier JR, Blackwood L. Treatment of nasal tumours in dogs: a review. *J Small Anim Pract*. 2020;61(7):404-415.
6. ICRU Report 50. Prescribing, recording, and reporting photon beam therapy. International Commission on Radiation Units and Measurements; 1993.

7. ICRU Report 62. Prescribing, recording, and reporting photon beam therapy (Supplement to ICRU Report 50). International Commission on Radiation Units and Measurements; 1999.
8. Raktoc SAS, Dehnad H, Raaijmakers CPJ, et al. Origin of tumor recurrence after intensity modulated radiation therapy for oropharyngeal squamous cell carcinoma. *Int J Radiat Oncol Biol Phys*. 2013;85(1):136-141.
9. Almarzouki H, Niazi T, Hier M, et al. Local failure rate in oropharyngeal carcinoma patients treated with intensity-modulated radiotherapy without high-dose clinical target volume. *Cureus*. 2018;10(7):e2958.
10. Wiegner EA, Daly ME, Murphy JD, et al. Intensity-modulated radiotherapy for tumors of the nasal cavity and paranasal sinuses: clinical outcomes and patterns of failure. *Int J Radiat Oncol Biol Phys*. 2012;83(1):243-251.
11. Dawson LA, Anzai Y, Marsh L, et al. Patterns of local-regional recurrence following parotid-sparing conformal and segmental intensity-modulated radiotherapy for head and neck cancer. *Int J Radiat Oncol Biol Phys*. 2000;46(5):1117-1126.
12. Morgan MJ, Lurie DM, Villamil AJ. Evaluation of tumor volume reduction of nasal carcinomas versus sarcomas in dogs treated with definitive fractionated megavoltage radiation: 15 cases (2010-2016). *BMC Res Notes*. 2018;11(1):70.
13. Nell E, Ober C, Rendahl A, Forrest L, Lawrence J. Volumetric tumor response assessment is inefficient without overt clinical benefit compared to conventional, manual veterinary response assessment in canine nasal tumors. *Vet Radiol Ultrasound*. 2020;61(5):592-603.
14. Bradshaw TJ, Bowen SR, Deveau MA, et al. Molecular imaging biomarkers of resistance to radiation therapy for spontaneous nasal tumors in canines. *Int J Radiat Oncol Biol Phys*. 2015;91(4):787-795.
15. Adams WM, Bjorling DE, McAnulty JE, Green EM, Forrest LJ, Vail DM. Outcome of accelerated radiotherapy alone or accelerated radiotherapy followed by exenteration of the nasal cavity in dogs with intranasal neoplasia: 53 cases (1990-2002). *J Am Vet Med Assoc*. 2005;227(6):936-941.
16. Packer RA, Rossmel JH, Kent MS, Griffin JF 4th, Mazcko C, LeBlanc AK. Consensus recommendations on standardized magnetic resonance imaging protocols for multicenter canine brain tumor clinical trials [published correction appears in *Vet Radiol Ultrasound*. 2018 Nov;59(6):796]. *Vet Radiol Ultrasound*. 2018;59(3):261-271.
17. Soukup JW, Drees R, Koenig LJ, et al. Comparison of the diagnostic image quality of the canine maxillary dentoalveolar structures obtained by cone beam computed tomography and 64-multidetector row computed tomography. *J Vet Dent*. 2015;32(2):80-86.
18. Al Abduwani J, ZilinSkiene L, Colley S, Ahmed S. Cone beam CT paranasal sinuses versus standard multidetector and low dose multidetector CT studies. *Am J Otolaryngol*. 2016;37(1):59-64.
19. Kubicek LN, Seo S, Chappell RJ, Jeraj R, Forrest LJ. Helical tomotherapy setup variations in canine nasal tumor patients immobilized with a bite block. *Vet Radiol Ultrasound*. 2012;53(4):474-481.
20. Harmon J, Van Ufflen D, Larue S. Assessment of a radiotherapy patient cranial immobilization device using daily on-board kilovoltage imaging. *Vet Radiol Ultrasound*. 2009;50(2):230-234.
21. Christensen NI, Forrest LJ, White PJ, Henzler M, Turek MM. Single institution variability in intensity modulated radiation target delineation for canine nasal neoplasia. *Vet Radiol Ultrasound*. 2016;57(6):639-645.
22. Lux CN, Culp WTN, Johnson LR, et al. Prospective comparison of tumor staging using computed tomography versus magnetic resonance imaging findings in dogs with nasal neoplasia: a pilot study. *Vet Radiol Ultrasound*. 2017;58(3):315-325.
23. Mayer MN, DeWalt JO, Sidhu N, et al. Outcomes and adverse effects associated with stereotactic body radiation therapy in dogs with nasal tumors: 28 cases (2011-2016). *J Am Vet Med Assoc*. 2019 Mar 1;254(5):602-612.
24. Kubicek L, Milner R, An Q, et al. Outcomes and prognostic factors associated with canine sinonasal tumors treated with curative intert cone-based stereotactic radiosurgery (1999-2013). *Vet Radiol Ultrasound*. 2016;57(3):331-340.
25. Gieger TL, Nolan MW. Linac-based stereotactic radiation therapy for canine non-lymphomatous nasal tumours: 29 cases (2013-2016). *Vet Comp Oncol*. 2018;16(1):E68-E75.
26. Thrall DE, McEntee MC, Novotney C, et al. A boost technique for irradiation of malignant canine nasal tumors. *Vet Radiol Ultrasound*. 1993;34(4):295-300.

How to cite this article: Poirier VJ, Koh ESY, Darko J, Fleck A, Pinard C, Vail DM. Patterns of local residual disease and local failure after intensity modulated/image guided radiation therapy for sinonasal tumors in dogs. *J Vet Intern Med*. 2021; 35:1062-1072. <https://doi.org/10.1111/jvim.16076>