

Available online at www.sciencedirect.com

ScienceDirect

journal homepage: www.elsevier.com/locate/radcr

Case Report

Incidentally detected Non-Hodgkin's lymphoma of the breast. A case report with review of literature

Kalind Parashar, MD*, Pankaj Nepal, MD, Richard Assaker, MD, Jose Vargas, MD, Sarah Rosasco, MD

Radiology, St Vincent's Medical Center, Bridgeport, Bridgeport-06606, CT-United States

ARTICLE INFO

Article history:

Received 19 August 2020

Revised 31 October 2020

Accepted 2 November 2020

ABSTRACT

We report a case of primary breast lymphoma which was incidentally detected in a 71 year-old-female while investigating for pulmonary embolism with Computed tomography angiograph (CTA) of the chest. Primary breast lymphoma has no specific imaging features however may have better prognosis than breast carcinoma and management is non-surgical.

© 2020 Published by Elsevier Inc. on behalf of University of Washington.

This is an open access article under the CC BY-NC-ND license

(<http://creativecommons.org/licenses/by-nc-nd/4.0/>)

Introduction

Primary lymphoma of the breast is rare, representing less than 1% of all breast malignancies [1,2]. Overall, secondary lymphomas of the breast are also rare, but represent the largest group of tumors metastasizing to the breast. Most common subtypes of primary breast lymphoma include diffuse large B-cell (DLBC), Burkitt/Burkitt-type, and mucosa-associated lymphoid tissue (MALT) type lymphomas [1,2]. The most common clinical presentation of breast lymphoma is a painless unilateral palpable breast mass. Approximately 10% of the patients may present with bilateral breast masses at the time of diagnosis [1]. In a rare event, Burkitt-type lymphoma may present in young women during pregnancy or postpartum, with rapidly enlarging bilateral breast masses. Imaging manifestations of primary breast lymphoma are variable and multimodality imaging is usually necessary; however, findings

such as solitary mass with well-defined margins, lack of calcifications, and absence of distortion of the normal breast parenchyma should raise the suspicion [1,2]. We present an interesting case of a 71-year-old female who was incidentally found to have a breast mass, which was biopsied after appropriate testing, and pathology confirmed Non-Hodgkin's lymphoma (NHL).

Case report

71 year-old-female with hypothyroidism and no other comorbidities, presented to the Emergency department with sudden development of shortness of breath. Physical examination was remarkable for tachypnea (respiratory rate -25/min) and tachycardia (heart rate 100 bpm). She was afebrile and

* Corresponding author. (K. Parashar)

E-mail address: drkalind@gmail.com (K. Parashar).

<https://doi.org/10.1016/j.radcr.2020.11.009>

1930-0433/© 2020 Published by Elsevier Inc. on behalf of University of Washington. This is an open access article under the CC BY-NC-ND license (<http://creativecommons.org/licenses/by-nc-nd/4.0/>)

normotensive. She denied cough, hemoptysis, leg swelling or orthopnea. She underwent a Computed tomography angiography (CTA) of the chest which confirmed a nonocclusive filling defect in the right lower lobe segmental branch of pulmonary artery consistent pulmonary embolism. In addition, the CTA showed a 2.0×2.6 cm asymmetric soft tissue in the superomedial aspect of the right breast at 2 o'clock position. Further evaluation with mammogram and ultrasound was recommended.

Patient underwent digital breast tomosynthesis (DBT) mammography, which revealed approximately 2.5 cm oval, high density mass with obscured margins. Simultaneously acquired targeted breast ultrasound identified a solid, heterogeneous mass with mostly well-defined margins at 2 o'clock position, 5 cm from the nipple. On color Doppler interrogation, internal vascularity was identified. The mass measured $2.2 \times 2.6 \times 1.1$ cm and corresponded to the findings on CT and mammography. Mass was suspicious for neoplasm (BIRADS 4), and ultrasound-guided core biopsy was recommended. A vacuum assisted biopsy of the mass was performed under ultrasound guidance. With 12-Gauze vacuum assisted device, six cores were obtained and specimens sent in formalin. On histopathology, micro-morphology and immunohistochemistry findings were consistent with the diagnosis of non-Hodgkin B-cell lymphoma with plasma cell differentiation, including extranodal marginal zone lymphoma, mucosa-associated lymphoid tissue (MALT) lymphoma, and lymphoplasmacytic lymphoma. No definite Reed-Sternberg cells were identified. Fluorescence in situ hybridization (FISH) was negative for t (11; 14), t (14; 18), ALK, BCL6, MYC rearrangements, and MYC amplification. MYD88 mutation was not detected. B-cell gene rearrangements were detected.

The patient was then evaluated with FDG-PET/CT scan for initial staging. FDG uptake was noted in the right breast mass with maximum standard uptake value (SUV max) of 3.2. An additional focus of FDG uptake was noted in para-aortic lymph nodes measuring up to 1cm (SUV max 2.9). There were no significantly enlarged or FDG avid axillary, hilar, or mediastinal lymph nodes. Two additional areas of FDG uptake were also present within the marrow of mid shaft of left femur (SUV max 3.2). Patient was on anti-coagulant for pulmonary embolism. Biopsy of the left femur was planned after stopping anticoagulants, but was difficult considering her performance status. Radiation oncologist planned for local radiotherapy of the right breast with 3060 cGy to the right breast in 180 cGy daily fractions, but the patient was hospitalized due to urosepsis. Recently biopsy of left femur was performed, which was positive for NHL infiltration. Further, treatment plan will follow her oncology clinic appointment.

Discussion

Primary breast lymphoma (PBL) is a rare malignancy arising in the breast without evidence of systemic disease as opposed to secondary breast lymphoma (SBL) which is the most common metastasis to the breast. PBL accounts for less than 1% of all breast tumors and approximately 2% of extranodal NHLs [3].

DLBC- NHL is the most common histopathological subtype of PBL, followed by follicular and MALT- lymphomas [3–5]. Breast involvement with Hodgkin's disease or T-cell lymphomas is very rare [6]. Lymphoma arising from the breast occurs almost exclusively in women [7]. Some studies have proposed probable relation to estrogen for this occurrence. Smaller series have reported that lymphoma arising from the breast occurs more commonly in the right breast [7]. The rarity of this cancer is because the breast contains less lymphoid tissue than other organs, such as the intestines and lungs, where primary lymphomas are more common [8].

Most patients with PBL present in their fifth or sixth decade of life with a painless palpable breast mass that may or may not be accompanied by axillary lymph nodes. The usual type B symptoms seen with lymphomas like fever, weight loss, and night sweats are very rare with PBL [6]. The imaging characteristics of PBL are nonspecific and resemble any other malignant and even benign breast tumors. The commonest mammographic finding is a single non calcified breast mass that is circumscribed or may have indistinct margins [6]. PBL have absence of calcifications, nipple retraction, or architectural distortion. Global asymmetry is another presentation of PBL which is detected by mammography in one-third of the PBL patients. Most patients with primary lymphoma of the breast develop distant disease to other regions [9]. On ultrasound, one 1 or more hypoechoic round or oval masse can be seen with or without posterior acoustic enhancement. On MRI, most common shape of the mass is oval (up to 87%), and the most common type of margin type is irregular (2/3rd) [1]. Positron emission tomography (PET) with 2-deoxy-2-[fluorine-18] fluoro-D-glucose (^{18}F -FDG) has a definitive role in every step of management of PBL, including diagnosis, staging, evaluation of treatment response, and detection of recurrence. Increased FDG uptake on PET/CT can be focal or diffuse depending on the involvement of the breast. Due to high tumor cellularity, FDG uptake is usually intense [10]. However, the activity of low-grade indolent breast lymphoma is not established. Our patient had B-cell marginal zone or MALT NHL, and FDG activity was only mildly elevated (SUVmax 3.2). Other advantage of FDG-PET is that increased breast density does not affect its accuracy in diagnosing malignant breast tumors [10].

Wiseman and Liao established the diagnostic criteria for primary lymphoma of the mammary gland in 1972. They were subsequently revised by Hugh et al. in 1990, and consist of:

1. The clinical location of presentation is the breast.
2. A previous history of lymphoma or indication of widespread disease are absent at diagnosis.
3. In pathologic specimen, lymphoma is recognized with close association to breast tissue.
4. Ipsilateral lymph nodes may be involved if they develop simultaneously with the primary breast tumor [11].

[Figs. 1–4](#)

The management strategies for PBL vary broadly, from surgical intervention to combination chemotherapy and radiotherapy. However, there is no up to date standard guideline for PBL treatment. Mastectomy for PBL is not well-supported because of no survival benefits or risk of recurrence. Several studies have recommended that surgery should be offered

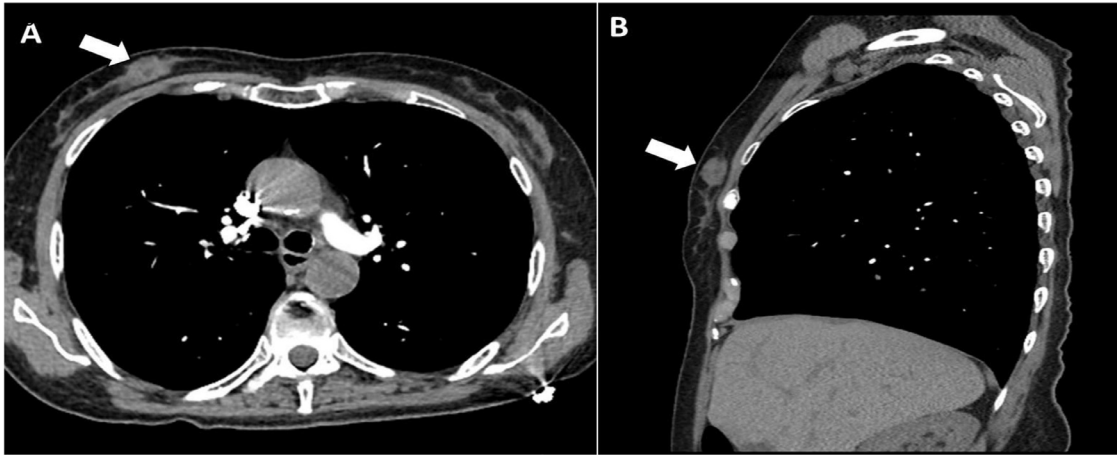


Fig. 1 – Axial (A) and sagittal (B) CT angiography (CTA) images of the chest performed to rule out pulmonary embolism, incidentally detected approximately 2.5 cm asymmetric soft tissue mass in the superomedial aspect of the right breast (arrows).

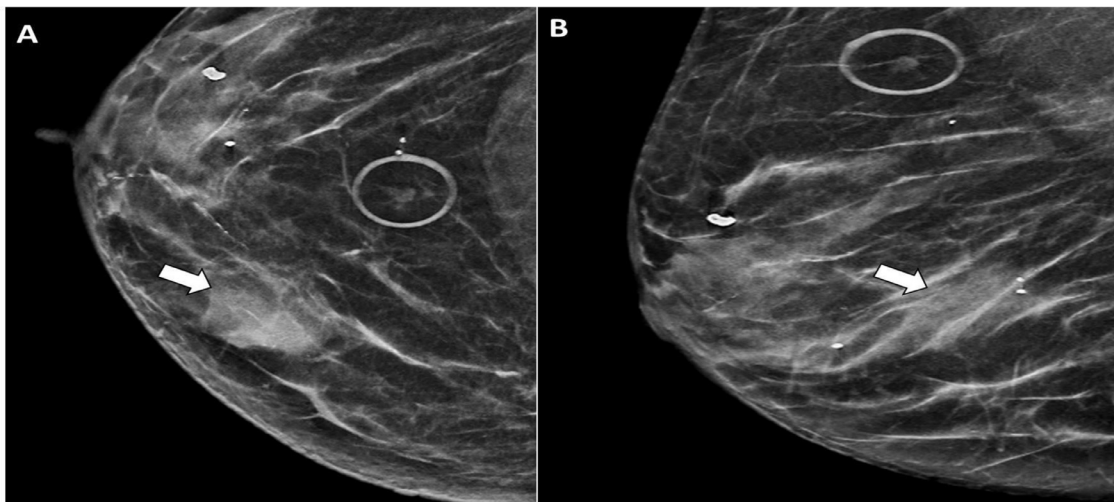


Fig. 2 – Craniocaudal (A) and mediolateral (B) mammography images of the right breast synthesized from digital breast tomosynthesis (DBT) revealed an oval, high density mass with obscured margins (arrows) which corresponded to CTA findings.

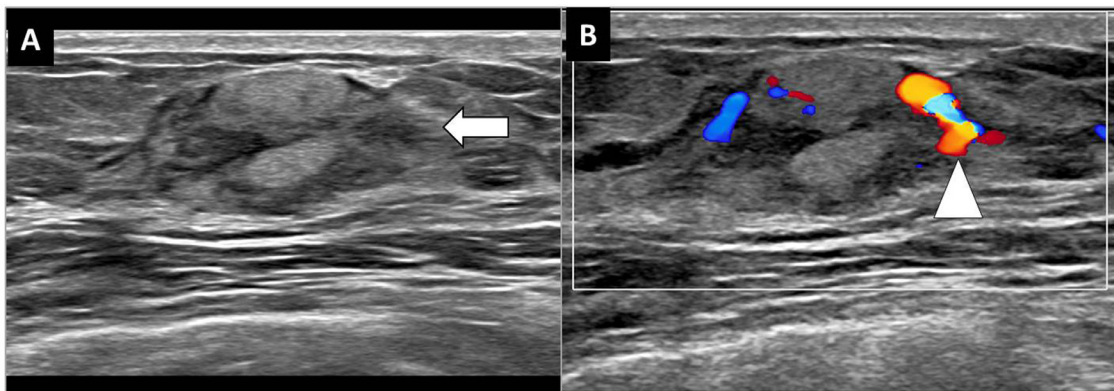


Fig. 3 – (A) Greyscale ultrasound image of the right breast shows an oval, heterogeneous solid mass, with mostly well-defined and peripherally indistinct margins (arrow) in the right breast at 2 o'clock axis, 5 cm from the nipple. (B) Color Doppler shows mass has internal vascularity (arrowhead).

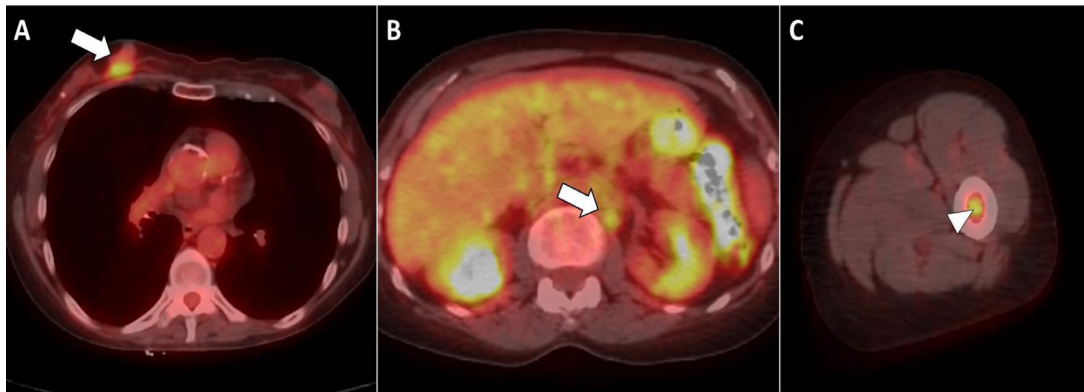


Fig. 4 – FDG-PET/CT study for initial staging of lymphoma. (A) Axial image at the level of the right breast mass shows uptake with SUV max 3.2 (arrow). (B) Additional focus of uptake noted in left paraortic lymph node measuring 1 cm with SUV max 2.9 (arrow). (C) Focal uptake also noted in bone marrow of the mid shaft of the left femur with SUV max 3.2 (arrowhead).

for diagnosis only and that minimally invasive surgery is the preferable option because extensive surgery may carry a high risk of morbidity. In addition, axillary dissection adds no therapeutic advantage [12]. Regarding prognosis, DLBC- NHL is the most common type of PBL, which tends to grow quickly, therefore prompt treatment is indicated. Treatment strategies for low grade PBL is not established and differs in different institutions utilizing chemotherapy, surgery or radiation. Prognosis of patients with breast lymphoma can range from 26 and 66% for 5-year survival rates and DLBC type has worse prognosis than other histologic subtypes with significant risk of contralateral breast involvement [13]. Low-grade B-cell lymphoma such as MALT lymphoma, follicular lymphoma, or small lymphocytic lymphoma tend to grow slowly and may be amenable to active surveillance alone. For secondary lymphoma involving the breast, the prognosis is dependent on the stage of the primary malignancy.

Although our case was a that of a PBL, it is important to keep in mind the SBL as well which is the most common metastasis to the breast. SBL usually presents later in life in the 6th or 7th decade of life. There are no imaging features to differentiate between the PBL and SBL however if a patient has known lymphoma, findings of multiple breast masses on imaging with or without axillary lymphadenopathy or an inflammatory-like appearance such skin thickening without a mass point to a high likelihood of SBL [14].

Conclusion

This is an atypical case of incidentally detected breast lymphoma with no presenting complains. Screening and diagnosis of PBL based on advanced radiological investigations are valuable for identification of this rare neoplasm. This case report can help in clinicians become more aware of this pathology which can lead to early diagnosis, appropriate treatment and favorable outcomes of breast lymphoma.

REFERENCES

- [1] Gluskin J, D'Alessio D, Kim AC, Morris EA, Chiu A, Noy A. Primary lymphoma of the breast: A report of two cases. *Clin Imaging* 2020 Aug 26;68:295–9 Epub ahead of print. PMID: 32961512. doi:10.1016/j.clinimag.2020.08.008.
- [2] Sabaté JM, Gómez A, Torrubia S, Camins A, Roson N, De Las Heras P, et al. Lymphoma of the breast: clinical and radiologic features with pathologic correlation in 28 patients. *Breast J* 2002;8(5):294–304. doi:10.1046/j.1524-4741.2002.08509.x.
- [3] Pruthi S, Stafyla VK, Phillips SW, Porrata LF, Reynolds CA. Primary mammary (non-Hodgkin) lymphoma presenting as locally advanced breast cancer. *Mayo Clin Proc* 2004;79:1310–14.
- [4] Gupta V, Bhutani N, Singh S, Chhabra S, Sen R. Primary non-Hodgkin's lymphoma of breast—A rare cause of breast lump. *Human Pathology: Case Reports* 2017;7:47–50.
- [5] Jabbour G, El-Mabrok G, Al-Thani H, El-Menyar A, Al Hijji I, Napaki S. Primary breast lymphoma in a woman: a case report and review of the literature. *Am J Case Rep* 2016;17:97–103.
- [6] Thomas A, Link BK, Altekruze S, Romitti PA, Schroeder MC. Primary breast lymphoma in the United States: 1975–2013. *J Natl Cancer Inst* 2017;109:294.
- [7] Harb OA, Balata SA, Ashour H, Eltokhy E, Gertallah LM, Ahmed RZ, Hassanin AM. Primary diffuse large B-cell non-Hodgkin's lymphoma of the breast—A case report and review of the literature. *Radiol Case Rep* 2018;14:22–7.
- [8] Nisar U, Khan M, Nisar S, Khan S. Primary breast lymphoma with unconventional presentation: a case report. *J Leuk* 2017;5:238. doi:10.4172/2329-6917.1000238.
- [9] Garg NK, Bagul NB, Rubin G, Shah EF. Primary lymphoma of the breast involving both axillae with bilateral breast carcinoma. *World J Surg Oncol* 2008;6:52.
- [10] Kumar R, Xiu Y, Dhurairaj T, Yu JQ, Alavi A, Zhuang H. F-18 FDG positron emission tomography in non-Hodgkin lymphoma of the breast. *Clin Nucl Med* Apr 2005;30(4):246–8. doi:10.1097/01.rlu.0000156374.64813.09.
- [11] Yhim HY, Kang HJ, Choi YH, Kim SJ, Kim WS, Chae YS, et al. Clinical outcomes and prognostic factors in patients with breast diffuse large B cell lymphoma; Consortium for Improving Survival of Lymphoma (CISL) study. *BMC Cancer* 2010;10:321.

-
- [12] Lee KC, Lee SH, Sung K, Ahn SH, Choi JY, Lee SH, et al. A case of primary breast diffuse large B-cell lymphoma treated with chemotherapy followed by elective field radiation therapy: a brief treatment pattern review from a radiation oncologist's point of view. *Case Rep Oncol Med* 2015;2015:907978.
- [13] Anne N, Pallapothu R. Lymphoma of the breast: a mimic of inflammatory breast cancer. *World J Surg Oncol* 2011;9:125. Published 2011 Oct 11. doi:10.1186/1477-7819-9-125.
- [14] Raj SD, Shurafa M, Shah Z, Raj KM, Fishman MDC, Dialani VM. Primary and secondary breast lymphoma: clinical, pathologic, and multimodality imaging review. *Radiographics* 2019;39(3):610–25. doi:10.1148/rg.2019180097.