

## CASE REPORT

# Cardiac hydatid cyst in left ventricular free wall

Shreya Ohri MD, Ankush Sachdeva MD FNICI<sup>1</sup>, Mona Bhatia MD FRIC<sup>1</sup> and Sameer Shrivastava MD DM (Cardiology)<sup>1</sup>

First Cardiology Clinic, University Hospital 'Dr G. Stranski' Pleven, Street Georgi Kochev 8A, Pleven 5800, Bulgaria

<sup>1</sup>Fortis Escorts Heart Institute, Okhla, New Delhi, India

Correspondence should be addressed to S Ohri  
**Email**  
drshreya.ohri@gmail.com

## Summary

We report a rare case of a cardiac hydatid cyst that was incidentally found during routine work up for a redo-CABG and was picked up on echocardiography and confirmed by magnetic resonance imaging and, after successful removal, further confirmed by histopathology. The report emphasizes the importance of early and urgent surgery for such cardiac hydatid cysts whenever discovered to prevent fatal and unexpected death. Cardiac hydatidosis is a most infrequent type, in comparison with hydatidosis of the liver (65%) and lung (25%).

### Learning points:

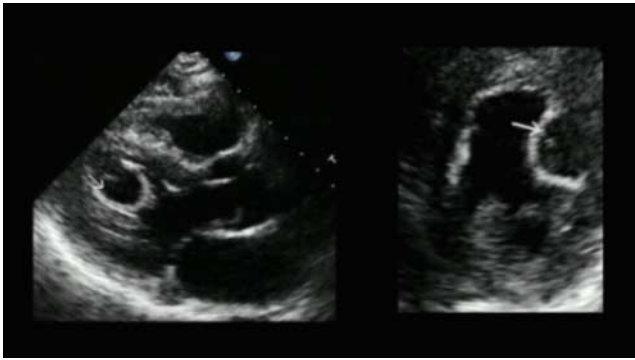
- Hydatidosis or cystic echinococcosis is caused by infection with the metacestode stage of the tapeworm *Echinococcus* (family Taeniidae). The adult tapeworm is usually found in dogs or other canines; the tapeworm eggs are expelled in the animal's feces and humans become infected after ingestion of the eggs. The initial phase of primary infection is asymptomatic.
- Cardiac hydatidosis is extremely rare, more commonly the liver and lungs are affected.
- Morbidity from heart echinococcosis in men is three times higher than that in women. Solitary cysts occur in almost 60% of the cases; the most frequent location is the ventricular myocardium and they are usually subepicardially located, hence they rarely rupture in the pericardial space. The left ventricle is damaged twofold to threefold more frequently than the right one.
- The diagnosis of echinococcosis in heart can be divided into two steps: detection of the cyst and its identification as echinococcus. It is based on serological reactions, echocardiography, X-ray, computerized tomography, and/or magnetic resonance imaging.
- The most dangerous complication of cardiac echinococcosis is cyst perforation. After cyst perforation three quarters of the patients die from septic shock or embolic complications.
- It is very important to understand that chemotherapy may lead to cyst death, and destruction of its wall and result in cyst rupture. Therefore, no germicide must be administered before surgical removal.

## Background

Cardiac hydatid cyst is a medical emergency. Rapid diagnosis must be performed using various imaging modalities with early surgical and pharmacological treatment of suspicious cystic masses, especially in endemic areas. Increased awareness is essential amongst cardiac physicians and diagnosticians (1).

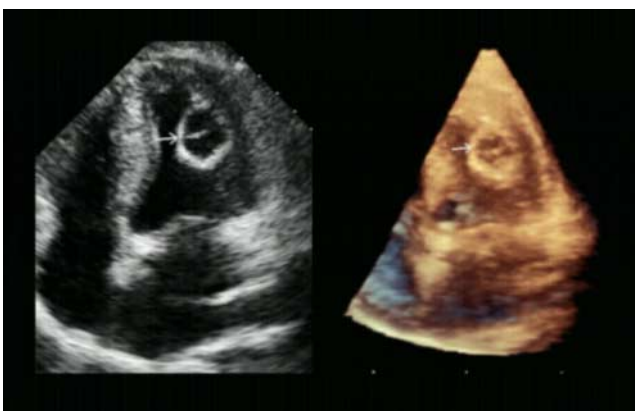## Case presentation and investigations

A 67-year-old male patient who had undergone CABG in the year 2003 was admitted with complaints of chest heaviness on exertion for the preceding few weeks. The patient underwent a stress test, which was positive for reversible myocardial ischemia. Subsequently, a coronary angiogram was done, which showed a 90–95% stenosis distal to the left

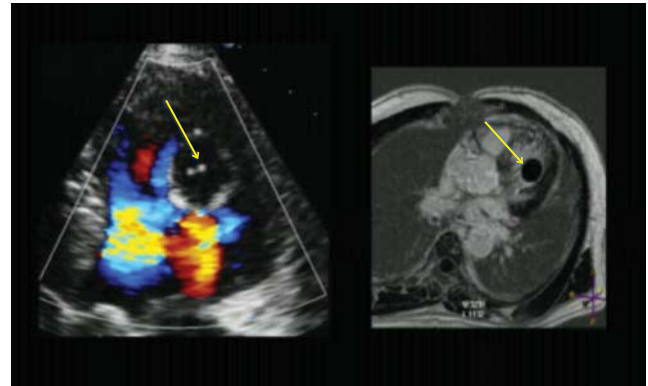


**Figure 1**  
Echo images showing a left ventricular cavity cyst attached to the posterolateral wall in parasternal long- and short-axis views (arrow) respectively.

internal mammary artery-to-left anterior descending artery graft anastomosis graft anastomosis. During the routine work up for a redo-CABG, echocardiography showed the presence of an intramural cystic mass ( $2.3 \times 2.1$  cm) attached to the posterolateral wall of the left ventricular cavity (Fig 1). On Doppler echocardiography no color flow was observed within the cystic cavity. Cardiac magnetic resonance imaging (MRI) was performed to further evaluate the single cyst and rule out other possible differential diagnosis, such as a simple post-infarction blood-filled cyst, etc. The MRI confirmed the diagnosis, which implied that the treatment of choice was urgent surgical cystectomy with cardiopulmonary bypass. A serological test was performed for specific echinococcus antibodies along with routine hematology and biochemistry. Ultrasound, chest X-ray, and remaining body scans were shown to be negative for involvement of other organs in the echinococcus infection. While the serology revealed equivocal results,



**Figure 2**  
2D and 3D echo images showing left ventricular cavity cyst (arrow) inseparable from the lateral wall in an apical four-chamber view.

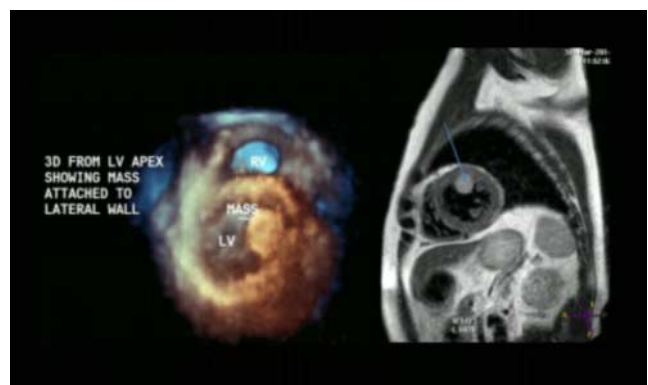


**Figure 3**  
Images showing no color flow in the cyst cavity on 2D echocardiography (arrow) and cardiac MRI showing a left ventricular cavity cyst embedded in the lateral wall (arrow) respectively.

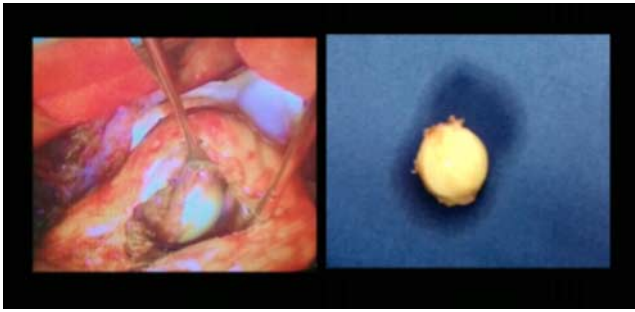
the cardiac MRI showed a  $2.2 \times 2.1$  cm well-encapsulated lesion medial to the anterior papillary muscle, occupying the left ventricular intracavitary space and inseparable from the underlying endocardium. The lesion appeared hypo- to iso-intense on T1W1 images and had no post-contrast enhancement. The patient was posted for early CABG and left ventricular cyst removal (Figs 2 and 3).

### Treatment and follow-up

After the redo-CABG, ventriculotomy was performed with a cardiopulmonary bypass pump, and the intracavitary cystic mass, identified to be similar in size on both echocardiography and MRI, attached to the lateral wall of the left ventricle was successfully removed. The patient had an unremarkable post-operative course and was discharged after a week staying on treatment with Albendazole 400 mg twice



**Figure 4**  
Comparative images of 3D full-volume and cardiac MRI showing the left ventricular cyst (arrow) embedded in the lateral wall.



**Figure 5**  
Intra and post-operative images of the gross appearance of the hydatid cyst.

daily *per os* for a period of 6 months, administered in cycles for of 3 weeks followed by 1 week of respite (in order to avoid toxicity), along with other drugs for coronary artery disease management. The patient was advised for timely follow-up to look for any reoccurrences in future (Figs 4 and 5).

## Discussion

The incidence of left ventricular invasion by echinococcus is 55–60% as it has the maximum myocardial mass and abundant blood supply the incidence of involvement of the interventricular septum is 5–9% of cases. The right ventricle is involved in 15% of cases, while the right atrium is involved in 3–4% of cases (2). Distribution in pulmonary artery, left atrium, and pericardium is up to 7–8% (3). There are no age limits to the presentation and such cysts can cause obstruction in outflow tract, valves, and chambers of the heart, and can induce conduction disturbances such as atrioventricular nodal blocks, ventricular tachycardia and fibrillation, or cardiac tamponade, or can be completely asymptomatic (4). Pulmonary embolism, anaphylactic shock, and systemic metastasis are some more important and catastrophic complications of cardiac hydatid cysts. Left ventricular hydatid cyst are usually located subpericardially and rarely rupture into the pericardial space. The risks of surgery involve leakage of fluid from the cyst cavity leading to anaphylaxis

and dissemination of infected scolices, which can be minimized by using scolicidal solutions such as iodine, hypertonic saline, methylene blue, or ethanol (5).

### Declaration of interest

The authors declare that there is no conflict of interest that could be perceived as prejudicing the impartiality of the research reported.

### Funding

This research did not receive any specific grant from any funding agency in the public, commercial or not-for-profit sector.

### Patient consent

This is to confirm that written informed consent has been obtained from the patient for publication of the submitted article and accompanying images.

### Author contribution statement

S Ohri and A Sachdeva were involved in obtaining the echocardiography images and in the clinical management of the patient under the supervision of S Shrivastava and M Bhatia – Head of Department of Cardiac MRI and CT – who was responsible for interpretation of the MRI used for establishing the diagnosis.

## References

- 1 Tuncer E, Tas SG, Mataraci I, Turner A, Donmez AA, Aksut M & Yakut C 2010 Surgical treatment of cardiac hydatid disease in 13 patients. *Texas Heart Institute Journal* **37** 189–193.
- 2 Maroto LC, Carrascal Y, López MJ, Forteza A, Pérez A & Zavarella C 1998 Hydatid cyst of the interventricular septum in a 3.5-year-old child. *Annals of Thoracic Surgery* **66** 2110–2111. (doi:10.1016/S0003-4975(98)01079-0)
- 3 Shevchenko YL, Travin NO, Musaev GH & Morozov AV 2006 Heart echinococcosis: current problems and surgical treatment. *Multimedia Manual of Cardiothoracic Surgery* **2006** 810. (doi:10.1510/mmcts.2005.001115)
- 4 Di Bello R & Menendez H 1963 Intracardiac rupture of hydatid cysts of the heart. A study based on three personal observations and 101 cases in the world literature. *Circulation* **27** 366–374. (doi:10.1161/01.CIR.27.3.366)
- 5 Shehatha J, Alward M, Saxena P & Konstantinov IE 2009 Surgical management of cardiac hydatidosis. *Texas Heart Institute Journal* **36** 72–73.

Received in final form 21 January 2015

Accepted 26 January 2015