

Lipoid proteinosis: A review with two case reports

VISHAL KABRE, SMITHA RANI, KEERTHILATHA M. PAI, SAKSHI KAMRA

Abstract

Lipoid proteinosis (LP) is a rare autosomal recessive genodermatosis characterized by deposition of amorphous hyaline material in different parts of the body, especially the skin, mucous membranes of the upper aerodigestive tract, and internal organs. Oral cavity is most extensively affected area by the disease. This paper reports two classic cases of LP with oral manifestations but without a history of consanguinity along with a concise review of the literature on the disease.

Keywords: Collagen disorder, extracellular matrix protein 1, genodermatosis, lipoid proteinosis

Introduction

Lipoid proteinosis (LP) is a very rare autosomal recessive genodermatosis whose true incidence is not known. It was first described by Siebenmann in 1908^[1] and the first case series as “lipoidosis cutis et mucosae” was presented by a Viennese dermatologist, Urbach and an otorhinolaryngologist, Weithe in 1929.^[2] Later was renamed by Urbach in 1930 as “LP cutis et mucosae.” It has been known by several terms such as “Urbach–Weithe disease,” “lipoglycoproteinosis,” “lipid proteinosis,” and “hyalinosis cutis et mucosae.” More than 300 cases have been reported in the world literature so far.^[3] The disease is characterized by the deposition of an amorphous hyaline material in the skin, mucosa, and viscera, classically manifesting as hoarseness of voice during infancy and consequently involving skin, mucosa, and any organ.^[3] The disease is slowly progressive having a benign course. Recently, loss of function mutations in the gene encoding extracellular matrix protein 1 (ECM1) on band 1q21 has been identified as the cause of LP.^[4] Histopathological examination shows epidermis with hyperkeratosis, focal parakeratosis, acanthosis, papillomatosis, and elongated rete ridges overlying. Superficial dermis showed deposition of dense

eosinophilic material oriented perpendicular to epidermis and forming thick perivascular mantles around blood vessels.

Previous studies have attributed the prevalence of LP to consanguineous parents. Here, we report oral and clinical manifestations of two young adults diagnosed with LP but without consanguinity among parents along with a concise review of the literature on the disease.

Case Reports

Case report 1

A 19-year-old male reported to our department with a complaint of multiple large ulcerations on his tongue since 1-week with associated burning sensation and fever. There were no previous episodes of similar ulcerations in the oral cavity. He gave the history of hoarseness of voice, alopecia, cracked skin over soles of the feet, repeated vomiting, and loose stools since childhood. Extraoral examination showed multiple ulcerations with discharge over both upper limbs. There were multiple nonpruritic yellowish papules and warty lesions on the neck. Right submandibular lymphadenopathy was present. Intraoral examination revealed multiple nontender ulcerations covered with slough measuring about 1–1.5 cm [Figure 1]. Entire floor of the mouth, palate and bilateral buccal mucosa were coated with scrapable curdy white patches. All second premolars were missing along with retained 53, 82, 83, and supernumerary tooth between 14 and 16 were noticed. Skin biopsy confirmed to be of LP. Radiographic examination showed no evidence of any calcifications.

Blood investigations revealed leukocytosis with increased monocytes (12.8%). Serum iron level was slightly low (36 µg/dL), with raised total iron binding capacity (471 µg/dL). Folate levels were also increased (>20 ng/dL).

Patient was a known case of LP, the facial and oral findings were considered to be due to the same condition. An additional diagnosis of pseudomembranous candidiasis was also given.

Department of Oral Medicine and Radiology, Manipal College of Dental Sciences, Manipal University, Manipal, Karnataka, India

Correspondence: Dr. Sakshi Kamra,
Department of Oral Medicine and Radiology, Manipal College of Dental Sciences, Manipal University, Manipal, Karnataka, India.
E-mail: sakshi_tis2006@yahoo.co.in

Access this article online	
Quick Response Code:	Website: www.contempclindent.org
	DOI: 10.4103/0976-237X.156053

The treatment plan for the patient included debridement with hydrogen peroxide and betadine solution under topical LA. Patient was instructed to maintain good oral hygiene and follow liquid diet till the ulcers heal. Antiseptic mouthwash and 1% clotrimazole mouth paint were prescribed. Debridement was carried out for the next 4 days, and healing of tongue ulcers was appreciated on the last visit.

Case report 2

An 11-year-old boy reported with a complaint of multiple ulcers on the tongue and hoarseness of voice since 6 months of age with similar ulcerations on bilateral buccal mucosa in the past and was associated with recurrent throat pain and dysphagia from past 2 to 3 years. He also had recurrent episodes of cough, cold and fever occurring once every month.

On general examination, multiple shiny skin-colored papules were present over forehead, nose and malar region in a background of thickened waxy skin with few comedones and multiple hyperpigmented papules bilaterally over both the eyelid margins [Figure 2]. Few skin-colored papules were found on the neck. There was erythema, edema, and tenderness of both the pinnae of ears. Few circular linear atrophic scars were noticed on the face. Hyperpigmentation and verrucous surface skin were seen over both the elbows, knuckles, sides of fingers, and over the palmar surface of hands and digits [Figure 3]. Few crusted healing erosions were seen around elbows. Nails were normal. On intraoral examination, whitish plaques were seen over the bilateral buccal mucosa, lips, sublingual mucosa, and palate. There was a restriction of tongue movements with thickening of the lingual frenum. Erosions, few fissures, and whitish plaques were noticed on the tongue. Based on the clinical findings and considering the patient being a known case of LP, a diagnosis of oral manifestations of LP was given.

X-ray skull showed focal areas of increased density, projected over the dorsum sellae. Lateral view showed probable suprasellar calcification with normal size of sella. Histopathologic examination revealed a diagnosis of LP [Figure 4] showing hyperkeratosis, acanthosis, and elongated rete ridges along with deposition of dense eosinophilic material in the superficial dermis.

Patient was instructed to maintain oral hygiene and to be under liquid diet. Antiseptic mouthwash was advised to be used thrice daily after foods. Patient was recalled after 1-week during which there was a considerable improvement in the healing of the intraoral lesions.

Discussion

Lipoid proteinosis is a rare collagen disorder with a genetic predisposition, with a higher prevalence in South Africa and Sweden, where consanguineous marriages are very common.^[5,6] LP has been seen in siblings born to

nonconsanguineous marriage also.^[7] Both our cases were of nonconsanguineous marriage.

It is characterized by the deposition of an amorphous hyaline material with a glycoprotein constitution in the skin, mucous membranes, and internal organs. The etiopathogenesis of the LP is not still completely understood, but it seems to be related to an alteration in the synthesis and metabolism of the collagen, leading to an increase in the synthesis of types IV and V collagen by the endothelial cells of the blood vessels, a glycoprotein substance by the fibroblasts, and a decrease in the production of collagen types I and II.^[7-9]

Lipoid proteinosis usually exhibits in early infancy with hoarseness of voice due to the vocal cord infiltration. It is then followed by collects of recurrent blood or pus-filled vesicles, bullae, macules, papules, and skin-colored nodules, which are often pruritic and may coalesce resulting in diffuse thickening of the skin and mucous membrane.^[10] They may appear in any part of the body.^[11] Infiltration of the scalp often gives patchy or diffuse alopecia. Mucocutaneous lymphatic system plays a major role in this disease because the lesions are usually seen in those areas having greater mobility demanding for high plasticity for example: The flexion and extension of knees, elbows, antecubital fossa; oral mucosa as a result of eating and speaking. Hence, a failure of mucocutaneous lymphangiogenesis may trigger the clinical feature of LP. Rarely occurrence of calcinosis cutis in LP has been reported. The hyaline material in the dermis was thought to be a nidus for calcification.^[12]

Oral mucosa manifests with generalized pearly papular yellowish deposits. The tongue may be hard, enlarged, stiff, and woody. Often, gingival hypertrophy with irregularly thickened lips is found.^[13] Lingual frenulum may be thickened restricting the tongue movements during deglutition and speech. Frequent involvement of salivary glands, usually submandibular and parotid gland^[14] can cause hyposalivation or xerostomia, leading to poor oral hygiene. Oral ulcerations have also been reported.^[15] Whether the oral manifestation or the cutaneous manifestations appear first is not known due to its variable presentation.

Moreover, the respiratory system, upper gastrointestinal tract, central nervous system, blood vessels, and lymph nodes may also be involved. LP are known to have calcification of the temporal lobes or hippocampi in the brain^[16] as in our second case radiographic investigation revealed suprasellar calcifications. Epilepsy, memory loss, schizophrenic behavior, mental retardation, emotional changes, and other neuropsychiatric abnormalities may be seen in some patients. Hyaline deposits have also been described in the conjunctiva, cornea, trabeculum, and retina.^[14] Corneal opacities or secondary glaucoma may appear later. The presence of beadlike papules on the margins of both upper and lower palpebral

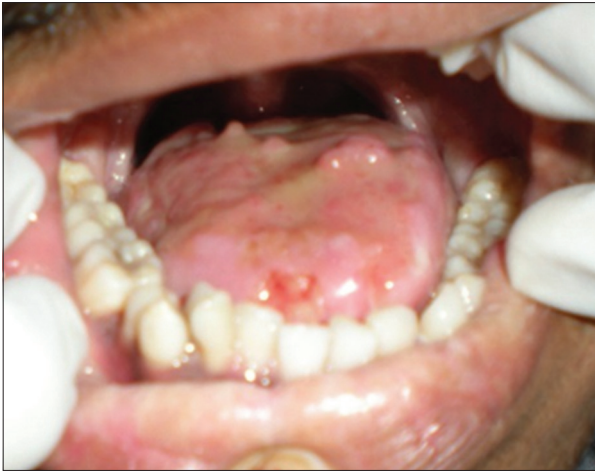

Figure 1: Multiple ulcerations on the dorsum of the tongue

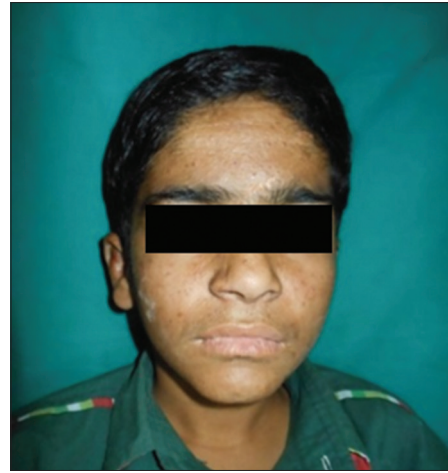

Figure 2: Multiple hyperpigmented papules on the face

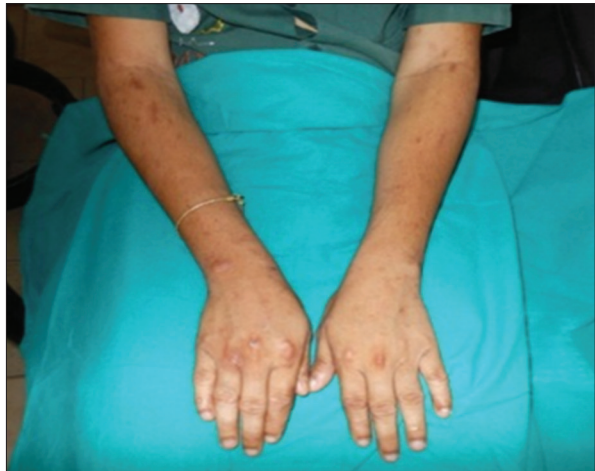

Figure 3: Hyperpigmented and verrucous surface skin over both the elbows, knuckles, sides of fingers

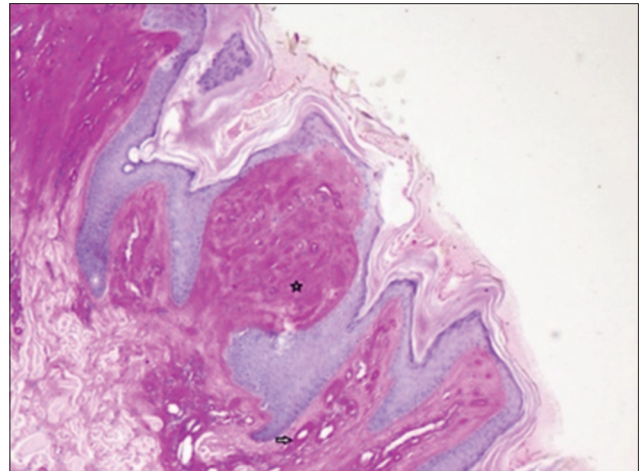


Figure 4: Histopathological picture showing hyperkeratosis, acanthosis, and elongated rete ridges with deposition of dense eosinophilic material in the superficial dermis

conjunctiva (moniliform blepharosis) is the universal sign of this disease.^[17] Epiphora is also one of the ocular signs. Nail dystrophy with hemorrhagic blisters on the wrists, fingers, and nailbed is a common finding.

Histological appearance shows disruption and/or duplication of the basement membrane along with deposition of hyaline material at the dermo-epidermal junction, papillary dermis, surrounding capillaries, and around adnexal epithelia with appearance of sweat coils. Immunofluorescence labeling with anti-collagen antibody shows types IV and V collagen accumulation and reduction of types I and III collagen around blood vessels.^[17] Total of 26 different inherited mutations in ECM1 have been reported in LP.^[18] ECM1 has been shown to have several important biological functions. It has a role in the structural organization of the dermis (binding to perlecan, matrix metalloproteinase-9 and fibulin) as well as being targeted as an autoantigen.

There is no effective and precise treatment regimen for LP. This disease compromises the quality of life^[11] due to

its disfiguring scars and multisystem involvement. The disease is not life-threatening except for the respiratory obstruction in severe cases. If the lesions start at an early age, it is found to be self-limiting.^[11] However, for esthetic consideration, dermabrasion can be done, as it can become a boon to the patient who is psychosocially affected due to his/her appearance. Chemical skin peeling is another good option. Treatment with dimethyl sulfoxide, D-penicillamine, etretinate, intralesional heparin has also been tried.^[19] None of them have given a promising result. Laser microlaryngoscopy, mucosal stripping, or dissection of the vocal cords and excision of deposits may be performed to preserve or improve the quality of voice. In very severe cases, if there is diffuse infiltration of the pharynx and larynx causing respiratory distress, tracheostomy is required.^[17]

As LP extensively involves the oral mucosa and indirectly, the dentition as well, it is important that the dentist be familiar about it. Furthermore, the oral mucosa exhibits clinical features resembling the oral manifestations of several other

systemic diseases. Thus, careful history taking and detailed clinical examination followed by necessary investigations is a must in establishing the diagnosis and whenever such cases are encountered all measures of alleviating patient symptoms should be undertaken so that oral complications of the systemic condition do not further deteriorate the quality-of-life. It is also important that parents of affected children be taken for genetic counseling concerning the risks of having other affected offspring.

References

- Orton CI, Buchan NG. Lipoid proteinosis: The oro-facial manifestations. *Br J Oral Surg* 1975;12:289-91.
- Urbach E, Weith C. Lipoidosis cutis et mucosae. *Virchows Arch* 1929;273:285-319.
- Kumar P, Sampath V, Manoharan K. Lipoid proteinosis in a child with recurrent respiratory infection. *EJ Indian Soc Tele Dermatol* 2009;3:6-11.
- Wollina U, Konrad H, Schönlebe J. Lipoid proteinosis. *Acta Dermatovenerol Alp Pannonica Adriat* 2004;13:131-4.
- Xu W, Wang L, Zhang L, Han D, Zhang L. Otolaryngological manifestations and genetic characteristics of lipoid proteinosis. *Ann Otol Rhinol Laryngol* 2010;119:767-71.
- Rizzo R, Ruggieri M, Micali G, Tinè A, Sanfilippo S, Pavone L. Lipoid proteinosis: A case report. *Pediatr Dermatol* 1997;14:22-5.
- Piérard GE, Van Cauwenberge D, Budo J, Lapière CM. A clinicopathologic study of six cases of lipoid proteinosis. *Am J Dermatopathol* 1988;10:300-5.
- Harper JI, Duance VC, Sims TJ, Light ND. Lipoid proteinosis: An inherited disorder of collagen metabolism? *Br J Dermatol* 1985;113:145-51.
- Williamson BK, Island R. Histology of lipoid proteinosis. *JAMA* 1994;272:564-5.
- Hamada T. Lipoid proteinosis. *Clin Exp Dermatol* 2002;27:624-9.
- Brajac I, Kastelan M, Gruber F, Peris Z. Hyalinosis cutis et mucosae: A 30 year follow up of a female patient. *Eur J Dermatol* 2004;14:310-3.
- Uchida T, Hayashi H, Inaoki M, Miyamoto T, Fujimoto W. A failure of mucocutaneous lymphangiogenesis may underlie the clinical features of lipoid proteinosis. *Br J Dermatol* 2007;156:152-7.
- Bazopoulou-Kyrkanidou E, Tosios KI, Zabelis G, Charalampopoulou S, Papanicolaou SI. Hyalinosis cutis et mucosae: Gingival involvement. *J Oral Pathol Med* 1998;27:233-7.
- Nanda A, Alsaleh QA, Al-Sabah H, Ali AM, Anim JT. Lipoid proteinosis: Report of four siblings and brief review of the literature. *Pediatr Dermatol* 2001;18:21-6.
- Sargenti Neto S, Batista JD, Durighetto AF Jr. A case of oral recurrent ulcerative lesions in a patient with lipoid proteinosis (Urbach-Wiethe disease). *Br J Oral Maxillofac Surg* 2010;48:654-5.
- Shivaswamy KN, Thappa DM, Laxmisha C, Jayanthi S. Lipoid proteinosis in two siblings: A report from south India. *Dermatol Online J* 2003;9:12.
- Di Giandomenico S, Masi R, Cassandrini D, El-Hachem M, De Vito R, Bruno C, *et al.* Lipoid proteinosis: Case report and review of the literature. *Acta Otorhinolaryngol Ital* 2006;26:162-7.
- Chan I, Liu L, Hamada T, Sethuraman G, McGrath JA. The molecular basis of lipoid proteinosis: Mutations in extracellular matrix protein 1. *Exp Dermatol* 2007;16:881-90.
- Vedamurthy M. Lipoid proteinosis in siblings. *Dermatol Online J* 2003;9:13.

How to cite this article: Kabre V, Rani S, Pai KM, Kamra S. Lipoid proteinosis: A review with two case reports. *Contemp Clin Dent* 2015;6:233-6.

Source of Support: Nil. **Conflict of Interest:** None declared.