

# Modified closed-loop double-endobutton technique for repair of rockwood type III acromioclavicular dislocation

LEI ZHANG<sup>1,2\*</sup>, XIN ZHOU<sup>1\*</sup>, JI QI<sup>2\*</sup>, YAN ZENG<sup>1\*</sup>, SHAOQUN ZHANG<sup>2\*</sup>,  
GANG LIU<sup>1</sup>, RUIYUE PING<sup>3</sup>, YIKAI LI<sup>2</sup> and SHIJIE FU<sup>1</sup>

<sup>1</sup>Department of Orthopedics, Affiliated Traditional Chinese Medicine Hospital of Southwest Medical University, Luzhou, Sichuan 646600; <sup>2</sup>Department of Orthopedics, School of Traditional Chinese Medicine, Southern Medical University, Guangzhou, Guangdong 510515; <sup>3</sup>Department of Dermatology, Guangzhou University of Traditional Chinese Medicine, Guangzhou, Guangdong 510403, P.R. China

Received April 18, 2017; Accepted November 2, 2017

DOI: 10.3892/etm.2017.5487

**Abstract.** Acromioclavicular dislocation (ACD) is a common injury. According to the Rockwood classification, ACD is classified into six types (type I-VI); however, for type III injuries, it remains controversial whether or not operative treatment should be applied. Numerous studies have advocated early surgical treatment to ensure early rehabilitation activities. Thus, the present study aimed to investigate a modified closed-loop double-endobutton technique (MCDT), that may be used to repair Rockwood type III ACD. In the current study, 61 patients with Rockwood type III ACD were enrolled during a period of 5 years at the Affiliated Traditional Chinese Medicine Hospital of Southwest Medical University. Patients were divided into three groups according to the surgical method used, the MCDT group (n=20), the common closed-loop double-endobutton technique (CCDT) group (n=21), and the clavicular hook plate fixation (CHPF) group (n=20). Preoperative and intraoperative information were recorded. Furthermore, the functional scores of injured shoulder were evaluated prior to surgery and following surgery with a 1-year follow-up. Among the three groups, postoperative

functional scores were significantly more improved compared with those prior to surgery ( $P<0.05$ ), and no significant difference was observed regarding the coracoclavicular interval with the 1-year follow-up ( $P>0.05$ ). Postoperative functional scores in the MCDT and CCDT groups were significantly more improved compared those in the CHPF group ( $P<0.05$ ). In addition, the duration of surgery in the MCDT group was significantly shorter compared with that in the CCDT group ( $P<0.05$ ). Furthermore, compared with the CHPF group, the incision length was significantly shorter with reduced hemorrhage in the MCDT group ( $P<0.05$ ). In conclusion, the results of the current study suggest that MCDT is more simple, convenient and efficient compared with CCDT, and is worth popularizing.

## Introduction

The acromioclavicular (AC) joint injury is a common orthopedic problem that accounts for 12% of shoulder injuries (1). Despite its prevalence, the lack of consensus regarding its diagnosis and treatment makes it one of the most controversial shoulder injuries (2,3). Firstly, Tossy *et al* (4) classified AC joint injury into types I, II, and III. Then, Rockwood *et al* (5) expanded the classification to types IV, V, and VI. The expanded classification recognized a variety of complete AC dislocation (ACD). According to the Rockwood classification, ACD is classified into types I-VI (6). The Rockwood classification system is very important for surgeons to accurately diagnose AC joint injuries and is used in the literature to guide nonoperative vs. operative management (7-10). Rockwood type I, II could be cured by expectant treatment, while the ACD of Rockwood types IV, V, and VI always requires surgical intervention. However, it remains controversial for type III injury whether to take operative treatment or not. Numerous biomechanical studies in recent years have led to the development of surgical techniques that stabilize the AC joint complex with fixation that more closely approximates the natural anatomic structure (11-14). Currently, many operative treatments for type III injury are effective, such as clavicular hook plate fixation (CHPF), kirschner wires tension band fixation, reconstruction of coracoclavicular ligaments, and so on (15-18). However,

---

*Correspondence to:* Professor Shijie Fu, Department of Orthopedics, Affiliated Traditional Chinese Medicine Hospital of Southwest Medical University, 16 Chun Hui Road, Luzhou, Sichuan 646600, P.R. China  
E-mail: 516774578@qq.com

\*Contributed equally

**Abbreviations:** AC, acromioclavicular; ACD, acromioclavicular dislocation; MCDT, modified closed-loop double-endobutton technique; CCDT, common closed-loop double-endobutton technique; CHPF, clavicular hook plate fixation; CMS, Constant-Murley Score; UCLA, University of California at Los Angeles shoulder rating scale; ASES, rating scale of the American Shoulder and Elbow Surgeons; OSS, Oxford Shoulder Score; CC-interval, coracoclavicular interval

**Key words:** acromioclavicular joint, dislocation, closed-loop, double-endobutton, Rockwood type III

the complications of surgery, including looseness of internal fixation, postoperative pain of shoulder, restricted joint motion and recrudescence of joint dislocation after removing internal fixation, is still an important issue (19-24).

Treatment of the ACD of Rockwood type III is particularly challenging for surgeons (25-29). The endobutton technique has been used for patients and is worthy of popularization (30-32). At present, the hook plate is currently used by 44% of all surgeons (33). But injury to the shoulder was worse. Compared with hook plate in the treatment of the ACD of Rockwood type III, the endobutton technique showed better short-term results with regard to complications and could be used effectively in the treatment. Biomechanical studies in recent years have demanded stabilization of the AC joint complex with fixation that more closely approximates the natural anatomic structure (34-36), and the double-endobutton technique could be compatible with anatomic structure. In a clinical study, there were no significant differences in the mean incision length, blood loss, the operative and radiation time, length of hospitalization, the Constant and VAS scores, and ability to return to previous work between a double endobutton group and triple endobutton group, and the triple endobutton treatment had higher hospital costs (37). Hu *et al* (38) explored the clinical efficacy of double endobutton reconstitution of the coracoclavicular ligament combined with repair of the acromioclavicular ligament in stage I in treating ACD with Rockwood type III-V, which suggested good early results. In fresh-frozen cadaveric upper extremities, Struhl *et al* (39) compared the stability of a novel closed-loop double-endobutton construct with a commercially available cortical button system in both the axial and superior directions and they suggested closed-loop double-endobutton construct provided good stability. In addition, Struhl and Wolfson (40) made a mean follow-up of 5.2 years for 35 patients who got a closed-loop double-endobutton technique to reconstruct both acute and chronic dislocations (Rockwood type III) and they suggested that this technique was a low-profile, durable fixation device that maintained a stable AC joint, which allowing enough time for strong soft tissue healing to develop. It was reported that arthroscopy seem to have a lower rate of residual postoperative pain and postoperative recurrence (40). We modified common closed-loop double-endobutton technique by shoulder arthroscopy, which would provide a better treatment for ACD patients.

The application of double-endobutton reconstruction in patients with ACD has significantly reduced the postoperative complications (35,41). Also, the effect on Rockwood type III has been confirmed (42-44). At the same time, the improvement of double-endobutton reconstruction is always ongoing, aiming at simplifying the surgical procedures, strengthening the internal fixation, and reducing the complications. With the rapid development of arthroscopic technique, we modified common closed-loop double-endobutton technique (CCDT) to treat ACD by shoulder arthroscopy. Based on replacement and stabilization of the AC joint, the modified closed-loop double-endobutton technique (MCDT) was more simple, convenient and efficient than CCDT, and was worth popularizing.

The ACD of Rockwood type III, the coracoclavicular ligament is ruptured completely, the stability of the acromioclavicular joint on the vertical direction is lost, and the distal

clavicle is shifted upwards, that causes shoulder joint pain, swelling, and even restricted movement. In the present study, MCDT was used to treat the ACD of Rockwood type III, two endobutton with loops were prepared, two loops were tied together, making a closed-loop slipknot between two endobuttons. The total length of the loops that was made before procedure, was approximately equal to CC-interval in uninjured side shoulder. The modified closed-loop double-endobutton was implanted in injured side by arthroscopy technique, so the ACD of Rockwood type III was restored, and it provided a stable environment, which was beneficial to early activities and recovery.

The present study still had some limitations. For example: Firstly, all cases enrolled were from the same hospital but not a multi-center study. Secondly, the length of the loops was determined by CC-interval in uninjured side shoulder, which maybe ignore the difference between the left and right side. Thirdly, the radiographic distance maybe were little erroneous.

In order to evaluate the clinical efficacy and recovery of the MCDT, we conducted a study in comparison with other surgical procedures, including CCDT and CHPF. By comparing the three groups, the advantages of MCDT were known, and it provided evidence and support for clinical extensive application.

## Materials and methods

*Inclusion standards.* Cases were enrolled according to such inclusion criteria: i) Patients were diagnosed as acute ACD without course of exceeding 7 days before surgical treatment. ii) The shoulder was injured with one side. iii) It was confirmed that injury belonged to Rockwood type III by CT or MRI. iv) Patients completely understood operation and expectant treatment and signed operative informed consent, doctor-patient communication consent and implantable informed consent. v) Patients had a follow-up of more than 1 year.

*Exclusion standards.* Other cases would be excluded with such criteria: i) Patients had an injury longer than 7 days before surgery. ii) Patients had serious associated injuries, such as clavicular fracture, coracoid fracture, or other fracture in shoulder. iii) Patients suffered from open shoulder injuries that would be infected easily. iv) Patients had anatomic variation of coracoid in shoulder. v) Patients had associated injuries of brachial plexus. vi) Patients had serious shoulder swelling or other injuries that affected operations. vii) Patients had special diseases of tumor, poisoning, infection and visceral organ failure. viii) Patients had a follow-up of less than 1 year. ix) Patients who were attending other project would not be enrolled.

*Patients and ethic.* All procedures were approved by the Ethical Committee of Affiliated Traditional Chinese Medicine Hospital of Southwest Medical University (no. 2016060518) and registry of clinical trial (ChiCTR-ORC-16008438), and performed in accordance with the 1964 Helsinki declaration and its later amendments or comparable ethical standards. Informed consent was obtained from all individual participants included in the present study. A total of 61 cases were enrolled from January 2010 to December 2014 in affiliated

Table I. Baseline data of all patients.

Characteristic	MCDT	CCDT	CHPF
Sex			
Male (N)	12	13	13
Female (N)	8	8	7
Age (years)	30.25±7.41	29.90±6.98	30.55±8.04
Injured side			
Right (N)	11	12	10
Left (N)	9	9	10
Arm dominance			
Right (N)	19	19	19
Left (N)	1	2	1
Injured time (days)	3.85±0.81	3.86±0.79	3.95±0.76

In three groups, compared each indicator  $P>0.05$ .

Traditional Chinese Medicine Hospital of Southwest Medical University.

**Grouping.** There were 3 kinds of operation methods chosen by patients, in terms of 3 kinds of operation methods, the enrolled patients were divided into 3 groups, MCDT group ( $n=20$ ), CCDT group ( $n=21$ ), CHPF group ( $n=20$ ). Each group underwent surgical treatment by one of three types of operations separately. All surgeries were completed by the same senior surgeons in our hospital. In addition, the main injury reasons contained traffic accident (22 cases), tension injury during exercise (20 cases), falling injury (10 cases) and heavy pound injury (3 cases).

**Detection index and methods.** Before operation, there was no significant difference in general data of sex, age, injured side, arm dominance, time interval from injury to surgery and shoulder functional scores, including Constant-Murley Score (CMS), University of California at Los Angeles shoulder rating scale (UCLA), rating scale of the American Shoulder and Elbow Surgeons (ASES), Oxford Shoulder Score (OSS) (45-48) and coracoclavicular interval (CC-interval) before surgery was noticed among three groups ( $P>0.05$ ) (Tables I and II). Meanwhile, operative time, incision lengths and intraoperative hemorrhage were observed as surgical index. And multiple validated measures were collected before and after 1 years, including CMS, UCLA, ASES, OSS, and CC-interval.

**Preoperative preparation.** First of all, CC-interval of all patients in both shoulders were measured under radiographs (Fig. 1). In MCDT group, two endobutton (titanium alloy, 4x12 mm, Smith&Nephew, USA) with loops were prepared (Fig. 2). Then, one of endobuttons' loop was penetrated into another endobutton's loop. Later, the former endobutton was reflected into its own loop which had passed through another endobutton's loop before. Finally, two endobuttons were strained from two opposite direction, making a closed-loop slipknot between two endobuttons, which was the modified closed-loop double-endobutton (Fig. 2A and C). The total length of the loops that was made before was approximately equal to CC-interval in uninjured side shoulder of the same patient. After that, non-absorption braided

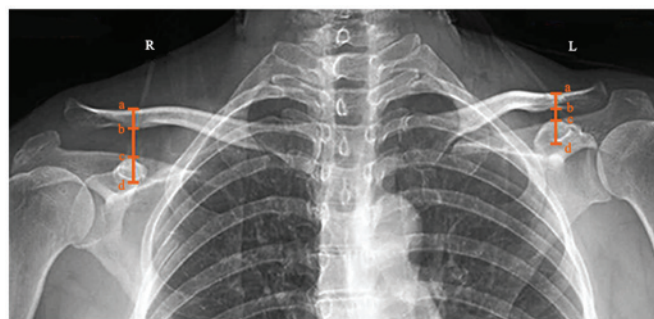

Figure 1. Preoperative radiographs of shoulders of injured side (right) and uninjured side (left). The CC-interval was vertical distance of the upper edge of clavicle to lower edge of coronoid, was measured from a to d, the interval from b to c increased in the injured side.

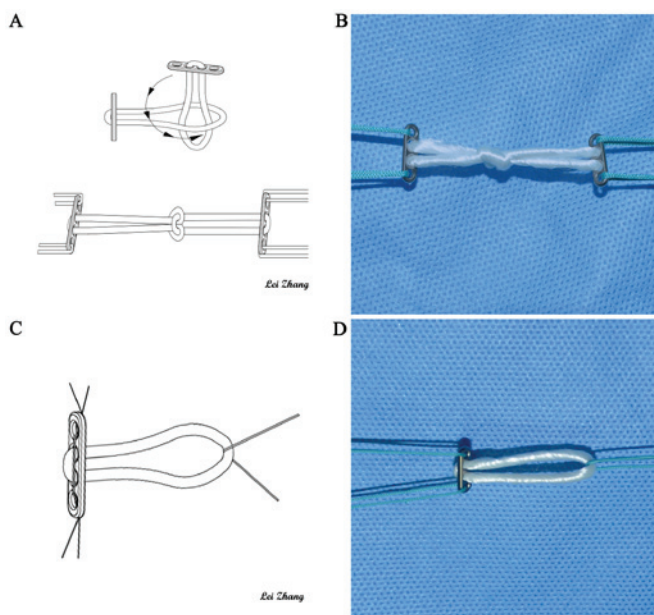


Figure 2. Preparation of MCDT and CCDT before surgery. (A) A hand-drawing of prepared MCDT; (B) A photograph of prepared MCDT; (C) A hand-drawing of prepared CCDT; (D) A photograph of prepared CCDT.

tendon sutures (Johnson, USA) were loaded into the first and fourth holes on plates separately as lead wires.

In CCDT group, single-endobutton with a loop was prepared at first. Then non-absorption tendon sutures (Johnson, USA) were pierced into the first and fourth holes on plates separately as lead wires, which was single-endobutton with a loop (Fig. 2B and D). At the same time, the other sutures fixed on the loop. Also another endobutton without loops was prepared. The diameter of loops was 4.5 mm and the length of loops was equal to CC-interval in uninjured shoulder at the same patient.

In CHPF group, the clavicular hook plate (titanium alloy, AO, Switzerland) was chosen before surgery.

**Surgical process of MCDT.** Under general anesthesia in beach chair position, almost with angle of 70 degree between horizontal line and the upper part of the body. Trunk, limbs and head were fixed and surgical incisions were marked before the procedure (Fig. 3A). The arthroscopic instruments (72200616,

Table II. Functional rating and CC-interval before surgery.

Group	Case(N)	CMS	UCLA	ASES	OSS	CC-interval (mm)
MCDT	20	46.50±2.16	14.65±1.31	44.15±2.54	45.25±3.01	16.77±0.91
CCDT	21	46.52±1.94	14.76±1.18	44.57±2.29	44.62±3.37	16.70±0.77
CHPF	20	46.55±2.31	14.70±1.17	44.25±2.55	45.20±3.25	16.83±0.75

In three groups, compared each indicator P>0.05.

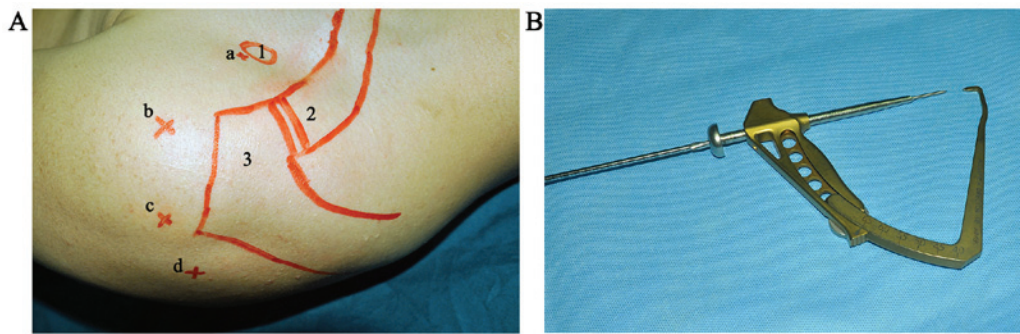


Figure 3. Marked incision, approach of shoulder arthroscopy and guiding locator in the surgical process of MCDT. (A) The bony marks of coracoid (1), distal clavicle (2) and acromion (3) and four approaches as anterior-medial (a), anterior-lateral (b), posterior-lateral (c) and posterial-medial (d) were marked; (B) The guiding locator which would be used in the next stage of surgery.

Smith & Nephew, USA) were prepared before operation, the instruments were strictly sterilized by operators. Then, the patients were anesthetized and were sterilized on surgical area. The shoulder joint was examined under anesthesia, and small incisions were made around the joint, the scope and surgical instruments would go into these incisions. The scope was inserted into the shoulder joint, saline solution flowed through a tube and into the shoulder capsule to expand the joint and to improve visualization. The image was sent to a video monitor where the surgeon could see inside the joint. Planer tool was inserted from anterior-lateral approach, with the scope was inserted from lateral approach, in order to remove partial plica that could cause pain and to expose clearly coracoid base, the guiding locator (Fig. 3B) was inserted from the anterior-medial approach and located on the center of base of the coracoid and the center of upper surface of clavicle, passing 2-mm kirschner wires between these two point. A hole was drilled in the top of the clavicle midway between the anterior and posterior borders and directly in line with the base of the coracoid, the tunnel was drilled over guide wire with the same diameter as the loop. By using a grasper, the lead wires were inserted from coracoid tunnel into clavicle tunnel and penetrated out the top of clavicle tunnel finally. Then the modified closed-loop double-endobutton would be inserted. One of endobuttons was taken from clavicle tunnel to the base of coracoid tunnel. While pushing the distal clavicle downwards, the lower endobutton was fixed on the base of coracoid, and the upper endobutton was fixed on the top of clavicle. Finally ACD was repaired (Fig. 4A and B). After that, the lead sutures on endobutton were drawn out, the surgical instruments were removed and the procedure was completed, the proper location of AC joint was confirmed through arthroscopy, the incision was cleaned and sutured finally.

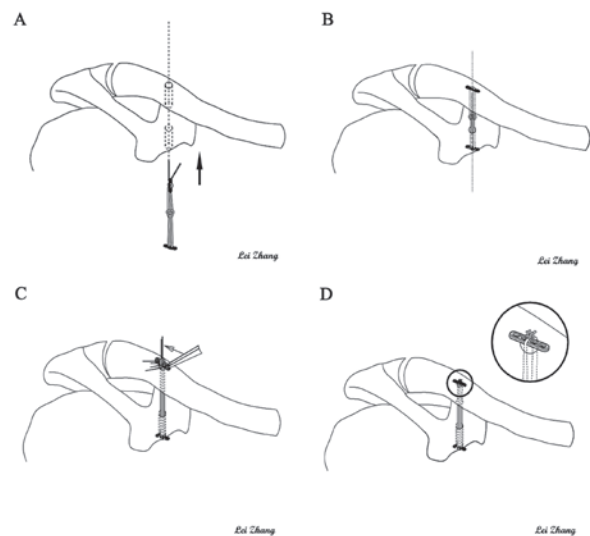


Figure 4. Hand-drawings of brief surgical process of MCDT and CCDT. (A) One of prepared endobuttons was taken from clavicle tunnel to the base of coracoid tunnel; (B) By pushing the distal clavicle downwards, the lower endobutton was fixed on the base of coracoid, and the upper endobutton was fixed on the top of clavicle; (C) Prepared single-endobutton with a loop was taken into base of coracoid tunnel and was fixed on the base of coracoid. Another single-endobutton without loops was placed in the loop on top of the clavicle; (D) The loop was locked by two knotted sutures on the single-endobutton without loops.

*Surgical process of CCDT.* The selection of body position and process of arthroscopic examination and establishing bone tunnel were same as MCDT. Prepared single-endobutton with a loop was taken into base of coracoid tunnel and was fixed on the base of coracoid. And the loop on the single-endobutton was pulled out clavicle tunnel at the same time, leaving empty

place for the single-endobutton without loops. After pushing distal clavicle downwards for qualified reconstruction, the single-endobutton without loops was placed in the loop on top of the clavicle. Then the loop was locked by two knotted sutures from the second to third and the first to fourth holes on the single-endobutton without loops and the lead sutures from the single-endobutton with a loop was also drawn out (Fig. 4C and D). At the end, the proper location of AC joint was confirmed through arthroscopy, the incisions were cleaned and sutured by layers finally.

**Surgical process of CHPF.** In supine position, after general anesthesia, patients were made an arc incision from middle part of clavicle to acromion with 7-9 cm, exposing AC joint. Intervening soft tissues were removed in the AC joint and the operative vision were cleared completely later. Then the prepared plate was moulded as the shape of clavicle, and was inserted on the top of the AC joint. The holes were drilled and the screws were inserted. Finally, the incisions were cleaned and sutured.

**Postoperative treatment.** Operated shoulder was rested in a sling for 4 weeks. Functional exercises were started 3 days after operation. Passive exercises began in 4 weeks. Active movement of the shoulder and resistant exercises were allowed after 4 to 12 weeks. Strenuous exercises were avoided during first three months following surgery. The time of using injury-side sling and functional exercise were extended for patients whose healing was slow. At first, all patients reviewed clinical postoperative examination at 2, 3, 6 months. Afterwards, they were required to get follow-up examination every 6 months. Removal of the internal fixations was not necessary in MCDT and CCDT group, while it was essential to remove internal fixations in CHPF group 1 year after surgery depending on the process of recovery.

**Statistical analysis.** The Pearson chi-square test and Fisher exact test were used to compare categorical outcomes. The paired t test was used to compare the functional scores and CC-interval after the operation with those before operation. And the one-way ANOVA was used to compare the functional scores and CC-interval among three groups. The level of statistical significance was set at  $P < 0.05$ . All data were analyzed with the use of SPSS software (version 20, IBM Corp). Results are expressed as the mean  $\pm$  SD unless otherwise specified.

## Results

**Surgical index.** Firstly, the operative time of MCDT or CHPF group was significantly shorter than that of CCDT group ( $P < 0.05$ ). But no significant difference between MCDT and CHPF group ( $P > 0.05$ ). Secondly, the incision lengths of MCDT or CCDT group was significantly shorter than that of CHPF group ( $P < 0.05$ ). And no significant difference was noted between MCDT and CCDT group ( $P > 0.05$ ). Thirdly, the hemorrhage of MCDT or CCDT group was significantly less than that of CHPF group ( $P < 0.05$ ). And significant difference was noted between MCDT and CCDT group ( $P < 0.05$ ) (Table III).

Table III. Comparison in surgical index among 3 groups.

Group	Case (N)	Operation time (min)	Length of cut (cm)	Hemorrhage (ml)
MCDT	20	77.00 $\pm$ 8.18 <sup>a</sup>	1.55 $\pm$ 0.26 <sup>b</sup>	52.00 $\pm$ 8.18 <sup>b</sup>
CCDT	21	101.19 $\pm$ 7.89	1.54 $\pm$ 0.25 <sup>b</sup>	75.24 $\pm$ 11.23 <sup>b</sup>
CHPF	20	76.50 $\pm$ 8.13 <sup>a</sup>	8.98 $\pm$ 0.65	140.00 $\pm$ 18.64

<sup>a</sup> $P < 0.05$  vs. CCDT group; <sup>b</sup> $P < 0.05$  vs. CHPF group.

**Follow-up outcome measurements.** One year after surgery, the CMS, UCLA, ASES, OSS, CC-interval were superior to those before surgery in three groups ( $P < 0.05$ ). Secondly, all post-operation functional scores of MCDT or CCDT group were better than those of CHPF group ( $P < 0.05$ ). And no significant difference in mean functional scores was noted between MCDT and CCDT group ( $P > 0.05$ ). In addition, radiographic findings confirmed that no significant difference in CC-interval was visible among three groups after surgery ( $P > 0.05$ ). And the radiography of patients in three group showed satisfying operative effect after one year (Figs. 5-7).

## Discussion

It had basically been obtained a consensus that the Rockwood type IV, V and VI injury should be treated with operation. However, the treatment of type III was still controversial (25,49-52). Nowadays, it had been put forward more and more high demands to the range of shoulder motion and its flexibility, but there were so much uncertainty and instability about conservative treatment. As a consequence, great emphases were put on the operational treatments (53-55). In addition, at present, the CHPF was the commonly recognized operation method with many advantages (56-59), for example, the great histocompatibility, the anatomic design, attaching with distal clavicular, stable fixation, continuously pressurizing distal clavicular, keeping slight activity of AC joint and noninterference in the normal physiological structure of AC joint. Nevertheless, studies had been reported that the CHPF also showed many complications, including shoulder pain, subacromial impingement, redislocation after extracting the internal fixation, even a stress fracture, and so on (60-62). Moreover, the CHPF provided healing condition for the AC ligament, the AC ligament and the surrounding soft tissue, even though the healing scar could not ensure the stability of the activity after shoulder surgery. With the application of arthroscopy and double-endobutton, treatment of ACD of the Rockwood type III has entered into a new period.

The MCDT was to be improved on the basis of CCDT, making fixation more solid, simple, convenient and faster. Thus, it not only inherited the advantages of CCDT, but also had its own new superiority: ① The MCDT was in advance of making a closed-loop between two endobuttons, it could not only keep the integrity of the double-endobutton with loops, but also save the redundant steps of CCDT such as resetting, knotting and so on. The MCDT could achieve firm fixation to avoid the slip of sutures in CCDT, at the same time, reduce the

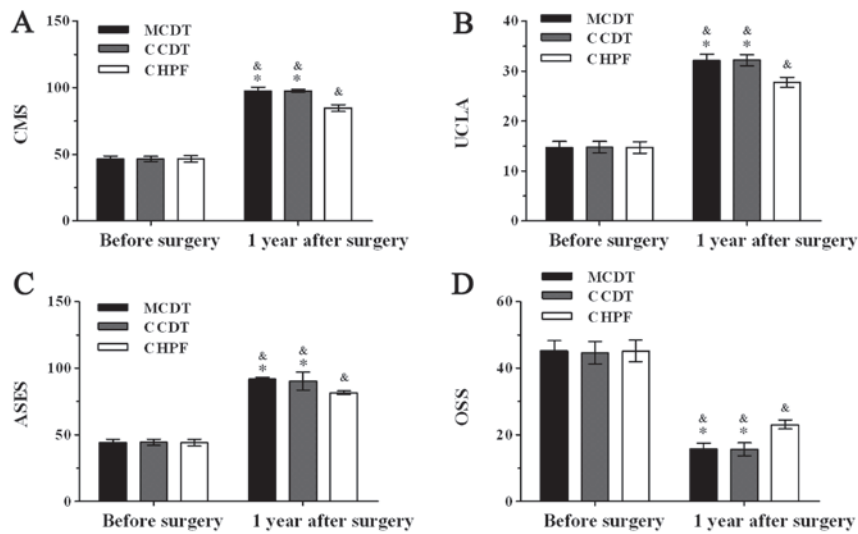


Figure 5. Differences in functional score of shoulder among 3 groups. (A) Constant-Murley Score (CMS); (B) University of California at Los Angeles shoulder rating scale (UCLA); (C) Rating scale of the American Shoulder and Elbow Surgeons (ASES); (D) Oxford Shoulder Score (OSS). &P<0.05 vs. functional score before surgery; \*P<0.05 vs. CHPF group.

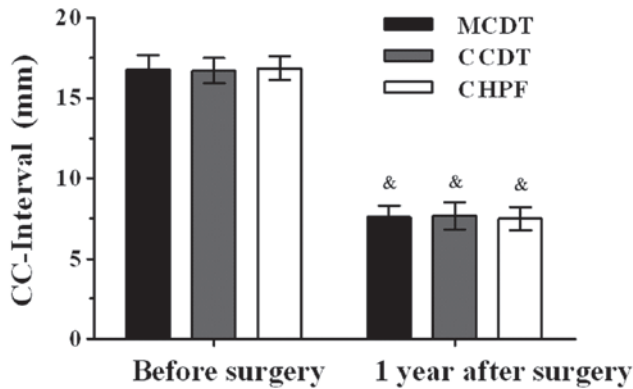


Figure 6. Difference in CC-interval among 3 groups. &P<0.05 vs. CC-interval before surgery.

operation time and blood loss effectively. ii) The minimally invasive surgical procedure was adopted, without exposing the AC joint in surgery, and the operation did not involve the rotator cuff, only 1.5-cm invasive incision was made minimally, and the incisions of arthroscopic conventional approach were no more than 1 cm, so it reduced blood loss and post-operative complications. Furthermore, it could deal with the associated injuries (rotator cuff injury, SLAP injury, Bankart injury, etc), and help patients with more satisfied recovery. iii) The AC joint was slightly movable joint attached with the surrounding ligaments and other soft tissue, in the procedure, the ACD was restored and AC ligament was reconstructed by the loop, the clavicle was fixed in the original anatomical position, that ensured the stability of shoulder joint. The AC joint was not used rigid fixation, so it could maintain a certain fretting, which ensured the soft tissue to heal in a stable environment, without any impingement-like pain and other complications in future and early postoperative functional exercise could be carried out. iv) When the bone tunnel of distal clavicle and coracoid was established in surgery, we applied the guiding locator which could accurately locate on

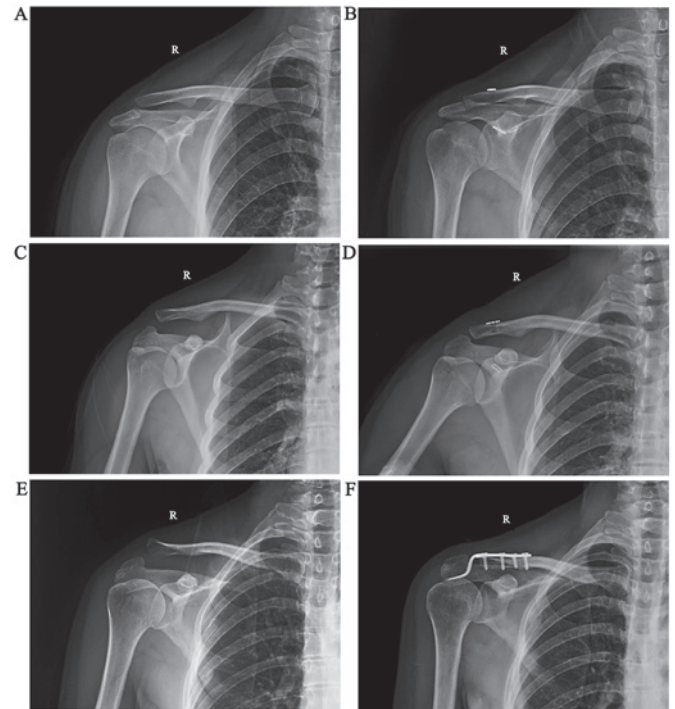


Figure 7. The radiography of injured shoulders in 3 groups showed satisfying operative effect. (A) The preoperative radiography in MCDT group; (B) The postoperative radiography in MCDT group with 1-year follow-up; (C) The preoperative radiography in CCDT group; (D) The postoperative radiography in CCDT group with 1-year follow-up; (E) The preoperative radiography in CHPF group; (F) The postoperative radiography in CHPF group with 1-year follow-up.

the insertion of the coracoid base of AC ligament, avoiding the situation such as the iatrogenic fracture, the injury of nerves and vessels (63). v) The loop was provided by Pfizer, and it was said that the strength of the device was more than 40% of the body's ligaments (48). Meanwhile, it was an implantable material with advantageous biocompatibility, no degradation and long-term retention in the body, without removing internal

fixation surgery and avoiding the possibility of recurrence of dislocation. Additionally, the following matters should also be paid attention to in the MCDT: i) Operators should control the contralateral the accurate measurement of CC-interval, to determine the length of the loop, and a few loops that were different lengths should be prepared before the surgery. ii) When coracoid tunnel was established, an optimal view should be found by arthroscopy in order to avoid the injury of brachial plexus and axillary arteries. Meanwhile, bone tunnel should be drilled an appropriate depth to keep the surrounding tissues from injury.

Firstly, CHPF for ACD had been applied for many years, which was a mature technology with widely application (64). In CHPF group, as a reference to compare with the MCDT group, any difference could not be found in statistically significant in operative time, but both the CHPF and MCDT group were better than the CCDT group, which indicated that surgical procedure of CCDT was relatively cumbersome, especially in resetting and fixing the endobutton on the top of clavicle, it was difficult for manipulation and took so much time. Secondly, in incision length, the MCDT and CCDT group were better than the CHPF group, because the arthroscopic incisions was minimally invasive. Thirdly, in intraoperative hemorrhage, the MCDT and CCDT group were better than CHPF group. Moreover, the MCDT group took less operation time than the CCDT group. mainly because that the MCDT and CCDT used minimally invasive surgery which reduced intraoperative hemorrhage, meanwhile the MCDT was to be improved on the basis of CCDT, making more convenient and faster. On the other hand, in the postoperative follow-up indicators, all groups were better than before surgery, and comparing the CC-interval value of the three groups after 1 year of follow-up, the difference was not statistically significant, which indicated three kinds of surgical methods were clinically effective. However, after 1 year follow-up, the MCDT and CCDT group were better than CHPF group, it associated with that large incision, soft tissue damage, the poor attachment of plate caused the limitation of shoulder mobility and the acromion impingement. On the contrary, few tissue damage was found around the shoulder joint with the MCDT, which was better for rehabilitating the shoulder joint at early stage.

However, the present study still has limitations. Firstly, all cases enrolled were from the same hospital but not multi-center study. Secondly, the total length of the loops was approximately equal to CC-interval in uninjured side shoulder, which maybe lead to ignore the physiological difference between the left and right side. Additionally, radiographic results were only measured in the vertical direction and did not account for displacement in the anteroposterior direction. In the following study, we will explore some more about it, consider some ways to modify the surgery. Moreover, related anatomic variation in AC joint also remained to be further studied. Only in these ways can we make a better contribution to clinical treatment for shoulder injury. Finally, in the present study, Rockwood type III ACD was suggested to receive the early surgical treatment, so we hadn't set up blank control group.

In conclusion, three kinds of surgeries to treat Rockwood type III ACD all were clinical effective. Although the MCDT in treating Rockwood type III ACD performed a remarkable effect and it had been widely used, there is still so much room

for improvement. The MCDT group had advantages in operative time, incision length, intraoperative hemorrhage and the score of CMS, UCLA, ASES, OSS and CC-interval. In brief, the MCDT, which was improved on the basis of the CCDT, the operative time, intraoperative hemorrhage had been significantly improved, that made the reduction and fixation more solid, simple, convenient and fast.

### Acknowledgements

The present study was supported by the National Natural Science Fund of China, grant no. 81674095, Science and Research Project of Education Department of Sichuan Province, grant no. 17ZB0472, the Science and Technology Project of Office of Science and Technology of Luzhou, grant no. 2016-176-13. We thank all patients and their family members, as well as all orthopedics from Affiliated Traditional Chinese Medicine Hospital of Southwest Medical University.

### References

1. Kim AC, Matcuk G, Patel D, Itamura J, Forrester D, White E and Gottsegen CJ: Acromioclavicular joint injuries and reconstructions: A review of expected imaging findings and potential complications. *Emerg Radiol* 19: 399-413, 2012.
2. Gstettner C, Tauber M, Hitzl W and Resch H: Rockwood type III acromioclavicular dislocation: Surgical versus conservative treatment. *J Shoulder Elbow Surg* 17: 220-225, 2008.
3. Tauber M: Management of acute acromioclavicular joint dislocations: Current concepts. *Arch Orthop Trauma Surg* 133: 985-995, 2013.
4. Tossy JD, Mead NC and Sigmund HM: Acromioclavicular separations: Useful and practical classification for treatment. *Clin Orthop Relat Res* 28: 111-119, 1963.
5. Rockwood CJ, Williams G and Young D: Disorders of the acromioclavicular joint. In *The Shoulder*. 2nd edition. Rockwood CJ, Matsen FA III (eds). Philadelphia: WB Saunders, pp483-553, 1998.
6. Guy DK, Wirth MA, Griffin JL and Rockwood CA Jr: Reconstruction of chronic and complete dislocations of the acromioclavicular joint. *Clin Orthop Relat Res*: 138-149, 1998.
7. Pallis M, Cameron KL, Svoboda SJ and Owens BD: Epidemiology of acromioclavicular joint injury in young athletes. *Am J Sports Med* 40: 2072-2077, 2012.
8. Kongmalai P, Apivatgaroon A and Chernchujit B: Morphological classification of acromial spur: Correlation between Rockwood tilt view and arthroscopic finding. *SICOT J* 3: 4, 2017.
9. McNeil JW, Beaulieu-Jones BR, Bernhardson AS, LeClere LE, Dewing CB, Lynch JR, Golijanin P, Sanchez G and Provencher MT: Classification and analysis of attritional glenoid bone loss in recurrent anterior shoulder instability. *Am J Sports Med* 45: 767-774, 2017.
10. Gorbaty JD, Hsu JE and Gee AO: Classifications in brief: Rockwood classification of acromioclavicular joint separations. *Clin Orthop Relat Res* 475: 283-287, 2017.
11. von Heideken J, Boström Windhamre H, Une-Larsson V and Ekelund A: Acute Surgical treatment of acromioclavicular dislocation type V with a hook plate: Superiority to late reconstruction. *J Shoulder Elbow Surg* 22: 9-17, 2013.
12. Wellmann M, da Silva G, Lichtenberg S, Magosch P and Habermeyer P: Instability pattern of acromioclavicular joint dislocations type Rockwood III: Relevance of horizontal instability. *Orthopade* 42: 271-277, 2013 (In German).
13. Kezunović M, Bjelica D and Popović S: Comparative study of surgical treatment of acromioclavicular luxation. *Vojnosanit Pregl* 70: 292-297, 2013.
14. Virtanen KJ, Remes VM, Tulikoura IT, Pajarinen JT, Savolainen VT, Björkenheim JM and Paavola MP: Surgical treatment of Rockwood grade-V acromioclavicular joint dislocations: 50 patients followed for 15-22 years. *Acta Orthop* 84: 191-195, 2013.

15. Kienast B, Thietje R, Queitsch C, Gille J, Schulz AP and Meiners J: Mid-term results after operative treatment of Rockwood grade III-V Acromioclavicular joint dislocations with an AC-hook-plate. *Eur J Med Res* 16: 52-56, 2011.
16. Kovilazhikathu Sugathan H and Dodenhoff RM: Management of type 3 acromioclavicular joint dislocation: Comparison long-term functional results of two operative methods. *ISRN Surg* 2012: 580504, 2012.
17. Gille J, Heinrichs G, Unger A, Riepenhof H, Herzog J, Kienast B and Oheim R: Arthroscopic-assisted hook plate fixation for acromioclavicular joint dislocation. *Int Orthop* 37: 377-382, 2013.
18. Struhl S: Double endobutton technique for repair of complete acromioclavicular joint dislocations. *Tech Shoulder Elbow Surg* 8: 175-179, 2007.
19. Di Francesco A, Zoccali C, Colafarina O, Pizzoferrato R and Flamini S: The use of hook plate in type III and V acromio-clavicular Rockwood dislocations: Clinical and radiological midterm results and MRI evaluation in 42 patients. *Injury* 43: 147-152, 2012.
20. Sandmann GH, Martetschläger F, Mey L, Kraus TM, Buchholz A, Ahrens P, Stöckle U, Freude T and Siebenlist S: Reconstruction of displaced acromio-clavicular joint dislocations using a triple suture-cerclage: Description of a safe and efficient surgical technique. *Patient Saf Surg* 6: 25, 2012.
21. Ranne JO, Sarimo JJ, Rawlins MI, Heinonen OJ and Orava SY: All-arthroscopic double-bundle coracoclavicular ligament reconstruction using autogenous semitendinosus graft: A new technique. *Arthrosc Tech* 1: e11-e14, 2012.
22. Choi NH, Lim SM, Lee SY and Lim TK: Loss of reduction and complications of coracoclavicular ligament reconstruction with autogenous tendon graft in acute acromioclavicular dislocations. *J Shoulder Elbow Surg* 26: 692-698, 2017.
23. Clavert P, Meyer A, Boyer P, Gastaud O, Barth J and Duparc F: SFA: Complication rates and types of failure after arthroscopic acute acromioclavicular dislocation fixation. Prospective multicenter study of 116 cases. *Orthop Traumatol Surg Res* 101 (8 Suppl): S313-S316, 2015.
24. Helfen T, Siebenbürger G, Ockert B and Haasters F: Therapy of acute acromioclavicular joint instability. Meta-analysis of arthroscopic/minimally invasive versus open procedures. *Unfallchirurg* 118: 415-426, 2015 (In German).
25. Longo UG, Ciuffreda M, Rizzello G, Mannering N, Maffulli N and Denaro V: Surgical versus conservative management of Type III acromioclavicular dislocation: A systematic review. *Br Med Bull* 122: 31-49, 2017.
26. Zumstein MA, Schiessl P, Ambuehl B, Bolliger L, Weihs J, Maurer MH, Moor BK, Schaer M and Raniga S: New quantitative radiographic parameters for vertical and horizontal instability in acromioclavicular joint dislocations. *Knee Surg Sports Traumatol Arthrosc*, May 25, 2017 (Epub ahead of print).
27. Porschke F, Schnetzke M, Aytac S, Studier-Fischer S, Gruetzner PA and Guehring T: Sports activity after anatomic acromioclavicular joint stabilisation with flip-button technique. *Knee Surg Sports Traumatol Arthrosc* 25: 1995-2003, 2017.
28. Faggiani M, Vasario GP, Mattei L, Calò MJ and Castoldi F: Comparing mini-open and arthroscopic acromioclavicular joint repair: Functional results and return to sport. *Musculoskelet Surg* 100: 187-191, 2016.
29. Biz C, Berizzi A, Cappellari A, Crimi A, Tamburin S and Iacobellis C: The treatment of acute Rockwood type III acromio-clavicular joint dislocations by two different surgical techniques. *Acta Biomed* 86: 251-259, 2015.
30. Struhl S and Wolfson TS: Closed-loop double endobutton technique for repair of unstable distal clavicle fractures. *Orthop J Sports Med* 4: 2325967116657810, 2016.
31. Ye G, Peng CA, Sun HB, Xiao J and Zhu K: Treatment of Rockwood type III acromioclavicular joint dislocation using autogenous semitendinosus tendon graft and endobutton technique. *Ther Clin Risk Manag* 12: 47-51, 2016.
32. Horst K, Garving C, Thometzki T, Lichte P, Knobe M, Dienstknecht T, Hofman M and Pape HC: Comparative study on the treatment of Rockwood type III acute acromioclavicular dislocation: Clinical results from the TightRope® technique vs. K-wire fixation. *Orthop Traumatol Surg Res* 103: 171-176, 2017.
33. Thomas K, Litsky A, Jones G and Bishop JY: Biomechanical comparison of coracoclavicular reconstructive techniques. *Am J Sports Med* 39: 804-810, 2011.
34. Groh GI, Mighell MA, Basamania CJ and Kibler WB: All things clavicle: From acromioclavicular to sternoclavicular and all points in between. *Instr Course Lect* 65: 181-196, 2016.
35. Grantham C, Heckmann N, Wang L, Tibone JE, Struhl S and Lee TQ: A biomechanical assessment of a novel double endobutton technique versus a coracoid cerclage sling for acromioclavicular and coracoclavicular injuries. *Knee Surg Sports Traumatol Arthrosc* 24: 1918-1924, 2016.
36. Kumar N and Sharma V: Hook plate fixation for acute acromioclavicular dislocations without coracoclavicular ligament reconstruction: A functional outcome study in military personnel. *Strategies Trauma Limb Reconstr* 10: 79-85, 2015.
37. Lu D, Wang T, Chen H and Sun LJ: A comparison of double Endobutton and triple Endobutton techniques for acute acromioclavicular joint dislocation. *Orthop Traumatol Surg Res* 102: 891-895, 2016.
38. Hu WY, Yu C, Huang ZM and Han L: Double Endobutton reconstructing coracoclavicular ligament combined with repairing acromioclavicular ligament at stage I for the treatment of acromioclavicular dislocation with Rockwood type III-V. *Zhongguo Gu Shang* 28: 500-503, 2015 (In Chinese).
39. Struhl S, Wolfson TS and Kummer F: Axial-plane biomechanical evaluation of 2 suspensory cortical button fixation constructs for acromioclavicular joint reconstruction. *Orthop J Sports Med* 16: 2325967116674668, 2016.
40. Struhl S and Wolfson TS: Continuous loop double endobutton reconstruction for acromioclavicular joint dislocation. *Am J Sports Med* 43: 2437-2444, 2015.
41. Beris A, Lykissas M, Kostas-Agnantis I, Vekris M, Mitsionis G and Korompilias A: Management of acute acromioclavicular joint dislocation with a double-button fixation system. *Injury* 44: 288-292, 2013.
42. Li H, Wang C, Wang J, Wu K and Hang D: Restoration of horizontal stability in complete acromioclavicular joint separations: Surgical technique and preliminary results. *Eur J Med Res* 18: 42, 2013.
43. Constant CR and Murley AH: A clinical method of functional assessment of the shoulder. *Clin Orthop Relat Res*: 160-164, 1987.
44. Amstutz HC, Sew Hoy AL and Clarke IC: UCLA anatomic total shoulder arthroplasty. *Clin Orthop Relat Res*: 7-20, 1981.
45. Richards RR, An KN, Bigliani LU, Friedman RJ, Gartsman GM, Gristina AG, Iannotti JP, Mow VC, Sidles JA and Zuckerman JD: A standardized method for the assessment of shoulder function. *J Shoulder Elbow Surg* 3: 347-352, 1994.
46. Dawson J, Fitzpatrick R and Carr A: The assessment of shoulder instability: The development and validation of a questionnaire. *J Bone Joint Surg Br* 81: 420-426, 1999.
47. Beitzel K, Cote MP, Apostolakis J, Solovyova O, Judson CH, Ziegler CG, Edgar CM, Imhoff AB, Arciero RA and Mazzocca AD: Current concepts in the treatment of acromioclavicular joint dislocations. *Arthroscopy* 29: 387-397, 2013.
48. Takase K and Yamamoto K: Changes in surgical procedures for acromioclavicular joint dislocation over the past 30 years. *Orthopedics* 36: e1277-e1282, 2013.
49. Arirachakaran A, Boonard M, Piyapittayanun P, Kanchanatawan W, Chaijenkij K, Prommahachai A and Kongtharvonskul J: Post-operative outcomes and complications of suspensory loop fixation device versus hook plate in acute unstable acromioclavicular joint dislocation: A systematic review and meta-analysis. *J Orthop Traumatol*, Feb 25, 2017 (Epub ahead of print).
50. Murena L, Vulcano E, Ratti C, Ceconello L, Rolla PR and Surace MF: Arthroscopic treatment of acute acromioclavicular joint dislocation with double flip button. *Knee Surg Sports Traumatol Arthrosc* 17: 1511-1515, 2009.
51. Korsten K, Gunning AC and Leenen LP: Operative or conservative treatment in patients with Rockwood type III acromioclavicular dislocation: A systematic review and update of current literature. *Int Orthop* 38: 831-838, 2014.
52. Balke M, Schneider MM, Akoto R, Bähis H, Bouillon B and Banerjee M: Acute acromioclavicular joint injuries: Changes in diagnosis and therapy over the last 10 years. *Unfallchirurg* 118: 851-857, 2014.
53. González-Erreguín V and Morales-Villanueva J: Surgical treatment of acute acromioclavicular dislocation Preliminary report. *Acta Ortop Mex* 29: 203-206, 2015 (In Spanish).
54. Ejam S, Lind T and Falkenberg B: Surgical treatment of acute and chronic acromioclavicular dislocation Tossy type III and V using the Hookplate. *Acta Orthop Belg* 74: 441-445, 2008.
55. Nühtern JV, Sellenschloh K, Bishop N, Jauch S, Briem D, Hoffmann M, Lehmann W, Pueschel K, Morlock MM, Rueger JM and Großterlinden LG: Biomechanical evaluation of 3 stabilization methods on acromioclavicular joint dislocations. *Am J Sports Med* 41: 1387-1394, 2013.



56. McKee MD: Operative fixation of chronic acromioclavicular joint dislocation with hook plate and modified ligament transfer. *J Orthop Trauma* 30 (Suppl 2): S7-S8, 2016.
57. Lee CH, Shih CM, Huang KC, Chen KH, Hung LK and Su KC: Biomechanical analysis of implanted clavicle hook plates with different implant depths and materials in the acromioclavicular joint: A finite element analysis study. *Artif Organs* 40: 1062-1070, 2016.
58. Lin HY, Wong PK, Ho WP, Chuang TY, Liao YS and Wong CC: Clavicular hook plate may induce subacromial shoulder impingement and rotator cuff lesion-dynamic sonographic evaluation. *J Orthop Surg Res* 9: 6, 2014.
59. Sun S, Gan M, Sun H, Wu G, Yang H and Zhou F: Does subacromial osteolysis affect shoulder function after clavicle hook plating?. *Biomed Res Int* 2016: 4085305, 2016.
60. Shih CM, Huang KC, Pan CC, Lee CH and Su KC: Biomechanical analysis of acromioclavicular joint dislocation treated with clavicle hook plates in different lengths. *Int Orthop* 39: 2239-2244, 2015.
61. Coale RM, Hollister SJ, Dines JS, Allen AA and Bedi A: Anatomic considerations of transclavicular- transcoracoid drilling for coracoclavicular ligament reconstruction. *J Shoulder Surg* 22: 137-144, 2013.
62. Chaudry SN and Waseem M: Clavicular hook plate: Complications of retaining the implant. *Injury* 37: 665, 2006.
63. Steinbacher G, Sallent A, Seijas R, Boffa JM, Espinosa W and Cugat R: Clavicular hook plate for grade-III acromioclavicular dislocation. *J Orthop Surg (Hong Kong)* 22: 329-332, 2014.
64. Jafary D, Keihan Shokouh H, Najd Mazhar F, Shariat Zadeh H and Mochtary T: Clinical and radiological results of fixation of acromioclavicular joint dislocation by hook plates retained for more than five months. *Trauma Mon* 19: e13728, 2014.



This work is licensed under a Creative Commons Attribution-NonCommercial-NoDerivatives 4.0 International (CC BY-NC-ND 4.0) License.