

## A rare case of Buschke–Löwenstein tumor in HPV-negative patient

Anfisa Lepekhova, Ekaterina Dunaeva, Natalia Teplyuk, Ekaterina Vertieva  
Sechenov University, Department of Dermatology and Venereology, Moscow, Russian Federation

### Abstract

Buschke–Löwenstein tumor is known to manifest not only in sexually active people and adolescents exposed to violence or drugs, but also in people who do not have any predisposing factors or bad habits. Several studies have shown that in the majority of children with anogenital warts, HPV can be transmitted asexually by hetero-inoculation or through infected objects. To our knowledge, there are currently few reports on BLT in HPV-negative patients in the literature. In our case, the patient presented early, with multiple slow growing warts, no history of alcohol intake, drug use or smoking and no HPV infection, which makes this case unique and important.

### Case Report

We describe a rare case of genital rash in a 21-year-old HPV-negative woman who first sought medical attention in December 2018. Verrucous lesions up to 0.5 cm in diameter first appeared 6 years ago (Figure 1a). They were treated with 1000 mg isoprinosine three times a day and glycyrrhizic acid spray with limited effect. The mass continued growing for one year. She had no history of homo – or heterosexual contact, alcohol intake, drug use or smoking.

Polymerase chain reaction and Pap smear didn't detect HPV infection.

The pathology report showed acanthosis, koilocytosis, papillomatosis and hyperkeratosis with the single lymphocytes in the thickness of the epidermis. In the papillary and reticular layer of the dermis the macrophage and lymphocyte infiltration with plasma cells and eosinophilic granulocytes was determined. There was no evidence of malignancy (Figure 1c). Histopathological examination revealed Buschke–Loewenstein tumour. Warty carcinoma (a variant of a well-differentiated SCC) was also excluded.

Magnetic resonance imaging did not find any infiltration into the deeper tissue

layers. The findings pointed to Buschke–Löwenstein Tumor (BLT; Figure 2).

Three injections of interferon- $\alpha$ 2c (1 MU every other day) and 5% imiquimod cream (three times a week) were prescribed. The lesions responded to therapy. However, in one month we observed recurrence that prompted surgical removal with radiotherapy. Following that, interferon- $\alpha$ 2b injections (3 MU 3 times weekly for 24 weeks) were prescribed (Figure 1b). For a year, the patient reported no recurrence of lesions.

Giant condyloma acuminata or Buschke–Löwenstein Tumor (BLT) is a rare presentation of the Human Papillomavirus (HPV) infection that is mainly seen in immunocompromised patients – people with vitamin deficiencies, infections of the genitourinary system, chronic diseases, HIV-positive people and patients after radiation therapy.<sup>1</sup>

Genital lesions are mainly caused by HPV subtypes 6, 11, 16 and 18, but there are few articles on BLT in HPV-negative patients.<sup>2,3</sup>

For example, in 2017 Rajeev Patel, *et al.* reported on a HPV-negative patient with active BLT growth.<sup>2</sup> In 2018, Osman Akdag, *et al.* also presented a rare case of BLT in an HPV- and HIV-negative patient.<sup>1</sup> There have also been other reports on HPV-negative patients with BLT. In 2017, Manish K. Gaur, *et al.* described a 16-year-old teenager without a history of sexual intercourse who tested negative for HIV,

Anfisa Lepekhova, Sechenov University, 4 Bolshaya Pirogovskaya Street, Building 1, Moscow, 119991, Russian Federation.  
E-Mail: anfisa.lepekhova@yandex.ru,  
Tel: +79 035433074.

Conflict of interest: The authors declare no potential conflict of interests.

Key words: Buschke–Löwenstein tumor; HPV-negative patient.

Received for publication: 4 November 2019.  
Accepted for publication: 17 July 2020.

This work is licensed under a Creative Commons Attribution-NonCommercial 4.0 International License (CC BY-NC 4.0).

©Copyright: the Author(s), 2020  
Licensee PAGEPress, Italy  
Dermatology Reports 2020; 12:8372  
doi:10.4081/dr.2020.8372

hepatitis C and B; but unfortunately, the authors did not indicate the presence or absence of HPV.<sup>4</sup>

BLT is known to manifest not only in sexually active people and adolescents exposed to violence or drugs, but also in people who do not have any predisposing factors or bad habits. Several studies have shown that in the majority of children with anogenital warts, HPV can be transmitted asexually by hetero-inoculation (e.g. from

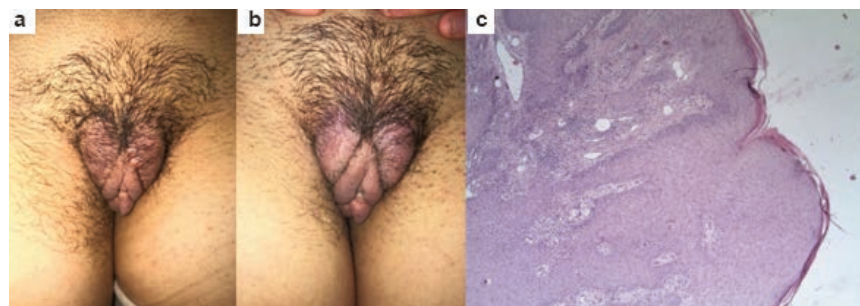

Figure 1. (a) Verrucous lesions up to 0.5 cm in diameter. (b) Regression of the lesions after the treatment. (c) Histopathological findings (HE, 40x). Acanthosis, koilocytosis, papillomatosis, macrophage and lymphocyte infiltration with plasma cells and eosinophilic granulocytes in the dermis and no signs of dysplasia.

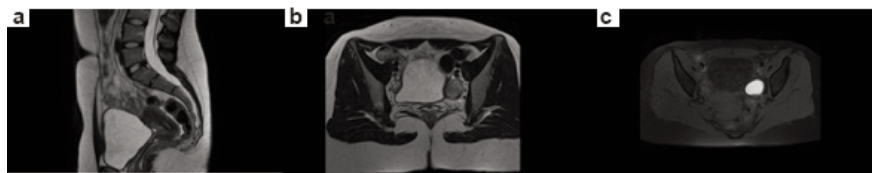


Figure 2. MRI of the pelvis did not show extensive infiltration of the mass. (a) Sagittal T2 – normal female pelvis. (b) Axial T2 – normal female pelvis. (c) Axial T1 – normal female pelvis.

the babysitter) or through infected objects.<sup>3,5</sup>

In our case, the patient presented early, with multiple slow growing warts, no history of alcohol intake, drug use or smoking and no HPV infection, which makes this case unique and important.

To our knowledge, there are currently few reports on BLT in HPV-negative patients in the literature. In such cases, it is important to rely on clinical and histopathological data. Moreover, accurate history taking is critical for prompt identification of the causative factor.

## References

1. Akdag O, Yildiran G. Malign Differentiation of a Large Buschke Loewenstein Tumor in Penis. *Surg J (N Y)*. 2018;4:e53-e4. doi: 10.1055/s-0038-1635571
2. Patel R, Kaloucava S. A case of penile Buschke-Lowenstein tumor in a developing country. *Clin Case Rep* 2017;5:257-9. doi: 10.1002/ccr3.805
3. Sinal SH, Woods CR. Human papillomavirus infections of the genital and respiratory tracts in young children. *Semin Pediatr Infect Dis* 2005;16:306-16. doi: 10.1053/j.spid.2005.06.010
4. Gaur MK, Goel A, Gupta S. Perianal cauliflower. *ANZ J Surg* 2017;87:850. doi: 10.1111/ans.14152
5. Akpadjan F, Adégbidi H, Attinsounon CA, et al. A case of recurring giant condyloma of vulva in infant without sexual abuse successfully treated with electrocoagulation in Benin. *Pan Afr Med J* 2017;27:159. doi: 10.11604/pamj.2017.27.159.11998