

Severe Coronary Vasospasm Complicated with Ventricular Tachycardia

Göksel Acar, Serdar Fidan, Servet İzci and Anıl Avcı

Kartal Koşuyolu High Specialty Education and Research Hospital, Cardiology Department, Istanbul - Turkey

Introduction

Variant form of angina was first described by Prinzmetal as transient and recurrent coronary spasm leading to recurrent episodes of myocardial ischemia¹. Although so many factors can trigger or aggravate coronary vasospasm; endothelial dysfunction was considered as an important mechanism underlying this situation. The location and extent of vasospasm determine the seriousness of the clinical picture, which can include myocardial infarction severe arrhythmias, cardiogenic shock and even death².

Case Report

A 68-year-old male was admitted to our emergency department complaining of severe chest pain for 4 hours. On physical examination his vital findings were within the normal limits with a slightly high blood pressure reading 150/90 mmHg, a regular pulse 80/min, a respiratory rate 15/min. His 12-lead electrocardiogram (ECC) showed 1 mm ST depression in lateral leads without significant ST elevation or T wave abnormality in other leads. The patient had a history of hypertension and a coronary angiography which was performed 10 days before in another hospital. The patient reported that he had had similar type of chest pain 10 days before and because of that a coronary angiography had been performed. There was not any critical lesion on his coronary angiography and he had been discharged on metoprolol 50mg and aspirin 100mg because of noncritical coronary lesions (Figure 1A, 1B). A bed side transthoracic echocardiogram revealed posterolateral wall hypokinesis with an ejection fraction around 50-55 %. The patient's cardiac enzyme levels on admission were above normal with a troponin T level 4.2 ng/ml (<0,01ng/ml) and CK-MB level 8.3 u/l (< 2 u/l). He was diagnosed with non ST elevated myocardial infarction and appropriate treatment was started including aspirin, clopidogrel, heparin and sublingual nitroglycerine. Just seconds before starting treatment, the patient condition deteriorated. He had a pulseless ventricular tachycardia attack which was successfully returned to sinus rhythm by defibrillation without need for endotracheal intubation. We performed an urgent coronary angiography because of ongoing ischemia and

malign arrhythmia. The angiography revealed out severe stenosis of circumflex artery (Figure 2A, 2B, 2C), noncritical plaques in left anterior descending and right coronary artery. To rule out coronary vasospasm, 300 microgram nitroglycerine was injected intracoronary before percutaneous coronary intervention (PCI). Although an increase in the distal flow of circumflex artery was observed, the view of occluded area has not changed much (Figure 2D). So we decided for PCI. Soon after advancing the floppy guide wire through circumflex artery, the occluded area seemed to be relieved (Figure 2E). We removed back the guide wire and injected 500mcg nitroglycerine directly to the coronary circulation. After applying increasing doses of nitroglycerin up to 500 mcg into the coronary circulation, final angiographic image demonstrated fully dilated circumflex artery without any stenotic lesion (Figure 2F). The patient was diagnosed with non ST elevated myocardial infarction due to variant angina. As variant angina was suspected, metoprolol was replaced by diltiazem and also the patient was discharged on nitrate and aspirin. At the 3months follow-up visit, the patient was asymptomatic and reported no chest pain episode. We followed up patient without any change in his medical treatment.

Discussion

Coronary vasospasm or variant form of angina pectoris is characterized by remarkable ST segment elevation and severe chest pain episodes usually without physical effort². Although coronary spasms usually occur in a focal area, it can be also multifocal and affect more than one coronary vessel at the same time. The definitive diagnosis is made when angiographically demonstrated coronary artery vasoconstriction reverses with nitroglycerin. The mechanism underlying variant angina is not fully identified. Although there are so many theories to enlight the mechanism of vasospastic angina, many of them focus on endothelial dysfunction and imbalance between local vasoconstrictors-vasodilators. There are ongoing discussions about nitric oxide. The results for nitric oxide are contentious². The location and extent of vasospasm determine the seriousness of the clinical picture, which can include myocardial infarction severe arrhythmias, cardiogenic shock and even death. Spasm of coronary artery reduces the myocardial perfusion and causes serious complications. In our patient, ventricular tachycardia was triggered by ongoing ischemia caused by severe circumflex artery vasospasm. The low coronary perfusion at the area of spasm probably prevented the collection of sufficient concentration of nitrate. This can be the probable mechanism for resistant vasospasm after first injection of 300mcg nitrates³.

Calcium channel blockers and long acting nitrates are first-line treatment choices for coronary vasospasm. Also there are studies showing beneficial effects of prazosin and nicorandil (potassium channel activator) on variant angina^{4,5}. Beside these medical treatment options, surgical or percutaneous revascularization therapies can be thought

Palavras-chave

Coronary Vasospasm; Angina Pectoris; Coronary Angiography; Nitrates / therapeutic use.

Mailing Address: Serdar Fidan •

Kartal Kosuyolu High Specialty Education and Research Hospital Kartal / Istanbul, Denizir Street, 34846.

Email: dr_serdar86@hotmail.com

Manuscript received October 10, 2013; revised manuscript 18 December, 2013; accepted December 27, 2013.

DOI: 10.5935/abc.20140166

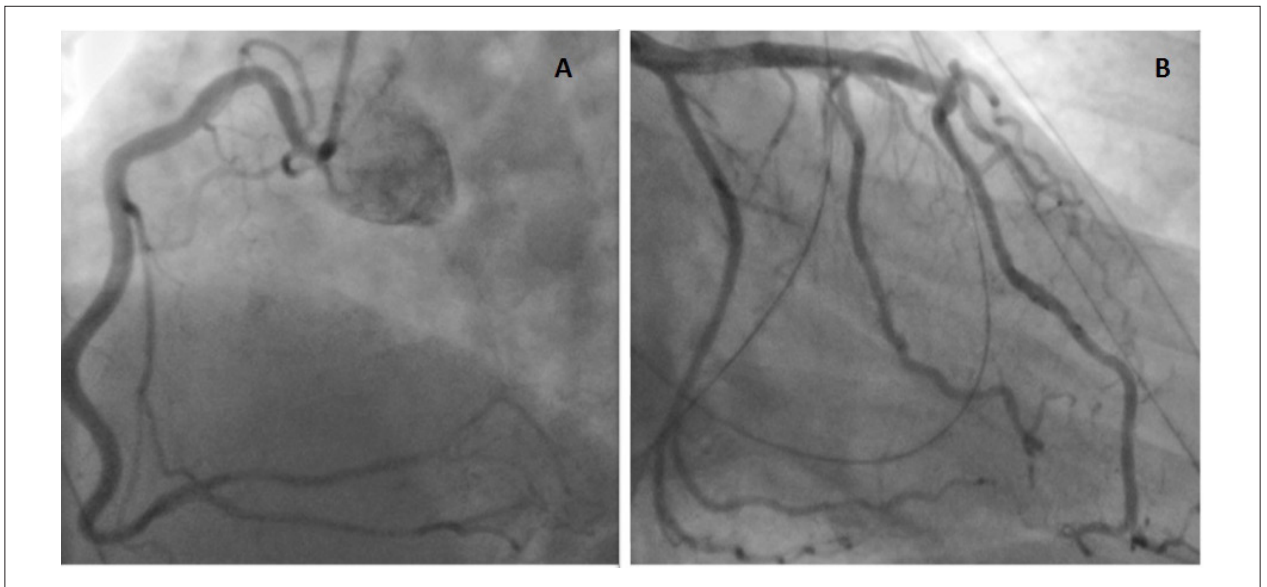


Figure 1 – Images of the coronary angiography of the patient which was performed 10 days before admission, demonstrating right (A) and left coronary arteries (B).

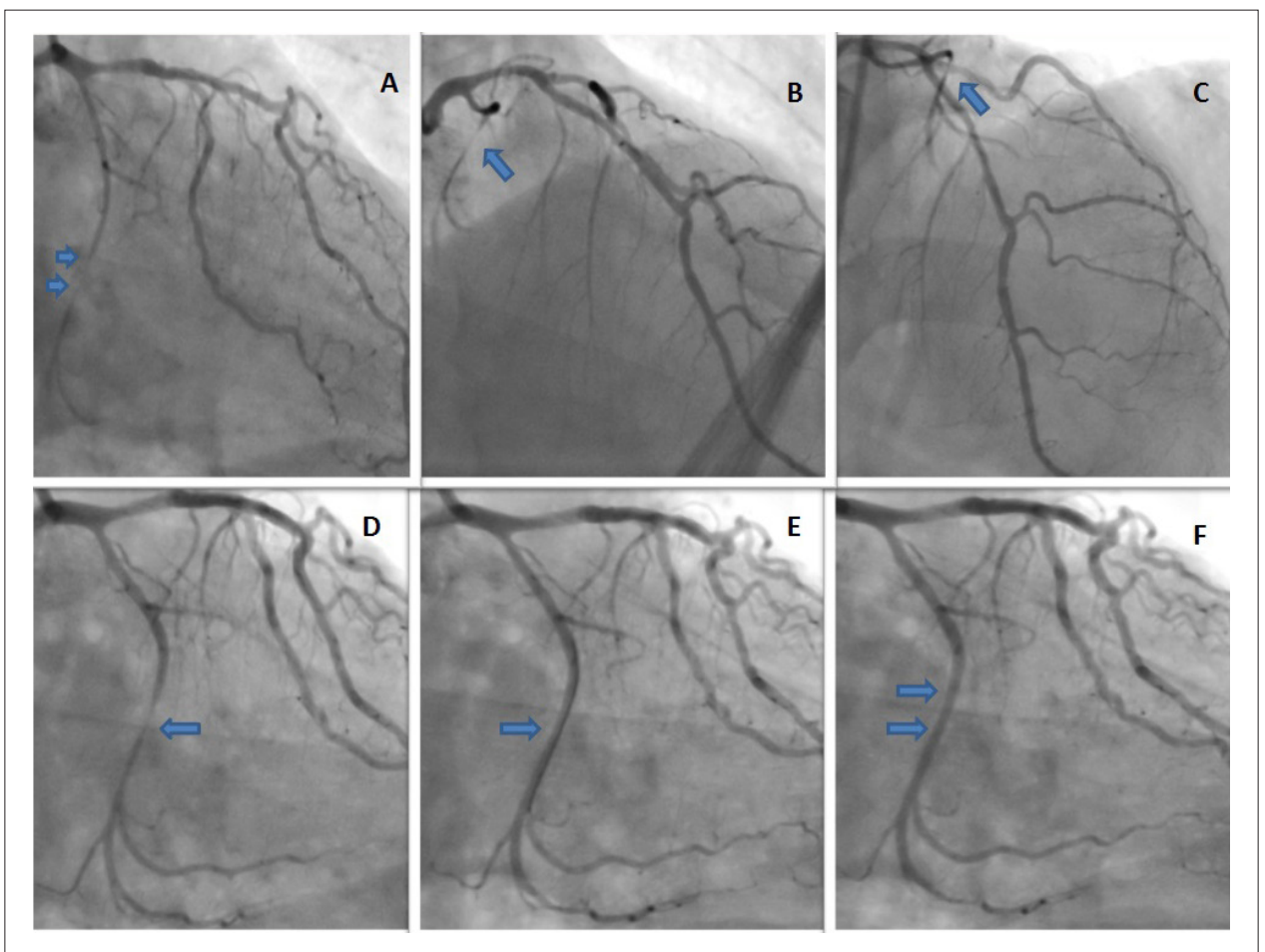


Figure 2 – Coronary angiographic images demonstrating severe circumflex artery spasm from right oblique caudal (A) and right oblique cranial views (B,C), arrows. Increased distal flow despite incomplete resolution of circumflex artery spasm after injection of 300 mcg nitroglycerine (D), arrows. After advancing the floppy guide wire through circumflex artery, the occluded area seemed to be relieved (E). Final angiographic image showing fully dilated circumflex artery after injection of 500 mcg nitroglycerine (F).

Case Report

for those refractory to medical treatment. Risk factor modification against known atherosclerotic disease also should be kept in mind.

Conclusion

Our case is an unusual presented variant angina without ST segment elevation on admission ECG. Vasospastic angina always should be kept in mind because it can lead to serious life threatening complications. Since there are some different treatments for the variant angina and atherosclerotic coronary arterial disease, the differential diagnosis must be done carefully. This case report emphasizes the importance of intracoronary usage of nitrates to rule out coronary vasospasm before the percutaneous coronary interventions. Proper use of nitroglycerin could prevent unnecessary coronary interventions.

Author contributions

Analysis and interpretation of the data: Acar G and İzci S; Writing of the manuscript: Acar G; Critical revision of the manuscript for intellectual content: Fidan S and Avcı A.

Potential Conflict of Interest


No potential conflict of interest relevant to this article was reported.

Sources of Funding


There were no external funding sources for this study.

Study Association


This study is not associated with any thesis or dissertation work.



Video 1 – Coronary angiography which was performed 10 days before admission demonstrating left coronary system without critical lesions.



Video 2 – *Coronary angiography demonstrating severe circumflex artery spasm from right oblique cranial view.*




Video 3 – *Coronary angiography demonstrating severe circumflex artery spasm from right oblique caudal view.*

Case Report



Video 4 – *Coronary angiography showing incomplete resolution of circumflex artery spasm after injection of 300 mcg nitroglycerin.*



Video 5 – *Completely dilated circumflex artery after injection of 500 mcg nitroglycerine.*

References

1. Prinzmetal M, Kennarmer R, Merliss R, Wada T, Bor N. Angina pectoris. I. A variant form of angina pectoris; preliminary report. *Am J Med.* 1959;27:375-88.
2. Stern S, Bayes de Luna A. Coronary Artery Spasm: A 2009 Update. *Circulation.* 2009;119(18):2531-4.
3. Sung LC, Chen CH, Hou CJ, Tsai CH. Severe coronary vasospasm during an acute myocardial infarction with cardiogenic shock. *J Intern Med Taiwan.* 2005;16:129-33.
4. Tzivoni D, Keren A, Benhorin J, Gottlieb S, Atlas D, Stern S. Prazosin therapy for refractory variant angina. *Am Heart J.* 1983;105(2):262-6.
5. Kaski JC. Management of vasospastic angina -- role of nicorandil. *Cardiovasc Drugs Ther.* 1995;9 Suppl 2:221-7.