

# LIGHT AND ELECTRON MICROSCOPE LOCALIZATION OF BINDING SITES OF ANTIBODIES AGAINST OVINE LUTEINIZING HORMONE AND ITS TWO SUBUNITS IN RAT ADENOHYPHYSIS USING PEROXIDASE-LABELED ANTIBODY TECHNIQUE

C. TOUGARD, B. KERDELHUE, A. TIXIER-VIDAL, and M. JUTISZ

From the Laboratoire de Biologie Moléculaire, Centre National de la Recherche Scientifique, Collège de France, Paris 75005, and the Laboratoire des Hormones Polypeptidiques, Centre National de la Recherche Scientifique, Gif-sur-Yvette 91190, France

## ABSTRACT

The binding sites of antisera generated in the guinea pig against ovine luteinizing hormone (oLH) and its two subunits (oLH $\alpha$  and oLH $\beta$ ) have been localized in rat anterior pituitaries taken from normal or castrated males and from ovariectomized females with the peroxidase-labeled antibody method, using light and electron microscopy. With the light microscope, the cells positive with antiserum to ovine luteinizing hormone (A-oLH) were violet after the Alcian blue-periodic acid-Schiff (AB-PAS) staining; they were also positive for A-oLH $\alpha$  and for A-oLH $\beta$  and, from castrated males, they displayed an increased affinity for A-oLH $\beta$ . Another cell type which was blue after the AB-PAS method reacted with the A-oLH $\alpha$  only; these cells, presumably thyrotropic cells, were retracted after castration and, besides their affinity for A-oLH $\alpha$ , acquired an affinity for A-oLH $\beta$ . As seen through the electron microscope, two cell types were positive for A-oLH, A-oLH $\beta$ , and A-oLH $\alpha$  and may be identified as luteinizing hormone-secreting cells. Type A cells were characterized by two classes of rounded, secretory granules. Type B cells were smaller and contained only small secretory granules. 1 mo after the rats were castrated the type A cells were hypertrophied and vacuolized. In both cases the secretory granules were the main sites of the antigenicity with the three antisera. A positive reaction was also found in the cytoplasm, particularly in hypertrophied cells from ovariectomized females and with A-oLH $\beta$ . The cisternae of the rough endoplasmic reticulum were usually negative, except in highly degranulated cells from ovariectomized females and with A-oLH $\beta$ .

## INTRODUCTION

The site of production of the two gonadotropins, luteinizing hormone (LH)<sup>1</sup> and follicle-stimu-

lating hormone (FSH), within the rat pituitary is not yet clearly established. Such a problem could

<sup>1</sup> *Abbreviations used in this paper:* A-bLH, antiserum to bovine luteinizing hormone; A-bTSH, antiserum to bovine thyrotropic hormone; AB-PAS, Alcian blue-periodic acid-Schiff; ACTH, adrenocorticotropin

hormone; A-IgG-Per, sheep anti-guinea pig immunoglobulin bound to peroxidase; A-oLH, antiserum to ovine luteinizing hormone; A-oLH $\alpha$ , antiserum to ovine LH $\alpha$ ; A-oLH $\beta$ , antiserum to ovine LH $\beta$ ; AS,

be examined in the light of recent data concerning the subunit nature of LH and FSH (11, 32, 33). In several mammalian species two subunits,  $\alpha$  and  $\beta$ , have been isolated from LH and FSH as well as from thyrotropic hormone (TSH). Furthermore, it is known that the  $\alpha$ -subunits of bovine LH and TSH have a similar structure. The  $\beta$ -subunits contain some common sequences but are not identical. The latter determine the specificity of the biological activity of their respective hormones (see review by Jutisz and De La Llosa, [19]).

The main objectives of this study were, (a), with the use of the light microscope to describe the cell types revealed by antisera to ovine LH (A-oLH), ovine LH $\alpha$  (A-oLH $\alpha$ ), and ovine LH $\beta$  (A-oLH $\beta$ ) and to correlate the results with histochemical staining and with experimental modifications of the pituitary-gonadal axis and (b), with the electron microscope to describe the ultrastructural features of the same cells and to contribute original information about the subcellular localization of the native hormone as compared to those of its two subunits.

We have already shown (38, 39) with the light microscope that in normal male and ovariectomized female rats the gonadotropic cells are immunohistochemically stained by A-oLH, A-oLH $\beta$ , and A-oLH $\alpha$ . These cells take a violet color after staining with the Alcian blue-periodic acid-Schiff (AB-PAS) histochemical method. Another cell type was always stained with the A-oLH $\alpha$  but never with A-oLH. The latter take a blue color with the AB-PAS method and were therefore presumed to be thyrotropic cells. More recently, Baker et al. (4) using antiserum to bovine thyrotropic hormone (A-bTSH), antiserum to bovine luteinizing hormone (A-bLH), and to their respective subunits found the same localization of the A-bLH, A-bLH $\beta$ , and A-bLH $\alpha$  within the gonadotropic cells of normal male and female rats as well as of ovariectomized and orchietomized rats. They nevertheless did not characterize these cells histochemically. They moreover found that the cells which react with A-bLH $\alpha$  were also

antiserum; DAB, 3-3'-diamino-benzidine tetrahydrochloride; FSH, follicle-stimulating hormone; LH, luteinizing hormone; NGPS, normal guinea pig serum; PAF, paraformaldehyde-picric acid; PBS, phosphate-buffered saline; RER, rough endoplasmic reticulum; rLH, rat luteinizing hormone; TSH, thyrotropic hormone.

stained with A-bTSH which clearly demonstrates that they are thyrotropic cells.

Preliminary results on the ultrastructural features of the cells which react with the three antisera (AS) have been previously reported (39). The subcellular sites of LH and its two subunits are identical.

## MATERIALS AND METHODS

### *Pituitaries*

Pituitaries from three types of rats were used in this study: (a) Normal adult male rats (Wistar and Sprague Dawley). (b) Castrated male rats (Wistar). Castration was performed on 1-mo old rats which were sacrificed 3½ mo later. Some of them were injected with 1.5 mg of testosterone propionate in 0.5 ml sesame oil and sacrificed 48 h later (c) Ovariectomized female rats (Wistar). Ovariectomy was performed on 1-mo old rats which were sacrificed 1 or 2 mo later. Some of them were injected subcutaneously with 25  $\mu$ g oestradiol benzoate and 12.5 mg progesterone in 0.5 ml sesame oil and sacrificed 72 h later.

### *Preparation of Tissues and Immunochemical Staining Procedure*

**LIGHT MICROSCOPE STUDY:** The pituitaries were fixed for 8 days in Bouin Hollande fixative without acetic acid and with 10% HgCl<sub>2</sub> according to Herlant (15). After embedding them in paraffin they were sectioned at 5  $\mu$ m, horizontal serial sections being made. The sections were deparaffined and washed in running tap water overnight, then rinsed in 0.01 M phosphate buffer with 9‰ NaCl (phosphate-buffered saline, PBS), pH 7.45.

The immunohistochemical staining procedure involved the following steps: (a) incubation with a specific AS diluted 1:100 for 1½ h at room temperature, (b) washing in PBS three times for 10 min, (c) incubation with sheep antiginea pig immunoglobulin bound to peroxidase (A-IgG-Per) diluted 1:10 for 1½ h, (d) washing again in PBS. (e) Finally the peroxidase was revealed by 3-3'-diamino-benzidine tetrahydrochloride (DAB) (Sigma Chemical Co., St. Louis, Mo.) according to Graham and Karnovsky (14).

For the simultaneous detection of two antigens the method described by Nakane (30) was applied. Two peroxidase substrates were used. DAB gave a yellowish staining and 4-chloro-1-naphthol (Aldrich Chemical Co., Inc., Milwaukee, Wis.) gave a bluish staining. The sections were treated for the first specific AS according to the method described above and the peroxidase complex was revealed with

DAB. The sections were then eluted with 0.05 N HCl for 2 h and washed in PBS overnight. They were then treated for the second specific AS and the peroxidase complex was revealed with the 4-chloro-1-naphthol-H<sub>2</sub>O<sub>2</sub> solution. Elution breaks the binding between the antigen and its antibody, but the DAB staining reaction remains. This was confirmed on control sections according to Nakane (30).

In order to correlate immunohistochemical and histochemical staining, the stained sections were temporarily mounted in glycerin and photographed and the coordinates of each photographed field were noted. The sections were then dismounted and bleached either with ethanol and toluene for the 4-chloro-1-naphthol staining or by oxidation with sulfuric permanganate for the DAB staining. They were then stained with the AB-PAS-Orange G method according to Herlant (15). The fields previously photographed were reexamined and rephotographed with the same light microscope. This method allowed comparing the immunohistochemical staining and the histochemical identification of glycoproteins in the same cell.

**ELECTRON MICROSCOPE STUDY:** A modification of the Nakane's technique for thick sections (31) was used. The pituitaries were fixed in paraformaldehyde-picric acid (PAF) (42) for 8 h at 4°C and washed overnight in 0.1 M phosphate buffer pH 7.3 with 10% sucrose. Thick sections (30 μm) were cut without freezing with a Sorvall TC2 sectioner. The sections were washed in 0.01 M PBS pH 7.45 for 1 h, then incubated with specific AS diluted 1:20 for 5 h at room temperature with continuous stirring. They were then washed in PBS overnight, incubated with A-IgG-Per diluted 1:10 for 5 h, and washed again in PBS overnight. Treated sections were postfixed in 1% glutaraldehyde in 0.2 M cacodylate buffer pH 7.4 with 1% sucrose for 2 h, then washed in the same buffer, and stained for peroxidase using Graham and Karnovsky's procedure (14). Tissues were first impregnated with DAB solution without H<sub>2</sub>O<sub>2</sub> for 1 h, then incubated in a complete medium (DAB plus H<sub>2</sub>O<sub>2</sub> in Tris maleate buffer) for 15 min at room temperature while stirring, according to the method of Nakane (31). The stained sections were washed in Tris maleate buffer, postfixed for 30 min in 2% osmium tetroxide, dehydrated gradually in ethanol and embedded in araldite (6). Thin sections (gold) were cut on a Porter-Blum MT-2 ultramicrotome and examined under the electron microscope without further staining. Alternate 1-μm thick sections were cut and examined with a light microscope in order to check the presence of immunoreactive cells.

### *Production of Antisera*

AS against oLH, oLH $\alpha$ , and oLH $\beta$  were obtained in the guinea pig using the immunization schedule

previously described (20). For this immunization, the following antigens obtained in our laboratory (Laboratoire des Hormones Polypeptidiques) were used: oLH (LH-M1: 1.83  $\times$  NIH-LH-S3) (18) and oLH subunits prepared by Dr. Tertrin-Clary according to the method of Papkoff and Samy (33).

The AS against guinea pig gamma globulins were prepared in sheep by Dr. G. Kann (INRA, Jouy-en-Josas), using an antigen of commercial origin (Cohn fraction II, Eurobio, Paris). Antibodies were isolated from sheep sera using specific absorption on a guinea pig gamma globulin polymer. The isolated antibodies were finally linked to horseradish peroxidase as described by Avrameas (1).

After preliminary experiments with the light microscope, the dilution of each AS for the cyto-immunochemical studies was chosen in a manner such that a maximum reaction was obtained. Subsequently, the same optimal dilution was adopted for the three specific AS (1:100 for light microscope study, 1:20 for electron microscope study).

### *Specificity of Immunochemical Reaction*

In order to test the specificity of the immunohistochemical reaction, at light and electron microscope levels, control sections were submitted to the following treatments: (a) DAB reaction without any incubation with AS, (b) Specific AS, then DAB reaction, (c) Normal guinea pig serum (NGPS), then DAB reaction, (d) A-IgG-Per, then DAB reaction, (e) NGPS, then A-IgG-Per, then DAB reaction, (f) specific AS, then A-IgG-Per, and finally the DAB reaction in medium without H<sub>2</sub>O<sub>2</sub>.

The specificity of the three AS has also been tested at the immunohistochemical level by using AS which have been preabsorbed with three doses of the following antigens: oLH, oLH $\alpha$ , oLH $\beta$ , oFSH (laboratory preparation, potency 8  $\times$  NIH-FSH-S<sub>1</sub>), bTSH (kindly supplied by Dr. Y. A. Fontaine, Laboratoire de Physiologie du Museum, Paris, potency 35 U/mg). In addition A-oLH $\alpha$  was absorbed with three doses of porcine ACTH (Choay, Paris). The detail of this treatment is described in the Table I. The 51 samples of preabsorbed AS have been tested at light microscope level on normal male and ovariectomized female pituitary sections. At electron microscope level only AS which were absorbed with their homologous antigen were used.

## RESULTS

### *Characterization of AS*

The titer of each AS was determined by means of iodinated antigen. Taking the binding affinity of an AS as equal to one for its respective antigen, the affinities for other antigens in the case of LH

TABLE I  
Effect of Preabsorption of AS with Hormones on Immunochemical Staining of LH Cells\*

AS†	Unab- sorbed	Antigen absorbant																	
		oLH			oLH $\alpha$			oLH $\beta$			oFSH			bTSH			ACTH		
		a	b	c	a	b	c	a	b	c	a	b	c	a	b	c	a	b	c
A-oLH	+	-	-	-	+	+	+	$\pm$	+	+	+	+	+	+	+	+			
	+				+	+	+		+	+	+	+	+	+	+	+			
	+				+	+	+			+	+	+	+	+	+	+			
	+					+	+				+	+	+						
A-oLH $\beta$	+	-	-	-	+	+	+	-	$\pm$	+	+	+	+	+	+	+			
	+				+	+	+				+	+	+	+	+	+			
	+				+	+	+				+	+	+	+	+	+			
	+					+	+							+	+	+			
A-oLH $\alpha$	+	-	-	$\pm$	-	-	-	+	+	+	$\pm$	$\pm$	+	+	+	+	+	+	+
	+							+	+	+				+	+	+	+	+	+
	+							+	+	+							+	+	+
	+								+	+							+	+	+
										+							+	+	+

\* Signification of symbols: + + + +, maximum reaction; -, no staining;  $\pm$ , limit of detection.  
 † 1 ml of each AS diluted  $\frac{1}{20}$  was absorbed for 40 h at 4°C with (a) 6.0, (b) 4.5, and (c) 3.0  $\mu$ g of each antigen, respectively, except the LH subunits which were used at the doses of (a) 1.0, (b) 0.75, and (c), 0.5  $\mu$ g, respectively. For immunochemical staining the preabsorbed AS were diluted  $\frac{1}{100}$ .

TABLE II  
Relative Binding Affinities of AS against oLH, oLH $\alpha$  and oLH $\beta$  for the Three Antigens

Antigen	AS		
	A-oLH $\alpha$	A-oLH $\beta$	A-oLH
oLH $\alpha$	1	0.001	0.0015
oLH $\beta$	0.0002	1	1.7
oLH	0.5	0.1	1

and LH subunits were calculated and are summarized in Table II (15, 16).

These data show that oLH $\alpha$  and oLH $\beta$  have different antigenic determinants, each one eliciting a population of specific antibodies capable of binding its respective subunit and, to a certain extent (especially for A-oLH $\alpha$ ), oLH. Consequently, the binding of a given antigen requires more of an heterologous AS than an homologous AS, except for anti-oLH which binds oLH $\beta$  better than oLH.

The binding affinities of labeled ovine FSH, bovine TSH, rat LH, and rat FSH were not investigated in this system but extensive radioimmunological studies were performed using the above mentioned antigens and the following

TABLE III  
Radioimmunological Activities of Various Antigens in Three Radioimmuno-assay (RIA) Systems

Antigen	RIA system		
	oLH $\alpha$ -A-oLH $\alpha$	oLH $\beta$ -A-oLH $\beta$	oLH-A-oLH
oLH $\alpha$	100	7	9
oLH $\beta$	0.5	100	113
oLH	18	30	100
rLH	1	10	37
oFSH	4	<0.1	0.4
rFSH			0.2
bTSH	18	10	16
rTSH			3

In each case, the response is expressed as the percent of the homologous antigen.

systems: oLH $\alpha$ -A-oLH $\alpha$ , oLH $\beta$ -A-oLH $\beta$ , and oLH-A-oLH. Table III summarizes these results.

It appears that the cross-reaction between AS against oLH and against oLH $\beta$ , and rat LH (rLH) is only partial though definite. These data concerning cross-reaction of rLH with AS against

oLH and against its two subunits are in accordance with the results recently published by Vaitukaitis et al. (40). These authors have shown that  $\beta$ -subunits from at least four species of LH (human, bovine, ovine, rat) are responsible for the interspecies cross-reaction of those hormones.

Rat FSH and rat TSH do not cross-react or cross-react only slightly with anti-oLH system. bTSH which has a primary structure similar to that of oTSH (34) gave a partial cross-reaction in the three systems.

*Identification of Immunohistochemically Positive Cells with Light Microscope (Table IV)*

CONTROL SECTIONS

No staining was observed with any of the six histochemical control treatments previously described. Such treated sections displayed a general pale yellow background staining. The effects of absorption of the AS with different antigens are summarized in Table I. It is shown that preabsorption with the homologous antigen inhibited the immunochemical staining for each one of the three AS. Staining with A-oLH was only slightly inhibited by absorption with high doses of oLH $\beta$ .

Staining with A-oLH $\beta$  was completely abolished with oLH, whatever the dose used. Staining with A-oLH $\alpha$  was abolished with oLH, oFSH, and partially with bTSH. In addition preabsorption with ACTH did not alter the staining.

NORMAL MALE RAT PITUITARIES

Numerous cells were immunohistochemically stained with the three AS. Among them two types might be distinguished by their shape and their localization within the pars distalis (Fig. 1): hypertrophied cells which were mainly located in the lateral and anterior part of the pars distalis and small and oval cells which were scattered throughout the pars distalis but more numerous in its posterior part. After destaining and restaining with the AB-PAS, these two cell types displayed the same violet color indicating that they were AB and PAS positive. These cells may therefore be considered as gonadotropic cells.

One cell type was immunohistochemically stained with A-oLH $\alpha$  only. These cells had a polygonal or stellate shape and were generally localized in the medial and posterior part of the pars distalis in the vicinity of the pars intermedia (Fig. 2). After destaining and restaining with the AB-PAS, these cells were blue, indicating that

TABLE IV  
Summary of Immunohistochemical Staining with the Light Microscope of Gonadotropic and Thyrotropic Cells with Three AS\*

Pituitaries	AS	Gonadotropic cells (AB+, PAS+)	Thyrotropic cells (AB+, PAS-)
Normal ♂	A-oLH	Two types, small and large +++	Stellate shape -
	A-oLH $\beta$	+++	±
	A-oLH $\alpha$	+++	+++
	A-oLH $\alpha$ (yellowish) + A-oLH $\beta$ (bluish)	Brown LH $\alpha$ $\approx$ LH $\beta$ ‡	Yellow or brown LH $\alpha$ $\gg$ LH $\beta$ §
		Hypertrophied	Regressed
Castrated ♂ and ♀	A-oLH	+++	-
	A-oLH $\beta$	+++	++
	A-oLH $\alpha$	+++	+++
	A-oLH $\alpha$ (yellowish) + A-oLH $\beta$ (bluish)	Bluish-brown LH $\beta$ > LH $\alpha$	Yellow or brown LH $\alpha$ $\geq$ LH $\beta$ ¶

\* Signification of symbols: +++, maximum reaction; -, no staining.

‡ LH $\alpha$   $\approx$  LH $\beta$ , the staining by A-oLH $\alpha$  and by A-oLH $\beta$  have a similar intensity.

§ LH $\alpha$   $\gg$  LH $\beta$ , the staining by A-oLH $\alpha$  is much higher than the staining by A-oLH $\beta$ .

|| LH $\beta$  > LH $\alpha$ , the staining by A-oLH $\beta$  is higher than the staining by A-oLH $\alpha$ .

¶ LH $\alpha$   $\geq$  LH $\beta$ , the staining by A-oLH $\alpha$  is higher or equal to the staining by A-oLH $\beta$ .

they were exclusively AB positive. They therefore have the histochemical and morphological features of the presumably thyrotropic cells already described (7, 16) (see Discussion). These cells were never immunohistochemically stained with A-oLH and almost never with A-oLH $\beta$  (except a few cells in one animal).

Simultaneous localization on the same section of binding sites of A-oLH $\beta$  and A-oLH $\alpha$  showed that the gonadotropic cells bind the two AS equally, whereas the thyrotropic cells generally bind only A-oLH $\alpha$ .

#### CASTRATED MALE AND FEMALE RAT PITUITARIES

The results were similar in castrated females treated or untreated with oestradiol-progesterone, although the intensity of the immunohistochemical staining was greater in the former. The cells positive with the three AS were highly hypertrophied and vacuolized. They were distributed throughout the pars distalis and showed a violet color after destaining and restaining with AB-PAS. These cells represent the so-called "castration cells." The intensity of the immunohistochemical staining was not affected by time elapsed after castration. The central vacuole of the "signet-ring" cells was negative. The positive reaction was generally greatest at the periphery of the cell and lowest over the Golgi zone (Fig. 3).

Another cell type which was always negative with A-oLH displayed an immunohistochemical staining with both A-oLH $\alpha$  and A-oLH $\beta$ . These cells were very small, angular or "comma" shaped, and seemed retracted (Fig. 4). After destaining and restaining with AB-PAS they ap-

peared either chromophobic or AB-stained which suggests that they might represent the thyrotropic cells. After a longer postcastration delay these cells became highly degenerate and difficult to distinguish.

When the sections have been treated for the binding sites of both A-oLH $\alpha$  and A-oLH $\beta$ , the castration cells displayed a brown-violet color. This suggests an increased affinity of these cells for A-oLH $\beta$ . Moreover, under the same conditions, some cells stained blue violet and therefore reacted only with A-oLH $\beta$ . These were either vacuolized or very small, but always chromophobic after destaining and restaining with AB-PAS.

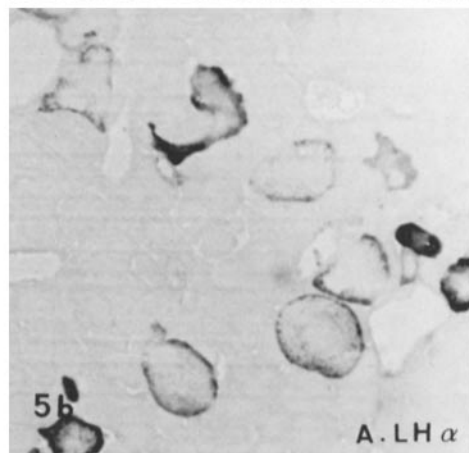
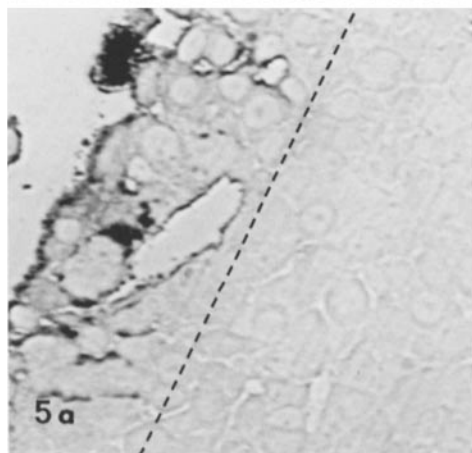
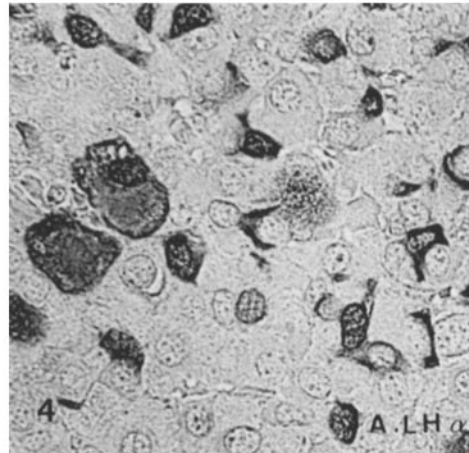
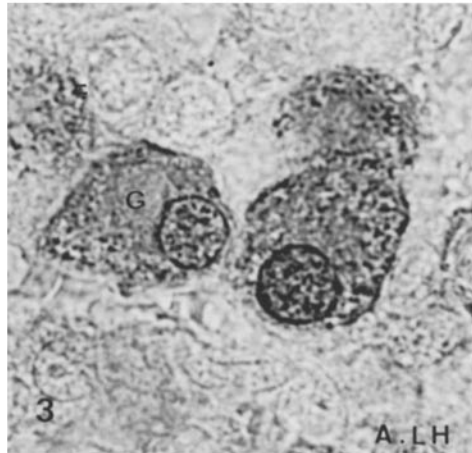
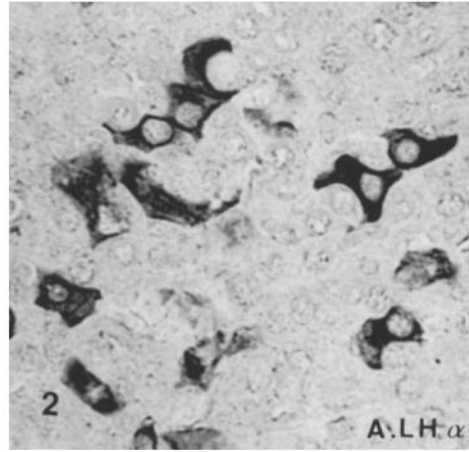
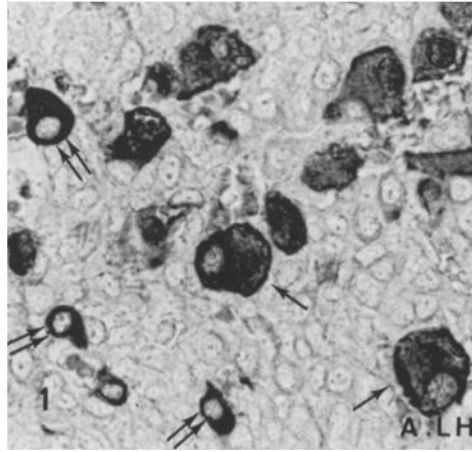
#### *Identity of the Immunohistochemically Positive Cells with the Electron Microscope*

##### NONSPECIFIC STAINING

Thick and thin sections were examined for non-specific staining after each one of the control treatments. After fixation with PAF and without any further treatment, the sections had a low contrast and the secretory granules a slight density proper to them. Control treatments gave a non-specific reaction in two cases only, with NGPS (Fig. 5 *a*) and with preabsorbed AS. In such material the reaction product was exclusively localized at the borders of the incubated tissue slices and was equally distributed over the peripheral cells which were often damaged (Fig. 5 *a*). In tissues treated with unabsorbed specific AS

---

FIGURES 1-5 Fig. 1 shows a 5- $\mu$ m paraffin section of a normal male rat pituitary treated with A-oLH. Two cell types are stained; the more numerous are large (single arrow) and the others are small and oval (double arrow) ( $\times$  530). Fig. 2 is the same material as Fig. 1 except the section is treated with A-oLH $\alpha$ . The positive cell types are localized into the medial zone. They often have a stellate shape. Such cells are negative with A-oLH and A-oLH $\beta$  ( $\times$  530). Fig. 3 shows a 5- $\mu$ m section treated with A-oLH from the anterior pituitary of a 1-mo old ovariectomized rat. The castration cells are strongly positive. The staining is intense over the secretory granules and weak over the Golgi zone (*G*). The staining of some nuclei presumably results from the superimposition over the nucleus of cytoplasm and positive secretory granules ( $\times$  1,330). Fig. 4 is the same material as Fig. 3 except the 5- $\mu$ m section is treated with A-oLH $\alpha$ . Besides the castration cells, numerous small and angular cells are also stained ( $\times$  530). Fig. 5 is a 1- $\mu$ m thick section from an araldite-embedded tissue slice from the anterior pituitary of a 1-mo old ovariectomized rat. (*a*) Control slice treated with (NGPS)-(A-IgG-Per). The reaction product is restricted to the border of the section. Such an area (i.e., left of the dotted line) has never been considered in specific AS-treated slices ( $\times$  530) (*b*) Tissue slice treated with A-oLH $\alpha$ . The positive cells appear dark and highly contrasted ( $\times$  530).



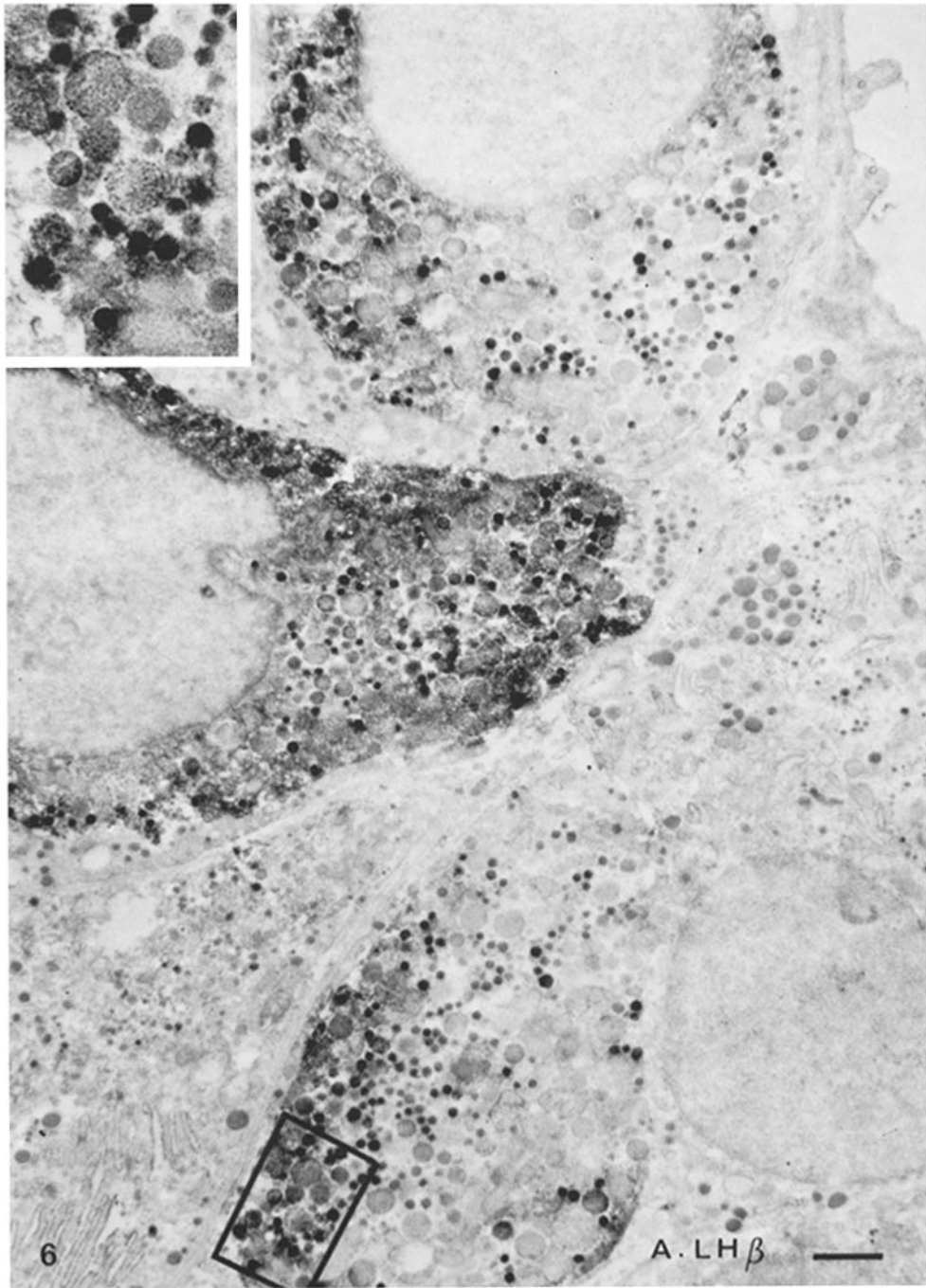


FIGURE 6 Normal male rat pituitary slice treated with A-oLH $\beta$ . Three gonadotropic cells (type A) are strongly stained. They are characterized by two types of secretory granules. The reaction product is more abundant over the small secretory granules than over the large ones (*inset*). It is also seen over the cytoplasm. The nucleus and the other cells are negative ( $\times 9,000$ . *Inset*,  $\times 21,000$ ).



this part of the sections was therefore never considered. The positive cells appeared brown and were localized more centrally, although they were absent at the core of the tissue slice (Fig. 5 *b*). This probably results from the limited penetration of the different AS into the incubated tissue slices. With the electron microscope, the positive cells were highly contrasted and were mainly identifiable by the increased density of their secretory granules and cytoplasm.

#### NORMAL MALE RAT PITUITARY

**IDENTIFICATION OF CELLS POSITIVE FOR A-OLH AND A-OLH $\beta$ :** The cellular and sub-cellular binding sites of A-OLH and A-OLH $\beta$  were identical. Two positive cell types were distinguished. Type A cells (Fig. 6) were rounded and had two classes of round secretory granules which differed in diameter. The smallest (200 nm) showed the highest staining intensity. The largest

(300–700 nm) contained various amounts of reaction product but always less than did the small secretory granules. The rough endoplasmic reticulum (RER) cisternae were often dilated and rounded. Type B cells were smaller, oval in shape, and less frequent than type A cells (Fig. 7). They contained only the small, positive, secretory granules and their RER cisternae were flattened. Numerous intermediate forms between these two cell types were seen. Besides the secretory granules, the cytoplasm also contained a fine deposit of reaction product. In the Golgi area, the saccules were always negative and only rare, positive, small, secretory granules could be seen.

No reaction product was found on the RER cisternae, the mitochondria, or the nucleus.

**IDENTIFICATION OF CELLS POSITIVE FOR A-OLH $\alpha$ :** After treatment with A-OLH $\alpha$  the same gonadotropic cells were stained over the

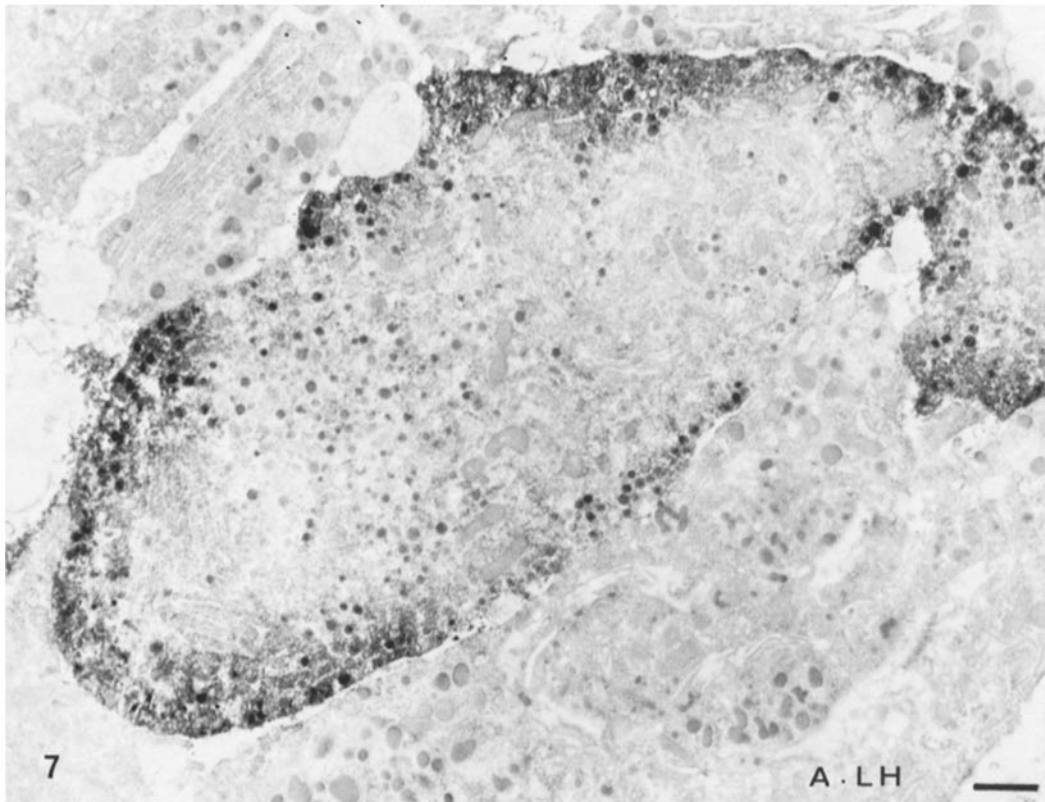

FIGURE 7 Same material as Fig. 6 but treated with A-OLH. This type B gonadotropic cell differs from the type A cells (see Fig. 6) by having one kind of secretory granules and flat RER cisternae. The immunocytochemical staining is restricted to the periphery of the cell over the granules as well as the cytoplasm ( $\times 9,000$ ).

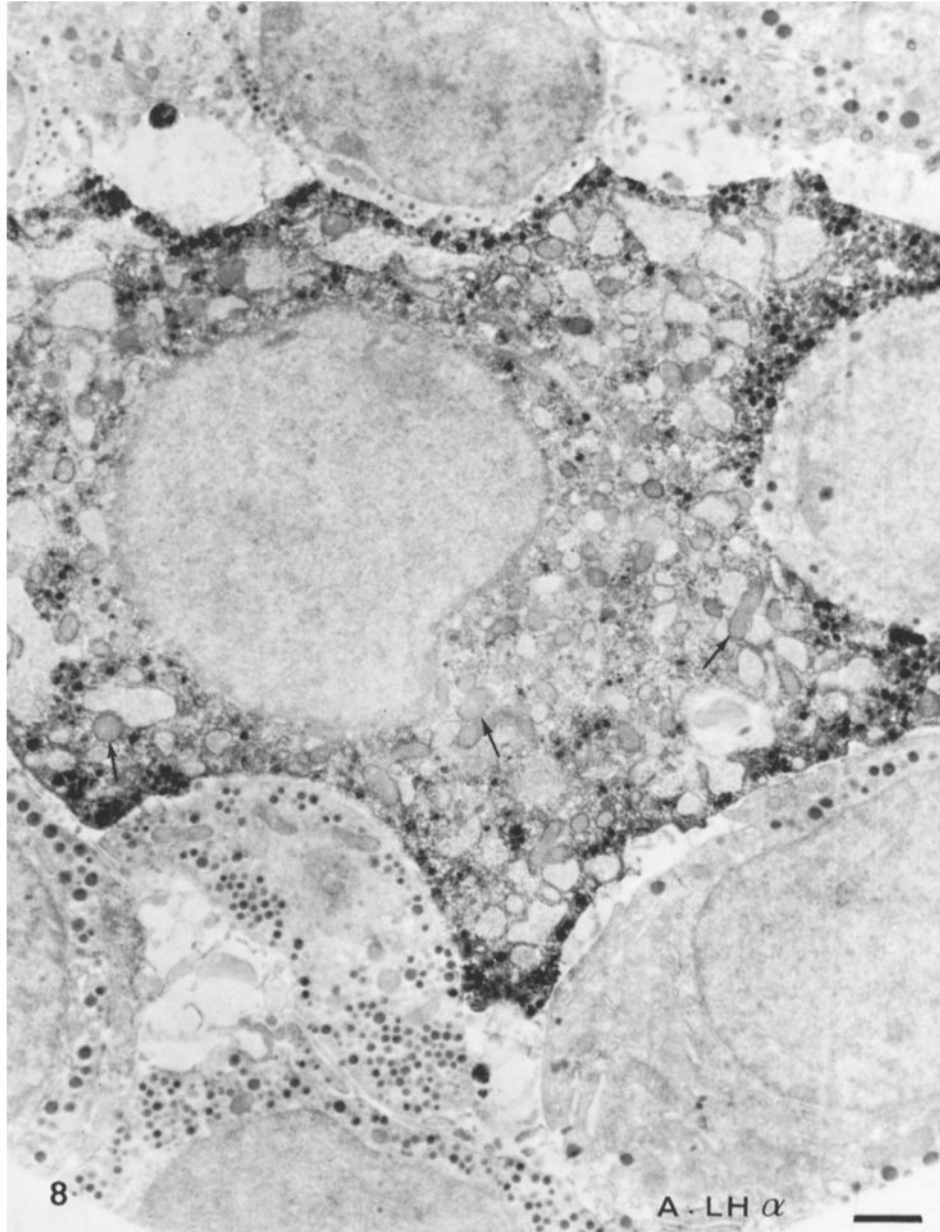


FIGURE 8 Same material as Fig. 6 but treated with A-oLH $\alpha$ . This positive cell type was never found in material treated with A-oLH and A-oLH $\beta$ . It is characterized by small secretory granules and a stellate shape. The secretory granules are strongly positive in any part of the cell. The RER cisternae content is always negative. The nucleus and the mitochondria (arrows) are negative ( $\times 9,000$ ).

same subcellular sites as after treatment with A-oLH and A-oLH $\beta$ . Another cell type was also immunohistochemically stained with the A-oLH $\alpha$  only. These cells have a polygonal or stellate shape, very small secretory granules (mean di-

ameter 100-150 nm), and dilated RER cisternae (Fig. 8). Such features are characteristic of the thyrotropic cells described by classical electron microscopy (13, 37) and by immunocytochemical reaction (31) (see Discussion).

## CASTRATED FEMALE RAT PITUITARIES

After treatment with A-oLH two types of gonadotropic cells were stained in castrated females. With this delay after castration (1 mo), the type A cells became very numerous and displayed various degrees of vacuolization and hypertrophy (Fig. 9) presenting the typical features of castration cells already described by Farquhar and Rinehart (13) and later by Yoshimura and Harumiya (41). An increased vacuolization was always accompanied by the disappearance of the large secretory granules. The small secretory granules persisted and were mainly localized at the periphery of the cell along the cell membrane (Fig. 9). Type B cells described in the normal male rat pituitary were rare and were unmodified in the castrated female. In these two cell types, immunohistochemical staining with the A-oLH was restricted to the periphery of the cell over the small secretory granules as well as the cytoplasm. Some small positive secretory granules were scattered throughout the rest of the cytoplasm. The RER cisternae were always negative in the two gonadotropic cell types.

The same cell types were also stained with A-oLH $\beta$ , but the positive reaction was observed over a greater portion of the cytoplasmic structures, except for the highly hypertrophied cells in which it remained restricted to the periphery of the cells. As with A-oLH, the small secretory granules and the cytoplasm were stained, but in highly degranulated cells the content of the dilated RER cisternae was also stained (Fig. 10). In the Golgi area, nevertheless, the saccules were again negative but the positive secretory granules seemed to be more numerous (Fig. 10). In sections treated with A-oLH $\beta$  and with A-oLH $\alpha$  another type of cell was occasionally found to be positive. It was characterized by RER cisternae resembling filigrees and might correspond to the cells seen by Farquhar and Rinehart (13) after a longer postcastration period. In these cells, the content of the RER cisternae was always negative (Fig. 11).

With A-oLH $\alpha$  the same gonadotropic cell types and the same subcellular sites were immunohistochemically stained, but the positive reaction was lower over the cytoplasm and the proportion of positive secretory granules was higher than with A-oLH and A-oLH $\beta$ . Another type of cell was stained with the A-oLH $\alpha$  alone; these cells were small and angular. Their cytoplasm was

retracted and they contained very small secretory granules which were strongly stained (Fig. 12).

## DISCUSSION

### *Significance of Immunohistochemical Staining*

In this work the immunohistochemical staining was used in an attempt to visualize interactions between antigenic determinants contained in rat pituitary tissues which have been previously treated with a fixative and AS against ovine LH and its two subunits. Does this staining allow identifying LH cells in rat pituitary sections? The immunological characterization of the AS showed that: (a) A-oLH presented a partial but definite cross-reaction with rat LH and no cross-reaction with rat FSH, (b) A-oLH $\beta$  presented a lower cross-reaction with rat LH and no cross-reaction with oFSH (and consequently no cross-reaction with rat FSH), (c) A-oLH $\alpha$  gave only a very low cross-reaction with rat LH. This agrees with recent results of Vaitukaitis et al. (40).

Study of the effects of preabsorption of AS with a different antigen (Table I) enabled analysis of the immunological significance of the staining. On pituitary section, A-oLH as well as A-oLH $\beta$  recognize LH and could recognize possible free LH $\beta$  molecules. In any case, they cannot recognize FSH and TSH, which is consistent with previous radioimmunological studies (20, 21, 40). A-oLH $\alpha$  recognizes LH, possible free LH $\alpha$  molecules, and FSH; it slightly recognized TSH, but does not recognize LH $\beta$  and ACTH.

These results support the following assumptions: (a) Only the cells which react with both A-oLH and A-oLH $\beta$  can be considered as LH secreting cells in the rat pituitary. (b) The cells which react with the A-oLH $\alpha$  but not with A-oLH and A-oLH $\beta$  cannot be considered as LH cells. On the basis of our present knowledge about the chemical similarities between the  $\alpha$ -subunits of oLH, oFSH, and oTSH, one might assume that such cells are either FSH or TSH cells. The retracted aspect of these cells in castrated rats seems to exclude the possibility that they could be FSH cells. Moreover, their histochemical and ultrastructural features are identical to those of TSH cells as previously identified by several authors (7, 13, 31, 37). Indeed, Baker et al. (4) have recently shown with the light microscope that the cells which react with an antiserum to bovine TSH $\beta$

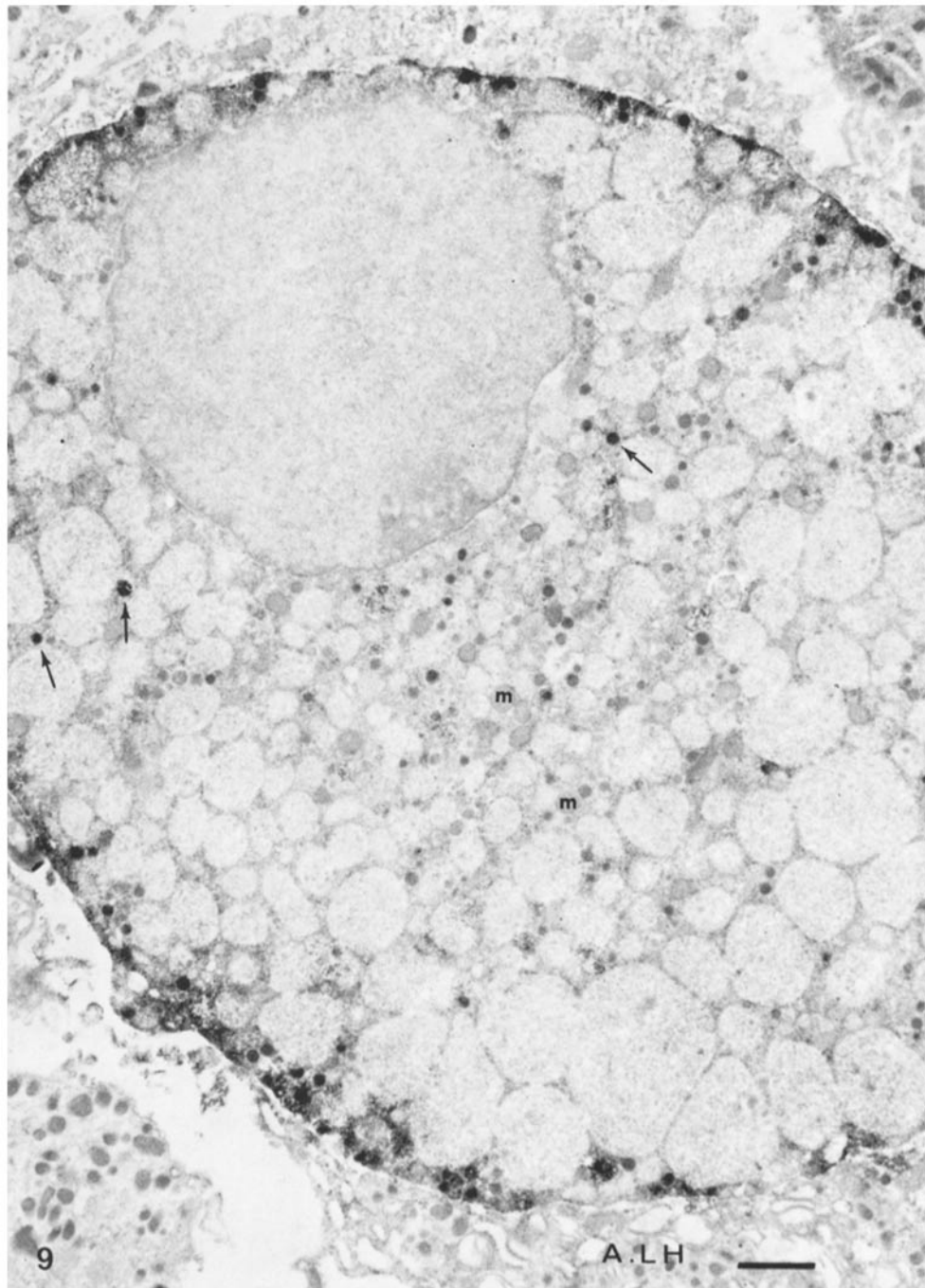


FIGURE 9 Anterior pituitary from an ovariectomized rat treated with A-oLH. This typical castration cell is immunocytochemically stained. The reaction is mainly localized at the periphery of the cell over the secretory granules and the cytoplasm. Some positive granules (arrowheads) are also scattered within the cytoplasm. The dilated RER cisternae are negative. One notices the absence of large secretory granules. The nucleus and the mitochondria (*m*) are negative ( $\times 10,500$ ).

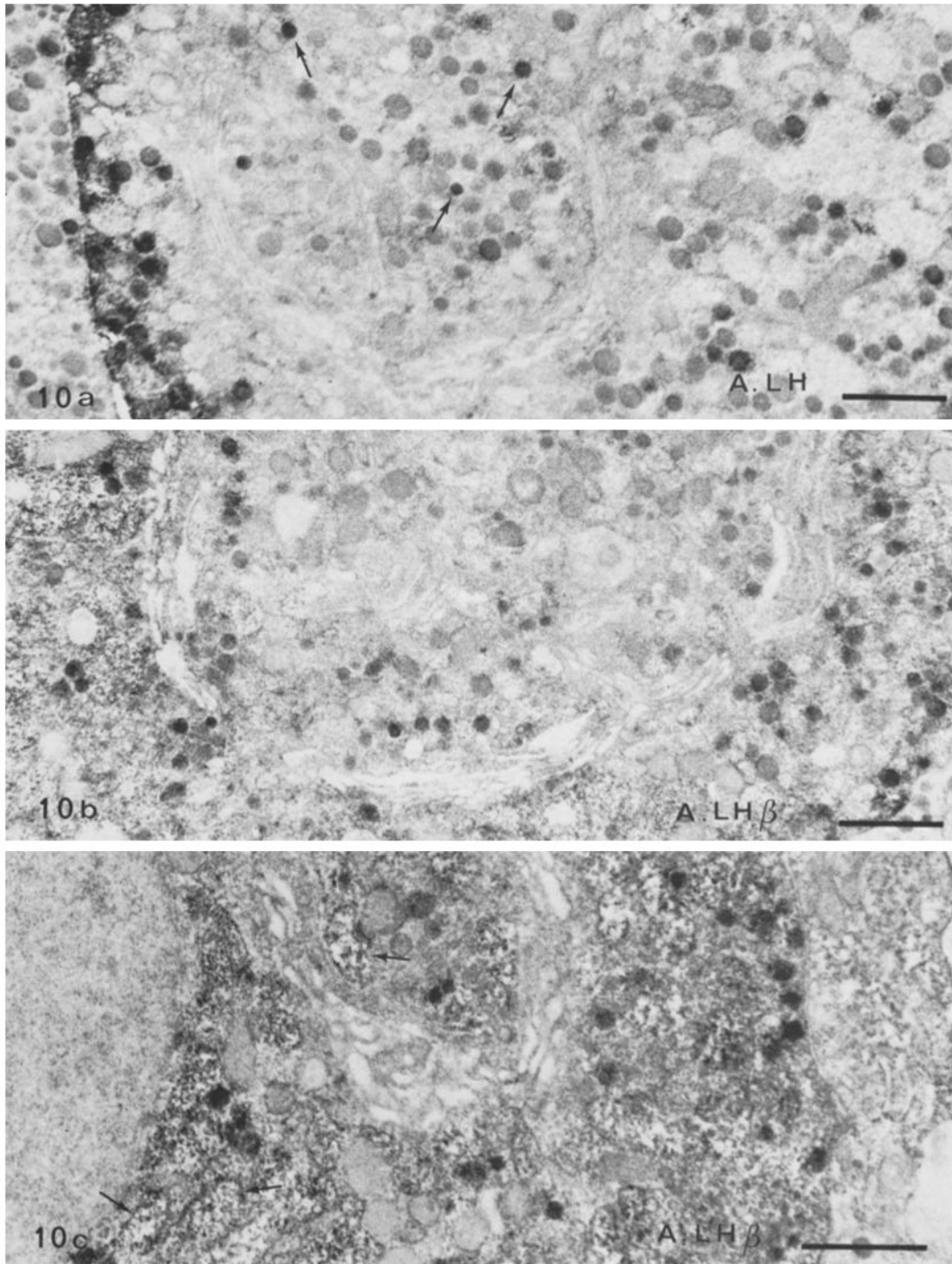


FIGURE 10 Same material as Fig. 9. Details of the Golgi zone of LH cells. (a) Section treated with A-oLH; very few positive secretory granules are seen in the core of the Golgi zone (arrows). The saccules are negative. As in Fig. 9, the positive reaction is intense at the periphery of the cells over secretory granules as well as cytoplasm ( $\times 15,000$ ) (b) Section treated with A-oLH $\beta$ . The saccules are again negative but the positive secretory granules are more numerous inside of the Golgi zone than in Fig. 10 a. Over the cytoplasm, outside the Golgi zone, the positive secretory granules are also more numerous than in Fig. 10 a ( $\times 15,000$ ). (c) Section treated with A-oLH $\beta$ . In this highly hypertrophied and degranulated cell, a positive reaction is seen over the content of the RER cisternae (arrows). The Golgi saccules are again negative ( $\times 18,000$ ).

are also stained by an antiserum to bovine LH $\alpha$ . The morphological features of the cells which react in such a manner in our material are identical to those described by Baker et al. (4) having

a "polygonal shape, large size, dominant distribution in the centromedial region of the lateral lobes." Moreover they are AB positive which is a typical histochemical property of thyrotropic

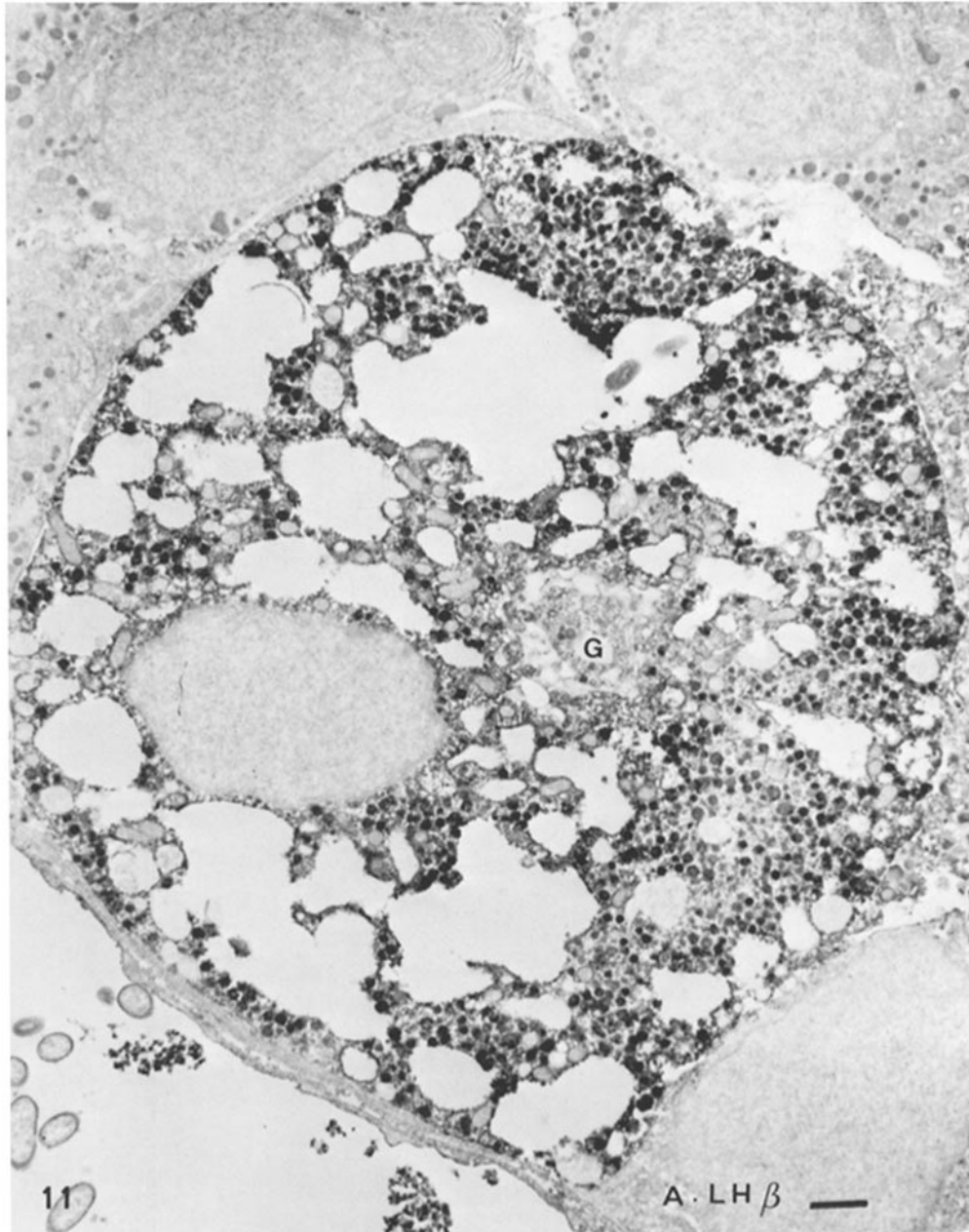


FIGURE 11 Same material as Fig. 9 but treated with A-oLH $\beta$ . This infrequent gonadotropic cell type is strongly stained. It is characterized by the filigree-like features of the RER cisternae and numerous secretory granules which have a uniform size and are strongly stained in any part of the cell. One again notices that the Golgi area is not stained (G). ( $\times 8,000$ ).

cells in several vertebrates (7, 16, 35). The stellate shape of these cells might suggest that they are adrenocorticotrophic cells. This idea can be excluded since staining with A-oLH $\alpha$  was not

affected by preabsorption with porcine ACTH. In addition morphological data also enable us to discard such a possibility: (a) With the light microscope the corticotropin cells identified by an

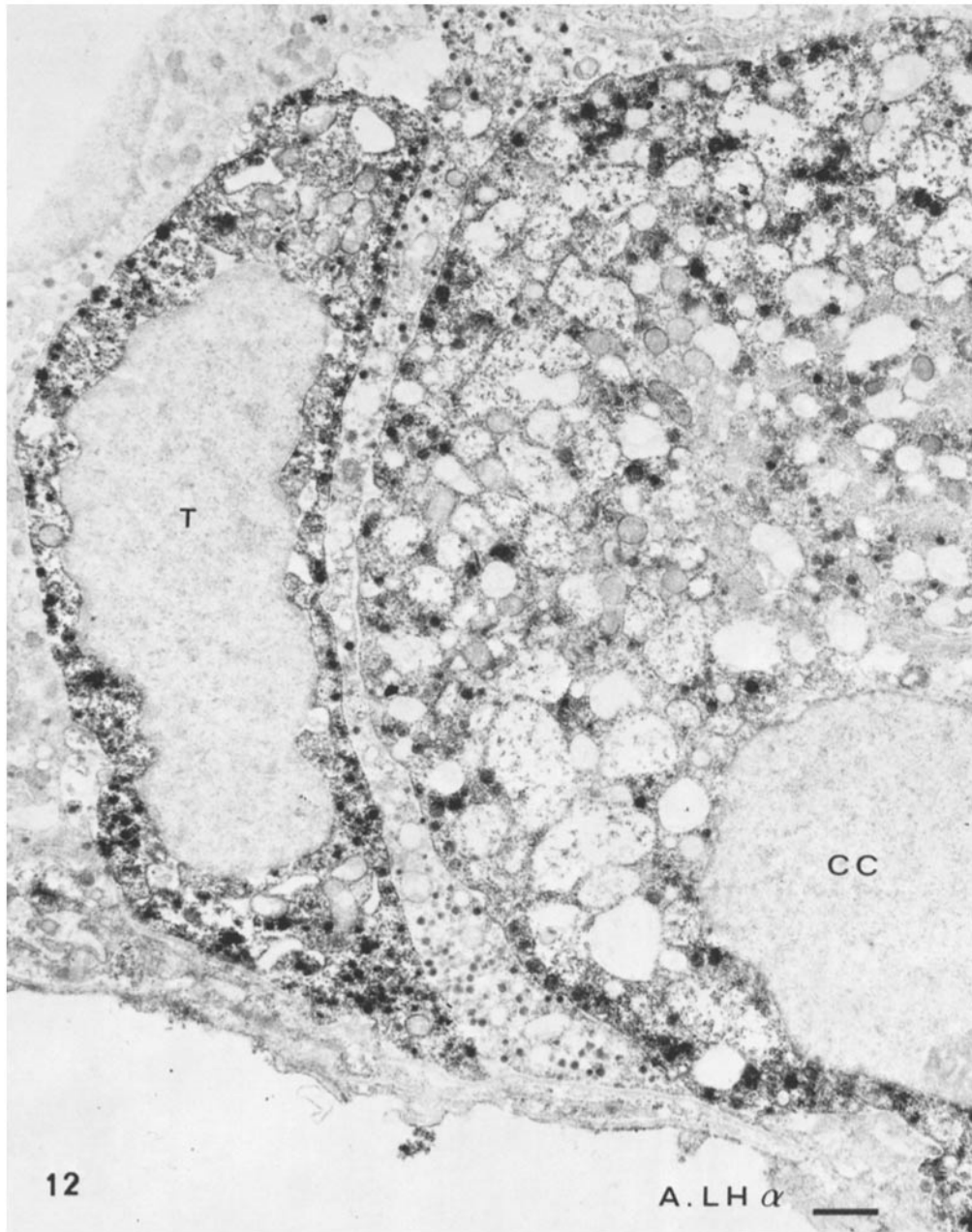


FIGURE 12 Same material as Fig. 9 but treated with A-oLH $\alpha$ . Besides the typical castration cell (CC) another cell type with very small secretory granules is also stained (T). This last cell type is presumed thyrotropic. In the two cells the secretory granules are strongly positive in any part of the cell. One notices that the positive reaction over the cytoplasm is less intense than in material treated with A-oLH $\beta$  (see Fig. 10 b-c). ( $\times 9,000$ ).

antibody to porcine corticotropin were not stained with AB (2). In contrast with TSH cells the immunoreactive corticotropin cells were distributed throughout the pars distalis and for a few cells within the pars intermedia (2). With our A-oLH $\alpha$  no positive cells were found within the pars intermedia. (b) With the electron microscope the ultrastructural features of the cells which were stained with A-oLH $\alpha$  (Fig. 8) were very similar to those of the thyrotropic cells described by several authors whose methods were either conventional electron microscopy (13, 37) or electron immunocytochemistry (31). The features were moreover clearly different from those of the ACTH cells described by conventional microscopy (37) and by electron microscopic immunocytochemistry (29). In the TSH cells the granules are usually smaller (100–150 nm instead of 200–300 nm) and the RER cisternae often vesiculated.

#### *Identification of LH Cells in the Normal Male Rat*

**LIGHT MICROSCOPE STUDY (TABLE IV):** LH cells may be considered as one cell type since these cells reacted with the three AS and gave the same violet color after the AB-PAS method. They nevertheless differed in shape and localization which suggest that they might correspond to two cell types: vacuolized cells mainly localized in the antero- and posterolateral parts of the pars distalis and small oval cells scattered throughout the pars distalis. The same variations in distribution and size of the LH cells were found by Baker et al. (4) using A-bLH and A-bLH $\beta$ ; nevertheless these authors concluded that there was a single LH cell type.

Do these cells secrete only LH? In order to answer this question we have recently begun a similar study with an A-oFSH. Preliminary examination shows that the two cell types are also immunohistochemically stained with this AS. These observations would agree with the previously mentioned results of Nakane (31).

**ELECTRON MICROSCOPE STUDY:** With the electron microscope two cell types positive for A-oLH, A-oLH $\beta$ , and A-oLH $\alpha$  were also identified. Type A cells were characterized by two classes of spherical secretory granules (200 nm and 300–700 nm diameter) and rounded RER cisternae and may also correspond to hypertrophied cells identified with the light microscope. They are the same as those already described on

the basis of histophysiological correlations as gonadotropic cells (41, 12) or as FSH cells (17, 22).

Type B cells were smaller, contained one kind of small spherical secretory granules (200 nm diameter) and flattened RER cisternae, and may also correspond to the small oval cells described with the light microscope. They have already been described as gonadotropic cells by Yoshimura and Harumiya (41) who found, as we did, numerous intermediate forms between type A and type B cells and suggested that they might represent different stages of the secretory cycle of one single cell type.

Using immunocytochemical methods, Nakane (31) described one cell type containing both LH and FSH and another containing FSH only. The former is oval and vacuolized, and the latter more angular in shape. They both contain one kind of round secretory granules (200–250 nm diameter). These two cell types described by Nakane are difficult to correlate with our type A and type B LH cells. More recently, Mazurkiewicz and Nakane (26) using an improved method found LH within “small dense secretion granules about 75  $\mu$  in diameter as well as in large dilated vacuoles of up to 235  $\mu$  in diameter.”

#### *Gonadotropic Cell Response after Castration*

**LIGHT MICROSCOPE STUDY:** In castrated males and females an apparently homogenous population of vacuolized cells was positive for the three AS. These cells have the classical features of castration cells and are violet after AB-PAS. The antigenicity of these cells was higher than in the normal male, although the central vacuole was negative and the Golgi zone was weakly stained. A similar intense staining of the castration cells was previously observed by Baker and Yu, who used also an A-oLH (5). Nevertheless, Baker et al. reported later on a decline in stainability of castration cells with A-oLH (4). It should be precised that an increase in stainability of castration cells is in agreement with the well established rise of the pituitary LH content after gonadectomy. We have previously shown that in castrated females the same cell type was also stained with an A-oFSH (38). The coexistence of LH and FSH within the castration cells has also been found by several authors using AS of several origins (27, 28, 23–25).

An original finding of our light microscope



study was the increased affinity of castration cells for A-oLH $\beta$  which appeared on sections successively treated with A-oLH $\alpha$  and A-oLH $\beta$ , whatever the order used. An increased secretory activity of the LH cells seems therefore to be related to an increase affinity of the cells for the A-oLH $\beta$ . This could be related with an increasing of the LH as well as LH $\beta$  contents of the cells. A conflicting result has been reported by Baker et al. (4) who found that 54 days after ovariectomy the staining capacity of LH cells declines with A-bLH $\beta$  but remains intense for A-bLH $\alpha$ . Such differences with our results may involve differences in the immunological properties of AS as well as differences in the fixatives. The Bouin's fluid used by Baker et al. contains acetic acid which is suppressed in the Herlant's procedure that we followed.

Regression of the thyrotropic cells as identified by AB-PAS staining was a striking phenomenon brought by castration in male and female pituitaries. This observation agrees with D'Angelo's previous finding (9) concerning the decrease in concentration and total amount of the pituitary TSH after gonadectomy. Baker et al. (4) did not observe after ovariectomy any modification of the size and number of TSH cells as revealed by immunochemical staining with an A-bTSH $\beta$ . Differences between Baker's findings and ours might be related to differences in the animals. In our material, the regressed cells displayed an affinity for both A-oLH $\alpha$  and A-oLH $\beta$ . Only a part of them represents AB positive cells. For the time being, we have no explanation for their affinity for A-oLH $\beta$ .

**ELECTRON MICROSCOPE STUDY:** As opposed to the light microscope observations, with the electron microscope at least two cell types were observed to be immunohistochemically stained in the castrated female pituitary. The type A cells were nevertheless far more numerous. They were modified, hypertrophied, and vacuolized in accordance with the first morphological descriptions of Farquhar and Rinehart (13). These authors suggested that these cells might represent the FSH cells. We found in fact that they displayed a selective affinity for A-oLH and its two subunits. This does not exclude an affinity of these cells for an A-FSH.

The other cell types that stained with the three AS were very rare. They seem to correspond to the cells described by Farquhar and Rinehart

(13) which become more numerous and hypertrophied with the time after castration.

Regression of the thyrotropic cells after castration is clearly confirmed by the electron microscope study in which we identified these cells by their affinity for A-oLH $\alpha$  and by the small diameter of their secretory granules. The same phenomena had been previously described with the electron microscope by Yoshimura and Harumiya (41).

### *Subcellular Localization of Immunohistochemical Staining*

The subcellular sites of staining were the same for the three AS. There were, in a decreasing range of staining intensity, the secretory granules, the cytoplasm, and the RER cisternae. Important differences in staining intensity were seen among the three AS. These differences may be related to differences in the binding affinity of each one of the AS for the rat LH and its two subunits (20). For example, A-oLH $\beta$  has a higher binding affinity than the other two AS. Nevertheless, these differences might also reflect interesting variations between the antigenic determinants within the cells.

**SECRETORY GRANULES:** The small secretory granules (200 nm) were always the main sites of antigenicity for the three AS. The large secretory granules of the type A LH cell showed a lower and variable affinity. In a parallel study of acid-phosphatase localization we found that these large secretory granules are devoid of this enzymatic activity and therefore are not lysosomes. Within the Golgi zone, after a glutaraldehyde fixation, these large secretory granules appear as large vacuoles of a low electron density which are sometimes related to the inner saccules. Such pictures suggest that they represent condensing vacuoles and a presecretory form of the small granules which could explain their low antigenicity. In favor of such an interpretation is the fact that these large secretory granules disappeared in type A cells 1 mo after castration.

Within the Golgi area the positive secretory granules were rare and with the light microscope the Golgi area showed a low antigenicity. This contrasts with recent findings on the ACTH cells of rat pituitary in which elements of the Golgi complex stained strongly (29). Although we used another immunohistochemical method, such a difference might reflect differences between the biosynthesis of a glycoprotein hormone (LH) and

of a polypeptide hormone (ACTH). The fact that in the LH cells the proportion of LH-positive secretory granules was always higher outside the Golgi zone suggests that the antigenicity of the secretory granules appears slowly and that the biosynthesis and association of LH subunits might occur within the secretory granules after they have migrated out of the Golgi zone. An improvement of the tissue preservation would be necessary to ascertain this interpretation. Another constant feature of the Golgi zone is the non-antigenicity of the Golgi saccules. Unfortunately, the quality of the morphological preservation is not good enough to identify other inner structures of the Golgi zone such as Novikoff's "Golgi endoplasmic reticulum lysosome" system.

**DIFFUSE STAINING OF CYTOPLASM:** A diffuse staining of the cytoplasm was frequently observed with A-oLH and A-oLH $\beta$ , but was less evident after A-oLH $\alpha$ . This could be due to an artifact resulting from a diffusion of the secretory granules during the lengthy treatment of the tissue slices. Nevertheless, several facts are in favor of a specific phenomenon: (a) The cytoplasmic staining is not higher around the secretory granules. (b) It is maximum in degranulated cells. (c) It is more frequent with A-oLH $\beta$  than with A-oLH $\alpha$ . A similar cytoplasmic staining was reported for calcitonine cells (10) and particularly for pituitary ACTH cells by Moriarty and Halmi (29) who used another immunohistochemical method. As the latter authors have suggested for ACTH, this may represent LH molecules in the process of being secreted. The evidence of exocytosis is very rare in the castration cells as already noted by Rennels et al. (36) and the possibility of another pathway of LH secretion ought to be considered.

**RER CISTERNAE:** The RER cisternae were generally negative. This is in agreement with the present concepts of the mechanism of glycoprotein biosynthesis which admit that the molecules synthesized on the ribosomes migrate into the endoplasmic reticulum, where they are concentrated and completed by the addition of carbohydrate components (see review by Clauser et al. [8]). The RER cisternae were nevertheless strongly positive in the case of highly vacuolized castration cells in sections treated with A-oLH $\beta$ . This might suggest that under such experimental conditions the antigenicity of the LH molecule appears early during its intracellular migration.

In this study, the use of AS against ovine LH and its two subunits improved the specificity of immunohistochemical identification of LH-secreting cells in the rat pituitary. It also provides new findings concerning correlation between an increased secretory activity of the LH cells and an increased affinity of the same cells for the A-oLH $\beta$ . Also, at the electron microscope level, a modification of the peroxidase-labeled antibody technique improved localization of the subcellular sites of antigenicity within LH cells. In this respect new results have been obtained. The secretory granules are not the only sites of binding, although they display the maximum affinity. The presence of LH molecules in the cytoplasm and in the RER cisternae in the case of increased secretory activity must be considered.

We express our thanks to Mrs. Renée Picart, Françoise Franquelin, and Mr. Claude Pennarun for their valuable technical assistance. It is a pleasure to acknowledge the advice and help of Dr. Susan Fiske of the Laboratoire de Médecine Experimentale, Collège de France, in the preparation of the English text.

This work was supported in part by a grant from the D. G. R. S. T. (France), contracts no. 7270100 and 7072448 and in part by a grant from the C. N. R. S. (France, E.R. no. 89).

Received for publication 27 December 1972, and in revised form 26 April 1973.

## REFERENCES

1. AVRAMEAS, S. 1969. *Immunochemistry*. 6:43.
2. BAKER, B. L., and S. T. DRUMMOND. 1972. *Am. J. Anat.* 134:395.
3. BAKER, B. L., S. PEK, A. R. MIDGLEY, JR., and B. E. GERSTEN, 1970. *Anat. Rec.* 166:557.
4. BAKER, B. L., J. G. PIERCE, and J. S. CORNELL. 1972. *Am. J. Anat.* 135:251.
5. BAKER, B. L., and Y. Y. YU. 1971. *Endocrinology*. 89:996.
6. BARNES, B. 1963. In *Cytologie de l'Adénohypophyse*. J. Benoit and C. Da Lage, editors. Editions du Centre National De La Recherche Scientifique. Paris. 91.
7. BENOIT, J., and C. DA LAGE, Editors. 1963. *Cytologie de l'adénohypophyse*, Editions du Centre National De La Recherche Scientifique. Paris.
8. CLAUSER, H., G. HERMAN, B. ROSSIGNOL, and S. HARBON. 1972. In *Glycoproteins, their Composition, Structure and Function*. Part. B. A.

- Gottschalk, editor. Elsevier Publishing Co. Ltd., Essex, England. 2nd ed. 1151.
9. D'ANGELO, S. A. 1966. *Endocrinology*. 78:1,230.
  10. DE GRANDI, P. B., J. P. KRAEHENBUHL, and M. A. CAMPICHE. 1971. *J. Cell Biol.* 50:446.
  11. DE LA LLOSA, P., C. COURTE, and M. JUTISZ. 1967. *Biochem. Biophys. Res. Commun.* 26:411.
  12. FARQUHAR, M. G. 1971. In *Subcellular Organization and Function in Endocrine Tissues*. H. Heller and K. Lederis, editors. Cambridge University Press, London. 79.
  13. FARQUHAR, M. G., and J. F. RINEHART. 1954. *Endocrinology*, 54:516.
  14. GRAHAM, R. C., and M. J. KARNOVSKY. 1966. *J. Histochem. Cytochem.* 14:291.
  15. HERLANT, M. 1960. *Bull. Microsc. Appl.* 10:37.
  16. HERLANT, M. 1964. *Int. Rev. Cytol.* 17:299.
  17. HERLANT, M. 1972. In *Hormones Glycoprotéiques Hypophysaires*. M. Jutisz, editor. Editions INSERM, Paris, 5.
  18. JUTISZ, M., and C. COURTE 1968. *Gen. Comp. Endocrinol.* 11:562.
  19. JUTISZ, M., and P. DE LA LLOSA. 1972. In *Glycoproteins, their Composition, Structure and Function*. Part B. A. Gottschalk, editor. Elsevier Publishing Co. Ltd., Essex, England. 2nd Edition. 1,019.
  20. KERDELHUE, B., S. PITOULIS, and M. JUTISZ. 1971. *C.R. Hebd. Seances Acad. Sci. Ser. D Sci. Nat. (Paris)* 273:511.
  21. KERDELHUE, B., S. PITOULIS, and M. JUTISZ. 1972. In *Structure, Activity Relationships of Protein and Polypeptide Hormones*. Part II. M. Margoulies and F. C. Greenwood, editors. Excerpta Medica Foundation, Publishers, Amsterdam. 396.
  22. KUROSUMI, K., and Y. OOTA. 1968. *Z. Zellforsch. Mikrosk. Anat.* 85:34.
  23. LELEUX, P., and C. ROBYN. 1970. *Ann. Endocrinol.* 31:181.
  24. LELEUX, P., and C. ROBYN. 1971. *Karolinska Symp. Res. Methods Reprod. Endocrinol.* 3:168.
  25. LELEUX, P., C. ROBYN, and M. HERLANT. 1968. *C.R. Hebd. Seances Acad. Sci. Ser. D Sci. Nat. (Paris)*. 267:438.
  26. MAZURKIEWICZ, J. E., and P. K. NAKANE. 1972. *J. Histochem. Cytochem.* 20:969.
  27. MONROE, S. E., and A. R. MIDGLEY. 1966. *Fed. Proc.* 25:315.
  28. MONROE, S. E., and A. R. MIDGLEY. 1969. *Proc. Soc. Exp. Biol. Med.* 130:151.
  29. MORIARTY, G. C., and N. S. HALMI. 1972. *J. Histochem. Cytochem.* 20:590.
  30. NAKANE, P. K. 1968. *J. Histochem. Cytochem.* 16:557.
  31. NAKANE, P. K. 1970. *J. Histochem. Cytochem.* 18:9.
  32. PAKKOFF, H., and M. EKBLAD. 1970. *Biochem. Biophys. Res. Commun.* 40:614.
  33. PAKKOFF, H., and T. S. A. SAMY. 1967. *Biochim. Biophys. Acta* 147:175.
  34. PIERCE, J. G., T. H. LIAO, R. B. CARLSEN, and T. REIMO. 1971. *J. Biol. Chem.* 246:866.
  35. PURVES, H. D. 1966. In *The Pituitary Gland*. G. W. Harris and B. T. Donovan, editors. Butterworth and Company (Publishers) Ltd., London. 147.
  36. RENNELS, E. G., E. M. BOGDANOVA, A. ARIMURA, M. SAITO, and A. V. SCHALLY. 1971. *Endocrinology*. 88:1318.
  37. SIPERSTEIN, E. R., and K. J. MILLER. 1970. *Endocrinology*. 86:451.
  38. TOUGARD, C., B. KERDELHUE, A. TIXIER-VIDAL, and M. JUTISZ. 1971. *C.R. Hebd. Seances Acad. Sci. Ser. D Sci. Nat. (Paris)*. 273:897.
  39. TOUGARD, C., A. TIXIER-VIDAL, B. KERDELHUE, and M. JUTISZ. 1972. *Proc. Int. Cong. Endocrinol.* (Abstr. 619).
  40. VAITUKAITIS, J. L., G. T. ROSS, L. E. REICHERT, and D. N. WARD. 1972. *Endocrinology*. 91:1,337.
  41. YOSHIMURA, F., and K. HARUMIYA. 1965. *Endocrinol. Jap.* 12:119.
  42. ZAMBONI, L., and C. DE MARTINO. 1967. *J. Cell Biol.* 35:148A.