

Available online at www.sciencedirect.com

ScienceDirect

journal homepage: <http://Elsevier.com/locate/radcr>

Interventional Radiology

Embolization of congenital intercostobronchial trunk-pulmonary artery fistula using Amplatzer vascular plugs

Souheil Saddekni M.D. FSIR, FAHA^a, Amr Ahmed Abouateya M.D.^a,
Rafik Mohamed Ibrahim M.D.^a, Maysoon Farouk Hamed M.D.^b,
Sherif Magdy Moawad M.D., M.Sc.^a, Ahmed Anwar Abouarab M.D.^a,
Ahmed Kamel Abdel Aal M.D., PhD., FSIR^{a,*}

^a Department of Radiology, University of Alabama at Birmingham, 619 19th Street South, Birmingham, AL 35249

^b Department of Family Medicine, University of Alabama at Birmingham, 619 19th Street South, Birmingham, AL 35249

ARTICLE INFO

Article history:

Received 14 May 2017

Accepted 26 June 2017

Available online

Keywords:

Embolization

Intercostobronchial

Pulmonary artery

Fistula

Amplatzer

ABSTRACT

We present the case of a 54-year-old male patient diagnosed with a right upper lobe lung cancer and was referred for resection. Positron emission tomography-computed tomography scan showed a prominent vascular structure in the right lung, suspicious for vascular malformation. A computed tomography angiography was done, demonstrating an intercostobronchial trunk-pulmonary artery fistula. There was also non-tapering dilated wandering pulmonary artery coursing through the right lower lung without any abnormal connection with pulmonary veins and were supplying normal lung parenchyma. Amplatzer vascular plugs were used for the treatment of the intercostobronchial trunk-pulmonary artery fistula. Our case highlights these very rare vascular anomalies, and their management.

© 2017 the Authors. Published by Elsevier Inc. under copyright license from the University of Washington. This is an open access article under the CC BY-NC-ND license (<http://creativecommons.org/licenses/by-nc-nd/4.0/>).

Introduction

Congenital anomalies of the pulmonary arteries are usually found incidentally on the imaging studies such as radio-

graphs and computed tomography (CT) scan [1]. The congenital anomalous systemic arterial supply to the lung usually occurs in association with congenital heart or lung disease, with systemic artery arising from descending the aorta [2]. The common congenital anomalies of peripheral pulmonary arteries include

Disclosures: Souheil Saddekni: Consultants, Abbott vascular. Amr Ahmed Abouateya: No disclosures. Rafik Mohamed Ibrahim: No disclosures. Maysoon Farouk Hamed: No disclosures. Sherif Magdy Moawad: No disclosures. Ahmed Anwar Abouarab: No disclosures. Ahmed Kamel Abdel Aal: Consultants, Abbott vascular, Bard Peripheral Vascular, Baxter Healthcare, W. L. Gore, Boston Scientific, Surefire Medical. Ethical Approval: For this type of study formal consent is not required.

Informed Consent: Informed consent was obtained from all individual participants included in the study.

* Corresponding author.

E-mail address: akamel@uabmc.edu (A.K. Abdel Aal).

<https://doi.org/10.1016/j.radcr.2017.06.014>

1930-0433/© 2017 the Authors. Published by Elsevier Inc. under copyright license from the University of Washington. This is an open access article under the CC BY-NC-ND license (<http://creativecommons.org/licenses/by-nc-nd/4.0/>).

sequestration, hypoplasia, stenosis, aneurysms, or pulmonary arteriovenous malformation. Meandering pulmonary veins is also a well-described entity [3,4]. We present a rare case of intercostobronchial trunk-pulmonary artery (ICBT-PA) fistula with congenital right upper PA atresia. This was associated with non-tapering dilated wandering pulmonary arteries that course circuitously throughout the right lower lung to supply normal lung parenchyma. The ICBT-PA fistula was successfully treated with multiple variable-sized Amplatzer vascular plugs (AVPs). This case highlights these sporadic vascular anomalies and their management using minimally invasive endovascular technique. To our knowledge, these findings were not reported previously.

Case report

Brief reports are exempt from institution review board approval in our institution.

We present a case of a 54-year-old Caucasian male patient who presented to his primary care physician with chronic obstructive pulmonary disease and obstructive sleep apnea. Subsequently, a chest X-ray was obtained and revealed a right upper lobe lung mass. Biopsy of this mass was performed, and revealed primary adenocarcinoma. The patient was referred to our institution for surgical resection of his lung mass. During workup, a PET-CT scan was performed and revealed some prominent vascular structures in the right lung, which were suspicious for vascular malformations.

A CT angiography was performed and showed a 2.6-cm mass in the right upper lobe that abuts the lateral pleural surface and was consistent with the patient's diagnosis of lung cancer. However, there was a dilated tortuous vessel connecting the proximal portion of the descending aorta and the upper branch of the right pulmonary artery (Fig. 1). There was also multiple non-tapering dilated wandering pulmonary arteries that course circuitously throughout the right lower lung (Fig. 2). The patient was asymptomatic, with history of vascular anomaly diagnosed 20 years ago.

The patient was referred to our service to further outline and diagnose these anomalies. An aortogram was performed through a right common femoral artery approach, and revealed a dilated tortuous ICBT that communicates with the upper branch of the right PA (Fig. 3A). On delayed images, there were 2 non-tapering dilated wandering pulmonary arteries that course circuitously throughout the right lower lung (Fig. 3B). On more delayed images, normal venous drainage of the whole right lung was noted, particularly the upper lobe (Fig. 3C). Therefore, we decided to perform a pulmonary arteriogram to further outline the course and supply of the wandering pulmonary arteries in the right lower lung. The right PA was selectively catheterized using a 7-French pulmonary pigtail catheter (Cook Medical, Bloomington, IN) through right common femoral vein approach. Right pulmonary angiogram showed 2 non-tapering dilated wandering pulmonary arteries passing circuitously through the right lower lung. Particularly, aberrant connection with the pulmonary veins was not observed in this case, and eventually, they ended supplying the lung parenchyma. The

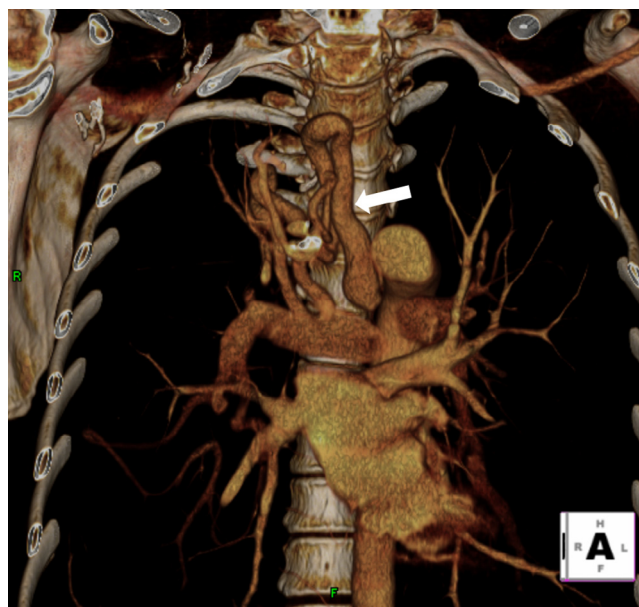


Fig. 1 – Fifty-four-year-old Caucasian male patient with adenocarcinoma of the upper lobe of the right lung. Three-dimensional volume-rendered (3-D VR) image showing dilated tortuous vessel (arrow) connecting the proximal portion of the descending aorta and the upper branch of the right pulmonary artery.

pulmonary veins drained normally into the left atrium, and there was no evidence of pulmonary arteriovenous malformation (Fig. 4). Catheterization of these 2 arteries was performed using 5-French Berenstein catheter (Slip Cath Beacon Tip; Cook Medical), and angiograms were obtained to further delineate the outline of these wandering pulmonary arteries. The 2 wandering pulmonary arteries had multiple normal pulmonary branches to the lung parenchyma, which showed normal peripheral tapering with normal parenchymal and venous phases (Fig. 5).

After discussion with the cardiovascular surgery team, a decision was made to treat the ICBT-PA fistula to avoid any risk of bleeding complication from the dilated tortuous ICBT during resection of the lung mass. Catheterization of the ICBT was then performed using a 5-French Cobra catheter (Slip Cath Beacon Tip; Cook Medical) followed by angiogram, which further revealed that the ICBT divides into 2 tortuous branches that eventually unite together before communicating with the upper branch of the right PA. Interestingly, the upper branch of the right PA appeared atretic (Fig. 6). This was suggestive of congenital atresia of the right upper PA with consecutive development of systemic collaterals from a markedly dilated and tortuous right ICBT.

The catheter was then exchanged with a 6-French sheath (Ansel; Cook Medical), which was advanced into the inferior branch of the ICBT, followed by deployment of four 12-mm, and one 16-mm AVPs (St. Jude Medical, Plymouth, MA) proximal to the fistulous communication in the inferior branch, as well as the main ICBT. Angiogram was performed through the sheath following each device deployment to confirm proper positioning before release. Final angiogram was then performed

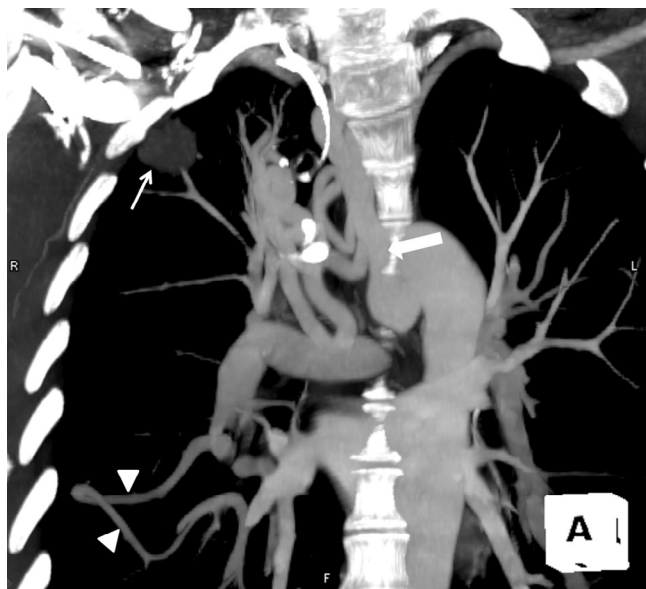


Fig. 2 – Maximum intensity projection (MIP) image showing a 2.6-cm nodule in the right upper lobe (small arrow) that abuts the lateral pleural surface and is consistent with the patient’s diagnosis of lung adenocarcinoma. Dilated tortuous vessel (large arrow) connecting the proximal portion of the descending aorta, and the upper branch of the right pulmonary artery is also seen. There is a non-tapering dilated wandering pulmonary artery (arrowheads) that courses circuitously throughout the right lower lung.

with the sheath placed at the proximal ICBT, and showed complete occlusion of the fistulous communication (Fig. 7). Because the tumor was staged T1N0M0, upper lobectomy was performed via a standard right posterolateral thoracotomy. The hospital course was uneventful, and the patient was discharged 4 days after his surgery.

Discussion

Aortopulmonary artery fistula is an uncommon condition that should be treated to prevent serious complications [5]. Aortopulmonary fistula may develop owing to several etiologies that may be either congenital or acquired. Acquired aortopulmonary fistula usually occurs because of erosion and perforation of the aortic aneurysm into the pulmonary artery. Aortic true or pseudoaneurysm may occur because of infection, trauma, or as a complication of aortic surgical procedures [5–7]. Other rare causes include chest tube insertion, spinal fixation device, or other foreign body [5]. In this case, we observed an unusual indirect aortopulmonary-fistula between enlarged ICBT and the upper branch of the right PA, rather than a direct aortopulmonary fistula. The overall appearance was suggestive of congenital atresia of the right upper PA, which led to the development of systemic collateral through a markedly dilated and tortuous right ICBT to compensate for the deficient pulmonary arterial supply to the right upper lobe. To our knowledge, this type of anomaly has not been described in literature so far.

Hypertrophy and enlargement of normal regional systemic arteries (ie, bronchial, intercostal, inferior phrenic arteries, or branches of the abdominal aorta) has been previously documented in literature and may be seen in patients with chronic pulmonary inflammatory diseases such as bronchiectasis [8]. Pulmonary sequestration is one of the most common congenital pulmonary malformations in which the involved lung parenchyma can also be supplied by an aberrant systemic artery [9]. Rarely, an anomalous systemic artery may supply an area of otherwise normal lung in the absence of congenital or acquired heart or lung disease. This latter condition has been traditionally considered within the broad framework of pulmonary sequestration as a mild form of intralobar pulmonary sequestration [8]. Even though systemic arterial supply to congenital or acquired pathology in the lung has been documented, there have been no reports published in the literature describing this pattern of fistulous

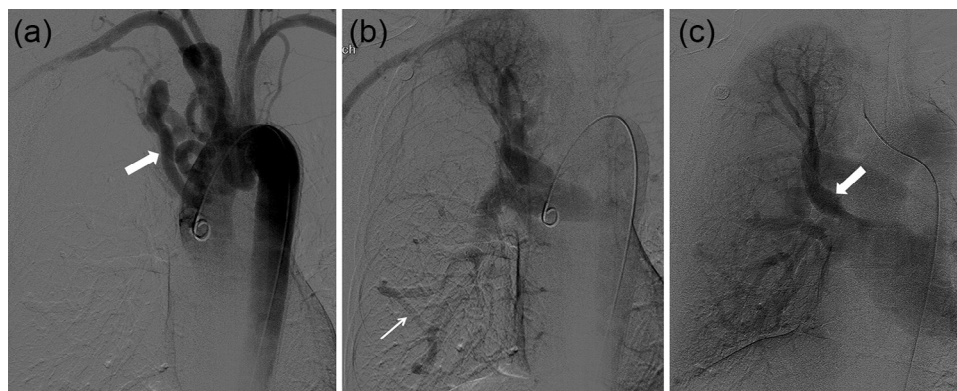


Fig. 3 – (A) Arch aortogram showing dilated tortuous intercostobronchial trunk (large arrow). (B) Delayed image from the same aortogram shows filling of the pulmonary artery owing to fistulous communication with between the dilated tortuous intercostobronchial trunk and the upper branch of the right pulmonary artery. There was a non-tapering dilated wandering pulmonary artery (small arrow) that courses circuitously throughout the right lower lung. (C) On more delayed images, normal venous drainage of the whole right lung was noted, particularly the upper lobe (small arrow).

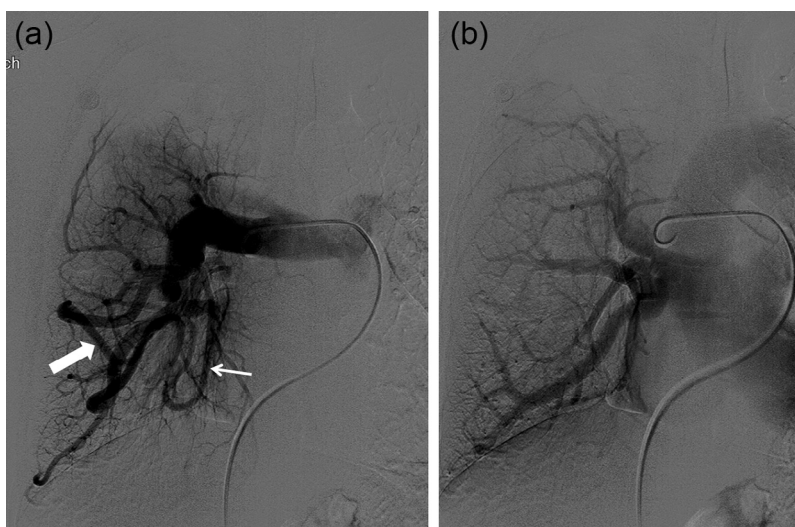


Fig. 4 – (A) Right pulmonary arteriogram showing 2 non-tapering dilated wandering pulmonary arteries (small and large arrows) coursing circuitously through the right lower lung without any abnormal connection with pulmonary veins and supplying normal lung parenchyma. (B) The pulmonary veins drained normally into the left atrium, and there was no evidence of pulmonary arteriovenous malformation.

communication between systemic arteries and pulmonary arteries, as seen in our case.

Systemic arterial supply to the lung is embryologically derived from a persistent primitive aortic branch that originally supplies the developing lung bud [2]. The vascular plexus of the primary lung buds is derived from the segmental arteries that arise from the dorsal aorta. Normally, these aortic connections disappear as the main PA develops. If this transition fails, as in the case of PA atresia, persistent systemic arterial communication continues to be the major blood supply to an otherwise normal lung [10].

The most frequent symptoms of aortopulmonary fistula are hemoptysis and chest pain. However, it may also include shortness of breath, fever, and other respiratory symptoms [5,11]. Such fistulas should also be suspected in a patient who is

known to have aortic aneurysm and showing signs of congestive heart failure [12].

The first successful case of surgical repair of aortopulmonary fistula was reported by Giocobine and Cooley in 1960 [13]. Surgical approach is associated with a high morbidity and mortality rates, and the outcome often depends on the patient's prior general condition [12]. Endovascular transcatheter embolization of systemic pulmonary fistula is a minimally invasive procedure that entails a high success rate, shorter hospital stay, combined with lower morbidity, and mortality compared with surgery, which is more invasive and confers the risk of intraoperative anesthesia. Endovascular repair of an aortopulmonary fistula has been reported in a patient where 2 detachable stainless steel coils coated were deployed partially in the aorta, across the fistula, and partially in the pulmonary artery [14].

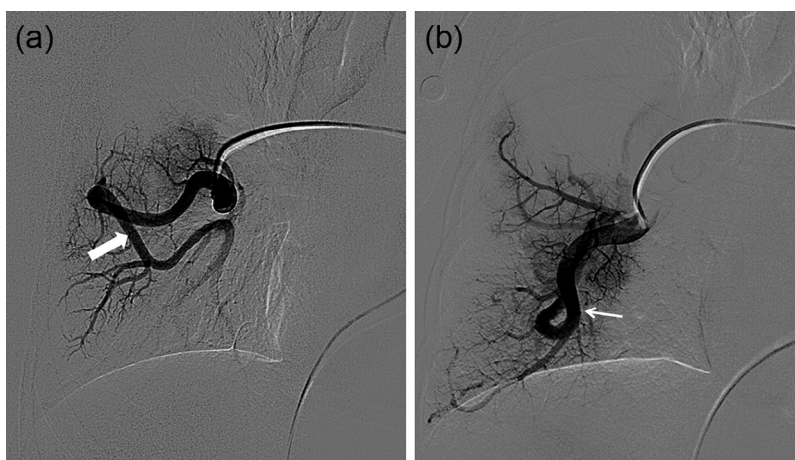

Fig. 5 – (A and B) Selective catheterization of the 2 wandering pulmonary arteries (large and small arrows) showing multiple normal pulmonary branches to the lung parenchyma.

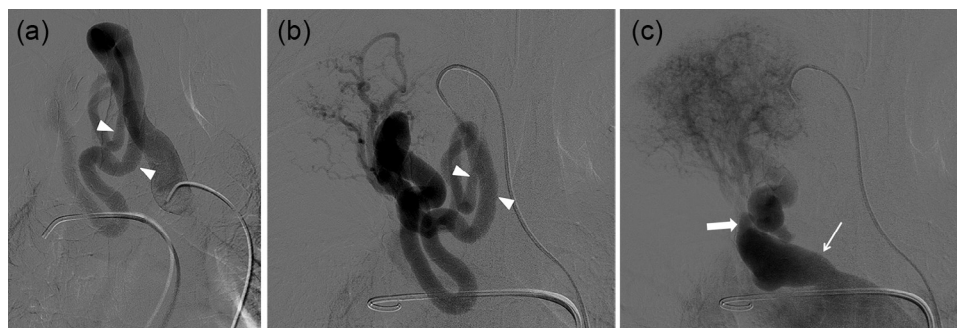


Fig. 6 – (A–C) Selective angiogram of the intercostobronchial artery was performed, which further revealed that the ICBT divides into 2 tortuous branches (arrowheads) that eventually unite together before communicating with the superior branch of the pulmonary artery (small arrow), which appears atretic (large arrow).

In our case, we decided to use AVP devices to embolize the fistula. The AVP is a self-expanding, cylindrical occluding device made out of nitinol mesh wires. It can be safely used in high-flow fistula, where coils are less accurately and safely released [15]. After placement of the device, angiograms can be performed to confirm location, and the device can then be deployed in a relatively precise and controllable fashion. The device can be retrieved and repositioned, if the location was unsatisfactory. Additionally, the device is usually oversized by 30%-50% of the size of the target vessel, which offers more stability in the deployed vessel, with less chances of migration. The AVP also has a distinctive appearance on CT, with significantly less metal artifact compared with coils, allowing more accurate interpretation of follow-up studies.

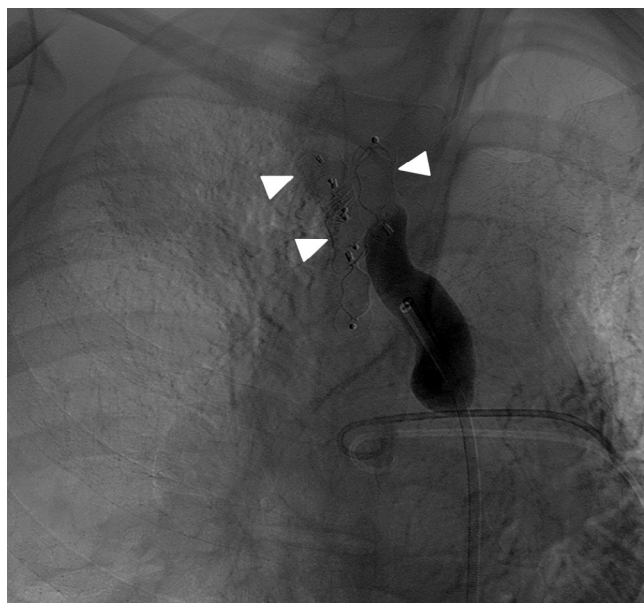


Fig. 7 – Follow-up angiogram of the intercostobronchial trunk after placement of 5 Amplatzer vascular plugs (arrowheads), showing occlusion of the fistulous communication.

Conclusion

The ICBT-PA fistula associated with PA branch atresia is a rare pathology that has not been previously reported in literature. Our patient also has wandering pulmonary arteries coursing circuitously through the lung. The decision to treat his fistula was to avoid hemorrhage during resection of his lung cancer. We performed minimally invasive embolotherapy using AVP, which offers several advantages compared with coils.

REFERENCES

- [1] Castaner E, Gallardo X, Rimola J, Pallardó Y, Mata JM, Perendreu J, et al. Congenital and acquired pulmonary artery anomalies in the adult: radiologic overview. *Radiographics* 2006;26(2):349–71.
- [2] Kent E. Developmental abnormalities in the systemic blood supply to the lungs. *AJR Am J Roentgenol* 1991;156:669–79.
- [3] Salazar-Mena J, Salazar-Gonzalez J, Salazar-Gonzalez E. Meandering right pulmonary vein: a case of scimitar variant. *Pediatr Radiol* 1999;29(8):578–80.
- [4] Tsitouridis I, Tsinoglou K, Morichovitou A, Stratilati S, Siouggaris N, Kontaki T. Scimitar syndrome versus meandering pulmonary vein: evaluation with three-dimensional computed tomography. *Acta Radiol* 2006;47(9):927–32.
- [5] Killen D, Muehlebach G, Wathanacharoen S. Aortopulmonary fistula. *South Med J* 2000;93(2):195–8.
- [6] Adhyapak S, Haridas A, Yeriswamy M, Santosh MJ, Shetty GG, Varghese K, et al. Syphilitic aortitis an uncommon cause of acquired aortopulmonary fistula. *Ann Thorac Surg* 2009;88(5):1672–4.
- [7] Chiostrri B, Lugones I, Grippo M, Trentacoste L, Schlichter AJ. Aortopulmonary fistula after an arterial switch operation. *Ann Thorac Surg* 2010;89:287–9.
- [8] Do K, Goo J, Im J, Kim KW, Chung JW, Park JH. Systemic arterial supply to the lungs in adults: spiral CT findings. *Radiographics* 2001;21:387–402.
- [9] Fraser RS. Developmental anomalies affecting the airways and lung parenchyma. In: Fraser R.S., Müller N.L., Colman N., Pare D.D., editors. *Fraser and Pare's diagnosis of diseases of the chest, vol. 1*. Philadelphia (PA): Saunders; 1999, p. 597–675.

-
- [10] Kurosaki Y, Kurosaki A, Irimoto M, Kuramoto K, Itai Y. Systemic arterial supply to normal basal segments of left lower lobe: CT findings. *J Comput Assist Tomogr* 1993;17:857–61.
- [11] Hampson S, Pepper J. Role of computed tomography in aortopulmonary fistula. *Thorax* 1987;42:395–6.
- [12] Dixit M, Gan M, Narendra N, Mohapatra RL, Halkatti PC, Bhaskar BV. A rare complication of an aortic aneurysm. *Tex Heart Inst J* 2009;36(5):483–5.
- [13] Giacobine J, Cooley A. Surgical treatment of aortopulmonary fistula secondary to aortic arch aneurysm: report of successful case. *J Thorac Cardiovasc Surg* 1960;39:130–6.
- [14] Slonim M, Adams T, Kollmeyer R. Endovascular repair of an aortopulmonary artery fistula with use of controlled-release coils. *J Vasc Interv Radiol* 2004;15(8):861–4.
- [15] Macdonald S, Garminati M, Butera G. Initial experience with the Amplatzer Vascular Plug IV in congenital heart disease: coronary artery fistula and aortopulmonary collateral artery embolization. *J Invasive Cardiol* 2011;23:120–4.