

A Breast Foreign Body Migrating to the Back

Osamu Ito, MD, PhD

Tomoyuki Yano, MD, PhD

Department of Plastic Surgery
Yokohama City Minato Red Cross Hospital
Yokohama, Kanagawa, Japan

Minako Ito, MD, PhD

Medical Check Center
Yokohama City Minato Red Cross Hospital
Yokohama, Kanagawa, Japan

Takayuki Shirai, MD

Hiroki Miyashita, MD

Noriko Uemura, MD

Department of Plastic Surgery
Tokyo Medical and Dental University
Bunkyo, Tokyo, Japan

Takeshi Kawazoe, MD, PhD

Department of Plastic Surgery
Kyoto University
Kyoto, Japan

Sir:

A 72-year-old woman presented to our hospital with bilateral back nodules. She had received breast augmentation with silicone injections over 40 years ago; however, the silicon had moved in recent months and spread outside the breasts, resulting in breast deformations. She underwent silicone removal with partial resection of the pectoralis major muscle 6 months after the breast augmentation.

MATERIAL AND METHODS

On presentation, the patient reported elevated masses in the back, growing over several years. Three-dimensional computed tomography showed some residual foreign bodies in the chest (Fig. 1) and masses under both the latissimus dorsi muscles (Fig. 2).

RESULTS

The excised masses comprised liquid silicone; they were thought to have moved through the loose

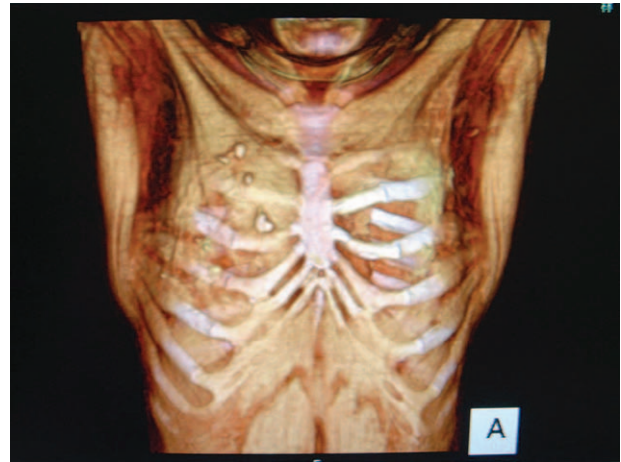

Fig. 1. There are deformations of both breasts and some residual foreign bodies in the chest.

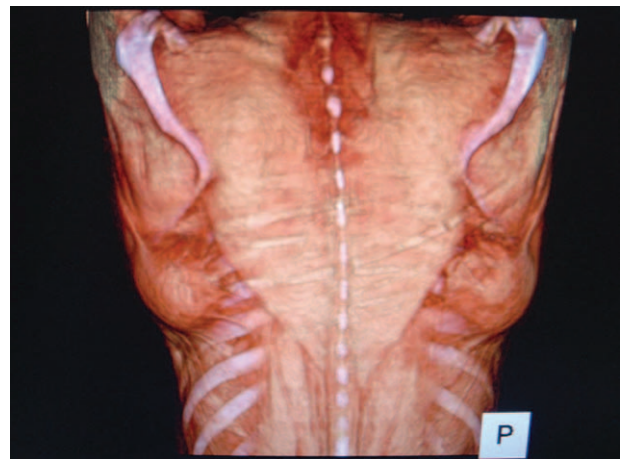


Fig. 2. There are masses under both the latissimus dorsi muscles.

tissue between the ribs and back muscles. The silicon had spread widely, and it was observed in the cervical and distal humerus.

DISCUSSION

In Japan and Asia, some people with silicone injections have experienced health issues¹⁻³; fortunately, this patient did not experience any silicon-related adverse events.

Correspondence to Osamu Ito, MD, PhD
Department of Plastic Surgery
Yokohama City Minato Red Cross Hospital
3-12-1, Shinyamashita, Naka-Ku
Yokohama, Kanagawa, Japan
osaito1005@yahoo.co.jp

Copyright © 2016 The Authors. Published by Wolters Kluwer Health, Inc. on behalf of The American Society of Plastic Surgeons. All rights reserved. This is an open-access article distributed under the terms of the Creative Commons Attribution-Non Commercial-No Derivatives License 4.0 (CCBY-NC-ND), where it is permissible to download and share the work provided it is properly cited. The work cannot be changed in any way or used commercially.
Plast Reconstr Surg Glob Open 2016;4:e662; doi: 10.1097/GOX.0000000000000662; Published online 22 March 2016.

DISCLOSURE

The authors have no financial interest to declare in relation to the content of this article. The Article Processing Charge was paid for by the authors.

REFERENCES

1. Okubo M, Hyakusoku H, Kanno K, et al. Complications after injection mammoplasty. *Aesthetic Plast Surg.* 1992;16:181–187.
2. Peters W, Fornasier V. Complications from injectable materials used for breast augmentation. *Can J Plast Surg.* 2009;17:89–96.
3. Nakahori R, Takahashi R, Akashi M, et al. Breast carcinoma originating from a silicone granuloma: a case report. *World J Surg Oncol.* 2015;13:72.