

Temporal changes in retinal vascular parameters associated with successful panretinal photocoagulation in proliferative diabetic retinopathy: A prospective clinical interventional study

Thomas Lee Torp,^{1,2}  Ryo Kawasaki,³ Tien Yin Wong,⁴ Tunde Peto^{2,5} and Jakob Grauslund^{1,2} 

¹Department of Ophthalmology, Odense University Hospital, Odense, Denmark

²Department of Clinical Research, University of Southern Denmark, Odense, Denmark

³Department of Public Health, Yamagata University Graduate School of Medical Science, Yamagata, Japan

⁴Singapore National Eye Centre, Duke-NUS Medical School, National University of Singapore, Singapore City, Singapore

⁵Queen's University Belfast, Belfast, UK

ABSTRACT.

Purpose: We aimed to investigate changes in retinal vascular geometry over time after panretinal photocoagulation (PRP) in patients with proliferative diabetic retinopathy (PDR).

Methods: Thirty-seven eyes with PDR were included. Wide-field fluorescein angiography (Optomap, Optos PLC., Dunfermline, Scotland, UK) was used to diagnose PDR at baseline and to assess activity at follow-up month three and six. At each time-point, a trained grader measured retinal vessel geometry on optic disc (OD) centred images using semiautomated software (SIVA, Singapore I Vessel Assessment, National University of Singapore, Singapore) according to a standardized protocol.

Results: At baseline, the mean age and duration of diabetes were 52.8 and 22.3 years, and 65% were male. Mean HbA1c was 69.9 mmol/mol, and blood pressure was 155/84 mmHg. Of the 37 eyes with PDR, eight (22%) eyes had progression at month three and 13 (35%) progressed over six months. Baseline characteristics, including age, sex, duration of diabetes, HbA1c, blood pressure, vessel geometric variables and total amount of laser energy delivered did not differ by progression status. However, compared to patients with progression of PDR, patients with favourable treatment outcome had alterations in the retinal arteriolar structures from baseline to month six (calibre, 154.3 μm versus 159.5 μm , $p = 0.04$, tortuosity 1.12 versus 1.10, $p = 0.04$) and in venular structures from baseline to month three (fractal dimension 1.490 versus 1.499, $p = 0.04$, branching coefficient (BC) 1.32 versus 1.37, $p = 0.01$).

Conclusion: In patients with PDR, successful PRP leads to alterations in the retinal vascular structure. However, baseline retinal vascular geometry characteristics did not predict treatment outcome.

Key words: clinical – computer-assisted – humans – NAVILAS – panretinal photocoagulation – proliferative diabetic retinopathy – prospective – retinal vessel geometry – SIVA

Acta Ophthalmol. 2018; 96: 405–410

© 2017 The Authors. Acta Ophthalmologica published by John Wiley & Sons Ltd on behalf of Acta Ophthalmologica Scandinavica Foundation.

This is an open access article under the terms of the Creative Commons Attribution-NonCommercial-NoDerivs License, which permits use and distribution in any medium, provided the original work is properly cited, the use is non-commercial and no modifications or adaptations are made.

doi: 10.1111/aos.13617

Introduction

In 2015, 415 million people had diabetes on a global scale, and the number is expected to rise to 642 million by 2040 (Rahelic 2016). Diabetic retinopathy (DR) is the leading complication to diabetes and is almost universal after 25 years (Grauslund et al. 2009; Cheung et al. 2010b; Wong et al. 2016). A late stage complication to DR is PDR which affects approximately 7% of all patients (Yau et al. 2012; Zheng et al. 2012). In PDR retinal hypoxia, an upregulation of vascular endothelial growth factor (VEGF) and subsequent retinal neovascularization can lead to vitreous haemorrhage, tractional retinal detachment and severe visual loss (Grauslund et al. 2009).

In 1976, the landmark Diabetic Retinopathy Study (DRS) showed that the risk of severe visual loss in PDR could be reduced by 57% when treated with PRP (DRS 1976). However, the beneficial mechanisms of PRP in preventing PDR progression have never been clearly understood (Cheung et al. 2010b; Wong et al. 2016). One theory is that the laser energy delivered to the retinal pigment epithelium is conducted to the neurosensory retina, leading to destruction of the affected retinal areas, thus reducing the hypoxic load (DRS

1976, 1981; ETDRS 1991; Stefansson et al. 1992). However, while PRP has been the gold-standard of care in PDR, interindividual variation exists and some eyes with PDR continue to progress while others remain stable after PRP. This has led to either insufficient or excessive treatment of some patients, which could either increase the risk of progression of PDR with severe visual loss or laser-induced side-effects like visual field loss, night-blindness and macular oedema (DRS 1981; Ferris et al. 1987; ETDRS 1991).

Studying the retinal vascular geometry may provide clues to structural changes after PRP (Cheung et al. 2015). Murray proposed in 1926, the optimal arteriolar branching angle (BA) to be 75 degrees (Murray 1926), and any deviation from this was seen as less optimal for the retinal circulatory system. In recent years, it has become possible to access local and global retinal vessel geometric variables such as calibre, fractal dimension (F_D) and tortuosity using new semiautomated software which has enabled more accurate and faster measurements (Cheung et al. 2010a; Sasongko et al. 2010, 2011).

The aim of our study was to individually predict the outcome of PRP treatment in eyes with PDR. We hypothesize that retinal vessel geometric variables may allow us to predict progression of PDR after PRP. In a cohort of patients with treatment-naïve PDR, we aimed to investigate if retinal vessel geometry at baseline could be used to identify patients at risk of progression of PDR after PRP treatment. We also investigated if retinal vessel geometry could be used as a postoperative biomarker for PDR activity at three (3 M) and six month (6 M) follow-up.

Materials and Methods

We conducted a prospective clinical interventional study of 38 eyes with treatment-naïve PDR who were followed for 6 months at Odense University Hospital, Odense, Denmark between 1 August 2014 and 31 October 2015. The study was registered at Clinical Trials (ID NCT02157350), approved by the Regional Scientific Ethics Committee (ID S-20140046), The Danish Data Protection Agency (ID 14/16546) and performed in

accordance with the criteria of the Helsinki II Declaration and good clinical practice. All patients gave informed consent before inclusion in the study. The inclusion criteria were age above 18, no clinical significant macular oedema or treatment-demanding cataract on the study eye.

At baseline, all patients provided a full medical history and underwent thorough slit lamp examination in mydriasis (Tropicamid 10 mg/ml (Mydriacyl) and phenylephrine 10% (Metaoxedrin)). Optical coherence tomography (OCT) and fundus photography with 45° OD centred image were captured by a 3D OCT-2000 Spectral domain OCT (Topcon, Tokyo, Japan), and wide-field fundus images and fluorescein angiography (Optomap; Optos PLC., Dunfermline, Scotland, UK) were performed. The baseline examinations were complemented by measurement of blood pressure (Omron 705CP, Hoofddrop, The Netherlands) and haemoglobin A_{1c} (HbA_{1c}). All examinations were performed by trained personnel.

After baseline examinations, all patients received PRP in two sessions 1 week apart by a navigated laser-system (NAVILAS[®], OD-OS GmbH, Berlin, Germany). Local anaesthetic (Oxybuprocain Hydrochloride 0.4%) was given prior to PRP, and a NAVILAS 34 or 38 mm contact lens was used during the treatment session. All treatments were given by certified personnel (TLT and JG). All baseline examinations were repeated at 3 M and 6 M follow-up. Progression of PDR was defined as new vessel formation, expanding area of minimum one proliferation or increased area of fluorescein leakage on angiography, as defined by clinical guidelines. Progression at 6 M was defined as the sum of eye with progression at 3 M and 6 M follow-up. Supplementary PRP was given for patients with progression of PDR at either follow-up.

Image assessment

Optic disc (OD) centred 45° fundus images (3D OCT-2000 Spectral domain OCT) acquired at baseline, 3 M, and 6 M were used for retinal vessel geometry analyses. The vessel geometry analyses were performed using the verified semiautomated SIVA software (Singapore I Vessel Assessment,

National University of Singapore, Singapore, software version 4). All images were graded by a single-trained grader (TLT) in accordance to the SIVA grading protocol. The equipment and technique are described elsewhere (Sasongko et al. 2010; Crosby-Nwaobi et al. 2012). In brief, the software automatically detects the OD and places a three-zoned grid around it. Zone A, Zone B and Zone C located 0–2.0 disc diameters from the OD (Fig. 1). We measured the following: the central retinal artery and vein calibre were estimated using the ‘Big-6-formula’ (Knudtson et al. 2003). The vessel tortuosity which is an index of how curvy the retinal vessels are as compared to a straight line of the same vessel segment. The F_D summarizes the complexity and density of branching of the retinal vascular tree in a single noninteger variable. The length diameter ratio (LDR) is a measure of the calibre which is independent of refractive magnification power of the eye. The BC indicates the change in vessel diameter from the parent vessel to the two daughter vessels across a bifurcation. The junctional exponent deviation (JED) is defined as the extent to which the relationship between the diameter of the parent vessel and the daughter vessels deviates from theoretically defined optimum.

All vessel geometric variables of interest (calibre, tortuosity, F_D , LDR, BA, BC and JED) (Fig. 2) were measured in Zone C. The grader was allowed to adjust the pretraced OD location, arterioles (red) and venules (blue) according to the grading protocol. Images were defined as ungradable if less than four arterioles or venules were traced or if the cut-off region took up more than half of a quadrant in Zone C.

Statistical analyses

All statistical calculations were performed using STATA 14.1 (StataCorp, College Station, TX), and p-values under 0.05 were considered statistically significant. We only included one eye from patients with biocular PDR because of the known potential correlation between two eyes from the same patient (Armstrong 2013). At baseline, categorical data are presented as percentage and continuous data concerning demographic data as mean with

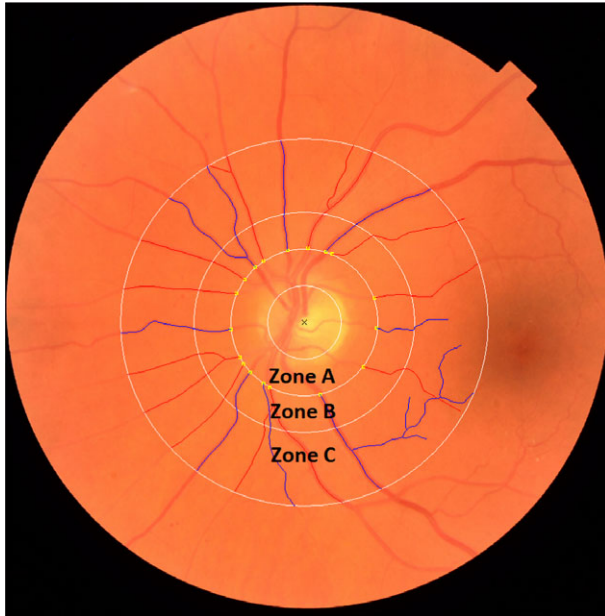


Fig. 1. The grid from the semiautomated vessel grading software *SIVA* as placed on an optic disc centred 45° fundus image. Arterioles and venules drawn as red and blue lines. Zones A, B and C are located 0.0–0.5, 0.5–1.0 and 1.0–2.0 disc diameters from the edge of the optic disc, respectively. All geometric variables are measured in Zone C.

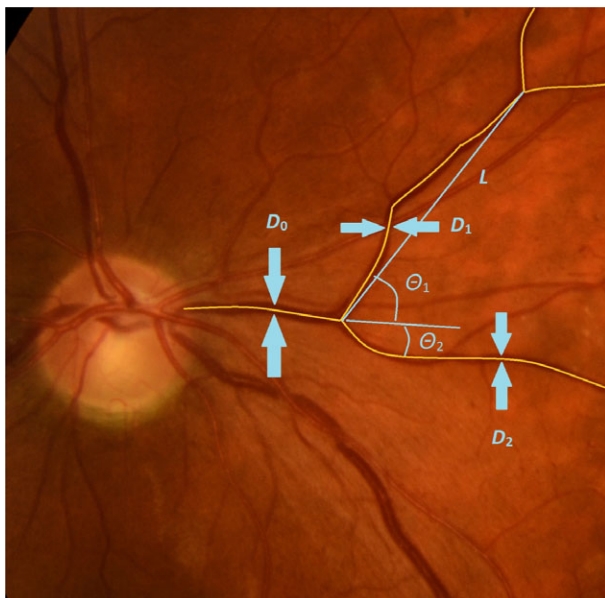


Fig. 2. Definition of the retinal vessel geometric variables. Yellow lines are traced retinal vessels, and blue lines, arrows and titles are drawn to explain the math used to define the geometric variables. D_0 = parent vessel diameter (μm), D_1 = diameter of daughter vessel one (μm), D_2 = diameter of daughter vessel two (μm), θ_1 = angle between daughter vessel one and imaginary progress of parent vessel if no branching had occurred (degree), θ_2 = angle between daughter vessel two and imaginary progress of parent vessel if no branching had occurred (degree), L = strait line from branching point to branching point, length diameter ratio = L/D_0 , branching angle = $\theta_1 + \theta_2$, branching coefficient = $(D_1 + D_2)^2/d_0^2$, junctional exponent deviation $((D_0^3 - D_1^3 - D_2^3)^{1/3})/D_0$.

standard deviation (SD). Vessel geometric variables are presented as median with interquartile range (IQR). Differences between patients with

progression and nonprogression of PDR were compared by the Wilcoxon rank-sum test for continuous data and Chi-squared test for categorical data.

The Wilcoxon matched-pairs signed-rank test was used when comparing data from baseline to follow-up on the same patient. The nonparametric Cuzick test was used to test for trends across time-points (BL, 3 M, 6 M) in matched data.

Results

We examined 38 eyes from 38 patients. One patient died before 3 M follow-up, thus 37 eyes completed the 6 M follow-up. At baseline, the mean \pm SD age and duration of diabetes were 52.8 ± 13.7 and 22.4 ± 12.1 years, and 65% were male. Mean HbA1c was 69.9 mmol/mol, and blood pressure was 155/84 mmHg. At baseline, patients in the two groups (postlaser nonprogression and progression of PDR) did not differ according to age, sex, duration of diabetes, HbA1c, blood pressure, vessel geometric variables (data not shown) or total amount of laser energy delivered to the retina (Table 1).

Eight (22%) study eyes had progression of PDR, at 3 M. We found no difference between the two groups by baseline characteristics or by any of the retinal vessel geometric variables (Table 2). We found a statistical significant increment in F_D from baseline to 3 M follow-up (nonprogression of PDR 1.490 ± 0.051 versus 1.499 ± 0.054 , $p = 0.04$, progression of PDR 1.487 ± 0.077 versus 1.501 ± 0.051 , $p = 0.03$). Furthermore, a statistical significant increment in the venular BC from baseline to 3 M was seen in patients with nonprogression of PDR (BC 1.32 ± 0.12 versus 1.37 ± 0.16 , $p = 0.01$).

A total of 13 (35%) study eyes progressed in PDR during the 6 M follow-up. We found no differences between the two groups comparing baseline features (Table 2). Patients with progression of PDR deviated more from the theoretical optimal BA than patients with nonprogression of PDR at 6 M ($82.85^\circ \pm 18.55^\circ$ versus $70.85^\circ \pm 21.56^\circ$, $p = 0.01$). Furthermore, we found a temporal trend of decreased arteriolar branching angle in patients with nonprogression of PDR from BL via 3 M to 6 M follow-up ($p = 0.04$) (data not shown). In addition, all differences seen at 6 M were found on the arteriolar side in patients with favourable treatment

Table 1. Demographic baseline characteristics for patients with subsequent nonprogression and progression of proliferative diabetic retinopathy after panretinal photocoagulation.

Demographic data	Nonprogression of PDR Mean (SD)	Progression of PDR Mean (SD)	p value
n	24	14	
Age, years	53.8 (13.9)	49.1 (14.9)	0.39
Sex, Male %	71%	50%	0.19
Duration of diabetes, years	22.7 (12.7)	21.1 (11.3)	0.70
HbA1c, mmol/mol	71 (20)	69 (18)	0.79
Systolic blood pressure, mmHg	158 (24)	146 (23)	0.23
Diastolic blood pressure, mmHg	86 (15)	82 (14)	0.71
Laser energy, Joule	12.26 (3.70)	12.29 (3.33)	0.98

Baseline characteristics in accordance to the number of patients with progression and nonprogression at follow-up month six. All values are represented as mean ± standard deviation (SD).

PDR = Proliferative diabetic retinopathy.

outcome. The arteriolar calibre increased ($154.3 \pm 16.8 \mu\text{m}$ versus $159.5 \pm 23.9 \mu\text{m}$, $p = 0.04$), and the tortuosity decreased (1.12 ± 0.04 versus 1.10 ± 0.04 , $p = 0.04$) from baseline to 6 M.

Discussion

In this prospective interventional study of patients with treatment-naïve PDR, we found that patients with successful PRP had changes in retinal arterial and venular structures during the first 6 months after PRP. However, the treatment outcome of PRP and whether eyes with PDR progressed could not be predicted by baseline retinal vascular geometry alone. Thus, while sufficient PRP leads to structural retinal modifications not found in patients with progressive disease, baseline retinal geometry was not useful in predicting disease progression.

Three months after PRP, we observed statistical significant changes in the F_D independent of the treatment response. Earlier studies have found a decreased in F_D in patients with PDR who earlier had been treated with PRP (Grauslund et al. 2010; Pedersen et al. 2016), and a 16-year prospective study by Broe et al. found that for every .01 decreased in F_D the risk of PDR increased with 22% (Broe et al. 2014b). A potential explanation could be that progressive ischaemia results in an auto-regulatory-mediated lower complexity and density of branching of the retinal vascular tree. In the short-term, PRP may reverse this process, but due to the underlying progressive nature of the disease, this temporary effect is lost again a few months later.

The BC explains the relationship between the calibres of the parent vessel compared to the daughter vessels at a bifurcation. The venular BC increased in patients with favourable treatment outcome from baseline to 3 M. It is difficult to determine if the changes in the BC is due the parent vessel decreasing or daughter vessels increasing in calibre. However, because the venular calibre did not change from baseline to 3 M, it could be argued that the daughter vessels increased in diameter, to obtain a more optimal relationship between parent and daughter vessel calibre in patients with favourable treatment outcome. Branching coefficient (BC) has not been studied to the same extent as many of the other vascular variables, and therefore, the association to PDR is unclear.

Six months after PRP, only eyes that stabilized in PDR developed changes in the retinal arteriolar structure. In a cross-sectional study from WESDR, Klein et al. found statistical significant smaller retinal arteriolar and venular vessel calibre in patients with PDR previously treated with PRP compared to patients without such treatment (Klein et al. 2006). The same results were found in a prospective study by Wilson et al. (1988). In a prospective study by Broe et al. it was shown that a decrease in arteriolar vessel calibre was significantly associated with the 16-year incidence of PDR (Broe et al. 2014a). We found an increase in the arteriolar vessel calibre that could represent a positive response to the PRP treatment with a lower hypoxic load on the retina and a subsequent auto-regulatory arteriolar dilation. We did not find any association between

changes in the venular vessel calibre from baseline to 6 M. Several studies have reported on retinal vasoconstrictive effect of PRP (Gottfredsdottir et al. 1993; Grunwald et al. 1993). Gottfredsdottir et al. (1993) found an overall retinal vessel constriction in patients with diabetic macular oedema treated with macular laser photocoagulation. Grunwald et al. (1993) reported on a retinal vasoconstrictive effect of PRP that may be due to a metabolic response, although this was not stratified to the treatment outcome and was performed on a limited cohort of patients with PDR.

In patients with favourable treatment outcome, the arteriolar vessel tortuosity decreased from baseline to 6 M, thus making the arterioles less twisted. One explanation could be that the hypoxic load increases with increased levels of DR. When the patient develops PDR, the vascular tree alters appearance and the overall tortuosity increases. After receiving sufficient PRP treatment, the hypoxic drive is diminished and the retinal vessels changes to a more ‘normal’ appearance (e.g. less tortuous), thus agreeing with the sparse literature on the area (Crosby-Nwaobi et al. 2012). Although the changes seen in the tortuosity were on the arteriolar side, the same mechanism, and to some extent, the same explanation may apply on the venular side, thus we found patients with nonprogression of PDR to be closer to the theoretical optimum BA when compared to patients with progression of PDR at 6 M. Additionally, patients with nonprogression of PDR showed a trend towards an overall decrease in BA across all time-points, whereas patients with progression of PDR were somewhat unchanged. Although patients with nonprogression of PDR decreased in BA, the group still showed a less theoretical optimal BA at 6 M compared to BL. This change could be seen as a persistent ability to alter the vascular appearance, in patients with favourable treatment response.

The strengths of this study were the prospective design, and the use of a semiautomated, validated computer software for analysing retinal vascular parameters. Patients only participated with one eye, thus strengthen the statistical finds in this study. Limitations include a limited sample size, and the

Table 2. Changes in retinal vascular geometrical variables in patients with nonprogression and progression of proliferative diabetic retinopathy three and six months after panretinal photocoagulation.

Retinal vascular morphology		3 months				6 months			
		n	BL Median (IQR)	3 M Median (IQR)	p value	n	BL Median (IQR)	6 M Median (IQR)	p value
Calibre (µm)									
Arterial	Nonprogression	29	155.1 (20.3)	153.4 (17.9)	0.75	24	154.3 (16.8)	159.5 (23.9)	0.04*
	Progression	8	161.3 (32.1)	161.6 (27.7)	0.77	13	163.9 (24.4)	159.0 (19.9)	0.91
	p value		0.53	0.76			0.40	0.75	
Venous	Nonprogression	29	240.6 (29.0)	237.3 (23.6)	0.99	24	238.8 (32.9)	235.3 (40.4)	0.21
	Progression	8	234.2 (14.9)	234.1 (14.9)	0.48	13	234.2 (15.9)	234.4 (21.9)	0.46
	p value		0.60	0.60			0.82	0.80	
Length diameter ratio									
Arterial	Nonprogression	26	16.13 (11.58)	18.32 (7.97)	0.13	22	16.13 (11.58)	13.18 (11.72)	0.38
	Progression	7	18.25 (11.93)	16.90 (10.19)	0.73	11	17.24 (11.93)	18.28 (12.23)	0.85
	p value		0.79	0.79			0.93	0.33	
Venous	Nonprogression	26	12.57 (8.53)	13.72 (6.47)	0.08	22	12.57 (7.33)	14.50 (7.67)	0.24
	Progression	7	15.74 (5.47)	16.47 (6.32)	0.73	11	15.24 (9.04)	12.87 (5.34)	1.00
	p value		0.09	0.48			0.18	0.73	
Fractal Dimension									
	Nonprogression	29	1.490 (0.051)	1.499 (0.054)	0.04*	24	1.490 (0.066)	1.481 (0.108)	0.54
	Progression	8	1.487 (0.077)	1.501 (0.051)	0.03*	13	1.490 (0.044)	1.508 (0.035)	0.38
	p value		0.78	0.59			0.86	0.37	
Tortuosity									
Arterial	Nonprogression	29	1.12 (0.04)	1.12 (0.04)	0.89	24	1.12 (0.04)	1.10 (0.04)	0.04*
	Progression	8	1.11 (0.04)	1.11 (0.06)	0.67	13	1.12 (0.04)	1.12 (0.03)	0.29
	p value		0.98	0.88			0.58	0.16	
Venous	Nonprogression	29	1.10 (0.02)	1.10 (0.02)	0.81	24	1.10 (0.02)	1.10 (0.03)	0.15
	Progression	8	1.11 (0.03)	1.10 (0.02)	0.32	13	1.10 (0.02)	1.11 (0.2)	0.38
	p value		0.57	0.47			0.92	0.50	
Branching angle (degree)									
Arterial	Nonprogression	29	79.16 (20.21)	78.38 (13.18)	0.53	24	76.09 (21.40)	70.85 (21.56)	0.15
	Progression	8	80.18 (18.19)	84.88 (7.95)	0.88	13	81.15 (14.49)	82.85 (18.55)	0.97
	p value		0.39	0.13			0.26	0.01*	
Venous	Nonprogression	29	80.64 (8.87)	80.12 (8.93)	0.59	24	80.66 (10.30)	80.13 (16.93)	0.49
	Progression	8	81.41 (5.65)	81.20 (8.41)	0.77	13	80.82 (5.52)	81.46 (11.42)	0.64
	p value		0.68	0.88			0.75	0.58	
Branching coefficient									
Arterial	Nonprogression	29	1.47 (0.14)	1.52 (0.32)	0.65	24	1.50 (0.20)	1.50 (0.28)	0.24
	Progression	8	1.48 (0.11)	1.45 (0.38)	1.00	13	1.45 (0.10)	1.47 (0.15)	0.70
	p value		0.91	0.79			0.61	0.44	
Venous	Nonprogression	29	1.32 (0.12)	1.37 (0.16)	0.01*	24	1.32 (0.13)	1.35 (0.27)	0.58
	Progression	8	1.32 (0.11)	1.40 (0.22)	0.16	13	1.32 (0.11)	1.34 (0.16)	1.00
	p value		0.85	0.71			0.71	0.79	
Junctional exponent deviation									
Arterial	Nonprogression	29	-0.50 (0.30)	-0.58 (0.49)	0.70	24	-0.49 (0.40)	-0.46 (0.37)	0.20
	Progression	8	-0.59 (0.29)	-0.46 (0.56)	0.77	13	-0.58 (0.23)	-0.48 (0.35)	0.24
	p value		0.53	0.81			0.42	0.88	
Venous	Nonprogression	29	-0.26 (0.24)	-0.36 (0.31)	0.06	24	-0.26 (0.14)	-0.31 (0.52)	0.84
	Progression	8	-0.30 (0.28)	-0.47 (0.27)	0.26	13	-0.35 (0.30)	-0.26 (0.30)	0.75
	p value		0.94	0.67			0.58	0.94	

All values are represented as median + interquartile range (IQR). Differences between patients with nonprogression and progression of proliferative diabetic retinopathy (PDR) (unpaired data) are given vertically, and changes from baseline (BL) to follow-up 3 months (3 M) or 6 months (6 M) (paired data) are represented horizontally.

* Statistically significant.

lack of an untreated observation group, which was not possible for ethical reasons. Furthermore, the retinal vessel geometric variables may to some extent be correlated with the degree of refractive deviations such as high myopia, which was not possible due to lack of refractive data, although this correlation

may be less important when evaluating vascular geometric changes over time.

In conclusion, our prospective cohort study showed that the overall baseline retinal vessel geometry could not predict the stability or activity of PDR after PRP treatment, there were measurable changes in the retinal vessel

geometry over 6 months in eyes with favourable PRP treatment outcome, reflecting structural vessel changes in response to possibly changes in metabolic demand in the retina. Hence, structural retinal arteriolar and venular changes may serve as an individual marker of laser efficacy in PDR.

References

- Armstrong RA (2013): Statistical guidelines for the analysis of data obtained from one or both eyes. *Ophthalmic Physiol Opt* **33**: 7–14.
- Broe R, Rasmussen ML, Frydkjaer-Olsen U et al. (2014a): Retinal vessel calibers predict long-term microvascular complications in type 1 diabetes: the danish cohort of pediatric diabetes 1987 (DCPD1987). *Diabetes* **63**: 3906–3914.
- Broe R, Rasmussen ML, Frydkjaer-Olsen U, Olsen BS, Mortensen HB, Peto T & Grauslund J (2014b): Retinal vascular fractals predict long-term microvascular complications in type 1 diabetes mellitus: the Danish Cohort of Pediatric Diabetes 1987 (DCPD1987). *Diabetologia* **57**: 2215–2221.
- Cheung CY, Hsu W, Lee ML et al. (2010a): A new method to measure peripheral retinal vascular caliber over an extended area. *Microcirculation* **17**: 495–503.
- Cheung N, Mitchell P & Wong TY (2010b): Diabetic retinopathy. *Lancet* **376**: 124–136.
- Cheung CY, Ikram MK, Klein R & Wong TY (2015): The clinical implications of recent studies on the structure and function of the retinal microvasculature in diabetes. *Diabetologia* **58**: 871–885.
- Crosby-Nwaobi R, Heng LZ & Sivaprasad S (2012): Retinal vascular calibre, geometry and progression of diabetic retinopathy in type 2 diabetes mellitus. *Ophthalmologica* **228**: 84–92.
- DRS (1976): Preliminary report on effects of photocoagulation therapy. The Diabetic Retinopathy Study Research Group. *Am J Ophthalmol* **81**: 383–396.
- DRS (1981): Photocoagulation treatment of proliferative diabetic retinopathy. Clinical application of Diabetic Retinopathy Study (DRS) findings, DRS Report Number 8. The Diabetic Retinopathy Study Research Group. *Ophthalmology* **88**: 583–600.
- ETDRS (1991): Early photocoagulation for diabetic retinopathy. ETDRS report number 9. Early Treatment Diabetic Retinopathy Study Research Group. *Ophthalmology* **98**: 766–785.
- Ferris FL 3rd, Podgor MJ & Davis MD (1987): Macular edema in Diabetic Retinopathy Study patients. Diabetic Retinopathy Study Report Number 12. *Ophthalmology* **94**: 754–760.
- Gottfredsdottir MS, Stefansson E, Jonasson F & Gislason I (1993): Retinal vasoconstriction after laser treatment for diabetic macular edema. *Am J Ophthalmol* **115**: 64–67.
- Grauslund J, Green A & Sjolie AK (2009): Prevalence and 25 year incidence of proliferative retinopathy among Danish type 1 diabetic patients. *Diabetologia* **52**: 1829–1835.
- Grauslund J, Green A, Kawasaki R, Hodgson L, Sjolie AK & Wong TY (2010): Retinal vascular fractals and microvascular and macrovascular complications in type 1 diabetes. *Ophthalmology* **117**: 1400–1405.
- Grunwald JE, Brucker AJ, Grunwald SE & Riva CE (1993): Retinal Hemodynamics in Proliferative Diabetic-Retinopathy - a Laser Doppler Velocimetry Study. *Invest Ophthalmol Vis Sci* **34**: 66–71.
- Klein R, Klein BE, Moss SE, Wong TY & Sharrett AR (2006): Retinal vascular caliber in persons with type 2 diabetes: the Wisconsin Epidemiological Study of Diabetic Retinopathy: XX. *Ophthalmology* **113**: 1488–1498.
- Knudtson MD, Lee KE, Hubbard LD, Wong TY, Klein R & Klein BE (2003): Revised formulas for summarizing retinal vessel diameters. *Curr Eye Res* **27**: 143–149.
- Murray CD (1926): The physiological principle of minimum work applied to the angle of branching of arteries. *J Gen Physiol* **9**: 835–841.
- Pedersen KB, Broe R & Grauslund J (2016): Inter-eye agreement in measurement of retinal vascular fractal dimension in patients with type 1 diabetes mellitus. *Ophthalmic Epidemiol* **23**: 131–135.
- Rahelic D (2016): [7th edition of *Idf Diabetes Atlas—call for immediate action*]. *Lijec Vjesn* **138**: 57–58.
- Sasongko MB, Wang JJ, Donaghue KC et al. (2010): Alterations in retinal microvascular geometry in young type 1 diabetes. *Diabetes Care* **33**: 1331–1336.
- Sasongko MB, Wong TY, Nguyen TT, Cheung CY, Shaw JE & Wang JJ (2011): Retinal vascular tortuosity in persons with diabetes and diabetic retinopathy. *Diabetologia* **54**: 2409–2416.
- Stefansson E, Macherer R, E de Juan . Jr, McCuen BW 2nd & Peterson J (1992): Retinal oxygenation and laser treatment in patients with diabetic retinopathy. *Am J Ophthalmol* **113**: 36–38.
- Wilson CA, Stefansson E, Klombers L, Hubbard LD, Kaufman SC & Ferris FL (1988): Optic disk neovascularization and retinal vessel diameter in diabetic-retinopathy. *Am J Ophthalmol* **106**: 131–134.
- Wong TY, Cheung CMG, Larsen M, Sharma S & Sim R ó (2016): Diabetic retinopathy. *Nat Rev Dis Primers* **2**: 16012.
- Yau JWY, Rogers SL, Kawasaki R et al. (2012): Global prevalence and major risk factors of diabetic retinopathy. *Diabetes Care* **35**: 556–564.
- Zheng Y, He M & Congdon N (2012): The worldwide epidemic of diabetic retinopathy. *Indian J Ophthalmol* **60**: 428–431.

Received on May 17th, 2017.
Accepted on September 6th, 2017.

Correspondence:
Thomas Lee Torp
Department of Ophthalmology
Odense University Hospital
Sdr. Boulevard 29
Odense, Denmark
Tel: +0045 65411682
Fax: +0045 66123468
Email: thomas.lee.torp@rsyd.dk

This work was supported by The Velux Foundation and The Region of Southern Denmark. None of the funders have been involved in any decisions regarding this study, and the authors declare no duality of interest associated with this article.