

Contents lists available at [ScienceDirect](https://www.sciencedirect.com)

International Journal of Surgery Case Reports

journal homepage: www.casereports.com

Two separate tumours—Concomitant papillary carcinoma in thyroglossal duct cyst and right thyroid lobe: Case report and review of the literature

Waleed Mahmoud^a, Walid El Ansari^{b,c,d,*}, Abdelrahman Abdelaal^a, Mahir Petkar^e, Mohamed S. Al Hassan^a

^a Department of General Surgery, Hamad General Hospital, Doha, Qatar

^b Department of Surgery, Hamad General Hospital, Doha, Qatar

^c College of Medicine, Qatar University, Doha, Qatar

^d School of Health and Education, University of Skövde, Skövde, Sweden

^e Department of Laboratory Medicine & Pathology, Hamad General Hospital, Doha, Qatar

ARTICLE INFO

Article history:

Received 23 June 2020

Received in revised form 15 July 2020

Accepted 15 July 2020

Available online 17 July 2020

Keywords:

Thyroglossal duct cyst

Thyroid papillary carcinoma

Thyroid surgery

Thyroid imaging

ABSTRACT

INTRODUCTION: Malignancy of thyroglossal duct cyst (TGDC) is rare, usually as papillary carcinoma, and less frequently as squamous cell or follicular carcinoma. TGDC carcinoma can present as a mass arising from the neck, with or without compression symptoms. Papillary carcinoma in TGDC concomitant with another papillary carcinoma in the thyroid gland is extremely rare.

PRESENTATION OF CASE: : 31 years old female with a neck lump since 2 years, slowly increasing in size, with mild pain while drinking fluids, and no change of voice. No past history of neck irradiation or family history of thyroid cancers. Ultrasonography of the neck showed TGDC and right thyroid nodule. Ultrasound guided fine needle aspiration and cytology of the TGDC showed TGDC papillary carcinoma. The patient underwent Sistrunk's procedure and total thyroidectomy.

DISCUSSION: Rare case of classic papillary carcinoma arising in TGDC, concomitant with another papillary carcinoma in the right thyroid nodule. Preoperative work up included US and fine needle aspiration and cytology (FNAC). Post-operative histopathology showed papillary carcinoma in the TGDC; and another in the right thyroid lobe that was a papillary carcinoma with follicular patterns.

CONCLUSIONS: TGDC carcinoma concurrent with another carcinoma in the right thyroid lobe as two separate tumours are extremely rare. All patients should undergo Sistrunk's procedure, and total thyroidectomy for the thyroid tumour. Follow-up requires thyroxine replacement therapy to treat hypothyroidism and to suppress TSH in order to prevent recurrence; and neck ultrasound and thyroglobulin tumour marker to detect recurrence if present.

© 2020 The Authors. Published by Elsevier Ltd on behalf of IJS Publishing Group Ltd. This is an open access article under the CC BY-NC-ND license (<http://creativecommons.org/licenses/by-nc-nd/4.0/>).

1. Introduction

Thyroglossal duct cyst (TGDC) is a common form of midline neck mass, and an anomaly in thyroid development, arising due to persistence of thyroglossal duct during early development [1]. In the third week of fetal life, the thyroid gland arises from a midline endodermal invagination of the foregut, at the level of the foramen caecum [2]. In childhood, about 70 % of midline masses in the neck are thyroglossal duct related; in adults, 7 % of midline masses in the neck are TGDC [3].

The complications associated with TGDC include cosmetic problems, fistula formation and recurrent infections [4]. There is also a

< 1 % chance of developing TGDC carcinoma [4,5], mostly papillary carcinoma (92 %), or other less common types e.g. squamous cell (5.2 %) or follicular (1.7 %) carcinomas [6]. Similar to thyroglossal duct cysts, TGDC carcinomas often present as an asymptomatic mass in the midline of the neck, although these tumours can arise in a lateral location [5].

The most common surgical procedure used for TGDC is Sistrunk's procedure, comprising excision of the TGDC, the central portion of the body of the hyoid bone, and a core of tissue around the thyroglossal tract to open into the oral cavity at the foramen caecum [7]. For patients with TGDC carcinoma, Sistrunk's procedure is performed as the only procedure in low-risk patients. In presence of another carcinoma elsewhere in the thyroid or in patients who are high-risk, additional total thyroidectomy and postoperative radioactive iodine ablation therapy are considered [7].

We report a case of classic papillary carcinoma arising in TGDC concomitant with another papillary carcinoma arising in the

* Corresponding author at: Department of General Surgery, Hamad General Hospital, Doha, Qatar.

E-mail address: welansari9@gmail.com (W. El Ansari).

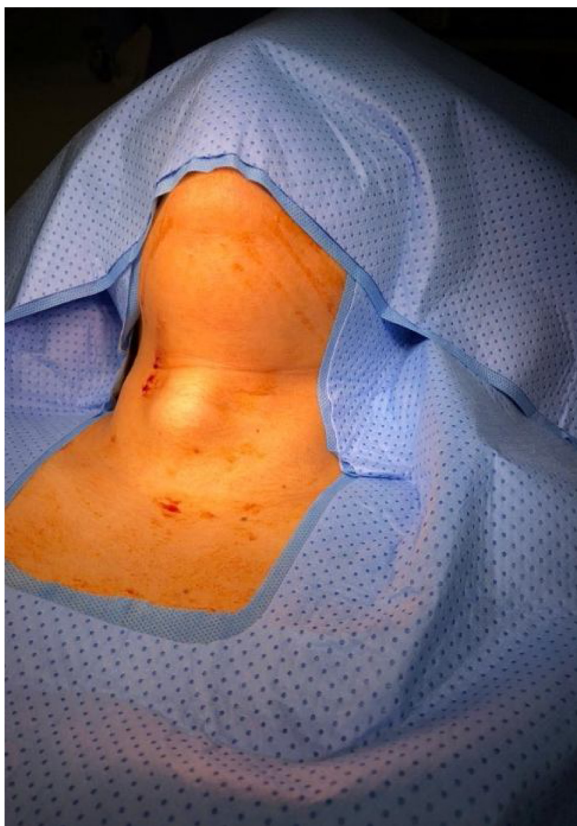

Fig. 1. Patient with midline neck swelling.

thyroid gland. We also undertook and include a comprehensive review of the literature of cases of papillary carcinoma in both the TGDC and the thyroid gland. The case is reported in line with the updated consensus-based surgical case report (SCARE) guidelines [8].

2. Case presentation

A 31 year old Filipina female patient was referred to our thyroid outpatient clinic at Hamad General Hospital (academic tertiary care hospital) in Doha, Qatar, with a neck lump of 2 years duration. The mass was slowly increasing in size, accompanied with mild pain while drinking fluids, no difficulty during swallowing of solid food, and no change of voice. There was no past history of recent upper respiratory tract infections, neck discharge or use of medication; no past history of neck irradiation, and no family history of thyroid cancers. Physical examination showed a well-demarcated, mobile, midline cervical swelling of about 4 cm in diameter (Fig. 1) that

moved with swallowing and with tongue protrusion. Palpation of the thyroid was otherwise normal, with no cervical lymphadenopathy.

Investigations: Laboratory investigation showed normal blood picture, thyroid function and normal vitamin D and calcium levels. Ultrasound scan of the neck (Fig. 2) showed a midline heterogeneous solid and cystic mass (3.6 × 2.3 cm) with thickened internal echoes and calcification, extending to the right side of the neck. The swelling moved with swallowing, and was suspicious for midline complex TGDC. In addition, there were nodules of the right thyroid lobe of which the largest measured 16 × 14 × 15 mm, and showed normal echogenicity with normal vascularity, and TI-RADS 4 finding. Ultrasound scan showed normal isthmus with no lesion. Ultrasound-guided fine needle aspiration and cytology (FNAC) of the anterior neck mass lesion (TGDC) was positive for malignancy, consistent with papillary thyroid carcinoma.

Management: Following our multidisciplinary team (MDT) consultation, the patient underwent total thyroidectomy and surgical excision of the TGDC using the Sistrunk procedure (Fig. 3). The surgical procedures were undertaken by an experienced thyroid surgeon and were uneventful. As per the standard practice at our institution, parathyroid hormone level was checked while the patient was in recovery and it was considerably low (6 pg/mL), so hypocalcemia treatment was started immediately and the patient did not develop any symptoms of hypocalcemia. She was discharged the next day after surgery, on oral calcium carbonate (1250 mg TID) and active form vitamin D (calcitriol 0.25 mcg daily), thyroxin replacement therapy (levothyroxine 100 mcg O.D) and oral analgesia.

The histological examination of the surgical excision specimen (Fig. 4), comprising the TGDC, hyoid bone and bilateral thyroid lobes with isthmus, showed features of usual conventional type papillary thyroid carcinoma in the right thyroid nodule and the TGDC. The larger focus was in the TGDC, measuring 3 cm in maximum dimension, whereas the thyroid focus measured 1.5 cm. Whilst the carcinoma in the TGDC displayed a predominantly papillary morphology (Fig. 5A), the carcinoma in the right thyroid nodule showed a mixture of papillary and follicular patterns (Fig. 5B). Both tumours had characteristic nuclear features, including nuclear clearing, nuclear grooves and pseudoinclusions. Normal thyroid tissue was present between the two foci, which along with the different predominant morphological appearance, indicated two separate tumour masses. Excision of both tumours appeared complete and no other focus of malignancy was identified in the background thyroid. An incidental benign parathyroid gland was also present.

The patient was then seen at our thyroid surgery clinic after 1 week. She was satisfied with the procedure and had no complaints, normal calcium level, normal thyroid function test (TSH 0.5 mIU/L, T4 20 pmol/l, PTH 24 pg/mL, thyroglobulin 112 ng/mL, thyroglobu-

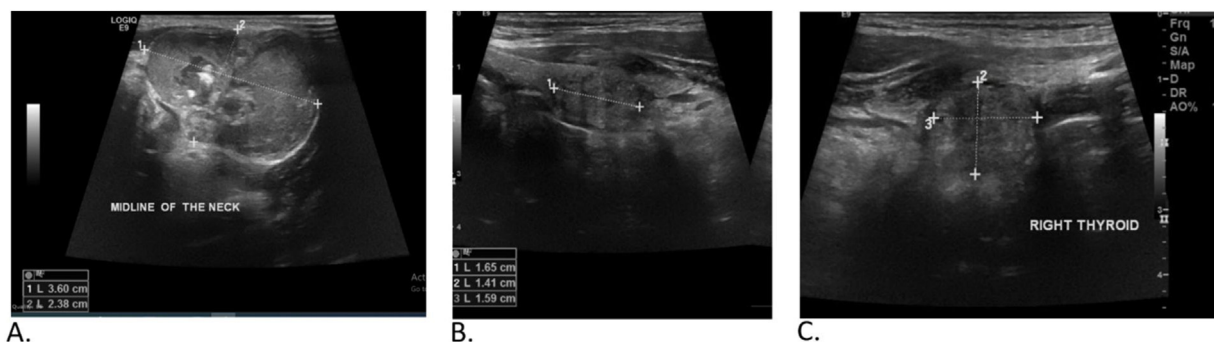


Fig. 2. Ultrasound of the neck showing A. Midline neck swelling (TGDC); B & C. Right thyroid lobe nodule (TI-RADS 4).

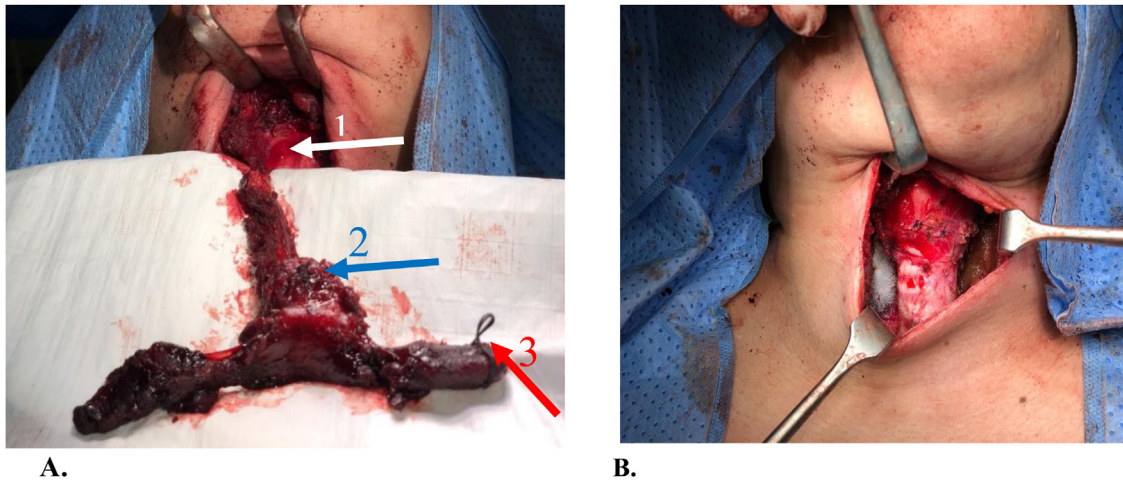


Fig. 3. **A.** Sistrunk’s procedure: removal of the thyroid gland (arrow 3) and thyroglossal duct cyst (arrow 2) with the anterior portion of the hyoid bone (arrow 1); **B.** After complete excision of thyroid gland and thyroglossal duct cyst.

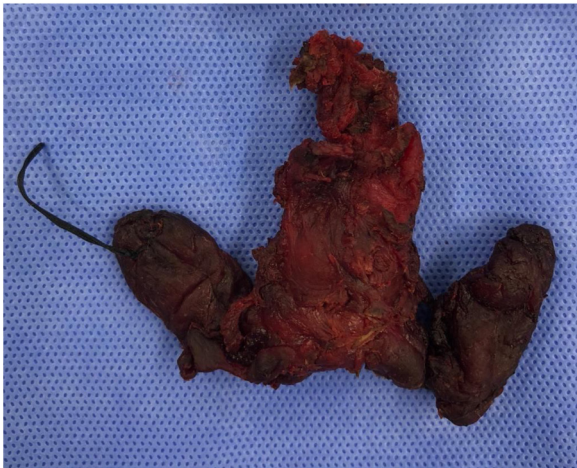


Fig. 4. Specimen (thyroid gland and thyroglossal duct cyst en block) after fixation in formalin.

lin AB < 0.9 ng/mL). The case was discussed again at our MDT, and the decision was to complete the treatment of the patient with a low dose postoperative radioactive iodine therapy (30 mci), and referral to the outpatient thyroid cancer clinic for follow up.

3. Discussion

We present a rare case of classic papillary carcinoma arising in TGDC, concomitant with another papillary carcinoma arising in the right thyroid nodule. Thyroid tissue is normally located in the wall of the TGDC and has potential to harbour malignancy, mostly papillary thyroid carcinoma [9]. Thyroid carcinoma arising in TGDC is rare and is slightly more often in women [10]. The cause of TGDC carcinoma is unclear, although the theories are metastatic disease from an occult primary; or spontaneous development from ectopic thyroid tissue found within the TGDC wall [9].

In terms of presentation, symptoms of TGDC carcinoma cannot be differentiated from benign TGDC. However, rapid increase in growth with compression symptoms or the presence of a firm or hard fixed irregular mass may be signs of TGDC carcinoma [7,11]. Our literature review (Table 1) illustrates that the clinical presentation of TGDC carcinoma is mostly as a painless mass of variable progression with time. In our case, the clinical presentation agrees with the literature, as it was a painless mass (only mild pain with swallowing). In addition, the US scan showed a midline heterogeneous solid and cystic mass with thickened internal echoes and calcification that played an important role in pre-operative diagnosis.

In terms of demographics, the age of our patient (31 years) was slightly younger than ages reported in literature, where the average age is usually ≥ 40 years old [12]. Table 1 shows that the

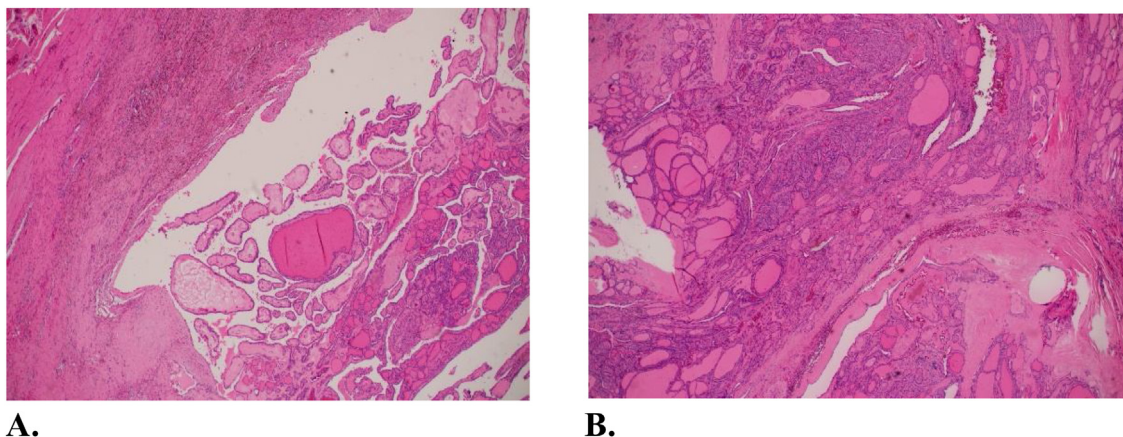


Fig. 5. **A.** Thyroglossal duct cyst showing characteristic features of papillary carcinoma (H&E x 2); **B.** Papillary carcinoma expanding the right thyroid nodule (H&E x 2).

Table 1
Literature review of cases of papillary carcinoma in both the thyroglossal duct cyst and the thyroid gland.

Report ^a	S	Age ^b	P	I ^b	Radiology	FNA	LN	Treatment	Site of tumour	Pathology	Post-op C
Current Case Qatar	F	31	Painless mid neck mass	2	US neck showed a midline heterogenous solid and cystic mass suspicious of mid line complex thyroglossal cyst with right thyroid nodule	PC (biopsy taken from anterior neck mass)	---	Total thyroidectomy + Sistrunk procedure in one setting	TGDC and right thyroid nodule	Classic papillary carcinoma origin from thyroglossal duct cyst and right thyroid nodule	None
Srivanitchapoom 2017 [13] Thailand	F	38	Painless mid neck mass	3	US neck: 1 × 8, 2 × 4 cm cystic mass with septations and solid mural component with micro-calcifications; 4 mm right thyroid nodule also detected	Non diagnostic result	No cervical lymphadenopathy	First procedure: Sistrunk Second procedure: total thyroidectomy	TGDC, right lobe and isthmus	Both pathology results were PC and invasion to right lobe and isthmus	None
Senthilkumar 2013 India [19]	M	52	Painless swelling, front of neck progressing slowly	6	CT suggested presence of irregular shaped complex TGDC (6 × 5 cm) with solid and cystic components, fine calcification within the solid areas. Also, mildly enhancing nodule in right lobe and thyroid isthmus with fine calcification	From TGDC suggested PC	---	Sistrunk and total thyroidectomy + central compartment dissection (intra-operative suspicion of paratracheal lymph nodes)	TGDC, thyroid gland	Multifocal PC of thyroid and thyroglossal cyst, no metastasis in level VI nodes	None
Ogawa 2010 [14] Japan	F	61	Mass in anterior neck, gradually enlarged	2	US: lobular solid mass with calcifications (35 × 28 mm), appeared intermixed multi-cystic lesion in contact with hyoid bone. MRI: tumour invasion to hyoid bone and surrounding soft tissue CT: suprahyoid region mass and narrow duct descending from mass to thyroid isthmus	From cystic and solid areas of tumour were positive for PC	No cervical lymphadenopathy	Sistrunk procedure and total thyroidectomy + central compartment dissection	TDR and left thyroid lobe	Thyroid PC (35 × 30 × 30 mm) with cystic lesions, arisen in wall of TDR, tumour invaded hyoid bone and surrounding muscle	None
Lehnerdt 2006 [18] Germany	-	51	Slowly progression of cervical mass in	2–3	US neck scan showed 34 × 32 × 21 mm oval, hypoechoic mass with homogeneous, Evidence of tumorous mass. Skeletal scintigraphy showed no evidence of metastases	---	Intraoperative, 2 metastatic spectra of pre-laryngeal lymph nodes as well as a cranial lobar pyramidalis were shown	total thyroidectomy with a central lymphadenectomy on both sides	TGDC, right thyroid lobe and prelaryngeal LN	Papillary micro-carcinoma 5 mm also found in left thyroid lobe Non-encapsulated papillary microcarcinoma in area of right thyroid lobe (0.2 cm), without involvement of thyroid capsule. Also, micro metastases up to 6 mm diameter in 2 pre-laryngeal LN. Cyst has psammoma bodies, also detected in lymph node metastasis. No psammoma bodies in thyroid	None

^a Due to space considerations, only the first author is cited.

^b Years; C: complication/s; F: female; FNA: fine needle aspiration; I: interval to thyroidectomy; LN: lymph nodes; LNM: Lymph node metastasis; M: male; P: presentation; PC: papillary carcinoma; Post-op: post-operative; S: sex; TDR: thyroglossal duct remnant; TGDC: thyroglossal duct cyst carcinoma; US: ultrasound.

current patient was the youngest in the reported cases of concomitant TGDC carcinoma and thyroid carcinoma. The female gender of our patient also supports the fact that more females are affected with TGDC carcinoma than males [10], and our review (Table 1) illustrates that concomitant papillary carcinoma in TGDC and in the thyroid could be twice more likely among females than males [13,14]. In addition, our patient was from the Philippines, where Filipinos are known to have higher prevalence of thyroid cancers that display more aggressive behaviour [15].

In terms of preoperative work up, the management pathway of TGDC carcinoma varies according to the histopathology. Preoperative evaluation of patients with TGDC should comprise complete physical examination, head and neck examination, and thyroid gland investigations (thyroid function tests, thyroid scan, biopsy). In the current case, there was clinical suspicion of malignancy, and pre-operative imaging could not show invasion of the capsule or adjacent structures (only US neck was done for our case and no other imaging was undertaken e.g. CT neck scan). US is more

sensitive than CT in imaging of the thyroid [16], and CT is reserved for suspected cases of tracheal compression, retrosternal goitre, or mediastinal lymph node metastasis [17]. The US showed, in addition to the suspicious midline complex TGDC, a right thyroid nodule with TIRADS 4. The differential diagnosis of a midline neck swelling includes TGDC, branchial cleft cyst, lipoma, metastatic thyroid carcinoma, dermoid cyst, sebaceous cyst, and enlarged lymph node [4]. The standard policy at our institution is to employ US and ultrasound-guided FNAC, as both together are sufficient to diagnose and plan the surgery for patients with TGDC carcinoma.

CT of the neck is not standard at our institution for uncomplicated cases, and is undertaken in suspected cases as mentioned above. This is in line with the literature, as Table 1 shows that within the published cases, US scan was undertaken for 4 out of the 5 cases including the current case [13,14,18], while CT of the neck was done in a minority (2 out of 5) of cases [14,19]. FNAC or core needle biopsy are safe, well-tolerated, and cost-effective for diagnosing thyroglossal duct lesions and are recommended [11]. We did not undertake core needle biopsy as it is not standard at our institute due to risk of bleeding. Our ultrasound-guided FNAC showed a papillary thyroid carcinoma in the anterior neck mass (TGDC) and confirmed the malignancy.

As for the surgical procedure, surgical excision of the TGDC (Sistrunk's procedure, the standard management comprising the removal of the entire duct and a portion of the hyoid bone) and total thyroidectomy [20]. Intra-operatively, TGDC carcinomas should also be distinguished from papillary carcinoma arising from the tip of the pyramidal lobe. The main difficulty encountered with a TGDC carcinoma is that the diagnosis is usually made intraoperatively or from definitive histopathology [7]. In our case, the thyroid gland and the TGDC were excised en block as one mass (Fig. 3), in line with that Sistrunk's procedure for TGDC carcinoma is curative and with a low recurrence rate in most cases [7]. Some surgeons recommend that total thyroidectomy should be performed in all cases of TGDC carcinoma [7], because of the high incidence of the presence of concomitant thyroid malignancy in the main thyroid gland as a pathophysiology; or to facilitate radioactive iodine therapy and adjuvant treatment therapy [2]. Table 1 shows a case treated by Sistrunk's operation as the primary surgery, and then after the histopathology results, the patient underwent secondary total thyroidectomy [13], compared with the rest of the cases in Table 1 that underwent total thyroidectomy in addition with compartmental dissection [14,18,19]. In our patient, despite her low risk (young patient, no past medical illnesses, no family history), a high measure of care was taken (Sistrunk's operation and total thyroidectomy undertaken together) because of the potential high risk of thyroid malignancy among individuals from the Philippines [15], and the possibility of carcinoma arising in the identified thyroid nodule. Both these considerations justified the added risk of surgery.

Others recommend total thyroidectomy as a routine procedure for TGDC carcinoma [3], although the benefits of this approach are questionable, given the risks associated with total thyroidectomy, including a 1%–2% incidence of recurrent laryngeal nerve injury in redo surgery [3]. Sistrunk's procedure can be performed as a stand-alone procedure in the setting of a clinically and radiologically normal thyroid gland with low-risk patients and low-risk of malignancy tumours, patients < 45 years old, without metastatic spread to lymph nodes, and no exposure to radiation, or concerning radiologic features, and with negative margins [12]. Such patients should not undergo a routine total thyroidectomy following TGDC carcinoma excision [12]. Post-operatively, microscopic examination of our specimen revealed two completely separate carcinomas in the right thyroid nodule and in the TGDC (Fig. 5). The finding of a concomitant primary thyroid cancer, invasion into the cyst wall of the TGDC, and tumours > 1 cm in diameter are indications for total thyroidectomy [21].

Radical neck dissection might add increased morbidity and was not performed in our case, given the lack of evidence of cervical lymph node involvement. Regional lymph node metastases of TGDC carcinoma occurs in only 7.7% of cases, local invasion rarely occurs [22], and the risk of metastasis is < 2% of cases [5]. In support, our patient's US scan showed a nodule in the thyroid with no lymph node involvement, confirming that the management plan being undertaken was the appropriate strategy.

In terms of origin, two theories regarding the origin of TGDC carcinoma have been suggested [23]. The first theory about the origin of TGDC is that it is a primary cancer; while the second suggests a metastasis from a thyroid cancer. Table 1 shows a case [18] where the histopathology found that the TGDC carcinoma had psammoma bodies, which were also detected in the lymph node metastasis, but there was no psammoma bodies in the thyroid carcinoma, suggesting a high likelihood of two different primary tumours. Furthermore, the presence of psammoma bodies in the micro metastases of the pre-laryngeal lymph nodes suggests that TGDC carcinoma was the more likely source [18]. Hence the authors proposed that the TGDC carcinoma had arisen separately and none of the tumours can be considered as metastasis of the other [18]. Table 1 also depicts that none of the other reports we identified in the review of the literature actually investigated this point further in the tumours they encountered.

In relation to our case, based on the histopathology, we speculate that these two carcinomas, the TGDC carcinoma (larger focus, 3 cm in maximum dimension, predominantly papillary morphology, Fig. 5A) and the carcinoma in the right thyroid nodule (smaller focus, 1.5 cm, mixture of papillary and follicular patterns, Fig. 5B) were completely separate tumours, and not an invasion from each other. Normal thyroid tissue was present between the two foci, which along with the different predominant morphological appearance, indicated two separate tumour masses. Characteristic nuclear features (nuclear clearing, nuclear grooves, pseudoinclusions) were present in both tumours.

In terms of follow up, careful long-term follow-up is important as papillary carcinoma is usually a low-grade malignancy and if there are recurrences, then they can be successfully treated with careful patient follow-up using e.g. thyroglobulin as a follow up marker for thyroid cancer in post-operative settings [12]. All patients must have a neck US scan and be re-assessed every 6 months during the first year and then annually thereafter [24]. The benefit of radioactive iodine for low-risk patients remains unclear [2]. Radioactive iodine may be beneficial for patients with larger tumours and metastatic disease, but the increased risk of secondary malignancies in low-risk patients, including children, is questionable, hence careful patient selection for radioactive iodine ablation therapy is necessary [2].

4. Conclusions

Classic papillary carcinoma arising in TGDC, concomitant with another papillary carcinoma arising in the thyroid gland are rare, and are usually diagnosed incidentally following histopathologic analysis of an excised TGDC carcinoma. Papillary thyroid carcinoma accounts for most TGDC carcinomas. All patients should undergo a Sistrunk's procedure for removal of the TGDC carcinoma, with total thyroidectomy for the thyroid nodule. Lateral neck dissection should be performed in patients with positive nodes and may be considered in patients with more aggressive tumour features. Follow-up requires thyroxine replacement therapy to treat hypothyroidism and to suppress TSH in order to prevent recurrence; and neck ultrasound and thyroglobulin tumour marker to detect recurrence if present. Future research could shed more light on whether such cases of carcinoma arising in TGDC concomitant

with another papillary carcinoma arising in the thyroid gland are two separate incidental tumours or otherwise, representing invasion or metastasis. Such deeper understanding is important, as different types of tumours require different treatment plans and post-operative care management. Overall prognosis of papillary thyroid carcinoma is good, with high survival and low recurrence.

Conflicts of interest

Nothing to declare.

Funding

Nothing to declare.

Ethical approval

Approved by Medical Research Center, Hamad Medical Corporation reference number (MRC-04-20-436).

Consent

Written informed consent was obtained from the patient for publication of this case report and accompanying images. A copy of the written consent is available for review by the Editor-in-Chief of this journal on request.

Author contribution

Waleed Mahmoud: data collection, data interpretation, writing the paper. Walid El Ansari: study concept, data interpretation, writing the paper. Abdelrahman Abdelaal: study concept, data interpretation, editing the paper. Mahir Petkar: laboratory and histopathology, data interpretation, editing the paper. Mohamed S. Al Hassan: study concept, data interpretation, editing the paper. All authors read and approved the final version.

Registration of research studies

Not first in Man.

Guarantor

Walid El Ansari.

Provenance and peer review

Not commissioned, externally peer-reviewed.

References

[1] J. Chou, A. Walters, R. Hage, et al., Thyroglossal duct cysts: anatomy, embryology and treatment, *Surg. Radiol. Anat.* 35 (10) (2013) 875–881.

- [2] Y. Carter, N. Yeutter, H. Mazeh, Thyroglossal duct remnant carcinoma: beyond the Sistrunk procedure, *Surg. Oncol.* 23 (3) (2014) 161–166.
- [3] N. Balalaa, M. Megahed, M.A. Ashari, F. Branicki, Thyroglossal duct cyst papillary carcinoma, *Case Rep. Oncol.* 4 (1) (2011) 39–43.
- [4] S. Narayana Moorthy, R. Arcot, Thyroglossal duct cyst-more than just an embryological remnant, *Indian J. Surg.* 73 (1) (2011) 28–31.
- [5] Y.C. Chu, J.Y. Han, H.S. Han, J.M. Kim, S.K. Min, Y.M. Kim, Primary papillary carcinoma arising in a thyroglossal duct cyst, *Yonsei Med. J.* 43 (3) (2002) 381–384.
- [6] S.D. Weiss, C.C. Orlich, Primary papillary carcinoma of a thyroglossal duct cyst: report of a case and literature review, *Br. J. Surg.* 78 (1) (1991) 87–89.
- [7] T. Kandogan, N. Erkan, E. Vardar, Papillary carcinoma arising in a thyroglossal duct cyst with associated microcarcinoma of the thyroid and without cervical lymph node metastasis: a case report, *J. Med. Case Rep.* 2 (2008) 42, <http://dx.doi.org/10.1186/1752-1947-2-42>.
- [8] R.A. Agha, M.R. Borrelli, R. Farwana, K. Koshy, A. Fowler, D.P. Orgill, For the SCARE Group, The SCARE 2018 statement: updating consensus Surgical Case Report (SCARE) guidelines, *Int. J. Surg.* 60 (2018) 132–136.
- [9] S. Wei, V.A. LiVolsi, Z.W. Baloch, Pathology of thyroglossal duct: an institutional experience, *Endocr. Pathol.* 26 (1) (2015) 75–79.
- [10] Y.J. Yang, S. Haghir, J.R. Wanamaker, C.N. Powers, Diagnosis of papillary carcinoma in a thyroglossal duct cyst by fine-needle aspiration biopsy, *Arch. Pathol. Lab. Med.* 124 (1) (2000) 139–142.
- [11] W. Pietruszewska, M. Wągrowaska-Danilewicz, M. Józefowicz-Korczyńska, Papillary carcinoma in thyroglossal duct cyst with uninvolved thyroid. Case report and review of the literature, *Arch. Med. Sci.* 10 (5) (2014) 1061–1065.
- [12] C.P. Plaza, M.E. López, C.E. Carrasco, L.M. Meseguer, L. Perucho Ade, Management of well-differentiated thyroglossal remnant thyroid carcinoma: time to close the debate? Report of five new cases and proposal of a definitive algorithm for treatment, *Ann. Surg. Oncol.* 13 (5) (2006) 745–752.
- [13] C. Srivannitchapoom, P. Sittitrai, K. Yata, P. Khongpiboonkit, Ultrasonographic findings of thyroglossal duct papillary carcinoma A case report, *Int. J. Surg. Case Rep.* 32 (2017) 3254–3257.
- [14] C. Ogawa, M. Kammori, H. Onose, et al., Utilization of three-dimensional computed tomography for papillary thyroid carcinoma arising in the thyroglossal duct remnant: report of a case, *Surg. Today* 40 (7) (2010) 650–653.
- [15] L.H. Kus, M. Shah, S. Eski, P.G. Walfish, J.L. Freeman, Thyroid cancer outcomes in Filipino patients, *Arch. Otolaryngol. Head Neck Surg.* 136 (2010) 138–142.
- [16] J.S. Choi, J. Kim, J.Y. Kwak, M.J. Kim, H.S. Chang, E.K. Kim, Preoperative staging of papillary thyroid carcinoma: comparison of ultrasound imaging and CT, *AJR Am. J. Roentgenol.* 193 (3) (2009) 871–878.
- [17] M.W. van den Brekel, Lymph node metastases: CT and MRI, *Eur. J. Radiol.* 33 (2000) 230–238.
- [18] K.H. Lehnerdt, J. Mehlhorn, H. Nürnberger, T. Deitmer, Simultanes papilläres Schilddrüsenkarzinom in einer medianen Halszyste und Zweitkarzinom der Schilddrüse [Simultaneous papillary carcinoma in a thyroglossal duct remnant and the thyroid gland], *Laryngorhinootologie* 85 (12) (2006) 909–912.
- [19] R. Senthilkumar, J.F. Neville, R. Aravind, Malignant thyroglossal duct cyst with synchronous occult thyroid gland papillary carcinoma, *Indian J. Endocrinol. Metab.* 17 (5) (2013) 936–938.
- [20] W.E. Sistrunk, The surgical treatment of cysts of the thyroglossal tract, *Ann. Surg.* 71 (2) (1920) 121–122, 2.
- [21] D. Dan, R. Rambally, V. Naraynsingh, et al., A case of malignancy in a thyroglossal duct cyst – recommendations for management, *J. Med. Assoc.* 104 (3,4) (2012), 211–214 L.
- [22] H. Aghaghazvini, Mazaher, H. Sharifian, S. Aghaghazvini, M. Assadi, Invasive thyroglossal duct cyst papillary carcinoma: a case report, *J. Med. Case Rep.* 3 (2009) 9308.
- [23] V.I. Forest, R. Murali, J.R. Clark, Thyroglossal duct cyst carcinoma: case series, *J. Otolaryngol. Head Neck Surg.* 40 (2) (2011) 151–156.
- [24] A. Chala, A. Álvarez, A. Sanabria, A. Gaitán, Primary papillary carcinoma in thyroglossal cysts. Case reports and literature review, *Acta Otorrinolaringol. Esp.* 67 (2) (2016) 102–106.

Open Access

This article is published Open Access at [sciencedirect.com](https://www.sciencedirect.com). It is distributed under the [IJSCR Supplemental terms and conditions](#), which permits unrestricted non commercial use, distribution, and reproduction in any medium, provided the original authors and source are credited.