

# Infiltrating angioliipoma of the lower lip: A case report and literature review

YUICHI OHNISHI, MASAHIRO WATANABE, TOMOKO FUJII,  
HIROKI YASUI, HIROHITO KUBO and KENJI KAKUDO

Second Department of Oral and Maxillofacial Surgery, Osaka Dental University, Chuo-ku, Osaka 540-0008, Japan

Received February 14, 2014; Accepted September 8, 2014

DOI: 10.3892/ol.2014.2737

**Abstract.** Infiltrating angioliipoma (IAL) is a rare lesion and is a clinicopathological variant of angioliipoma. IAL occurs most commonly in the trunk and extremities, it is rarely found in the head and neck regions and extremely rare in the oral cavity. This study presents the case of a 74-year-old female with IAL of the lower lip. To the best of our knowledge, this is the first case of IAL arising in the lower lip to be reported. Microscopically, IAL was unencapsulated and mature lipocytes were separated by a branching network of proliferating small vessels that infiltrated the adjacent tissues. Therefore, complete excision was difficult to perform. Magnetic resonance imaging has been reported to be valuable in determining the extent of the tumor and asserting a preoperative diagnosis. According to previous studies, the recurrence rate of IAL following surgical extirpation is 35-50%. Furthermore, the levels of mRNA expression of the vascular endothelial growth factor (VEGF) family members in the tumor were investigated. VEGF-A and -B expression were detected, however, VEGF-C and -D were expressed at extremely low levels. Excisional biopsy was performed under local anesthesia. During four years of follow-up, no evidence of tumor recurrence had been identified. An operating microscope may be utilized for the total removal of an IAL to minimize damage to normal tissues. This report indicates that mast cell-derived VEGF may be responsible for the enhanced vascularity in the tumor. We would therefore consider careful extirpation with no wide safety margin to be the procedure of choice, except when the tumor invades irregularly into the muscles.

## Introduction

Benign lipomatous tumors are classified into five types, lipoma, variants of lipoma, heterotopic lipomas, hamartomatous

lesions, infiltrating or diffuse neoplastic or non-neoplastic proliferations of mature fat and hibernoma. Angioliipoma is a variant of lipoma (1). Infiltrating angioliipoma (IAL) is a rare lesion, and is a clinicopathological variant of angioliipoma, characterized by infiltration of the surrounding structures, particularly skeletal muscle. Angioliipoma accounts for 5-17% of all lipomas and predominantly presents as subcutaneous nodules in young adults, which are tender or painful on palpation, particularly during the initial growth period. Angioliipoma exists in two forms, circumscribed and diffuse. Diffuse tumors are considered to be IAL with infiltration of the surrounding muscles. IAL has a high risk of recurrence following surgical excision. Furthermore, IAL may behave in a similar manner to that of a local aggressive neoplasm. In 1966, the tumor was characterized as a clinicopathological entity by Gonzalez-Crussi *et al* (2), who reviewed the previous literature and identified cases which were consistent with this diagnosis.

According to the English literature, the tumor rarely occurs in the head and neck and is extremely rare in the oral cavity (3). Wide resection is recommended for the treatment of infiltrating angioliipomas, due to the risk of recurrence (4). The current study reports the case of a 74-year-old female with IAL of the lower lip. Following the surgical excision of the tumor, the mRNA expression levels of the vascular endothelial growth factor (VEGF) family members in the tumor were investigated. To the best of our knowledge, this is the first case of IAL arising in the lower lip to be reported. Written informed consent was obtained from the patient's family.

## Case report

**Patient and case history.** In April 2000, a 74-year-old female was referred to the Second Department of Oral and Maxillofacial Surgery, Osaka Dental University (Osaka, Japan) with a painless mass in the lower lip, which had been present for approximately four months. The patient had no history of facial trauma. Clinical examination revealed a relatively circumscribed soft-tissue mass of 20x19 mm in diameter in the lower lip (Fig. 1). The overlying mucosa was intact. Hematological and biochemical parameters were within the normal limits. White blood cell count,  $68.6 \times 10^2/\mu\text{l}$  (normal range,  $35.8-80.0 \times 10^2/\mu\text{l}$ ); red blood cell count,  $483 \times 10^4/\mu\text{l}$  (normal range,  $380-480 \times 10^4/\mu\text{l}$ ); hemoglobin level, 15.2 g/dl

---

*Correspondence to:* Dr Yuichi Ohnishi, Second Department of Oral and Maxillofacial Surgery, Osaka Dental University, 1-5-17 Otemae, Chuo-ku, Osaka 540-0008, Japan  
E-mail: ohnishi@cc.osaka-dent.ac.jp

**Key words:** angioliipoma, lip, vascular endothelial growth factor

Table I. PCR primers sequences used for reverse-transcription-PCR.

Gene	Product size, bp	Primer sequence
VEGF-A	212	5'-GCAGAATCATCACGAAGTGG-3' 5'-GCATGGTGATGTTGGACTCC-3'
VEGF-B	246	5'-CCTTGACTGTGGAGCTCATG-3' 5'-TGTCTGGCTTCACAGCACTG-3'
VEGF-C	435	5'-AGACTCAATGCATGCCACG-3' 5'-TTGAGTCATCTCCAGCATCC-3'
VEGF-D	313	5'-GCTGTTGCAATGAAGAGAGC-3' 5'-TCTTCTGTTCCAGCAAGTGG-3'
$\beta$ -actin	610	5'-TGACGGGGTCACCCACACTGTGCCCATCTA-3' 5'-CTAGAAGCATTGCGGTGGACGATGGAGGG-3'

PCR, polymerase chain reaction; bp, base pairs; VEGF, vascular endothelial growth factor.

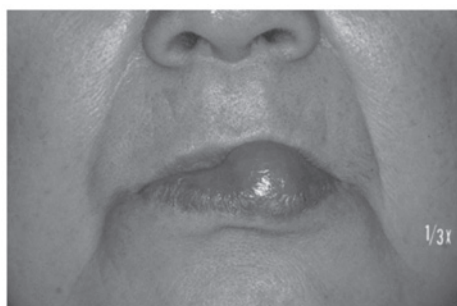

Figure 1. Image of patient captured at initial presentation showing a semi-firm painless mass in the lower lip.

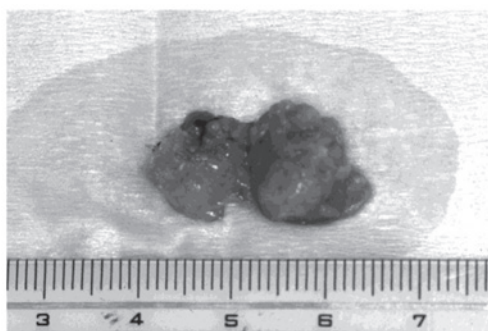


Figure 2. Macroscopic aspect of the cutting surface of the surgical specimen.

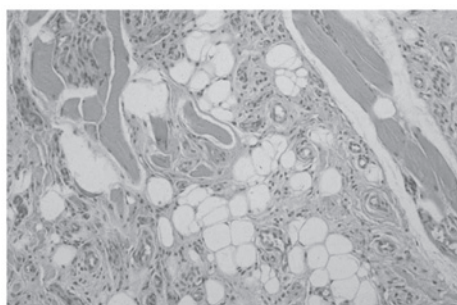


Figure 3. Photomicrograph shows mature lipocytes and blood vessels infiltrating cross-striated muscle fibers (hematoxylin-eosin stain, original magnification x100).

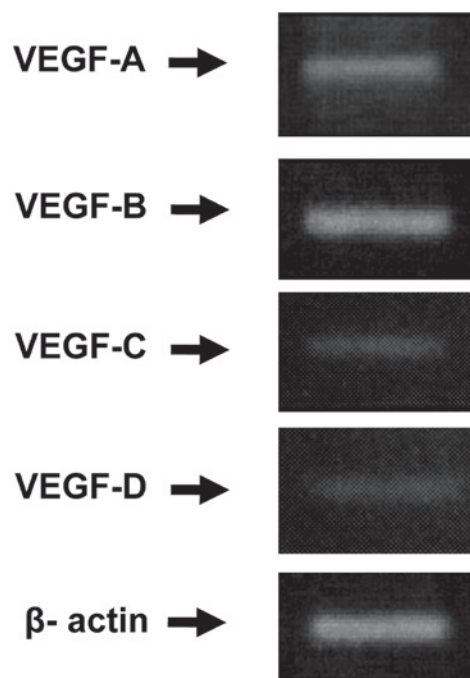


Figure 4. Reverse transcription-polymerase chain reaction analysis of the VEGF family members in the tumor. VEGF, vascular endothelial growth factor.

(normal range, 11.3-15.2 g/dl); hematocrit level, 44.0% (normal range, 34.0-43.0%); platelet count,  $23.4 \times 10^4/\mu\text{l}$  (normal range,  $15.0-35.0 \times 10^4/\mu\text{l}$ ); glutamic oxaloacetic transaminase level, 22 U/l (normal range, 7-38 U/l); glutamic pyruvic transaminase level, 30 U/l (normal range, 4-44 U/l);  $\gamma$ -glutamyl transpeptidase, 30 U/l (normal range 9-35 U/l); creatine phosphokinase, 96 U/l (normal range, 32-187 U/l); blood urea nitrogen level, 17.5 mg/dl (normal range, 8.0-20.0 mg/dl); creatinine level, 0.51 mg/dl (normal range, 0.44-0.75 mg/dl); c-reactive protein level, 0.06 mg/dl (normal range, 0.00-0.30 mg/dl). A diagnosis of a benign tumor was determined preoperatively. Ultrasound examination was performed, however, detailed information could not be obtained due to the size of the tumor. Subsequently, an excisional biopsy was performed under local anesthesia. As

Table II. Infiltrating angiolipoma of the oral cavity.

Authors (ref)	Age, years	Gender	Location	Size, cm
Lin <i>et al</i> (10)	49	Male	Tongue	3.0x2.0x2.5
Sugiura <i>et al</i> (11)	74	Male	Mucolabial fold	1.0x1.0x2.0
Dalambiris <i>et al</i> (3)	56	Female	Upper labial	1.0x1.2x0.5
Present case	74	Female	Lower lip	2.0x1.9x1.0

the tumor was unencapsulated, the normal tissue surrounding the tumor was extirpated. The excised specimen revealed a solid soft-tissue mass (20x19x10 mm) with a dark yellow surface (Fig. 2).

Microscopically, the specimen was unencapsulated and mature lipocytes were separated by a branching network of proliferating small vessels that infiltrated the adjacent tissues, and muscle fibers partially existed in the tumor. It was composed of proliferating mature lipocytes and numerous small blood vessels containing microthrombi under the epithelium (Fig. 3). Cellular atypia was not observed, therefore, the pathological diagnosis of this lesion was IAL arising in the lower lip. No evidence of recurrence has been identified during four years of follow up.

The expression of mRNA of all VEGF family members was detected in the tumor by reverse transcription (RT)-polymerase chain reaction (PCR) analysis, as shown in Fig. 4. However, the relative expression level of each of the VEGF family members differed significantly. A higher relative expression level of VEGF-A and -B were observed, when compared with VEGF-C and -D, which exhibited extremely low expression levels.

**RNA preparation and RT-PCR.** Total RNA was isolated from the tissues of the patient using TRIZOL reagent (Invitrogen Life Technologies, Inc., Carlsbad, CA, USA), immediately after resection, according to the manufacturer's instructions. A total of 10  $\mu$ l RT buffer (3 mM MgCl<sub>2</sub>, 10 mM Tris-HCl, 75 mM KCl, 1 mM bovine serum albumin; pH 8.3) containing 1  $\mu$ g RNA, 0.2  $\mu$ g oligo-dT primers, 0.5 mM dNTP, 5 U of RNasin and 100 U of Moloney murine leukemia virus reverse transcriptase (Invitrogen Life Technologies, Inc.) was incubated at 37°C for 60 min and a section of each RT product was amplified by PCR, using a thermo cycler (Takara PCR Thermal Cycler Dice Gradient TP600; Takara Bio, Inc., Otsu, Japan).

The size and sequences of the primers used are shown in Table I. The PCR reactions conditions were as follows: 40 cycles of denaturation at 94°C for 1 min, annealing at 52°C for 2 min, and chain extension with Taq polymerase (Invitrogen Life Technologies, Inc.) at 72°C for 1 min, followed by a final extension step at 72°C for 20 min. Following amplification, the PCR reaction mixture was analyzed by 2% agarose gel electrophoresis and stained with ethidium bromide (Invitrogen Life Technologies, Inc.).

## Discussion

Infiltrating lipoma is a rare variant of lipoma. In 1853, Paget reported the case of a lipoma that infiltrated the trapezius

muscle (2). In 1946, Regan *et al* (5) reviewed several cases and defined this entity. The tumor is most commonly identified in the deep muscles of the buttock, shoulder, thigh and extremities (6). Clinically, oral infiltrating lipoma presents as a painless solitary submucosal swelling. On palpation, the tumor is semi-firm and rubbery, with poorly defined margins. It is usually identified in the deeper tissues. Dionne and Seemayer (7) reviewed 20 patients with infiltrating lipoma and observed a recurrence rate of 62.5%.

Angiolipoma accounts for 5-17% of all lipomas and predominantly presents as subcutaneous nodules in young adults, which are tender or painful on palpation, particularly during the initial growth period (8). Microscopically, the tumor presents as yellow nodules, which consist of mature fat cells separated by a branching network of small vessels. The proportion of fatty tissue and vascular channels varies (9). The vessels commonly contain fibrin thrombi, without evidence of necrosis due to the extensive collateral circulation (8). Angiolipoma exists in two forms, circumscribed and diffuse. The circumscribed variants, with a few exceptions, are limited to the subcutis. Diffuse angiolipoma arises in the deep soft tissues and infiltrates adjacent structures and thus, complete excision is difficult (8). In the present case, the tumor was considered to be IAL and may be termed intramuscular angiolipoma, with infiltration of the surrounding muscles.

IAL occurs most commonly in the trunk and extremities (7-9), however, it is extremely rare in the oral cavity. To the best of our knowledge, only four cases of IAL of the oral cavity, including our case, have been reported in the English literature (Table II). The first and second cases of oral IAL were found in the tongue of a 49-year-old male (10) and the mucolabial fold of a 74-year-old male, respectively (11).

Lipoma is usually well encapsulated with a smooth or lobulated surface and thus, it may be resected easily, however, IAL is not encapsulated and complete excision is difficult due to the infiltration of the surrounding tissues, particularly the muscle. The recurrence rate of the tumor following surgical extirpation is 35-50% (7). The probable causes of recurrence are inaccurate preoperative estimation of the extent of the tumor and the obscure demarcation encountered during surgery (8,12). In order to clarify the extent of tumor demarcation, ultrasound provides information regarding the extent of the tumor and the infiltration of other anatomical structures. In the present case, the tumor could not be differentiated from the muscle by ultrasound. Angiography may provide more detailed information with regard to association between the vascular supply and the major vessels (13). However, magnetic resonance imaging has been reported to be more valuable than angiography or computed tomography

in determining the extent of the tumor and asserting a preoperative diagnosis (12). Wide excision of the tumor has been previously reported, however, this often results in significant morbidity (14). Ida-Yonemochi *et al* (15) hypothesized that an operating microscope may be utilized for total removal of an IAL in order to minimize damage to the normal tissues during total extirpation of cerebral arteriovenous malformations (12). In the present study, the tumor was unencapsulated and infiltrated the muscle of the lower lip and thus, the tumor was extirpated carefully, including the normal tissue surrounding the tumor. A number of studies have reported the use of radiotherapy for the treatment recurrences (2,9,16). In this case, the tumor was completely excised and therefore, no further treatment was required and no recurrence was observed during the four years of postoperative follow up.

Matsuoka *et al* (12) revealed that mast cells surrounding blood vessels expressed high levels of VEGF, which is known to be an essential growth factor for endothelial cells in vasculogenesis. This result indicates that mast cell-derived VEGF may be responsible for the enhanced vascularity observed in this tumor. In the present case, VEGF-A and -B, which are known to stimulate the formation of blood vessels in tumors, were expressed. However, VEGF-C and -D, which may promote the development of lymphatic vessels in tumors and entry of tumor cells into lymphatic vessels, were expressed at extremely low levels. We hypothesize that VEGF-C and -D expression was low due to the benign nature of the tumor.

Ida-Yonemochi *et al* (15) demonstrated that mast cells surrounding blood vessels strongly expressed VEGF, which is known to be an essential growth factor for endothelial cells in vasculogenesis. Although *in situ* hybridization was not performed in the present study, VEGF production by mast cells is highly probable as there were no other inflammatory cells within the tumor tissue. These result indicates that mast cell-derived VEGF may be responsible for the enhanced vascularity of this tumor. Therefore, we believe that IAL is associated with fat, rather than with neoplasm. We therefore recommend careful extirpation with no wide safety margin to be the procedure of choice, except in those cases where the tumor has invaded irregularly into the muscles.

In conclusion, cases of infiltrating angioliipoma of the oral cavity are extremely rare. Magnetic resonance imaging has been reported to be valuable in determining the extent of the tumor

and asserting a preoperative diagnosis. Histopathology showing mature fat cells and numerous capillaries invading surrounding structure may verify the diagnosis. We consider careful extirpation with no wide safety margin to be the procedure of choice, with the exception of cases where the tumor invades irregularly into the muscles.

## References

1. Weiss SW and Goldblum JR (eds): Benign lipomatous tumors. In: Enzinger and Weiss's Soft Tissue Tumors, 4th edition. Mosby, St Louis, MO, pp571-639, 2001.
2. Gozalez-Crussi F, Enneking WF and Aream VM: Infiltrating angioliipoma. J Bone Joint Surg 48: 1111-1124, 1966.
3. Dalambiras S, Tilaveridis I, Iordanidis S, Zaraboukas T and Epivatianos A: Infiltrating angioliipoma of the oral cavity: report of a case and literature review. J Oral Maxillofac Surg 68: 681-683, 2010.
4. Hamakawa H, Hino H, Sumida T and Tanioka H: Infiltrating angioliipoma of the cheek: a case report and a review of the literature. J Oral Maxillofac Surg 58: 674-677, 2000.
5. Regan JM, Bickel WH and Brodes AC: Infiltrating lipomas of the extremities. Surg Gynecol Obstet 54: 87, 1946.
6. Kindblom LG, Angervall L, Stener B and Wickbom I: Intermuscular and intramuscular lipomas and hidradenomas: A clinical, roentgenologic, histologic and prognostic study of 46 cases. Cancer 33: 754-762, 1974.
7. Dionne GP and Seemayer TA: Infiltrating lipomas and angioliipomas revisited. Cancer 33: 732-738, 1974.
8. Lin JJ and Lin F: Two entities in angioliipoma: A study of 459 cases of lipoma with review of literature on infiltrating angioliipoma. Cancer 34: 720-727, 1974.
9. Enzinger FM and Weiss SW: Soft Tissue Tumors. St Louis, MO, Mosby 301-345, 1988.
10. Lin SC, Wang TY and Hahn LJ: Angioliipoma of the tongue: Report of a case. Ann Dent 48: 37-38, 1989.
11. Sugiura J, Fujiwara K, Kurahashi I and Kimura Y: Infiltrating angioliipoma of the mucolabial fold: A case report and review of the literature. J Oral Maxillofac Surg 57: 446-448, 1999.
12. Matsuoka Y, Kurose K, Nakagawa O and Katsuyama J: Magnetic resonance imaging of infiltrating angioliipoma of the neck. Surg Neurol 29: 62-66, 1988.
13. Chew FS, Hudson TM and Hawkins IF: Radiology of infiltrating angioliipoma. AJR Am J Roentgenol 135: 781-787, 1980.
14. Austin RM, Mack GR, Townsend CM and Lack EE: Infiltrating (intramuscular) lipoma and angioliipomas. A clinicopathologic study of six cases. Arch Surg 115: 281-284, 1980.
15. Ida-Yonemochi H, Swelam W, Saito C and Saku T: Angioliipoma of the buccal mucosa: a possible role of mast cell-derived VEGF in its enhanced vascularity. J Oral Pathol Med 34: 59-61, 2005.
16. Stimpson N: Infiltrating angioliipoma of skeletal muscle. Br J Surg 58: 464-466, 1971.