

# Gastric Necrosis because of Ingestion of Calcium Chloride

Yoichi Nakagawa, MBBS<sup>1</sup>, Atsuyuki Maeda, MD, PhD<sup>2</sup>, Takamasa Takahashi, MD, PhD<sup>2</sup>, and Yuji Kaneoka, MD, PhD<sup>2</sup>

<sup>1</sup>Department of Pediatric Surgery, Ogaki Municipal Hospital, Ogaki City, Gifu Pref, Japan

<sup>2</sup>Department of Surgery, Ogaki Municipal Hospital, Ogaki City, Gifu Pref, Japan

## ABSTRACT

Calcium chloride is a relatively harmless chemical that is frequently used as a dehumidifying agent. However, there have been rare reports that the accidental ingestion of this substance can cause gastric necrosis. We describe such a case of gastric necrosis in a 66-year-old woman who had accidentally ingested calcium chloride. Our findings indicate that the gastric necrosis in this patient was probably attributable to heat generated by the calcium chloride solution in the stomach. When ingested in large amounts, calcium chloride thus has the potential to cause gastric necrosis.

## INTRODUCTION

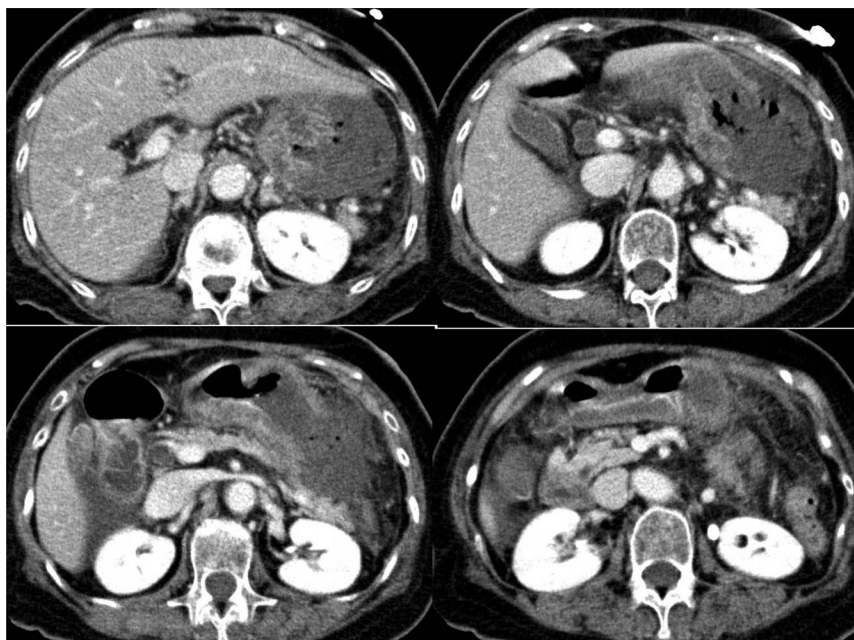
Calcium chloride is widely used for a range of different purposes, including as a freezing point depressor, in road surfacing, and as a dehumidifying agent, and is generally considered to be relatively harmless. However, it has been reported, albeit rarely, that calcium chloride can cause skin and soft-tissue necrosis.<sup>1-3</sup> We report a case of gastric necrosis caused by the ingestion of calcium chloride.

## CASE REPORT

A 66-year-old woman from Japan presented with symptoms of vomiting and abdominal pain, followed by disturbance of consciousness. She had a history of hypertension and early Alzheimer disease, and frequently experiences difficulty in communicating. Physical examination revealed that the patient was of average build and was a well-nourished woman who had right upper quadrant severe tenderness without rigidity and muscular defense. She was somnolent with a Glasgow Coma Scale score of 11, temperature of 37.1°C, heart rate of 90 bpm, and blood pressure of 184/122 mm Hg. Laboratory examination of the patient's blood indicated hypercalcemia, hyperlactacidemia, nonanion gap metabolic acidosis, and elevated acute inflammatory markers. The patient was hospitalized for hypercalcemia and disturbance of consciousness and received intravenous saline, furosemide, and 3 g of intravenous sulbactam/ampicillin twice daily.

According to the information provided by the patient's family on day 2 of admission, the woman had accidentally ingested a dehumidifying agent composed mainly of calcium chloride, approximately 18 hours before the time of hospital presentation. Although she had complained of vomiting and diarrhea several hours after ingestion, her family decided not to take any immediate action and instead waited to see whether her condition would improve. However, the following morning she was found unconscious and was brought to the hospital. She was diagnosed with hypercalcemia caused by the calcium chloride, the amount of which ingested was estimated to be approximately 70 g. After receiving treatment with the intravenous fluids (3,500 mL saline and 500 mL lactated Ringer solution on day 1 of admission and 2000 mL saline and 1,000 mL half normal saline on day 2 of admission), the albumin-adjusted calcium level was corrected to be 11 mg/dL. Nevertheless, the disturbance of consciousness and mild tenderness in the epigastric region persisted.

On day 3 of admission, a physical examination indicated epigastric tenderness with mild rebound tenderness, and a contrast-enhanced computed tomography scan revealed a hypoenhanced lesion along the greater curvature of the stomach (Figure 1). Because



**Figure 1.** A contrast-enhanced computed tomography scan showing a hypoenhanced lesion along the greater curvature of the stomach.

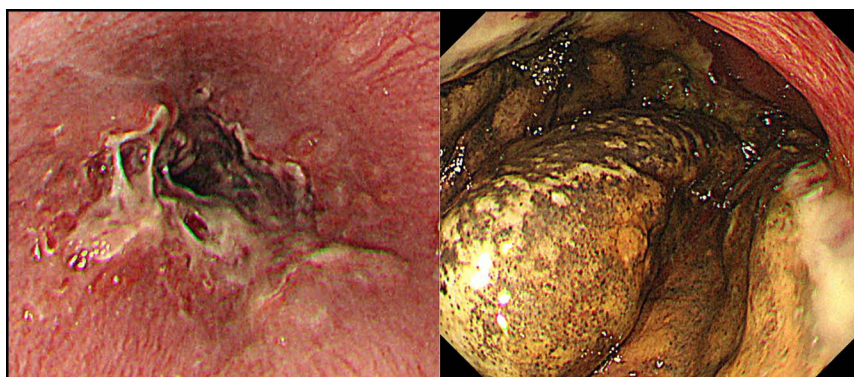
gastric necrosis was suspected, upper gastrointestinal endoscopy was performed and disclosed mucosal injury in the lower esophagus and black discoloration of the mucosa along the greater curvature of the stomach, with a normal duodenal mucosa (Figure 2). Thus, necrosis of the stomach caused by calcium chloride with peritonitis was suspected, and an emergency laparotomy was performed. The surgical findings included necrosis of the serosa along the greater curvature of the stomach from the fundus to the lower body of the stomach and an extremely edematous gastric wall, although no perforation was detected. Gastric necrosis was diagnosed, and a total gastrectomy with a resection of 5 cm of the lower esophagus was performed. On postoperative day 1, the patient's level of consciousness was found to have returned to normal, and thus, the disturbance of consciousness was assumed to be associated with hypercalcemia and abdominal pain. She received 1 g of cefmetazole sodium twice daily for 3 days after surgery, started total parental nutrition on postoperative day 2, and resumed

consumption of a normal diet on postoperative day 5. Thereafter, the postoperative course was uneventful, and the patient was discharged on postoperative day 19.

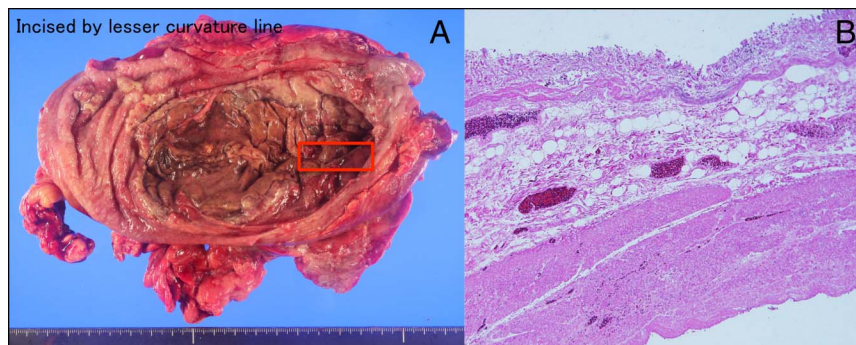
The pathological results were consistent with corrosive gastritis, with full-thickness necrosis of the stomach caused by calcium chloride (Figure 3). Given that the pathological results showed full-thickness coagulation necrosis of the stomach with low neutrophil infiltration, it was concluded that the gastric necrosis was probably caused by heat generated by the calcium chloride solution, rather than by direct contact with the substance per se.

## DISCUSSION

Calcium chloride is a water-soluble compound, the aqueous solutions of which are neutral with generally low toxicity. Although considered relatively harmless, the lethal dose of calcium chloride in humans is unclear. Nevertheless, intoxication caused



**Figure 2.** An upper gastrointestinal endoscopic image showing mucosal injury to the lower esophagus and greater curvature of the stomach. The necrotic area appears to have a liquid-like surface.



**Figure 3.** Image and stained section of the necrotic area of the stomach of a woman who had ingested approximately 70 g of calcium chloride. (A) Gross appearance of a specimen resected from the stomach. Although the gastric mucosa is burned and necrotic, the gastric folds are preserved. (B) Hematoxylin and eosin-stained section of the necrotic area in the stomach. There is full-thickness coagulation necrosis of the stomach with vascular thrombosis and low neutrophil infiltration.

by calcium chloride can cause hypercalcemia and metabolic acidosis, which may result in nausea, vomiting, diarrhea, and arrhythmia.<sup>4-6</sup> Although gastrointestinal necrosis caused by ingestion of calcium chloride has rarely been reported, skin and soft tissue necrosis caused by calcium chloride have been observed more frequently.<sup>1-3</sup> Soft-tissue necrosis is considered to be due to direct contact with calcium chloride or extravasation during intravenous administration of this compound. The ingestion of calcium chloride is relatively rare because of its unpleasant taste, and to our knowledge, gastric necrosis caused by its ingestion has only been reported only on a single occasion. Consistent with the findings of this study, Padmanabhan et al have reported that the ingestion of calcium chloride results in necrosis of the stomach via an exothermic reaction and hypercalcemia.<sup>7</sup> Although the mechanisms whereby calcium chloride causes gastrointestinal necrosis have yet to be determined, heat, direct contact, and dehydration are believed to be involved.

The patient reported ingestion of approximately 70 g of solid-state calcium chloride, and we speculate that the gastric necrosis detected in this patient could be accounted for by the following considerations. Given that 1 g of calcium chloride produces 68 calories of heat.<sup>8</sup> Seventy gram would have produced 4,760 calories. Furthermore, if we assume that the volume of the stomach contents is 50 mL and radiant heat is not considered, the temperature of gastric fluids could theoretically have risen by approximately 95°C. However, because the rate of calcium chloride dissolution is relative slow, the dissolution and radiant heat is present; this would tend to prevent such an excessive increase in temperature. Nevertheless, there would still be a moderate increase in temperature, which could be associated with symptoms such as gastric necrosis. Moreover, the heat thus generated could promote pyloroantral motility dysfunction and prolong gastric emptying time and thus increase the probability of mucosal injury caused by direct chemical contact.<sup>9</sup> In this regard, Falk et al discovered that local heat initially destroys smaller capillaries and, ultimately, the destruction of larger blood vessels in the stomach of animal models.<sup>10</sup> Moreover, the absorption of moisture and an increase in osmotic pressure can lead to

dehydration of the stomach tissue, thereby contributing to the production of cytotoxic effect. In summary, mucosal injury is considered to occur because of heat generated by calcium chloride solution in the stomach and dehydration of the stomach tissue, which is consistent with our pathological results. The fact that the esophagus remained unaffected by the consumption of calcium chloride is assumed to be attributable to the rapid passage through the esophagus, which would have allowed insufficient time for injury to the esophageal mucosa.

Upper endoscopy is a useful technique for determining the severity and treatment of corrosive gastritis, and Di Costanzo et al have reported that the findings of upper endoscopy can be used to classify the severity of the corrosive burns and predicted the risk of stenosis.<sup>11</sup> They found that mucosal burns with multiple ulcerations, extensive necrosis involving the entire esophagus and/or stomach, and massive hemorrhage are risks for stenosis. In this case, imaging studies and physical examination revealed gastric necrosis with peritonitis, and hence, emergency laparotomy was performed.

In summary, we investigated a case of gastric necrosis caused by the accidental ingestion of calcium chloride. Our findings indicate that the gastric necrosis was probably caused by the heat generated by calcium chloride solution in the stomach. Ingestion of large amounts of calcium chloride may thus cause gastric necrosis, which is a life-threatening condition.

## DISCLOSURES

**Author contributions:** All authors contributed equally to this manuscript. Y. Nakagawa is the article guarantor.

**Financial disclosure:** None to report.

**Previous presentation:** This case was presented at the Tokai Geka Gakkai; October 13, 2019; Gifu, Japan.

**Informed consent** was obtained for this case report.

Received January 31, 2020; Accepted June 8, 2020

## REFERENCES

1. Lin CY, Hsieh KC, Yeh MC, et al. Skin necrosis after intravenous calcium chloride administration as a complication of parathyroidectomy for secondary hyperparathyroidism: Report of four cases. *Surg Today*. 2007;37:778–81.
2. Yosowitz P, Ekland DA, Shaw RC, et al. Peripheral intravenous infiltration necrosis. *Ann Surg*. 1975;182:553–6.
3. Kim MP, Raho VJ, Mak J, et al. Skin and soft tissue necrosis from calcium chloride in a deicer. *J Emerg Med*. 2007;32:41–4.
4. Fauci AS, Braunwald E, Kasper DL, et al. *Harrison's Principles of Internal Medicine*. 17th edn, McGraw-Hill Professional: New York, 2008, pp 2382.
5. Slattery A, King WD, Nichols M, et al. Hypercalcemia following Damp-rid™ ingestion. *Clin Toxicol*. 1995;33:487.
6. Kronenberg H. In: Melmed S, Polonsky K, Larsen PR, (eds). *Williams Textbook of Endocrinology*. 11th edn, Saunders Elsevier: Philadelphia, PA, 2008, p 1240.
7. Padmanabhan P, Spiller HA, Bosse GM. A case of hypercalcemia and gastric necrosis from hot pack ingestion. *J Med Toxicol*. 2010;6:139–42.
8. Macintyre JE. *Dictionary of Inorganic Compounds*. CRC Press: Boca Raton, FL, 1992.
9. Sun WM, Penagini R, Hebbard G, et al. Effect of drink temperature on antropyloroduodenal motility and gastric electrical activity in humans. *Gut*. 1995;37:329–34.
10. Falk P. The effect of elevated temperature on the vasculature of mouse jejunum. *Br J Radiol*. 1983;56:41–9.
11. Di Costanzo J, Noirclerc M, Jouglard J, et al. New therapeutic approach to corrosive burns of the upper gastrointestinal tract. *Gut*. 1980;21(5): 370–5.

---

**Copyright:** © 2020 The Author(s). Published by Wolters Kluwer Health, Inc. on behalf of The American College of Gastroenterology. This is an open-access article distributed under the terms of the Creative Commons Attribution-Non Commercial-No Derivatives License 4.0 (CCBY-NC-ND), where it is permissible to download and share the work provided it is properly cited. The work cannot be changed in any way or used commercially without permission from the journal.