

## Case Report

# Choriocarcinoma in Post-Menopausal Women- 3 Case Reports with Review of Literature

Upasana Baruah, Roma Jethani, Debabrata Barmon, Dimpy Begum, Haelom Liegise, Megha Nandwani

Department of Gynecological Oncology, Dr. B. Borooah Cancer Institute, Guwahati, Assam, India

### ABSTRACT

Gestational trophoblastic neoplasia is of uncommon occurrence in postmenopausal women, unlike in the reproductive age group. The diagnosis is based on levels of beta-human chorionic gonadotropin (hCG) in serum. The management is similar to that in premenopausal women. First case, fifty-two-year-old, P8 L4A3 postmenopausal female, presented with postmenopausal bleeding. Diagnosis of choriocarcinoma was made in view of raised serum beta-hCG levels with uterine lesion with lung metastasis. The patient started on Multi-agent chemotherapy. The patient succumbed to death due to Grade III hematological toxicity while on the first cycle of the EMA/CO regimen. Second case, forty-two-year-old, P2 L2, postmenopausal, with a history of Choriocarcinoma 20 years, back presented with postmenopausal bleeding. After metastatic workup, the patient started on EMACO regimen. She is asymptomatic and on regular follow-up after 8 cycles of chemotherapy. Third case, forty-seven-year-old, P4 L4, postmenopausal, presented with histopathology report suggestive of choriocarcinoma after hysterectomy. After evaluation, lung metastasis was detected. The patient responded to eight cycles to Multi-agent chemotherapy and is on regular follow-up. Choriocarcinoma is a rare gynecological malignancy in postmenopausal women. High index of suspicion is required for its diagnosis. The prognosis of the disease is not encouraging as compared to the premenopausal woman

**KEYWORDS:** Choriocarcinoma, gestational trophoblastic neoplasia, postmenopausal

**Submitted:** 08-Mar-2021

**Revised:** 16-Nov-2021

**Accepted:** 06-Dec-2021

**Published:** 20-Jan-2022

## INTRODUCTION

Gestational Trophoblastic Disease (GTD), developing due to abnormal proliferation of trophoblastic tissue, is a common condition seen in reproductive-age women. It encompasses two distinct entities: Benign and malignant. Benign includes complete and partial mole whereas malignant counterpart includes Gestational Trophoblastic Neoplasm which in turn has 4 variants namely Choriocarcinoma, Invasive mole, Placental Site Trophoblastic Tumor/Epithelioid Trophoblastic Tumor. The incidence of Choriocarcinoma varies in different geographic areas because of racial/nutritional/hormonal differences. Histo-pathological diagnosis is not available in most of the cases and an elevated or persistence of high beta-human chorionic gonadotropin (hCG) is the key to diagnosis. The presence of metastatic disease further supports the diagnosis of choriocarcinoma. High incidence

of metastasis with an excellent response to chemotherapy are its two unique features. The occurrence of Gestational Trophoblastic Neoplasia in postmenopausal women is rare. We are reporting three cases of Choriocarcinoma in Postmenopausal women along with the review of literature. The rare occurrence and poor prognosis make the diagnosis and management challenging.

## CASE REPORT

### Case 1

A 52-year-old, P8 L4A3 postmenopausal female presented chief complaints of pain abdomen and

**Address for correspondence:** Dr. Roma Jethani, C/O Mr Prakash Jethani, St No. 2, Ravigram, Telibandha, Raipur - 492 001, Chhattisgarh, India. E-mail: romajethani18@gmail.com

This is an open access journal, and articles are distributed under the terms of the Creative Commons Attribution-NonCommercial-ShareAlike 4.0 License, which allows others to remix, tweak, and build upon the work non-commercially, as long as appropriate credit is given and the new creations are licensed under the identical terms.

**For reprints contact:** WKHLRPMedknow\_reprints@wolterskluwer.com

**How to cite this article:** Baruah U, Jethani R, Barmon D, Begum D, Liegise H, Nandwani M. Choriocarcinoma in post-menopausal women- 3 case reports with review of literature. J Mid-life Health 2021;12:319-22.

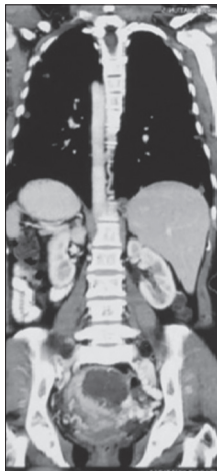
Access this article online	
<b>Quick Response Code:</b> 	<b>Website:</b> www.jmidlifehealth.org
	<b>DOI:</b> 10.4103/jmh.jmh_38_21

postmenopausal bleeding for 1.5 months associated with decreased appetite. The patient had her last menstrual period 1.5 years back. The patient had a history of spontaneous abortion 4 years back for which dilatation and evacuation were done. Histo-pathological reports were unavailable. There was no history of hormonal replacement therapy. The patient had no significant past medical or surgical history.

Her general and systemic examination findings were normal. On abdominal examination, uterus was 14–16 weeks size. On per-speculum examination, the cervix and vagina were normal. On bimanual examination, uterus was 14 weeks, mobile, bilateral adnexa were normal.

The urinary pregnancy test was positive and serum beta-hCG was 146,000 mIU/ml. Complete blood count revealed mild anemia (9.9 gm%), with normal white blood cell count, and platelet count, liver function, kidney function, and thyroid function tests were within normal limits. ECG was normal. Chest X-ray revealed multiple pulmonary metastasis bilaterally.

Contrast-enhanced computed tomography of abdomen and pelvis [Figure 1] revealed diffusely enhanced uterus showing heterogeneously enhancing ill-defined soft-tissue density mass/lesion with internal peripherally enhancing hypodense fluid content causing engorgement of the parametrial vasculature and dilatation of right gonadal vein. Multiple small ill-defined lytic lesions at multiple dorso-lumbar vertebral bodies. Computed tomography of the thorax revealed multiple confluent nodular lesions in both lungs-suggestive of secondary deposits [Figure 2]. Magnetic Resonance Imaging of the Brain showed no abnormality.



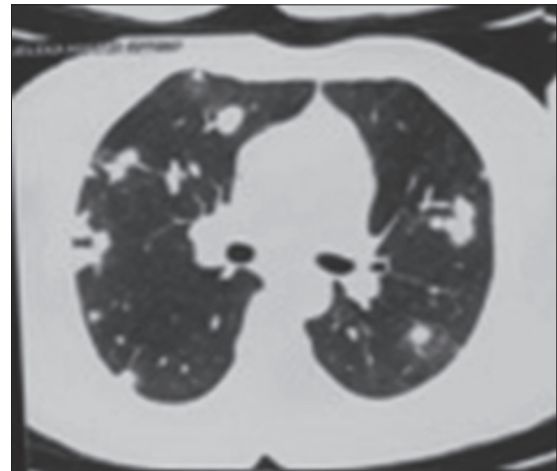
**Figure 1:** Contrast enhanced computed tomography of pelvis (Case 1)

In view of raised serum beta-hCG, uterine mass, and pulmonary lesions suggestive of metastasis, provisional diagnosis of Gestational Trophoblastic Neoplasm (Choriocarcinoma) was made. The FIGO (WHO) score<sup>[1]</sup> was 12 (High risk) and thus, the patient was started on multi-agent chemotherapy. The patient developed severe Grade III hematological toxicity leading to sepsis. She died while on the first cycle of EMACO.

### Case 2

A 42-year-old, P2 L2, presented with postmenopausal bleeding for 2 months. The patient had a history of choriocarcinoma 20 years back which was treated with Actinomycin D following which the patient conceived spontaneously. The patient had a history of postpartum hemorrhage after the birth of the second child at the age of 30 years following which the patient had amenorrhoea. No investigations were done for premature menopause. There is no other significant medical or surgical history. Her general and system examination were normal. On abdominal examination, the uterus was 14 weeks size. On per-speculum examination, the cervix and vagina were normal. On bimanual examination, uterus was 14 weeks, mobile, right adnexal cystic mass, left adnexa was normal.

Contrast-enhanced computed tomography of abdomen and pelvis revealed heterogeneous mass lesion of 37.3 mm × 32 mm in the fundus-body region with internal necrotic areas of uterus. Cystic lesion of 49 mm × 36 mm size with internal echoes in right adnexa seen. Endometrial biopsy showed features of choriocarcinoma. Initial serum beta-hCG was 13,142 mIU/ml. Complete blood count, liver function, kidney function, and thyroid function tests were within the normal limits. Chest X-ray showed no signs of parenchymal disease.



**Figure 2:** Contrast enhanced computed tomography of thorax (Case 1)

Table 1: Review of literature

Year of publication	Author	Number of cases	Age (years)	FIGO score	Chemotherapy	Surgery	Outcome
1996	G Massenkeil, <i>et al.</i>	1	58	14	EMACO	No	Expired
2006	U Mukherjee, <i>et al.</i>	1	54	9	EMACO	No	Expired
2010	N. R. Desai, <i>et al.</i>	1	73	12	EMAO	No	Alive
2012	M S Even, <i>et al.</i>	1	58	8	EMACO	Yes	Expired
2014	Sunil K Samal, <i>et al.</i>	1	52	11	EMACO	Yes	Alive
2017	L F Rafanan, <i>et al.</i>	2	50	11	EMACO	Yes	Expired
			51	9	EMACO	No	Alive
2018	Gou N, <i>et al.</i>	1	61	11	EMACO	No	Alive
2020	Present study	3	52	12	EMACO	No	Expired
			42	11	EMACO	No	Alive
			47	10	EMACO	Yes	Alive

FIGO: International Federation of Gynecology and Obstetrics, EMACO: Etoposide, Methotrexate, Actinomycin D, Cyclophosphamide, Vincristine

Based on raised serum beta hCG, and uterine lesion, the patient was diagnosed with a case Gestational Trophoblastic Neoplasm (Choriocarcinoma). The patient was started on multi-agent chemotherapy in view of High-risk based on FIGO score-11. After completing 6 cycles of EMA-CO, her serum Beta-hCG was 4.47 mIU/ml. The patient received 2 more cycles of consolidation chemotherapy and is on regular follow-up.

### Case 3

Forty-seven-year, P 4 L4, presented with postmenopausal bleeding for 4 months. The patient attained menopause 3 years back and her last childbirth was 12 years back. The patient underwent hysterectomy with bilateral salpingo-oophorectomy at the private clinic which showed features of choriocarcinoma of the uterus on histopathological examination. Initial serum beta-hCG was 75,500 mIU/ml. Clinical examination revealed no abnormality. Complete blood count, liver function, kidney function, and thyroid function tests were within the normal limits. Contrast-enhanced computed tomography of the whole abdomen revealed 2 cysts in the right lobe of the liver (noninfiltrating) with no abnormality in the pelvis. Contrast-enhanced computed tomography of the thorax showed small nodular metastatic nodules in bilateral lung fields with few subcentimetric pretracheal lymphadenopathy.

A provisional diagnosis of High-risk (FIGO score-10) choriocarcinoma was made based on raised Beta-hCG, liver, and lung metastasis. The patient was started on Multi-agent chemotherapy (EMA-CO). Patient received six cycles of chemotherapy followed by 2 cycles of consolidation chemotherapy after serum beta-hCG was <5 mIU/ml. The patient is on regular follow-up at our hospital.

## DISCUSSION

Choriocarcinoma accounts for rare gynecological malignancies in postmenopausal women. The exact incidence has not been documented yet due to the rarity of the disease, however, several case reports have been published. Typically, in reproductive-age women, Choriocarcinoma presents within 12 months of antecedent pregnancy, however long latent periods have in women who are postmenopausal. Leslie F. Rafanan, *et al.*, reported two cases of Choriocarcinoma in postmenopausal women developing 11 and 25 years after last pregnancy. The risk of GTD progressing to GTN is 5% in younger women however after 45 years the risk is 5-fold higher (27%). Apart from vaginal bleeding, vaginal/uterine mass, Choriocarcinoma can present with nonspecific symptoms of hemoptysis, nausea in postmenopausal women suggesting the presence of metastatic disease.<sup>[1]</sup> Once the diagnosis of choriocarcinoma is confirmed, Contrast-enhanced Computed Tomography of the abdomen, Chest X-ray, MRI of the brain and pelvis, a Doppler ultrasound of the pelvis are done in sequential manner to rule out metastatic disease. Cerebrospinal fluid to serum hCG ratio, >1:60 suggests occult central nervous system disease. The management is based on FIGO scoring:-low-risk disease (score 0–6) is treated with single-agent chemotherapy whereas for high-risk disease (score >=7), multi-agent chemotherapy EMA/CO regimen (Etoposide, Methotrexate, Actinomycin D, Cyclophosphamide, Vincristine) is used.<sup>[1]</sup> Only a few cases of postmenopausal choriocarcinoma have been reported in the literature<sup>[2,3]</sup> and most of them have a poor prognosis.<sup>[4]</sup> Evsen *et al.*, reported a case of Molar pregnancy progressing to GTN who died of Grade IV hematological toxicity while on EMA/CO.<sup>[2]</sup> B Chittenden *et al.* encountered a Postmenoapusal woman with Choriocarcinoma who developed Toxis

Epidermal Necrolysis while on EMA/CO and died. Guo *et al.* and Leslie F. Rafanan *et al.* reported cases with recurrent and advanced Choriocarcinoma who did not respond to first-line chemotherapy and succumbed to the disease.<sup>[3]</sup> Another case reported by G. Massenkeil *et al.* is of a 58-year-old woman who died due to advanced, metastatic choriocarcinoma. Out of 3 of our patients, 1 succumbed to death while the other two completed 8 cycles of multi-agent chemotherapy and are on regular follow-up till date [Table 1].

## CONCLUSION

Choriocarcinoma is rare gynecological malignancy in postmenopausal women. The presentation mimics that of other gynecological malignancies and thus, high index of suspicion is required to diagnose the disease. Histopathological confirmation is not available in most of cases. In our report, only one of the patients had biopsy-proven choriocarcinoma and other two were diagnosed based on raised beta-hcg, uterine lesion without or without the presence of distance metastasis. The prognosis of the disease is good in younger women, however, after reviewing the literature it was deduced that in older, postmenopausal women, it carries a grave prognosis. There is high incidence of metastatic, recurrent disease and low tolerance to standard multi-agent chemotherapeutic drugs. Thus, it might be prudent to say that research is needed to deduce the reason for the aggressive behavior of the tumor in

older women also, new treatment guidelines need to be formulated to improvise the outcome.

## Declaration of patient consent

The authors certify that they have obtained all appropriate patient consent forms. In the form the patient (s) has/have given his/her/their consent for his/her/their images and other clinical information to be reported in the journal. The patients understand that their names and initials will not be published and due efforts will be made to conceal their identity.

## Financial support and sponsorship

Nil.

## Conflicts of interest

There are no conflicts of interest.

## REFERENCES

1. Rafanan LF, Greenberg H, Rondeau NU, Mulla ZD, Boman DA. Primary choriocarcinoma in postmenopausal women: Two case reports and review of the Texas Cancer Registry. *Gynecologic oncology reports* 2017;22:69.
2. Seckl MJ, Sebire NJ, Fisher RA, Golfier F, Massuger L, Sessa C, *et al.* Gestational trophoblastic disease: ESMO clinical practice guidelines for diagnosis, treatment and follow-up. *Ann Oncol* 2013;24 Suppl 6:i39-50.
3. Evsen MS, Erdal SM, Ender SH, Senem S, Ugur F, Mehmet K. A rare case of postmenopausal bleeding: Choriocarcinoma. *J Clin Gynecol Obstet* 2012;1:79-81.
4. Guo N, Yin R, Li Q, Song L, Wang D. Postmenopausal choriocarcinoma: A rare case report and review of the literature. *Menopause* 2018;25:239-41.