

High Levels of Copper, Zinc, Iron and Magnesium, but not Calcium, in the Cerebrospinal Fluid of Patients with Fahr's Disease

Isao Hozumi^a Akihiro Kohmura^a Akio Kimura^a
Tatsuya Hasegawa^b Akiko Honda^c Yuichi Hayashi^a
Kazunori Hashimoto^a Megumi Yamada^a Takeo Sakurai^a
Yuji Tanaka^a Masahiko Satoh^c Takashi Inuzuka^a

^aDepartment of Neurology and Geriatrics, Gifu University, Graduate School of Medicine, Gifu, ^bLaboratory of Environmental Biochemistry, Yamanashi Prefectural Environmental Science Institute, Fuji-Yoshida, and ^cLaboratory of Pharmaceutical Health Sciences, School of Pharmacy, Aichi Gakuin University, Nagoya, Japan

Key Words

Fahr's disease · Calcification · Copper · Zinc · Dementia · Parkinsonism

Abstract

Patients with marked calcification of the basal ganglia and cerebellum have traditionally been referred to as having Fahr's disease, but the nomenclature has been criticized for including heterogeneous etiology. We describe 3 patients with idiopathic bilateral striatopallidodentate calcinosis (IBSPDC). The patients were a 24-year-old man with mental deterioration, a 57-year-old man with parkinsonism and dementia, and a 76-year-old woman with dementia and mild parkinsonism. The former 2 patients showed severe calcification of the basal ganglia and cerebellum, and the latter patient showed severe calcification of the cerebellum. We found significantly increased levels of copper (Cu), zinc (Zn), iron (Fe) and magnesium (Mg), using inductively coupled plasma mass spectrometry in the CSF of all these 3 patients. The increased levels of Cu, Zn, Fe and Mg reflect the involvement of metabolism of several metals and/or metal-binding proteins during the progression of IBSPDC. More numerous patients with IBSPDC should be examined in other races to clarify the common mechanism of the disease and to investigate the specific treatment.

Introduction

Mild calcification of the basal ganglia is sometimes seen, especially in the elderly. Some patients with marked calcification of the basal ganglia and cerebellum have been reported to be associated with hypoparathyroidism. Most other idiopathic cases have traditionally been referred to as having Fahr's disease, but the nomenclature has been criticized for including a heterogeneous etiology and the disease has presented as a clinically complex syndrome. The patients have not been clearly demonstrated to exhibit any endocrine, metabolic or genetic disorder [1, 2]. The pathophysiological mechanism remains to be elucidated and there is no clue for the treatment. The disease is thus being referred to by some as idiopathic bilateral striatopallidodentate calcinosis (IBSPDC). Inductively coupled plasma mass spectrometry (ICP-MS) can measure the levels of several metals in a small amount of CSF [3]. We have measured those of Japanese patients with IBSPDC to clarify the pathophysiological features of the disease.

Case Reports

Patient 1

A 24-year-old man was hospitalized for gait and speech disturbance. He had been diagnosed with Fahr's disease when 15 years old in a hospital and his IQ was 79. On admission, neurological examination revealed mental deterioration (IQ 69), exaggerated deep tendon reflexes, mild rigidity on the right, and limb and truncal ataxia. CT showed a striking high density area in the basal ganglia and dentate nuclei and revealed progression with age (fig. 1a). No abnormal findings were detected in the blood tests including metals [calcium (Ca), iron (Fe), copper (Cu), zinc (Zn), magnesium (Mg) and manganese (Mn)], in Ca metabolism including parathyroid hormone and the Ellsworth-Howard test, and in routine CSF studies.

Patient 2

A 57-year-old man was hospitalized for dementia, bradykinesia, and gait disturbance. He showed parkinsonism at age 50 and mental deterioration since age 55. Neurological examination revealed dementia, slurred speech, limb ataxia, rigidity, bradykinesia and truncal ataxia. Interestingly, L-DOPA led to a slight improvement in symptoms. He showed similar CT findings as patient 1 (fig. 1b), diabetes mellitus, and no other abnormal findings either in the above-mentioned tests.

Patient 3

A 76-year-old woman came to our hospital for dementia. Neurological examination revealed dementia and mild parkinsonism. CT showed a striking high density area in the dentate nuclei, and a moderate area in the basal ganglia and border of the cortex and white matter of the parietal lobe (fig. 1c). No abnormal findings were detected in the above-mentioned tests.

None of the 3 patients had a skeletal structural abnormality or a family history of IBSPDC. Analysis of the levels of Ca, Fe, Cu, Zn, Mg, and Mn in the scalp hair showed no specific findings in the 3 patients using a commercially-available ICP-MS method (La Belle Vie Inc., Tokyo, Japan).

Metals in CSF Analysis

CSF samples were obtained from 3 patients with IBSPDC and 15 controls (9 females and 6 males, age from 22 to 81 years with a mean of 52 years). CSF samples were nebulized with perhydroxyl-nitrate, and the levels of metals (Fe, Cu, Zn, Mg, and Mn) were measured using ICP-MS (HP4500, Agilent Technologies, Japan). Scandium (Sc), yttrium (Y) and thallium (Tl) were added to samples as internal standards. The concentrations of the elements were normalized by the internal standards. The level of

Ca in the CSF was measured by colorimetry using o-cresolphthalein-complexone (o-CPC) for appropriate means. This study was approved by the Ethics Committee of the Gifu University Graduate School of Medicine.

Results

The levels of Cu, Zn, Fe, and Mg were significantly increased by 3.7, 2.5, 1.9, and 1.6 times of control levels, respectively. Statistical analysis using Mann-Whitney U test showed significant difference ($p < 0.01$) in the levels of Cu, Fe and Mg, and significant difference ($p < 0.05$) in that of Zn, but the levels of Ca (1.1 times) and Mn (0.9 times) in the CSF of all 3 cases with IBSPDC were not significantly different from those of controls ([table 1](#) and [fig. 2](#))

Discussion

Chemical analyses of brain stones in the striopallidodental system has shown high levels of Ca and other metals, such as Fe, Mg, Cu, Zn, Mn, lead, and aluminium [4, 5]. However, there is no apparent explanation for the accumulation of calcium and other metals. The pathophysiological features of Fahr's disease thus remain to be elucidated. The term 'Fahr's disease' has various entities including familial and secondary cases. As the concept of Fahr's disease may encompass diseases derived from different genetic or environmental etiologies in the region, we prefer the term 'IBSPDC' to 'Fahr's disease'. In Japan, elderly patients with dementia and calcification of the basal ganglia were reported to show diffuse neurofibrillary tangles and absence of senile plaques in the pathology [6, 7]. Patients 2 and 3 are considered to be included in this category. We presented 3 clinically idiopathic cases of IBSPDC with variable clinical characteristics and ages.

ICP-MS can measure the level of several metals in a small amount of CSF (less than 1 ml). ICP-MS is more sensitive and accurate than traditional colorimetry and the atomic absorption spectrophotometry method for the measurement of several metals such as Cu, Zn, Mg, except for that of Ca.

Generally, the high density of the basal ganglia and cerebellum in CT images has been thought to be mainly associated with calcification. However, a disorder of Ca metabolism has not been demonstrated in IBSPDC. Only one preliminary study reported rather decreased levels of Ca in the CSF in Fahr's disease, contrary to our expectations [8]. Our 3 cases with IBSPDC showed various ages and clinical presentation, but a similar and significant increase in Cu, Zn, Fe and Mg. This suggests that some cases with IBSPDC are associated with a disorder including heavy metals, especially Cu, Zn, and Fe metabolism, and some metal-binding proteins. Even at low levels, Fe and Cu can catalyze a Fenton reaction, producing highly reactive hydroxyl radicals. Excessive amounts of Cu can be a directly neurotoxic factor and also damage neurons by producing reactive oxygen in neurodegenerative disorders, such as Alzheimer's disease, Parkinson's disease, and amyotrophic lateral sclerosis [9–11].

Pathological and biochemical analyses at autopsy are needed for further evaluation. In the study we could not recognize whether metals in the CSF are free or are derived from metal-binding proteins such as superoxide dismutase-1 and metallothioneins (MT). The high levels of metals in the CSF do not necessarily reflect correctly the pathophysiological mechanisms in the brain; however, this feature of the CSF provides some novel aspects of

the diseases. CSF of more numerous and clinically variable cases with IBSPDC should be examined in other races to clarify the common pathophysiological features.

We have detected high levels of Cu, Zn, Fe and Mg in the CSF of 3 patients with IBSPDC in Japan. There is no specific and effective treatment for IBSPDC at present, and the progression of the disease is accelerated with age. MT is a small (7 kDa), metal-binding (4 Cu and 3 Zn per molecule) protein that scavenges reactive oxygen species [10]. The study of CSF may provide a clue regarding a common pathway of IBSPDC including the metabolism of Cu, Zn, Fe and Mg and appropriate treatments including metal-chelating agents such as ammonium tetrathiomolybdate, a Cu-chelating agent [11], and metal-binding proteins such as MT [10].

Disclosure

Dr. Hozumi has received research support from the Ministry of Education, Culture, Sports, Science and Technology of Japan (Basic Research (B) 19390151) and Mitsui Sumitomo Insurance Welfare Foundation, Japan.

Table 1. Levels of metals in CSF

	Age	Ca (mg/l)	Mg (mg/l)**	Fe (µg/l)**	Cu (µg/l)**	Zn (µg/l)*	Mn (µg/l)
Patient 1	26	45.0	49.1	418	33.9	8.00	2.10
Patient 2	58	42.0	47.3	461	38.0	10.0	1.00
Patient 3	76	49.0	48.2	458	40.1	22.2	2.10
Average ± SD	53.3 ± 25.3	45.3 ± 3.51	48.2 ± 0.90	446 ± 23.7	37.3 ± 3.15	13.4 ± 7.69	1.73 ± 0.635
Control (n = 15)							
Average ± SD	48.4 ± 22.2	41.1 ± 4.64	29.6 ± 6.52	238 ± 54.7	10.2 ± 2.07	5.30 ± 3.31	1.90 ± 0.971

The levels of Ca, Fe, Cu, Zn, Mg, and Mn in CSF of patients and controls (n = 13). Statistical analysis was performed using Mann-Whitney U test.

* Significant difference, $p < 0.05$. ** Significant difference, $p < 0.01$.

Fig. 1. CT findings in patients. **a** CT findings in patient 1. A sagittal view shows a striking high density area in the basal ganglia and the dentate nuclei of the cerebellum. **b** CT findings in patient 2. An axial view shows a marked high density area in the basal ganglia and spots at various sites such as the pulvinar thalami, the subcortical area in the frontal lobe, and the border area of the cortex and white matter in the occipital lobe. **c** CT findings in patient 3. An axial view shows a striking high density area in the dentate nuclei of the cerebellum.

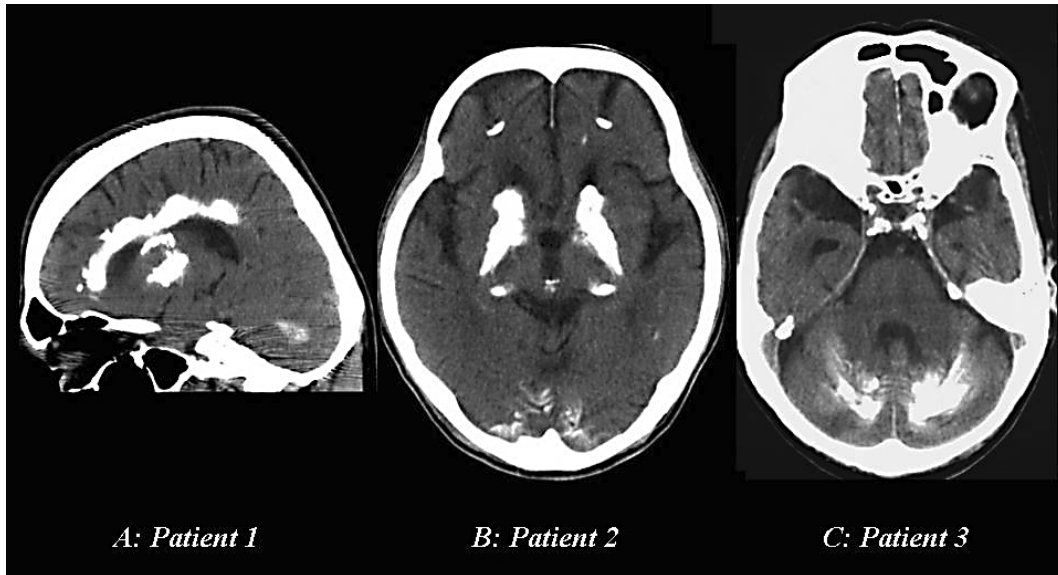
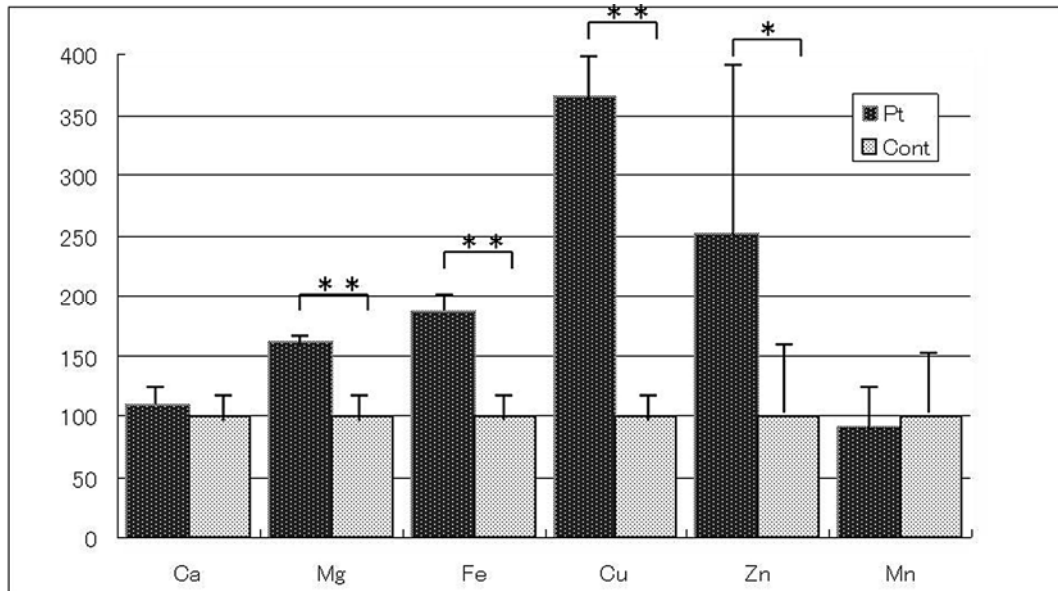


Fig. 2. Comparative values of metals in the CSF. The average levels of Ca, Fe, Cu, Zn, Mg, and Mn in the CSF of patients and controls are shown to be set at the value of 100 (%) in the figure. Especially the values of Cu and Zn in patients are markedly higher compared to those of controls. * Significant difference, $p < 0.05$. ** significant difference, $p < 0.01$.



References

- 1 Oppenheimer DR, Esiri MM: Calcification of the basal ganglia; in Adams JH, Duchen LW (eds): *Greenfield's Neurology*, ed 5, Oxford University Press, 1992, pp 1005–1007.
- 2 Manyam BV: What is and what is not 'Fahr's disease'. *Parkinson Relat Disord* 2005;11:73–80.
- 3 Gellein K, Roos PM, Evje L, Vesterberg O, Flaten TP, Nordberg M, Syversen T: Separation of proteins including metallothionein in cerebrospinal fluid by size exclusion HPLC and determination of trace elements by HR-ICP-MS. *Brain Res* 2007;1174:136–142.
- 4 Löwenthal A, Bruyn GW: Calcification of the striopallidodentate system; in Vinken PJ, Bruyn GW (eds): *Handbook of Clinical Neurology*, vol 6, Amsterdam, North-Holland, 1968, pp 703–725.
- 5 Smeyers-Verbeke J, Michotte Y, Pelsmaeckers J, Löwenthal A, Massart DL, Dekegel D, Karcher D: The chemical composition of idiopathic nonarteriosclerotic cerebral calcifications. *Neurology* 1975;25:48–57.
- 6 Shibayama H, Kobayashi H, Nakagawa M, Yamada K, Iwata H, Iwai K, Takeuchi T, Mu-Qune X, Ishihara R, Iwase S, Kitoh J: Non-Alzheimer non-Pick dementia with Fahr's syndrome. *Clinical Neuropathol* 1992;11:237–250.
- 7 Kosaka K: Diffuse neurofibrillary tangles with calcification: a new presenile dementia. *J Neurol Neurosurg Psychiatry* 1994;57:594–596.
- 8 McLellan TL, Manyam BV, Wilmington DE, Philadelphia PA: Diagnostic implications of CSF calcium measurement. *Neurology* 1984;34(suppl 1):198.
- 9 Harris ED: Basic and clinical aspects of copper. *Crit Rev Clin Lab Sci* 2003;40:547–586.
- 10 Hozumi I, Asanuma M, Yamada M, Uchida Y: Metallothioneins and neurodegenerative diseases. *J Health Science* 2004;50:323–331.
- 11 Tokuda E, Ono S, Ishige K, Naganuma A, Ito Y, Suzuki T: Ammonium tetrathiomolybdate delays onset, prolongs survivals, and slows progression of disease in a mouse model for amyotrophic lateral sclerosis. *Exper Neurol* 2008;122–128.