

Ectopic goitrous submandibular thyroid with goitrous orthotopic thyroid gland

Avinash Kumar Bhardwaj, Vinayaga Mani, Rashmi Dixit, Anju Garg

Department of Radiodiagnosis, Maulana Azad Medical College and Associated Lok Nayak Hospital, New Delhi, India

Correspondence: Dr. Avinash Kumar Bhardwaj, Room No. 142, Department of Radiodiagnosis, Lok Nayak Hospital, New Delhi - 110 002, India. E-mail: drbhardwajbcl2@gmail.com

Abstract

Ectopic thyroid is a rare developmental anomaly with lingual thyroid accounting for majority of the cases. The presence of ectopic thyroid tissue lateral to the midline is very rare, and very few cases located in the submandibular region have been reported. The simultaneous finding of submandibular ectopic thyroid tissue and a functional orthotopic thyroid gland is even rarer. In the differential diagnosis of an ectopic submandibular thyroid, it is fundamental to exclude a metastasis from well-differentiated thyroid cancer, even when primary thyroid carcinoma is not demonstrable.

Key words: Ectopic thyroid; midline ectopic thyroid; submandibular ectopic thyroid

Introduction

Ectopic thyroid is defined as thyroid tissue that is not located anterolaterally to second and fourth tracheal cartilages.^[1] Thyroid is the first endocrine gland to form during embryogenesis. It is derived from a large median anlage and two lateral anlages.^[2] The cause of ectopic thyroid tissue remains unclear in most cases. Mutation of thyroid transcription factor 2, which is required for the downward migration of the thyroid gland, has been proposed as a possible mechanism.^[3] Failure of the descent of median anlage results in a lingual thyroid. In some rare cases, the lack of fusion of the lateral anlage with median anlage results in lateral ectopic thyroid.^[4] Other than lacking the characteristic bilobate shape, ectopic thyroid tissue appears identical to orthotopic thyroid tissue. All diseases that can affect the normal thyroid, for example, adenoma, hyperplasia, inflammation, and malignancy can also involve the ectopic thyroid.^[5]

We report a case of colloid goiter of ectopic submandibular thyroid in a person with goitrous orthotopic thyroid gland.

Case Report

A 57-year-old female was referred to the Department of Radiodiagnosis with a history of painless swelling in the neck and submandibular region for the past 4 years. There was no history of dysphagia or dyspnea. There were no clinical features of hypo/hyperthyroidism. On physical examination, a mobile, nontender, firm swelling was found on the right side of neck. Mild enlargement of the thyroid gland was also present. Thyroid function tests were found to be normal. Ultrasound of the neck using high-frequency linear transducer (12 MHz) revealed a diffusely enlarged heterogeneous thyroid gland with multiple echogenic nodular lesions in both lobes of thyroid largest of 25 mm in upper pole suggestive of multinodular goiter [Figure 1].

This is an open access article distributed under the terms of the Creative Commons Attribution-NonCommercial-ShareAlike 3.0 License, which allows others to remix, tweak, and build upon the work non-commercially, as long as the author is credited and the new creations are licensed under the identical terms.

For reprints contact: reprints@medknow.com

Cite this article as: Bhardwaj AK, Mani V, Dixit R, Garg A. Ectopic goitrous submandibular thyroid with goitrous orthotopic thyroid gland. Indian J Radiol Imaging 2016;26:245-8.

Access this article online

Quick Response Code:



Website:
www.ijri.org

DOI:
10.4103/0971-3026.184420

Ultrasonography (USG) of the right submandibular lesion revealed a large echogenic solid lesion [Figure 2] with internal and peripheral vascularity. The submandibular gland was seen separately from the lesion. Computed tomography (CT) of neck was carried out on a 128-slice multiple detector CT after intravenous injection of nonionic

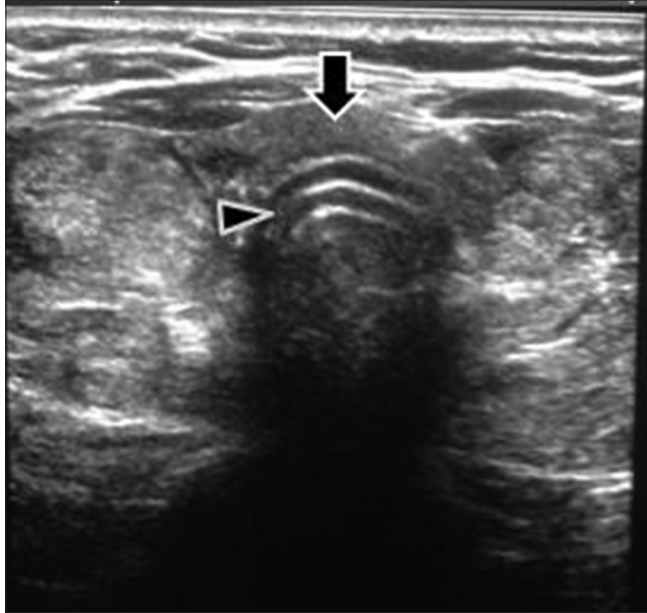


Figure 1: High-resolution sonography at mid neck level on transverse section shows enlarged thyroid with isthmus (arrow) overlying the trachea (arrow head) and multiple echogenic nodules in both lobes

contrast. It revealed a well-defined intensely enhancing soft tissue mass lesion in right submandibular space [Figure 3], displacing the submandibular gland anteriorly and extending up to right parotid and parapharyngeal space. It was abutting the right sternocleidomastoid muscle which appeared normal. Thyroid gland appeared bulky and heterogeneous with lobulated borders [Figure 4]. There was no evidence of any significant cervical lymphadenopathy.

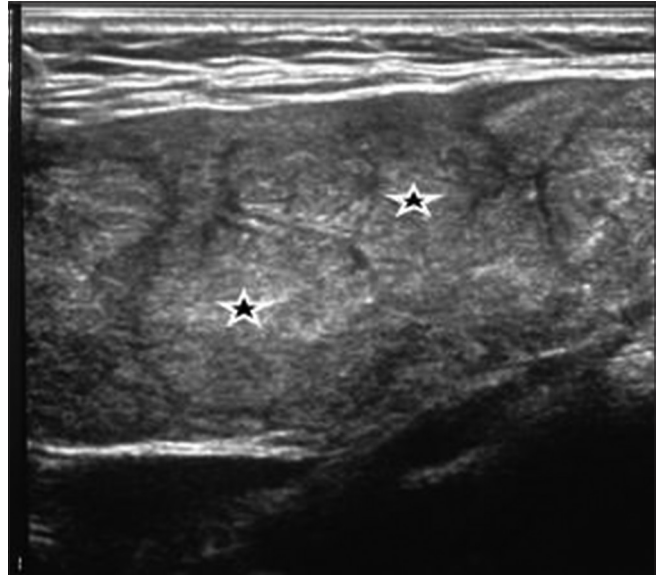


Figure 2: High-resolution sonography image on longitudinal view shows multiple heteroechoic nodules (stars) in submandibular mass lesion whose echo pattern matches that of orthotopic goitrous thyroid gland

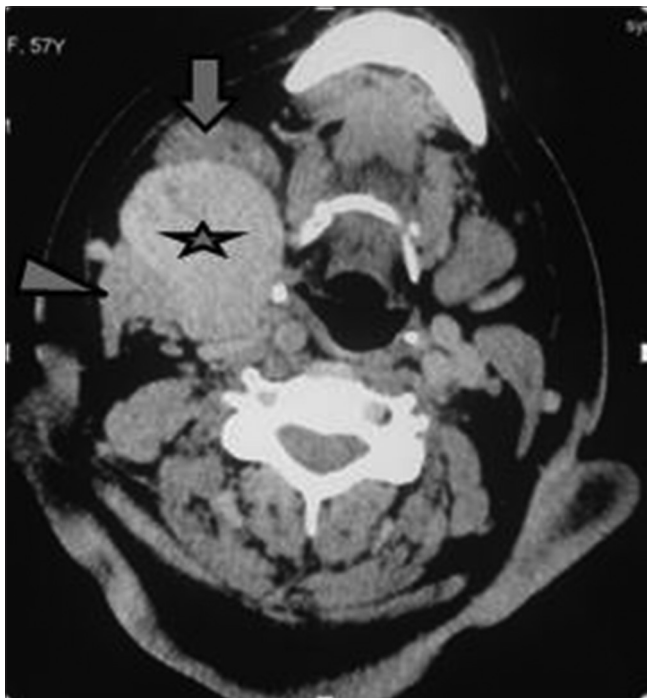


Figure 3: Postcontrast axial computed tomography image shows an intensely enhancing submandibular mass lesion (star) seen in between right submandibular gland (arrow) and right sternocleidomastoid muscle (arrowhead)

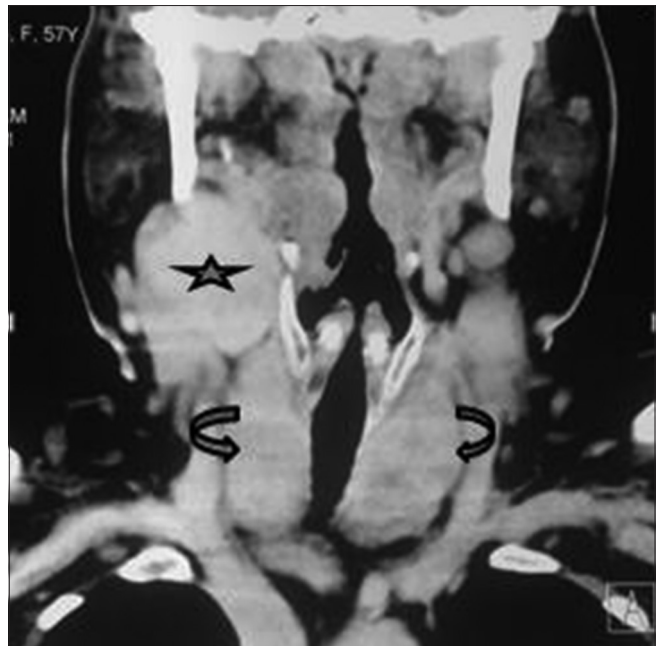

Figure 4: On the coronal reconstruction image, the mass lesion (star) is seen to be completely separate from the thyroid gland with a clear plane of cleavage between them. The thyroid gland itself is enlarged and heterogeneous due to changes of multinodular goiter (curved arrows)

On the basis of imaging a differential diagnosis of paraganglioma, neurogenic tumor, metastasis, ectopic goitrous submandibular thyroid were considered. Thyroid scintigraphy revealed diffuse uptake in thyroid gland and right submandibular swelling and confirmed the submandibular region mass to be thyroid in nature with goitrous changes in the orthotopic and ectopic gland. Fine-needle aspiration cytology (FNAC) was done which showed occasional thyroid follicular epithelial cells with a few scattered cysts in a clear background suggestive of colloid goiter with cystic degeneration. She underwent surgery, and an encapsulated solid cystic mass measuring 5 cm × 5 cm × 3.5 cm was dissected with clear fat planes and resected [Figure 5]. No connection was present with the goitrous thyroid gland. Histopathology revealed colloid goiter with cystic degeneration [Figure 6].

Discussion

Thyroid gland is a bilobed gland connected by an isthmus overlying the second to fourth tracheal rings. There are several circumstances in which normal or abnormal thyroid tissue may be found within the neck but outside the thyroid gland. Rosai and Ackerman's classification^[6] distinguishes such tissue as follows:

1. Ectopic thyroid tissue resulting from faulty embryogenesis
2. Hyperplastic thyroid tissue outside the gland in patients with Graves' disease
3. Mechanical implantation of thyroid tissue in the neck secondary to surgical intervention or accidental trauma
4. A sequestered thyroid nodule, also known as a parasitic or accessory nodule, i.e. the occurrence of a peripherally located thyroid nodule in which the anatomic connection with the main gland is either lost or missed by the surgeon
5. Thyroid tissue within cervical lymph nodes, which may develop by two unrelated processes: Metastases of

clinically undetected thyroid carcinomas, nearly always of the papillary variety or the development of normal follicles within lymph nodes

6. Thyroid tissue as a component of a teratoma, particularly in the ovary.

Ectopic thyroid is very rare with a prevalence of approximately 1 in 100,000–300,000 in the population with a female:male ratio of about 4:1.^[7] It is mostly located in the midline along the path of the thyroglossal duct, i.e., from foramen cecum at the junction of anterior two-third and posterior one-third of tongue to the mediastinum. Ninety percent of ectopic thyroids are at the base of the tongue, so-called lingual thyroid.^[8] Rarely, ectopic thyroid gland may present lateral to midline.^[9] The presence of ectopic thyroid in submandibular space and a functional orthotopic thyroid gland is rarely reported in literature.^[10-17]

In our case, the patient had colloid goiter of the ectopic thyroid in the presence of an orthotopic goitrous gland with no history of previous surgery or trauma. Kanaya *et al.*^[14] reported ectopic thyroid tissue with partial adenomatous goiter in a 53-year-old woman who had undergone a subtotal thyroidectomy 30 years earlier.

The common differential diagnoses for a solid mass in submandibular location are pleomorphic adenoma or carcinoma, inflammatory lesions such as sialadenitis, neurogenic tumors, paragangliomas, fibrolipomas, and lymphadenopathy of various etiologies. Although rare, ectopic thyroid should be considered as a differential diagnosis of submandibular mass separate from the submandibular gland as in our case.^[17,18]

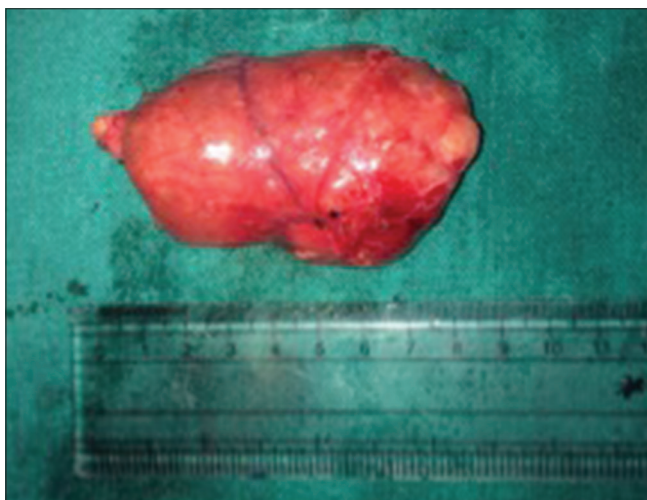


Figure 5: Postoperative specimen showing the excised ectopic goitrous thyroid mass

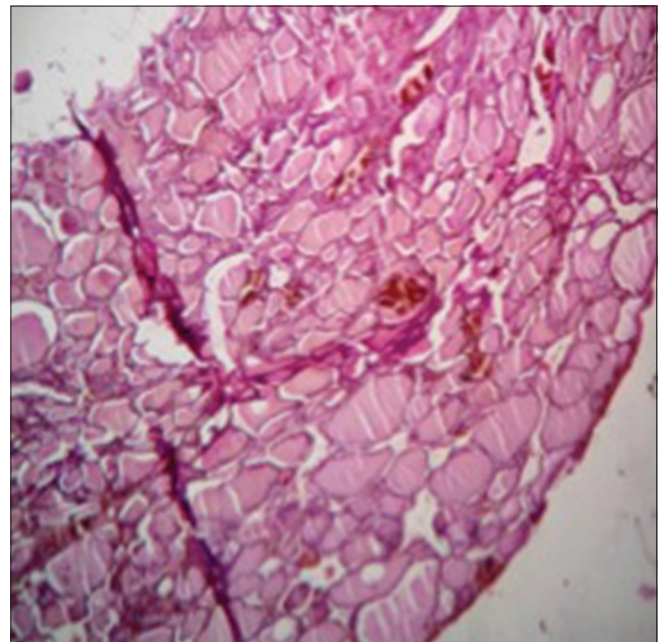


Figure 6: The submandibular swelling showing changes of colloid goiter with cystic degeneration (H and E, ×100)

The most important diagnostic modality for ectopic thyroid is thyroid scanning with technetium-99 m. Thyroid scanning also detects the presence of other sites of thyroid tissue.^[19] However, FNAC, USG, CT, and magnetic resonance imaging may help define the extension and location of the ectopic thyroid gland.

Since only the ectopic tissue is functional in up to 70% of cases, there are diagnostic and therapeutic difficulties when submandibular ectopic thyroid occurs. To choose the best treatment in these cases, identification of the presence or absence of orthotopic functioning thyroid should be done.^[20]

In our case, scintigraphy helped confirm the ectopic tissue to be thyroid and also showed the presence of functional orthotopic thyroid gland; hence, the patient could undergo surgical excision of the ectopic glandular tissue.

Submandibular ectopic thyroid needs to be differentiated from metastatic thyroid cancer. Metastatic thyroid cancer can be diagnosed on FNAC/cytopathology and always need to be excluded before diagnosis of ectopic thyroid. The rate of malignant transformation in ectopic thyroid is no greater than in normally placed thyroid.^[10] In our case, FNAC both from the lesion and orthotopic gland as well as postsurgical excision of the ectopic gland excluded metastatic thyroid cancer or malignant change.

To the best of our knowledge, only eight cases of simultaneous submandibular ectopic thyroid tissue and a functional orthotopic thyroid gland have been reported in the literature.^[10-17]

Conclusion

Cases of submandibular ectopic thyroid, though extremely rare, should be considered as a differential diagnosis of submandibular region mass especially when the submandibular gland is seen separately and the lesion shows intense enhancement. A high degree of suspicion on imaging is essential as surgical resection and pathologic assessment represent the most appropriate therapeutic option; however, before surgical excision of the ectopic thyroid, it is necessary to ensure that normal, functioning thyroid tissue is present elsewhere so that the patient is not rendered severely hypothyroid.

Financial support and sponsorship

Nil.

Conflicts of interest

There are no conflicts of interest.

References

1. Damiano A, Glickman AB, Rubin JS, Cohen AF. Ectopic thyroid tissue presenting as a midline neck mass. *Int J Pediatr Otorhinolaryngol* 1996;34:141-8.
2. Choi JY, Kim JH. A case of an ectopic thyroid gland at the lateral neck masquerading as a metastatic papillary thyroid carcinoma. *J Korean Med Sci* 2008;23:548-50.
3. Van Vliet G. Development of the thyroid gland: Lessons from congenitally hypothyroid mice and men. *Clin Genet* 2003;63:445-55.
4. Paresi RJ Jr, Shah D. Hashimoto's thyroiditis presenting as an enlarging submandibular mass in a patient with a lingual thyroid. *Otolaryngol Head Neck Surg* 2005;132:806-8.
5. Jarvis JF. Lingual thyroid: A report of three cases and discussion. *S Afr Med J* 1969;43:8-12.
6. Rosai J. *Ackerman's: Surgical Pathology*. 10th ed., Vol. 1. Missouri: Elsevier Mosby; 2011. p. 488-91.
7. Yeung VT, Loong EP, Cockram CS. Cretinism and lingual thyroid presenting in an adult. *Postgrad Med J* 1987;63:881-3.
8. Noyek AM, Friedberg J. Thyroglossal duct and ectopic thyroid disorders. *Otolaryngol Clin North Am* 1981;14:187-201.
9. Feisal TK, Prepageran N, Shahrizal T, Zulkiflee AB. Unusual parapharyngeal lesion: Aberrant thyroid gland. *Singapore Med J* 2008;49:e137-8.
10. Yilmaz MS, Aytürk S, Güven M, Dilek FH. Submandibular ectopic thyroid with normally located thyroid gland. *Kulak Burun Bogaz Ihtis Derg* 2014;24:50-3.
11. Aköz T, Erdogan B, Ayhan M, Cinar F. Ectopic submandibular thyroid tissue. *Rev Laryngol Otol Rhinol (Bord)* 1998;119:323-5.
12. Feller KU, Mavros A, Gaertner HJ. Ectopic submandibular thyroid tissue with a coexisting active and normally located thyroid gland: Case report and review of literature. *Oral Surg Oral Med Oral Pathol Oral Radiol Endod* 2000;90:618-23.
13. Mace AT, McLaughlin I, Gibson IW, Clark LJ. Benign ectopic submandibular thyroid with a normotopic multinodular goitre. *J Laryngol Otol* 2003;117:739-40.
14. Kanaya H, Tanigaito Y, Shyono N, Hirabayashi H, Baba K. A rare case of ectopic, normally functioning thyroid tissue presenting as a left submandibular mass. *Nihon Jibiinkoka Gakkai Kaiho* 2005;108:850-3.
15. Huang TS, Chen HY. Dual thyroid ectopia with a normally located pretracheal thyroid gland: Case report and literature review. *Head Neck* 2007;29:885-8.
16. Piantanida E, Compri E, Lai A, Lombardi V, Mule ID, Gandolfo M, *et al.* Ectopic submandibular thyroid tissue with a coexisting normally located multinodular goitre: Case report and review of the literature. *BMJ Case Rep* 2009;2009. pii: Bcr07.2009.2136.
17. Amodi HA, Makki F, Taylor M, Trites J, Bullock M, Hart RD. Lateral ectopic thyroid goiter with a normally located thyroid. *Thyroid* 2010;20:217-20.
18. Kumar R, Sharma S, Marwah A, Moorthy D, Dhanwal D, Malhotra A. Ectopic goiter masquerading as submandibular gland swelling: A case report and review of the literature. *Clin Nucl Med* 2001;26:306-9.
19. Abdallah-Matta MP, Dubarry PH, Pessey JJ, Caron P. Lingual thyroid and hyperthyroidism: A new case and review of the literature. *J Endocrinol Invest* 2002;25:264-7.
20. Zieren J, Paul M, Scharfenberg M, Menenakos C. Submandibular ectopic thyroid gland. *J Craniofac Surg* 2006;17:1194-8.