



Changes in the Normal Infrarenal Aortic Length and Tortuosity in Elderly People

Shin-Seok Yang¹ and Woo-Sung Yun²

¹Division of Vascular Surgery, Department of Surgery, Samsung Medical Center, Sungkyunkwan University School of Medicine, Seoul,

²Division of Transplantation and Vascular Surgery, Department of Surgery, Yeungnam University Medical Center, Yeungnam University College of Medicine, Daegu, Korea

Purpose: To investigate the changes in the infrarenal aortic length and tortuosity in elderly patients.

Materials and Methods: We retrospectively reviewed the medical records and computed tomography (CT) scans of 857 patients who underwent surgery for colorectal cancer between August 2009 and July 2012. Among these patients, 48 patients who were aged ≥ 60 years, underwent follow-up CT at least 5 years after surgery, did not have aortic disease, and did not receive radiation therapy were enrolled. The aortic tortuosity index (ATI) was defined by dividing the distance along the central lumen line from the lowest renal artery to the aortic bifurcation (L1) by the straight-line distance from the lowest renal artery to the aortic bifurcation (L2). Aortic diameters were measured at the lowest renal artery level (D1) and 20 mm below (D2). A paired t-test and Wilcoxon signed-rank test were used to compare lengths and diameters between the initial and final CT scan. Spearman's correlation analysis was performed to determine the correlations between time and the changes in L1 and ATI.

Results: The average follow-up period was 68 months. The mean changes in L1 and L2 were 0.69 mm and -0.59 mm, respectively, while the mean changes in D1 and D2 were 0.77 mm and 0.58 mm, respectively. The mean increase in ATI was 0.015. All findings were statistically significant. On Spearman's correlation analysis, $\Delta L1$ and ΔATI showed no correlation with follow-up duration.

Conclusion: The infrarenal aortic length and tortuosity of elderly patients increases at a slow rate over time.

Key Words: Abdominal aorta, Elongation, Tortuosity

Received September 27, 2019

Revised January 15, 2020

Accepted February 14, 2020

Corresponding author: Woo-Sung Yun

Division of Transplantation and Vascular Surgery, Department of Surgery, Yeungnam University Medical Center, Yeungnam University College of Medicine, 170 Hyeonchung-ro, Nam-gu, Daegu 42415, Korea

Tel: 82-53-620-3580

Fax: 82-53-624-1213

E-mail: wsyun@me.com

<https://orcid.org/0000-0001-8956-8310>

Copyright © 2020, The Korean Society for Vascular Surgery

This is an Open Access article distributed under the terms of the Creative Commons Attribution Non-Commercial License (<http://creativecommons.org/licenses/by-nc/4.0>) which permits unrestricted non-commercial use, distribution, and reproduction in any medium, provided the original work is properly cited.

Vasc Specialist Int 2020;36(1):15-20 • <https://doi.org/10.5758/vsi.2020.36.1.15>

INTRODUCTION

Neck angulation is a major obstacle in endovascular abdominal aortic aneurysm repair (EVAR). There are many possible causes of aortic tortuosity in abdominal aortic aneurysm (AAA) patients. Firstly, there is height loss and vertebral deformity associated with old age [1,2]. Since the aorta is trapped within a limited space, it can begin to

meander if space is reduced. Secondly, if a patient has a fusiform AAA, the aneurysm neck can push the neck away from the spine creating a craniocaudal neck angulation and aortic tortuosity. Finally, marked arterial elongation and tortuosity are a unique character of transforming growth factor- $\beta 2$ mutation related to aortic dissection, aneurysm, and other musculoskeletal deformities [3]. Genetic disorders of such types are uncommon and the most common etiol-

ogy of AAA is degeneration. Even though it is degenerative, longitudinal extension takes place as well as an increase in diameter during aneurysm dilatation. Furthermore, not only the diseased segment of the aorta, but the normal segment may also elongate.

There are few cross-sectional studies that confirm that the aorta in the older population is longer than in younger groups [4,5]. We presumed that the normal segments of the abdominal aorta could elongate with age as a senile change, but the elongation of the disease-free abdominal aorta has not been shown in a cohort study yet. Therefore, we aimed to examine the changes in abdominal aortic length and tortuosity in elderly patients.

MATERIALS AND METHODS

1) Patients

As it was not feasible to enroll healthy adults with long-term serial abdominal computed tomography (CT) scans in this retrospective study, we decided to investigate patients with colorectal cancer. We identified 857 colorectal cancer patients who underwent colorectal surgery in a tertiary hospital from August 2009 to July 2012. Inclusion criteria of this study were 1) age ≥ 60 years and 2) available follow-up abdominal CT at least 5 years from preoperative CT. Exclusion criteria were 1) known aortic aneurysm or dissection and 2) perioperative radiation therapy. A total of 48 patients were eligible for this study. The patient clinical characteristics are presented in Table 1. The mean age of

the patients was 70.4 years and 56.3% was male. Twenty-nine patients (60.4%) received perioperative adjuvant chemotherapy. Before initiation of the study, approval was obtained from the Institutional Review Board of Yeungnam University Hospital (IRB no. 2018-12-029).

2) Measurements

The initial and final CT scans of each patient were re-

Table 1. Patient clinical characteristics (n=48)

Variable	Value
Age (y)	70.4 \pm 5.06 (62-82)
Sex, male	27 (56.3)
Height (cm)	159.0 \pm 8.88
Body weight (kg)	60.5 \pm 9.56
Body mass index (kg/m ²)	24.0 \pm 3.39
Body surface area (m ²)	1.63 \pm 0.157
Smokers	19 (39.6)
Hypertension	21 (43.8)
Diabetes mellitus	11 (22.9)
Coronary artery disease	3 (6.3)
Peripheral artery disease	0 (0.0)
Medications	
Antiplatelet agent	15 (31.3)
Statin	6 (12.5)
Chemotherapy	29 (60.4)

Values are presented as mean \pm standard deviation (range), number (%), or mean \pm standard deviation.

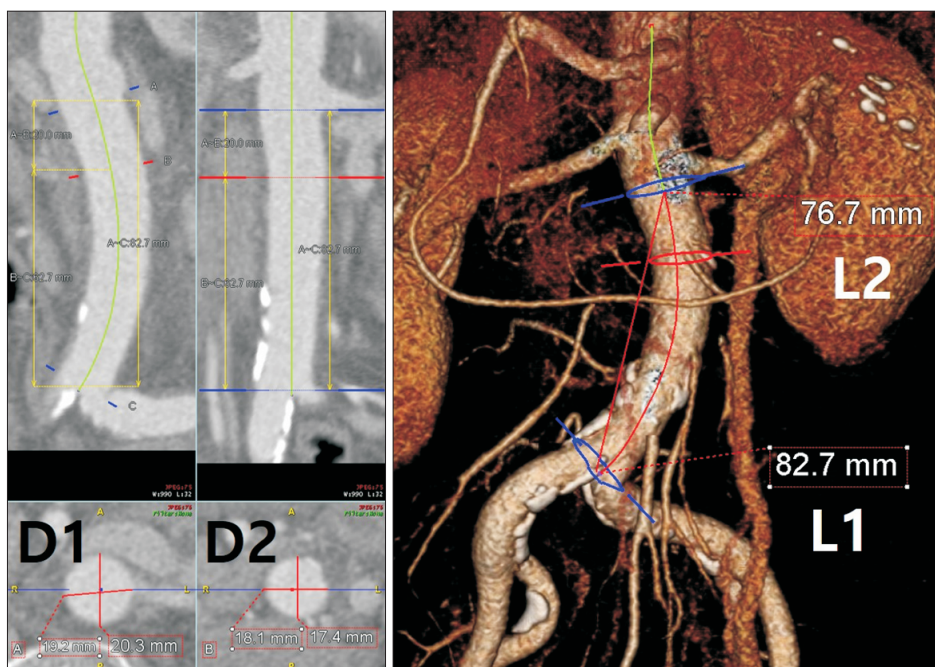


Fig. 1. Measurements of lengths and diameters with Aquarius iNtuition™ (TeraRecon Inc., Foster City, CA, USA). L1 is the aortic length from the lowest renal artery to the aortic bifurcation along the central lumen line. L2 is the length of straight line between the lowest renal artery and the aortic bifurcation. In this case, the calculated aortic tortuosity index is 1.078 (82.7/76.7). D1 and D2 are the aortic diameters at the level of lowest renal artery and 20 mm below, respectively.

viewed. The infrarenal aortic length (L1) was measured from the lowest renal artery to the aortic bifurcation along the central lumen line. The shortest distance (L2) from the lowest renal artery to the aortic bifurcation was measured with the straight-line between both. The aortic tortuosity index (ATI) was defined by dividing L1 by L2 [6]. Aortic diameters were also assessed at the level of the lowest renal artery (D1) and 20 mm below the lowest renal artery (D2). The aortic diameter was measured from the outer wall to the outer wall by images perpendicular to the central lumen line. All the measurements were performed using Aquarius iNtuition™ Ed ver. 4.4.6 (TeraRecon Inc., Foster City, CA, USA) by a single vascular surgeon (Fig. 1). All measurements were first performed on the baseline images and then measurements on the final images were completed.

3) Outcomes

The primary endpoints were the changes in L1, L2, ATI, D1, and D2 ($\Delta L1$, $\Delta L2$, ΔATI , $\Delta D1$, and $\Delta D2$) during the follow-up. The secondary endpoint was the correlation between the follow-up duration and $\Delta L1$ and ΔATI . To adjust

$\Delta L1$ and ΔATI according to the body surface area (BSA), they were divided by the BSA and reanalyzed. All data analysis was performed using IBM SPSS Statistics version 22.0 (IBM Corp., Armonk, NY, USA). A paired t-test and Wilcoxon signed-rank test were used to compare lengths and diameters between the initial and the last CT scans. Spearman's correlation analysis was performed for the secondary endpoints. P-values <0.05 were considered statistically significant.

RESULTS

The mean time interval from the initial CT to the last CT was 68 months (range, 60–102 months). The changes in aortic diameters and lengths are shown in Table 2. There were significant differences in all variables. L1, D1, and D2 tended to increase over time, whereas L2 showed a tendency to decrease. As a result, the postoperative mean ATI increased compared to the initial ATI.

On Spearman's correlation analysis, $\Delta L1$ and ΔATI showed no correlation with follow-up duration (Fig. 2). Similarly, when the variables were adjusted for BSA, no dif-

Table 2. Changes in the infrarenal aortic lengths and diameters

Variable	Initial	Final	Δ	P-value
L1 (mm)	95.12±10.38 (73.6 to 130.0)	95.80±10.86 (73.3 to 132.0)	0.69±1.49 (-3.1 to 5.0)	0.002 ^a
L2 (mm)	90.44±9.82 (70.0 to 124.0)	89.98±9.90 (69.5 to 120.0)	-0.59±2.01 (-5.5 to 4.3)	0.049 ^b
D1 (mm)	18.32±2.00 (14.4 to 24.0)	19.09±2.11 (14.5 to 24.4)	0.77±0.72 (-0.6 to 2.2)	<0.001 ^b
D2 (mm)	18.05±1.77 (14.3 to 21.6)	18.63±2.03 (14.2 to 24.1)	0.58±0.76 (-0.7 to 3.3)	<0.001 ^a
ATI	1.053±0.039 (0.99 to 1.19)	1.067±0.045 (1.00 to 1.24)	0.015±0.019 (-0.02 to 0.06)	<0.001 ^a

Values are presented as mean±standard deviation (range).

ATI, aortic tortuosity index.

^aWilcoxon signed-rank test, ^bpaired t-test.

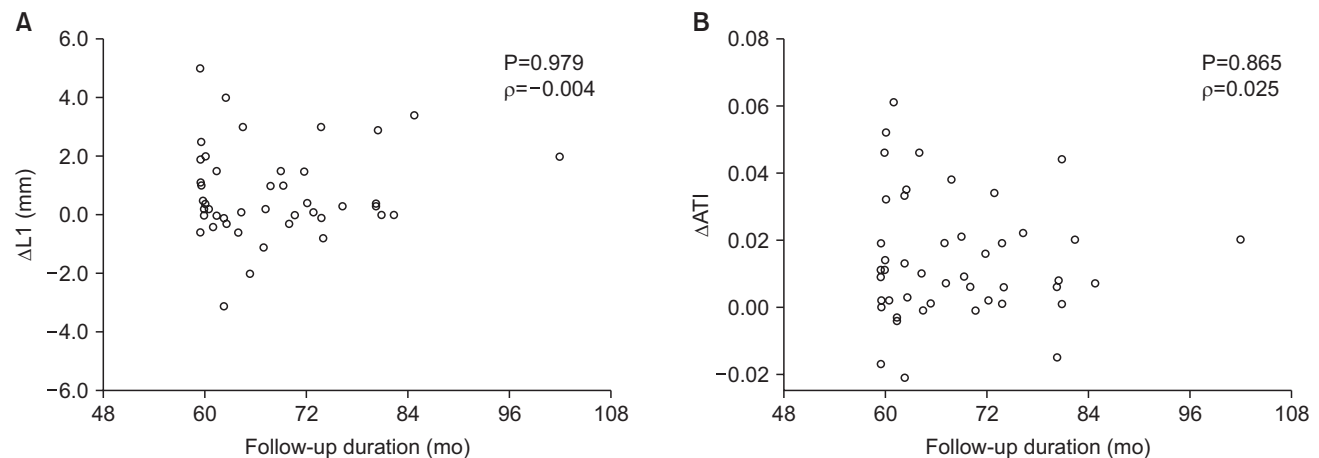


Fig. 2. Scatter plots and Spearman's correlation analyses between the follow-up duration and changes in (A) L1 and (B) aortic tortuosity index (ATI).

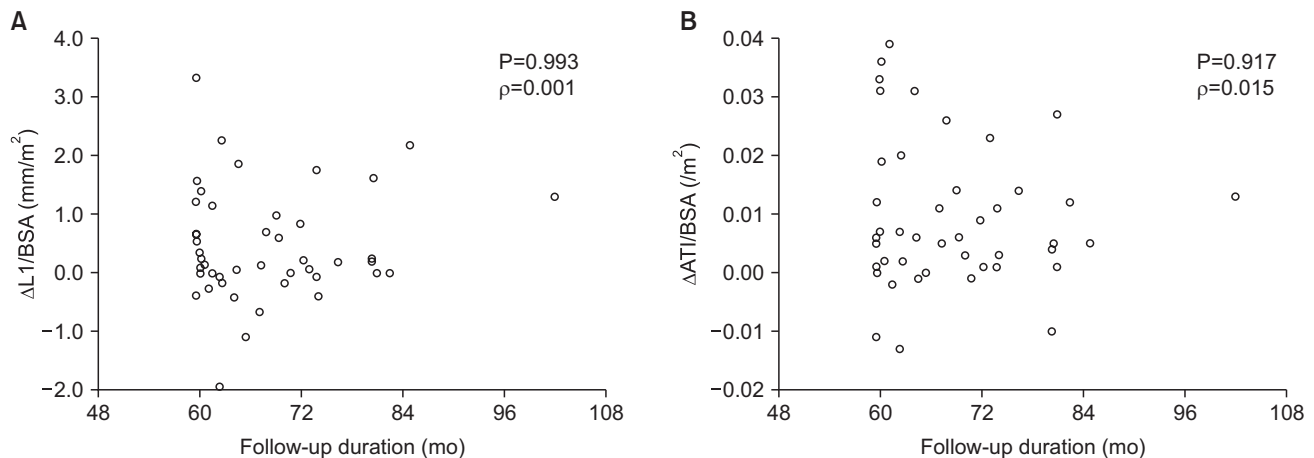


Fig. 3. Scatter plots and Spearman's correlation analyses between the follow-up duration and changes in body surface area (BSA)-indexed (A) L1 and (B) aortic tortuosity index (ATI).

ference was observed in the results (Fig. 3).

DISCUSSION

Currently, there are limited cross-sectional studies which investigate age-related aortic elongation [4,7]. Sugawara et al. [7] performed magnetic resonance image arterial tracing of the aorta in 256 apparently healthy adults (130 males and 126 females, age 19 to 79 years). The length of descending aorta from the top of the aortic arch to the aortic bifurcation was not related to age, whereas the ascending aorta from the sinus of Valsalva to the top of the aortic arch showed a strong positive correlation with age ($\rho=0.72$, $P<0.0001$). However, when the aortic lengths were adjusted for torso length, the descending aorta was only weakly correlated with age ($\rho=0.13$, $P<0.005$).

Another study that analyzed CT scans of aortopathy-free patients, including 101 males and 94 females, aged 20 to 96 years found an increase in the total aortic length associated with age, and the rate was 0.98 ± 0.07 cm/10 years [4]. When the total aorta was divided into 4 segments (the ascending aorta, the aortic arch, the descending thoracic aorta, and the abdominal aorta), the increase in BSA-indexed length was the lowest in the abdominal aorta (1.4% change in males, and 1.5% in females per 10 years) [4].

These 2 studies suggest that the abdominal elongation may increase with age, but not as significantly as the ascending aorta or the aortic arch. There is a further report which showed that the descending aortic elongation is not associated with age [5]. They analyzed chest CT images of 210 consecutive patients without aortic disease or a previous history of cardiothoracic surgery. The BSA-indexed thoracic aortic length showed a significant correlation with age ($\rho=0.54$, $P<0.001$), but the elongation was mainly

caused by the proximal parts of the thoracic aorta. When the entire thoracic aorta was divided into 4 segments, the lengths of the first three segments (the ascending aorta, the aortic arch, and the proximal descending aorta) were related to age, but the length of distal descending aorta (from the level of the pulmonary trunk bifurcation to the diaphragm) did not show a statistically significant correlation with age ($\rho=0.09$, $P=0.178$). They explained 2 possible reasons for this difference; the difference in wall composition between segments and the presence of intercostal arteries. The distal descending aorta contains less elastin than the proximal segments [8] and is fixed to the spine by the intercostal arteries [9]. It is hypothesized that this explanation can also apply to the abdominal aorta.

However, the previously discussed studies were all cross-sectional studies. We were unable to find a longitudinal study within a normal population regarding abdominal aortic elongation. Our study shows that the infrarenal aortic length slowly increases over time in patients ≥ 60 years without aortic disease (mean 0.69 mm for a mean of 68 months, $P=0.002$) and affects the change in ATI. There was no significant correlation between the infrarenal aortic length change and the follow-up duration. The BSA-indexed change in aortic length also failed to show a significant correlation with time. Considering the average annual increase in length as only 0.12 mm/year, a possible explanation could be the difference in the follow-up period among the patients being only 42 months, which was too small to discriminate between the increases in length according to the follow-up duration.

This study began as part of an effort to identify risk factors of AAA neck angulation. We hypothesized that the healthy-looking aortic segment, such as the neck, may elongate and affect the neck angle. Based on the results of

this study, we believe that the natural elongation of the abdominal aorta would have minimal influence on aneurysm neck angulation.

However, the healthy-looking segment in AAA patients may not be completely healthy and AAA patients may have unknown systemic factors stimulating elongation of the normal aorta. We were unable to find any studies investigating the changes in aortic length and angulation in untreated patients with AAA. It has been reported however, that not only the diameter but also the length of the proximal neck increased after EVAR and open repair [10,11]. In fact, these are not natural changes of the aorta as there are several potential factors that have an influence on aortic anatomy such as surgical trauma, sustained outward force from over-sized endograft, and postoperative rheologic modification.

This study has several limitations. Firstly, this has a retrospective study design and a selection bias. All patients had colorectal cancer and underwent surgery. Sixty percent of the patients received chemotherapy, which may affect the outcomes. The second limitation is the small sample size and short follow-up period for the detection of changes in aortic length. In this study, the average change in the infrarenal aortic length during a mean of 68 months was merely 0.69 mm. Although the difference was statistically significant, it may attribute to measurement error. Therefore, a more definitive determination for the changes in the abdominal aortic length should be obtained by much larger and longer-term studies. Despite these limitations, this is

a novel study with a longitudinal design investigating the changes in abdominal aortic length and can be used as a reference for subsequent studies.

CONCLUSION

The infrarenal aortic length and the tortuosity in population ≥ 60 years without aortic disease increases at a slow rate.

CONFLICTS OF INTEREST

The authors have nothing to disclose.

ORCID

Shin-Seok Yang

<https://orcid.org/0000-0003-4957-3080>

Woo-Sung Yun

<https://orcid.org/0000-0001-8956-8310>

AUTHOR CONTRIBUTIONS

Concept and design: WSY. Analysis and interpretation: SSY, WSY. Data collection: SSY. Writing the article: SSY, WSY. Critical revision of the article: WSY. Final approval of the article: SSY, WSY. Statistical analysis: WSY. Obtained funding: none. Overall responsibility: SSY, WSY.

REFERENCES

- 1) Sorkin JD, Muller DC, Andres R. Longitudinal change in height of men and women: implications for interpretation of the body mass index: the Baltimore Longitudinal Study of Aging. *Am J Epidemiol* 1999;150:969-977.
- 2) Masunari N, Fujiwara S, Nakata Y, Nakashima E, Nakamura T. Historical height loss, vertebral deformity, and health-related quality of life in Hiroshima cohort study. *Osteoporos Int* 2007;18:1493-1499.
- 3) van de Luijtgaarden KM, Bastos Gonçalves F, Majoor-Krakauer D, Verhagen HJ. Arterial elongation and tortuosity leads to detection of a de novo TGF- β 2 mutation in a young patient with complex aortic pathology. *Eur Heart J* 2013;34:1133.
- 4) Rylski B, Desjardins B, Moser W, Bavaria JE, Milewski RK. Gender-related changes in aortic geometry throughout life. *Eur J Cardiothorac Surg* 2014;45:805-811.
- 5) Adriaans BP, Heuts S, Gerretsen S, Cheriex EC, Vos R, Natour E, et al. Aortic elongation part I: the normal aortic ageing process. *Heart* 2018;104:1772-1777.
- 6) Walker TG, Kalva SP, Yeddula K, Wicky S, Kundu S, Drescher P, et al. Clinical practice guidelines for endovascular abdominal aortic aneurysm repair: written by the Standards of Practice Committee for the Society of Interventional Radiology and endorsed by the Cardiovascular and Interventional Radiological Society of Europe and the Canadian Interventional Radiology Association. *J Vasc Interv Radiol* 2010;21:1632-1655.
- 7) Sugawara J, Hayashi K, Yokoi T, Tanaka H. Age-associated elongation of the ascending aorta in adults. *JACC Cardiovasc Imaging* 2008;1:739-748.
- 8) Sokolis DP. Passive mechanical properties and structure of the aorta: segmental analysis. *Acta Physiol (Oxf)* 2007;190:277-289.
- 9) Morrison TM, Choi G, Zarins CK, Taylor CA. Circumferential and longitudinal

nal cyclic strain of the human thoracic aorta: age-related changes. *J Vasc Surg* 2009;49:1029-1036.

10) Curl GR, Faggioli GL, Stella A, D'Addato M, Ricotta JJ. Aneurysmal change at or above the proximal anastomosis

after infrarenal aortic grafting. *J Vasc Surg* 1992;16:855-859; discussion 859-860.

11) Litwinski RA, Donayre CE, Chow SL, Song TK, Kopchok G, Walot I, et al. The role of aortic neck dilation and

elongation in the etiology of stent graft migration after endovascular abdominal aortic aneurysm repair with a passive fixation device. *J Vasc Surg* 2006;44:1176-1181.