

This article is licensed under the Creative Commons Attribution-NonCommercial 4.0 International License (CC BY-NC) (<http://www.karger.com/Services/OpenAccessLicense>). Usage and distribution for commercial purposes requires written permission.

Single Case

Overstaged Rectal Cancer by MRI due to Fibrosis Induced by Tattoo Marker

Gorana Gasljevic^a Nina Boc^b Erik Breclj^c Jasna But Hadzic^d
Marko Klancic^e Jernej Mlakar^f

^aDepartment of Pathology, Institute of Oncology Ljubljana, Ljubljana, Slovenia;

^bDepartment of Radiology, Institute of Oncology Ljubljana, Ljubljana, Slovenia;

^cDepartment of Surgery, Institute of Oncology Ljubljana, Ljubljana, Slovenia;

^dDepartment of Radiotherapy, Institute of Oncology Ljubljana, Ljubljana, Slovenia;

^eKlanMedic Diagnostic Center, Sempeter pri Gorici, Slovenia; ^fInstitute of Pathology, Faculty of Medicine, University of Ljubljana, Ljubljana, Slovenia

Keywords

Colorectal cancer · Endoscopic tattooing · MRI · Fibrosis · Staging

Abstract

Endoscopic colorectal tattooing with carbon-based dyes is commonly employed in order to assist with later localization of the lesion. Although carbon is thought to be nontoxic, there usually is some inflammatory reaction with fibrosis and granuloma formation after tissue injection. The aim of this report is to alert to a possible underestimated, late consequence of colorectal carbon-based marker tattooing, namely pronounced fibrosis at the site of the injection that could lead to a blurring and misinterpretation of changes evaluated by radiological techniques. We describe a case of cT stage overestimation due to fibrosis of the rectal wall and perirectal fat, induced by carbon-based dye injection in a 66-year-old patient. In our case it was an overestimation of MR evaluation in the case of early invasive carcinoma. Although there have been some studies on tissue effect of carbon-based dyes, the possible scenario consequence of cancer stage overestimation due to fibrosis has not yet been described. Such a mistake could lead to inappropriate overtreatment. Clinicians must be aware of the possible consequences of dye injection and resultant overestimation of T stage of colorectal cancer. More histological studies concerning histological changes after carbon-based marker tattooing are needed to establish the extent of its significance.

© 2018 The Author(s)
Published by S. Karger AG, Basel

Introduction

Colonic tattooing with carbon-based markers is a widely practiced technique in a wide range of situations wherein a specific portion of the large bowel requires resection and the lesion is not readily apparent by visual examination or palpation. Its value is inestimable in the laparoscopic setting. In the past, india ink was the preferred substance because it provided permanent marking of the colonic lesion. Since india ink preparations contain components that could be toxic, the use of so-called SPOT[®], the only FDA-approved endoscopic marker, has been recommended. Endoscopic tattooing is generally regarded as a safe, accurate, and reliable procedure. The risk of clinical complications is reported to be only 0.22% [1] and they are usually related to the transmural injection. Case reports and small series of adverse effects like focal peritonitis [2, 3], infected hematoma and/or abscess formation [3–5] and tumor cell inoculation [6] have been reported.

Reports about tissue responses on tattoo agent injection and their clinical implications are limited. One of the earliest studies performed by Lane et al. [7] showed that early changes after india ink injections consist of pronounced acute inflammatory reaction with vasculitis and consequent foci of mucosal and submucosal necrosis, while late changes (more than 6 weeks old) included extensive, dense fibrosis or fibroblastic proliferation of the submucosa as well as muscularis propria at the place of previous india ink injection. Different components of india ink solution, lack of its sterility as well as inoculation of intestinal flora into an injection site were suspected to play a role in the development of complications. However, colloidal carbon which is the main component of india ink is assumed to be nontoxic.

The aim of this report is to alert to a possible underestimated, late consequence of colorectal carbon-based marker tattooing, namely pronounced fibrosis at the site of the injection that could lead to a blurring and misinterpretation of changes evaluated by radiological techniques. In our case it was an overestimation of magnetic resonance (MR) evaluation in the case of early invasive carcinoma.

Case Report

A 66-year-old woman was referred to colonoscopy for a positive fecal occult blood test which was performed in the national colorectal cancer screening program. Her medical history was unremarkable. She denied prior overt gastrointestinal bleeding or other gastrointestinal symptoms. Her laboratory tests were unremarkable, including the levels of CEA and CA 19.9 which were normal. Colonoscopy revealed a 70-mm-wide sessile polyp in the rectum located 5 cm from the ano-cutaneous verge. A total of 5 mL of SPOT[®] endoscopic marker was injected circumferentially around the polyp base. Pathological examination of the colonoscopic biopsies revealed tubulovillous adenoma with low-grade epithelial dysplasia and surgical resection was recommended due to its size. As a part of the preoperative planning, the patient underwent magnetic resonance imaging (MRI) of the pelvis that was performed 3.5 months after the colonoscopy. MRI showed a 7 cm large tumor formation of the rectum with restriction of diffusion and focus of the probable invasive growth with penetration of the whole thickness of the bowel wall and incipient infiltration of the mesorectal fat (Fig. 1a). Mesorectal fascia was intact and the lymph nodes were unsuspecting (Fig. 1b). There were no signs of vascular invasion present. The radiological report was signed out as a large adenoma with probable cT3N0 rectal carcinoma. Since pathological and radiological reports were inconsistent, the patient was introduced to a multidisciplinary team consisting of gastro-

enterologist, radiotherapist, and surgeon. Since the lesion was large, reliability of repeated colonoscopic biopsies could be questionable in such a case and MRI showed signs of mesorectal invasion, short regimen irradiation (5 × 5 Gy) of the affected rectal segment was performed and was followed by surgical resection 4 days after the completion of radiotherapy.

Pathological examination of the resection specimen revealed a tubulovillous adenoma with high-grade dysplasia and a focus of invasive adenocarcinoma (Fig. 2a) that penetrated the lamina muscularis mucosae to a depth of only about 1.5 mm. There was no vascular invasion, lymphangiosis or perineural invasion. There were no areas of fibrosis after tumor regression. However, there were areas of fibrosis combined with abundant deposition of coarse clumps of black pigment, corresponding to the carbon-based dye that was previously used as a marker during the endoscopic procedure (Fig. 2b). The pigment was partially extracellular and partially engulfed by macrophages that formed numerous foreign body type granulomas (Fig. 2c). The area of dye deposition spanned the entire thickness of the rectal wall and focally involved some areas of perirectal fat (Fig. 2d). The macrophage infiltration was accompanied by a mild lymphocytic infiltrate and there were no granulocytes.

Discussion

Tattooing of the gastrointestinal tract is used to facilitate the relocation of the biopsy site or other sites at the time of subsequent biopsy or surgery. Submucosal injection of tattooing agents produces a zone of coloration that is grossly visible from both mucosal and serosal surfaces. Traditionally, carbon-based tattooing agents are used; in the past, it was india ink, nowadays so-called SPOT® endoscopic marker is in use. Colloidal carbon which is the main component of carbon-based dyes is supposed to be nontoxic.

Studies concerning histological changes after injection of the carbon-based tattoo markers and tissue responses in the different time periods are occasional. An early experimental study performed by Hammond et al. [8] showed that in comparison with other tattooing agents india ink produces a much more pronounced and significant inflammatory reaction with microhemorrhage and thrombosis. Lane et al. [7] confirmed similar findings in human large bowel specimens in the early period after india ink injection. Pronounced inflammatory reactions with vasculitis and necrosis of the mucosa and submucosa were present, while late changes (more than 6 weeks old) showed an extensive fibrosis of the colonic wall at the site of the previous injection as was noticed in our case. Shatz et al. [9] studied histological changes in biopsy specimens taken from tattoo marks for post-polypectomy surveillance colonoscopy. Altogether, 56 tattoos have been examined. Histology showed mild chronic inflammation in 6 patients and hyperplastic changes in 1 patient, while the majority showed no histological changes. The reason fibrosis was not noticed could be superficial sampling during endoscopic biopsy as well as small size of endoscopic bioptic material. In the study by Askin et al. [10] altogether 113 patients were followed up after SPOT® tattooing. Eighty-two underwent subsequent colonoscopy without biopsy, while 31 of them had segmental resection 1–69 days after tattooing. In 10 resected specimens, the authors described histological changes related to SPOT® injection. No necrosis or abscess formation was found but fibrosis of different degrees (mild, moderate, pronounced) was found in half of the resected specimens (5/10) even in 4 of those who had surgery within 14 days of SPOT® injection.

In our opinion, fibrosis is an underestimated histological consequence of carbon-based marker tattooing. The reason for that lies in the fact that fibrosis is most frequently limited to the colonic wall and to a much lesser extent to pericolic fat tissue (personal observation),

probably in correlation with the depth of injection. These kinds of histological sequelae do not produce any clinical symptoms but could become important in the interpretation of changes visualized by different radiological techniques. Carbon itself is inert and is localized mainly in the macrophages in the lamina propria or submucosa but probably can induce activation of the macrophages with consequential extensive fibrosis, maybe as hypersensitivity reaction to the carbon particles.

Probable carbon-induced fibrosis could also explain a handful of reports describing some of the India ink injection complication in which proliferation of fibrous tissue was described. Two of them included a formation of the inflammatory pseudotumor at the site of injection [11], while in 1 case India ink induced peritoneal adhesions with consequent ileus [12]. Extensive fibrosis was also described in the case of small bowel pseudotumor formation after large bowel tattooing [13].

In conclusion, herein we describe profound fibrosis of the rectal wall at the site of previous tattooing that has resulted in overestimation of changes visualized by MRI and overtreatment of the patient. In our opinion, tattooing with carbon-based markers can induce extensive fibrosis at the site of injection at least in some patients. It is clinically only rarely important but could be a source of incorrect interpretation of MRI and probably other radiological techniques. Such a mistake could lead to inappropriate overtreatment. More histological studies concerning histological changes after carbon-based marker tattooing are needed to establish the extent of its significance.

Statement of Ethics

There were no ethics violations in the writing of this case report; patient confidentiality was maintained.

Disclosure Statement

The authors declare that they have no conflict of interest.

Funding Sources

Publication of the article was financed by the Slovenian Research Agency (ARRS), grant No P3-0289. The funder had no role in study design, data collection and analysis, decision to publish, or preparation of the manuscript.

References

- 1 Nizam R, Siddiqi N, Landas SK, Kaplan DS, Holtzapple PG. Colonic tattooing with India ink: benefits, risks, and alternatives. *Am J Gastroenterol*. 1996 Sep;91(9):1804–8.
- 2 Singh S, Arif A, Fox C, Basnyat P. Complication after pre-operative India ink tattooing in a colonic lesion. *Dig Surg*. 2006;23(5-6):303–6.
- 3 Park SI, Genta RS, Romeo DP, Weesner RE. Colonic abscess and focal peritonitis secondary to india ink tattooing of the colon. *Gastrointest Endosc*. 1991 Jan-Feb;37(1):68–71.
- 4 Marques I, Lagos AC, Pinto A, Neves BC. Rectal intramural hematoma: a rare complication of endoscopic tattooing. *Gastrointest Endosc*. 2011 Feb;73(2):366–7.

- 5 Alba LM, Pandya PK, Clarkston WK. Rectus muscle abscess associated with endoscopic tattooing of the colon with India ink. *Gastrointest Endosc.* 2000 Oct;52(4):557–8.
- 6 Tutticci N, Cameron D, Croese J, Roche E. Peritoneal deposits with carbon pigmentation associated with endoscopic submucosal tattooing of a rectal cancer. *Endoscopy.* 2010;42(S 02 Suppl 2):E136.
- 7 Lane KL, Valleria R, Washington K, Gottfried MR. Endoscopic tattoo agents in the colon. Tissue responses and clinical implications. *Am J Surg Pathol.* 1996 Oct;20(10):1266–70.
- 8 Hammond DC, Lane FR, Welk RA, Madura MJ, Borreson DK, Passinault WJ. Endoscopic tattooing of the colon. An experimental study. *Am Surg.* 1989 Jul;55(7):457–61.
- 9 Shatz BA, Weinstock LB, Swanson PE, Thyssen EP. Long-term safety of India ink tattoos in the colon. *Gastrointest Endosc.* 1997 Feb;45(2):153–6.
- 10 Askin MP, Wayne JD, Fiedler L, Harpaz N. Tattoo of colonic neoplasms in 113 patients with a new sterile carbon compound. *Gastrointest Endosc.* 2002 Sep;56(3):339–42.
- 11 Coman E, Brandt LJ, Brenner S, Frank M, Sablay B, Bennett B. Fat necrosis and inflammatory pseudotumor due to endoscopic tattooing of the colon with india ink. *Gastrointest Endosc.* 1991 Jan-Feb;37(1):65–8.
- 12 Yano H, Okada K, Monden T. Adhesion ileus caused by tattoo-marking: unusual complication after laparoscopic surgery for early colorectal cancer. *Dis Colon Rectum.* 2003 Jul;46(7):987.
- 13 Kochar K, Pai A, Marecik S, Park J, Prasad L: An unusual small bowel mass: india ink tattooing mimicking malignancy. *CRSLS.* 2014 Jan.

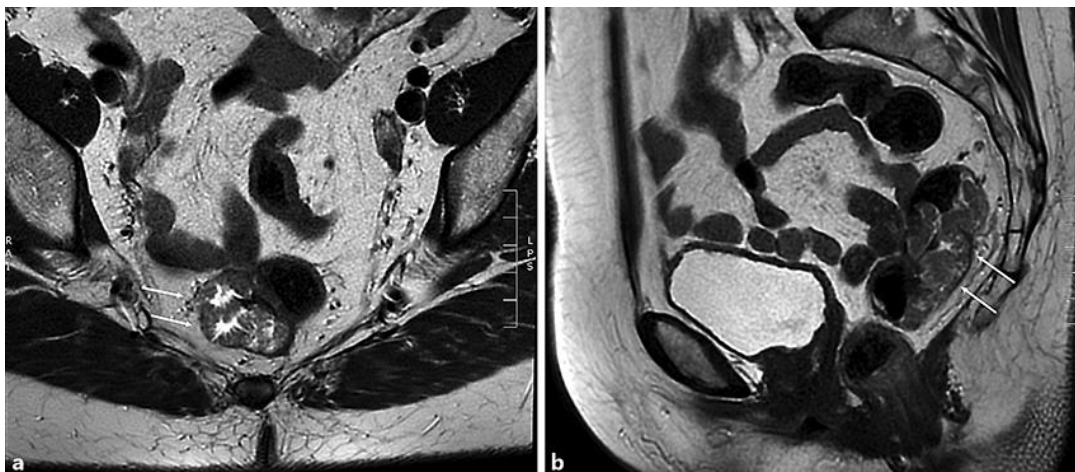

Fig. 1. **a** MRI of the 7 cm large rectal tumor with restriction of diffusion and focus of the probable invasive growth with penetration of the whole thickness of the bowel wall and incipient infiltration of the mesorectal fat. **b** Mesorectal fascia is intact and the lymph nodes are unsuspecting. There are no signs of vascular invasion.

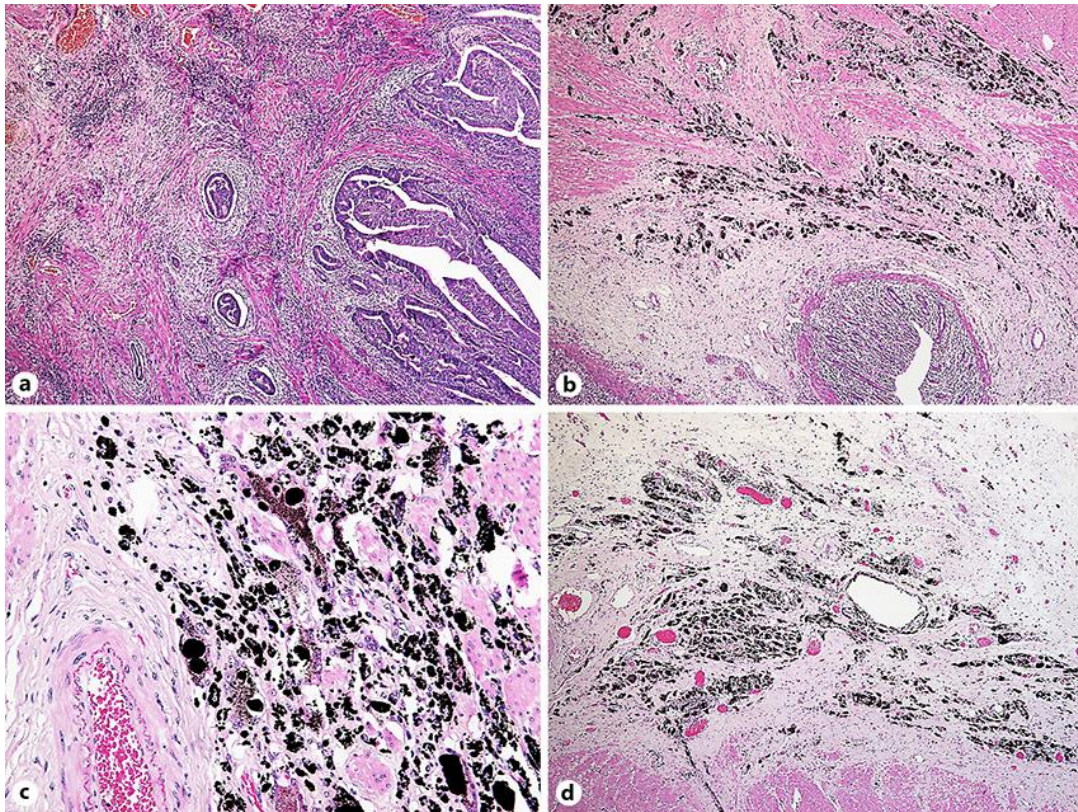


Fig. 2. **a** Tubulovillous adenoma with high-grade dysplasia and a focus of invasive adenocarcinoma. HE. $\times 20$. **b** Area of fibrosis combined with abundant deposition of coarse clumps of black pigment. HE. $\times 20$. **c** The pigment is partially extracellular and partially engulfed by macrophages that form numerous foreign body type granulomas. HE. $\times 40$. **d** The area of dye deposition spans the entire thickness of the rectal wall and focally involves perirectal fat. HE. $\times 20$.