

Persistent Brainstem Dysfunction in Long-COVID: A Hypothesis

Shin Jie Yong*

Cite This: *ACS Chem. Neurosci.* 2021, 12, 573–580

Read Online

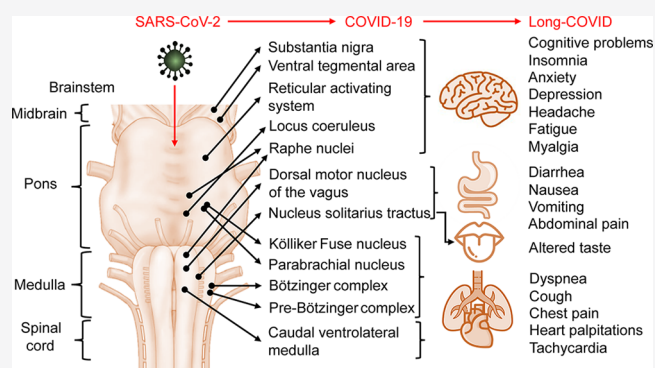
ACCESS |

Metrics & More

Article Recommendations

ABSTRACT: Long-COVID is a postviral illness that can affect survivors of COVID-19, regardless of initial disease severity or age. Symptoms of long-COVID include fatigue, dyspnea, gastrointestinal and cardiac problems, cognitive impairments, myalgia, and others. While the possible causes of long-COVID include long-term tissue damage, viral persistence, and chronic inflammation, the review proposes, perhaps for the first time, that persistent brainstem dysfunction may also be involved. This hypothesis can be split into two parts. The first is the brainstem tropism and damage in COVID-19. As the brainstem has a relatively high expression of ACE2 receptor compared with other brain regions, SARS-CoV-2 may exhibit tropism therein. Evidence also exists that neuropilin-1, a co-receptor of SARS-CoV-2, may be expressed in the brainstem. Indeed, autopsy studies have found SARS-CoV-2 RNA and proteins in the brainstem. The brainstem is also highly prone to damage from pathological immune or vascular activation, which has also been observed in autopsy of COVID-19 cases. The second part concerns functions of the brainstem that overlap with symptoms of long-COVID. The brainstem contains numerous distinct nuclei and subparts that regulate the respiratory, cardiovascular, gastrointestinal, and neurological processes, which can be linked to long-COVID. As neurons do not readily regenerate, brainstem dysfunction may be long-lasting and, thus, is long-COVID. Indeed, brainstem dysfunction has been implicated in other similar disorders, such as chronic pain and migraine and myalgic encephalomyelitis or chronic fatigue syndrome.

KEYWORDS: Long-COVID, coronavirus, brainstem, tropism, nervous system, brain autopsy



1. INTRODUCTION

The severe acute respiratory syndrome coronavirus 2 (SARS-CoV-2) is arguably one of the most highly infectious viruses faced by humankind. Nearing the end of 2020, the coronavirus disease 2019 (COVID-19) pandemic, caused by SARS-CoV-2, has exceeded 70 million cases with nearly two million deaths worldwide (www.worldometers.info/coronavirus/). About 81% of COVID-19 cases are asymptomatic and mild, which takes about 2 weeks to recover. In contrast, severe pneumonia and critical multiorgan failure happen to 14% and 5% of cases, respectively, that last for 3–6 weeks.^{1,2} However, a sizable proportion of COVID-19 survivors do not fully recover and suffer a postviral syndrome known as long-COVID (or long-haul COVID-19), despite being released from the hospital and tested negative for SARS-CoV-2.^{3,4}

While the official medical definition or diagnostic criteria remains unconfirmed, the current description of long-COVID is the ongoing symptoms of fatigue, dyspnea, headache, cognitive impairments, cough, joint and chest pains, mood alterations, smell and taste dysfunction, and myalgia that persist for at least 4 weeks after symptom onset or hospital discharge.^{5–8} Studies conducting follow-ups on survivors of COVID-19 have reported that 30–80% of them will develop symptoms of long-COVID

lasting for 1–6 months. Such studies have also found that long-COVID can happen to anyone, even in young adults, students, children, and those who had only mild COVID-19 that needed neither respiratory support nor hospital care.^{9–18}

This raises an intriguing question: Why does COVID-19, even when mild, turn into long-COVID in about 30–80% of the time? Common explanations thus far are residual tissue damage, viral persistence, and chronic inflammation that remain unresolved from acute COVID-19.^{3,5,6,19,20} However, one more potential cause of long-COVID, which has not been discussed in detail elsewhere, could be the brainstem tropism of SARS-CoV-2 and the resulting persistent, low-grade brainstem dysfunction.

Received: December 14, 2020

Accepted: February 1, 2021

Published: February 4, 2021

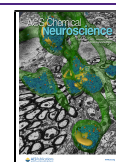


Table 1. Autopsy Studies Investigating Specific Brain Regions, with Emphasis on the Brainstem or Medulla Oblongata

study	brain samples from deceased COVID-19 patients	notable autopsy findings
38	Whole brain from 1 patient (male; 73 years; New York, U.S.).	Shrunken neurons, infarcts, and inflammation present in several brain regions, including the medulla. Positive SARS-CoV-2 RNA in olfactory bulb and cerebellum but not medulla.
67	Whole brain from 5 patients (42–84 years; 2 males and 3 females; Washington, U.S.).	Hemorrhages present in the brainstem of 1 patient.
68	Olfactory nerve, gyrus rectus, and brainstem's medulla from 1 patient (male; 54 years; Milan, Italy).	Numerous viral-like particles and tissue damage were present in olfactory nerves, gyrus rectus, and medulla.
39	Whole brain from 7 patients (6 males and 1 female; 54–96 years; Basel, Switzerland).	Pronounced inflammation (microglial and astrocytic activations) in the olfactory bulb, pons, brainstem, and medulla in 2 representative patients. Positive SARS-CoV-2 RNA in the olfactory bulb and optic nerve of 4 and 2 patients, respectively. Negative SARS-CoV-2 RNA in brainstem and cerebellum in all cases.
40	Whole brain from 10 patients (7 males and 3 females; 51–74 years; Bologna, Italy).	Positive SARS-CoV-2 RNA in the olfactory nerve and brain of 1 patient. Pronounced microthrombi in the basal ganglia and brainstem of all patients.
69	Whole brain from 2 patients (2 males; 70–79 years; Zurich, Switzerland).	Pronounced inflammation (leukocyte infiltration) and microthrombosis in olfactory epithelium and nerves, and the basal ganglia in both patients.
36	Whole brain from 43 patients (27 males and 16 females; 51–94 years; Hamburg, Germany).	Pronounced inflammation (leukocyte infiltration and microglial and astrocytic activations) in most cases that were most evident in the cerebellum and medulla. Positive SARS-CoV-2 RNA in the frontal lobe (9 out of 23 patients) and brainstem (4 out of 8 patients). Positive SARS-CoV-2 nucleocapsid or spike protein in the medulla and its neural connections (glossopharyngeal or vagal cranial nerves) in 16 out of 40 patients.
37	Olfactory mucosa and specific brain regions from 33 patients (22 males and 11 females; 67–79 years; Berlin, Germany).	Positive SARS-CoV-2 RNA in olfactory mucosa (20 out of 30 patients), cerebellum (3 out of 24 patients), and medulla (6 out of 31) samples. Positive SARS-CoV-2 spike S1 protein in olfactory mucosa–neuronal junction. Pronounced inflammation (leukocyte infiltration and microglial activation; 13 out of 25 patients) and microthrombi (6 out of 33 patients) in the brain.
42	Whole brain from 9 patients from a sample of 21 patients (16 males and 5 females; 41–78 years; Amsterdam, Netherlands).	Pronounced inflammation (leukocyte infiltration and microglial and astrocytic activations) was most evident in the olfactory bulb and medulla in all cases.
35	20 brain sections from various brain regions from 2 patients (2 males; 50–71 years; Massachusetts; U.S.).	Ambiguous viral infection (<5 copies/mm ³ of SARS-CoV-2 RNA) in 9 sections, of which 4 sections belonged to the medulla. Negative viral infection in the remaining 11 sections.
	32 brain sections (16 from the frontal lobe and olfactory nerve and 16 from the brainstem's medulla) from 16 patients (12 males and 4 females; 48–90 years; Massachusetts; U.S.).	Positive viral infection (>5 copies/mm ³ of SARS-CoV-2 RNA) in 6 sections (3 from the frontal lobe and olfactory nerve and 3 from the medulla). Ambiguous and negative viral infection in 20 and 6 sections, respectively.
34	Whole brain from 6 patients (4 males and 2 females; 58–82 years; Munich, Germany).	Perivascular and interstitial encephalitis and neurodegeneration of brainstem's solitary, dorsal raphe nucleus, and neural connections (i.e., dorsal motor nuclei of the vagus nerve, olfactory and trigeminal nerves, and fasciculus longitudinalis medialis) in all samples. Hypoxia-prone regions such as the neocortex, hippocampus, and cerebellum were not extensively damaged.

2. SARS-COV-2 TROPISM FOR THE BRAINSTEM

It is widely known that SARS-CoV-2 is a neurotropic virus with the capacity to infect and replicate in neuronal cell cultures, brain organoids, and murine brains.^{21–23} This is in line with the high rate of neuropsychiatric or neurological symptoms (e.g., cognitive and mood impairments, headache, smell and taste alterations, fatigue, and myalgia) among cases of COVID-19 and other pathogenic human coronaviruses.^{24–26} Even mild COVID-19 cases exhibit these neurological signs, indicating that brain involvement may occur in the early phase of COVID-19.²⁷ Moreover, SARS-CoV-2 RNA has been found in the brain in 30–40% of cases during autopsy of deceased COVID-19 patients.^{28–30} However, other autopsy studies found no histological alterations or SARS-CoV-2 materials in the brain of COVID-19 victims.^{31–33} This suggests that SARS-CoV-2 neurotropism or brain invasion can happen but not in every case.

More interestingly, autopsy studies examining specific brain regions have found evidence of brainstem involvement in COVID-19, such as inflammatory responses, neurodegeneration, and viral invasion (Table 1). For example, in six victims of COVID-19, brain autopsies have identified pronounced neurodegeneration in the brainstem and its neural connections in every case examined. Importantly, this study ruled out hypoxia as the cause of brainstem damage as other brain areas more

susceptible to hypoxia were not significantly injured. Thus, either pathological immune responses or SARS-CoV-2 invasion of the brainstem was suspected.³⁴ Another autopsy study has isolated 32 brain sections from 16 victims of COVID-19 and found concentrated SARS-CoV-2 RNA (>5 copies/mm³) in three sections from the olfactory nerves and the brainstem's medulla.³⁵ More convincingly, in another autopsy study of deceased COVID-19 patients, SARS-CoV-2 RNA and proteins (nucleocapsid or spike) were detected in 50% and 40% of brainstem samples, respectively.³⁶ Similarly, another autopsy study has found SARS-CoV-2 RNA and spike proteins in the olfactory mucosal-neuronal junction and brainstem's medulla in 67% and 19% of samples, respectively.³⁷ In sum, these autopsy studies have provided evidence for SARS-CoV-2 tropism from the olfactory system into the brainstem.

However, in other instances, brainstem neuropathology was observed despite the absence of SARS-CoV-2 RNA in brain autopsy of deceased COVID-19 patients.^{38–40} This suggests that COVID-19 may induce brainstem damage through methods besides SARS-CoV-2 invasion, such as pathological immune or vascular activation. For example, leukocyte infiltration, activation of resident microglia and astrocytes, and microthrombosis have been observed in brain autopsies of COVID-19 victims, particularly at the brainstem.^{37,39,41,42} Indeed, the brainstem is known to be highly vulnerable to

acute and chronic damage from various sources, including inflammation, trauma, metabolic alterations, or vascular injury.⁴³ Taken together, SARS-CoV-2 may damage the brainstem through viral invasion, inflammation, and vascular activation⁴⁴ (Table 1, Figure 1).

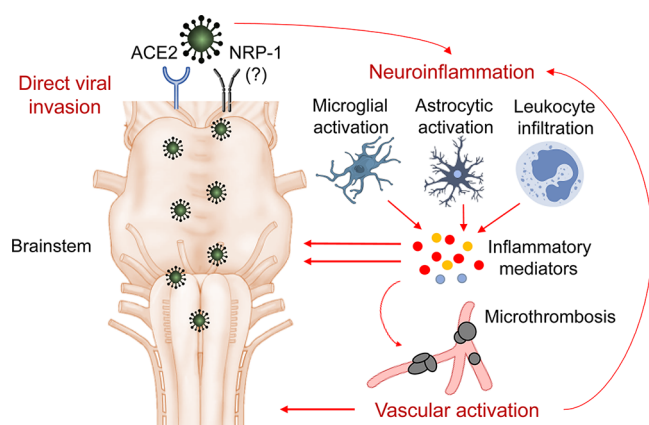


Figure 1. Mechanisms of SARS-CoV-2-induced brainstem dysfunction. For one, SARS-CoV-2 may invade the brainstem directly via the surface expression of angiotensin-converting enzyme 2 (ACE2) and possibly neuropilin-1 (NRP-1) receptors. SARS-CoV-2 or COVID-19 may also initiate neuroinflammation via microglial and astrocytic activation and leukocyte infiltration through the blood–brain barrier. These would lead to the production of inflammatory mediators, which damage the brainstem and vascular cells. The resulting microthrombosis from vascular injury may further potentiate neuroinflammation and brainstem dysfunction.

Angiotensin-converting enzyme 2 (ACE2) is the receptor SARS-CoV-2 uses to infect cells.^{45,46} The brainstem also expresses ACE2, which may explain the SARS-CoV-2 tropism therein. Indeed, ACE2 mRNA and proteins have been found in neurons and astrocytes of the murine brainstem.^{47–49} A study analyzing tissues collected from 21 distinct human brain regions has discovered high ACE2 expression in the cerebral cortex, amygdala, and brainstem. Importantly, the brainstem’s pons and medulla have the highest expression of ACE2.⁵⁰ More recently, neuropilin-1 has been confirmed as a co-receptor that facilitates SARS-CoV-2 infection into cells, especially in the olfactory epithelium where ACE2 expression is relatively low.^{51,52} Interestingly, neuropilin-1 is also expressed in the brainstem of developing animal brains.^{53,54} Thus, the mature brainstem may also express neuropilin-1 that promotes SARS-CoV-2 infection.

Prior pathogenic severe acute respiratory syndrome (SARS) and Middle East respiratory syndrome (MERS) coronaviruses have also shown a predilection to target and damage the brainstem in murine experiments.^{55–58} Intriguingly, a proportion of SARS and MERS survivors also face long-lasting postviral illnesses that last for years.^{24,59–61} Therefore, it is not a surprise that SARS-CoV-2 evolved a similar tropism feature and the capacity to induce postviral long-COVID. The putative pathways by which SARS-CoV-2 invades the brainstem involve trans-synaptic transfer via peripheral, olfactory, or cranial nerves and blood–brain-barrier (BBB) penetration from systemic circulation.^{62–66}

3. BRAINSTEM FUNCTIONS OVERLAP WITH LONG-COVID SYMPTOMS

Others have also raised the idea of SARS-CoV-2 tropism for the brainstem as a possible cause of respiratory failure in COVID-19. This is because the brain’s cardiorespiratory center is located in the brainstem.^{70–75} However, the brainstem consisting of the medulla, pons, and midbrain also plays other roles besides respiratory regulation, such as maintaining cardiovascular, gastrointestinal, and neurological processes (Figure 2). Since

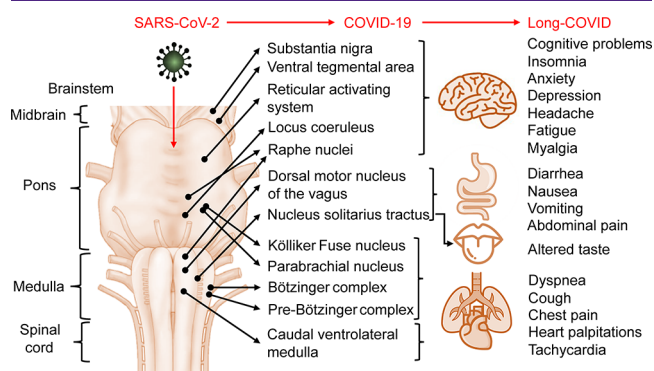


Figure 2. Overview of the brainstem dysfunction hypothesis in long-COVID. Note that nuclei and subparts of the brainstem’s medulla, pons, and midbrain are not drawn to scale and may not reflect the exact neuroanatomical structures. Abbreviations used are the following: ACE2, angiotensin-converting enzyme 2; COVID-19, coronavirus disease 2019; NRP-1, neuropilin-1; SARS-CoV-2, severe acute respiratory syndrome coronavirus 2.

both peripheral and central neuronal injury may be permanent and regeneration is extremely rare and slow,^{76–78} brainstem injury may be long-lasting as well. Interestingly, functions of the brainstem and symptoms of long-COVID overlap to a great extent (Figure 2).

For one, up to 30–50% of COVID-19 survivors experience persistent dyspnea and cough for 2–3 months.^{13,15,79–81} Chest pain, heart palpitations, and tachycardia are also common symptoms of long-COVID that occur in about 20–40% of survivors.^{13,82} Notably, the brain’s respiratory and cardiovascular neuron circuits are closely intertwined in the brainstem.⁸³ The ventral respiratory column (VRC) in the medulla harbors the Bötzing and pre-Bötzing complexes, which control rhythmic breathing during expiration and inspiration, respectively.^{84,85} The brainstem also contains the pontine respiratory group (PRG), where the parabrachial and Kölliker Fuse nuclei reside and control transition between expiration and inspiration.⁸⁶ In addition, the brainstem has the caudal ventrolateral medulla (CVLM) that contains neurons responsible for regulating heart rhythms.^{87,88} Hence, persistent brainstem dysfunction at the level of VRC, PRG, and CVLM may explain the cardiorespiratory-related symptoms of long-COVID.

About 25–30% of COVID-19 survivors may also experience gastrointestinal symptoms, such as nausea, vomiting, diarrhea, and abdominal pain, for 2–3 months after hospital discharge.^{82,89} Interestingly, the nucleus tract solitaries (NTS) and dorsal motor nucleus of the vagus (DMV) of the brainstem have afferent and efferent neuronal projections, respectively, with the gastrointestinal tract to regulate motility and secretion.^{90,91} Dysfunction of these brainstem areas may, therefore, lead to diarrhea, vomiting, and abdominal pain. While receiving afferent neurons from the gastrointestinal tract,

the NTS also has neural connections to higher-order brain areas (e.g., amygdala, insula, and anterior cingulate cortex), which may convey nausea sensation.^{92,93}

Long-COVID entails a myriad of neurological symptoms that may happen to 20–70% of COVID-19 survivors, such as fatigue, myalgia, insomnia, headache, depression, anxiety, smell and taste alterations, and cognitive impairments.^{10–13,15} The brainstem has gustatory neurons within the NTS that relay neural information from taste buds into the gustatory cortex.⁹⁴ While dysfunction of this area may explain the altered taste perception in long-COVID, the associated smell malfunction may be attributed to olfactory bulb damage commonly observed in COVID-19 autopsy (Table 1). Moreover, the reticular activation system (RAS) in the brainstem controls the sleep–wake cycle and executive attention.⁴³ The brainstem also harbors the raphe nuclei and locus coeruleus, the brain's primary source of serotonergic and noradrenergic neurons, respectively.^{95,96} The ventral tegmental area and substantia nigra also reside in the brainstem's midbrain, which supplies dopaminergic neurons to the higher brain regions.^{97,98} These neurotransmitters stemming from the brainstem have been implicated in a broad range of neurological disorders, including depression, anxiety, sleep and cognitive impairments, headache, fatigue, myalgia, and pain perception.^{99–102} Therefore, SARS-CoV-2 invasion into the brainstem may disrupt neurotransmitter systems in the brain, resulting in diverse neurological symptoms.

4. PERSISTENT LOW-GRADE BRAINSTEM DYSFUNCTION IN LONG-COVID

Taken together, it can be hypothesized that brainstem dysfunction may be involved in the pathology of long-COVID. However, one major caveat to this hypothesis is the ambiguity in the magnitude of brainstem dysfunction. Disruption to the brainstem, particularly at the respiratory pacemaker pre-Bötzinger complex, has been proved to be lethal, resulting in neurogenic respiratory failure and death.^{43,71,103} Moreover, primary brainstem injury from traumatic brain impact has a high mortality rate.¹⁰⁴ It has also been proposed that sudden infant death syndrome (SIDS) results from failure of the medullary serotonergic system in the brainstem.^{105,106} Other severe and life-threatening clinical outcomes associated with brainstem damage include dysautonomia, consciousness disorders (e.g., coma and delirium), and brain death.^{43,107} Hence, it may be difficult to conceive the involvement of brainstem dysfunction in chronic or persistent conditions such as long-COVID.

However, brainstem dysfunction has also been implicated in the pathophysiology of chronic disorders. For one, brain imaging studies have identified altered diffusivity and functional connectivity in the brainstem among participants with chronic musculoskeletal and neuropathic pain.^{108–110} The involvement of brainstem dysfunction in chronic migraine or headache in humans has also been widely demonstrated.^{111–114} Notably, long-COVID resembles and is closely associated with myalgic encephalomyelitis or chronic fatigue syndrome (ME/CFS), characterized by fatigue, myalgia, and cognitive and sleep impairments.^{115,116} Interestingly, brain imaging research has found that symptom severity of ME/CFS associates and correlates with brainstem dysfunction, particularly at the RAS.^{117–121} Thus, brainstem dysfunction may result in fatal or persistent disease, of which the latter may include long-COVID (Figure 3).

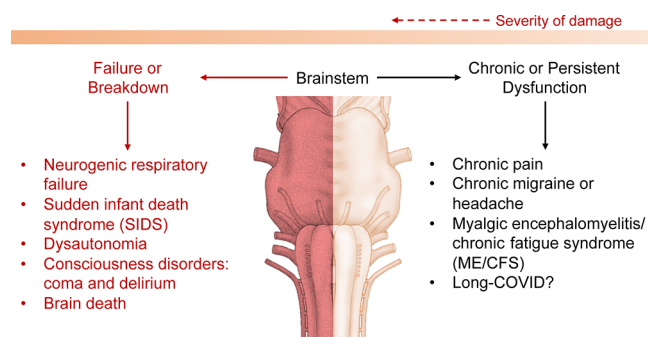


Figure 3. Overview of the disorders related to brainstem dysfunction, which can be fatal or persistent. Note that darker shades of red/orange indicate more severe conditions.

5. CONCLUDING REMARKS

This review emphasized that the brainstem may be an overlooked aspect of long-COVID. In acute COVID-19, brainstem damage has been widely documented in autopsy studies. A few autopsy reports have even found SARS-CoV-2 genes and proteins in the brainstem, indicative of viral tropism and invasion. Indeed, the brainstem has a relatively high expression of ACE2 receptor, and possibly neuropilin-1, that SARS-CoV-2 exploits for cell infection. As neurological manifestations appear even in mild cases of COVID-19, the brainstem could be affected in the early disease phase. Since neurons rarely regenerate, the brainstem damage from COVID-19 may be long-lasting. Following this, the respiratory, cardiovascular, gastrointestinal, and neurological functions of the brainstem may get compromised indefinitely. Interestingly, these systems are also suspected to have malfunctioned in long-COVID. Indeed, brainstem dysfunction has also been implicated in other chronic disorders, such as chronic pain and migraine and ME/CFS. Therefore, it can be hypothesized that long-COVID may stem from persistent brainstem dysfunction.

In line with this, only one study to date has discovered persistent structural brain changes (e.g., cingulate gyrus, olfactory cortex, and hippocampus) among long-COVID survivors that were discharged from the hospital 3 months ago; unfortunately, this study did not examine the brainstem due to technological limitations.¹¹ In conclusion, future studies involving long-COVID may be interested in probing the brainstem dysfunction hypothesis further, such as performing brain imaging, neurophysiological assessments, and reflex (e.g., cough, pupillary light, or corneal reflexes) and auditory response tests to detect any brainstem abnormalities.^{43,64,121}

■ AUTHOR INFORMATION

Corresponding Author

Shin Jie Yong – Department of Biological Sciences, Sunway University, Petaling Jaya, Selangor 47500, Malaysia;
 orcid.org/0000-0001-9752-8386;
 Phone: +60178487513; Email: shin.y7@imail.sunway.edu.my

Complete contact information is available at:
<https://pubs.acs.org/10.1021/acscchemneuro.0c00793>

Author Contributions

S.J.Y. confirms that he is the sole author of this paper.

Funding

No funding was received for this work.

Notes

The author declares no competing financial interest.

ACKNOWLEDGMENTS

The author thanks the editor and peer-reviewers involved in the publication process of this paper.

REFERENCES

- (1) Cascella, M., Rajnik, M., Cuomo, A., Dulebohn, S. C., and Di Napoli, R. (2020) Features, Evaluation, and Treatment of Coronavirus. In *StatPearls*; StatPearls Publishing, Treasure Island, FL.
- (2) Hu, B., Guo, H., Zhou, P., and Shi, Z. L. (2020) Characteristics of SARS-CoV-2 and COVID-19. *Nat. Rev. Microbiol.*, DOI: 10.1038/s41579-020-00459-7.
- (3) Nath, A. (2020) Long-Haul COVID. *Neurology* 95 (13), 559–560.
- (4) Rubin, R. (2020) As Their Numbers Grow, COVID-19 “Long Haulers” Stump Experts. *JAMA* 324 (14), 1381–1383.
- (5) Yong, S. J. (2020) Long-Haul COVID-19: Putative Pathophysiology, Risk Factors, and Treatments. *Preprints*, DOI: 10.20944/preprints202012.0242.v1.
- (6) Greenhalgh, T., Knight, M., A’Court, C., Buxton, M., and Husain, L. (2020) Management of Post-Acute COVID-19 in Primary Care. *BMJ*. 370, m3026.
- (7) Yelin, D., Margalit, I., Yahav, D., Runold, M., and Bruchfeld, J. (2020) Long COVID-19 - It’s not Over Until? *Clin. Microbiol. Infect.*, DOI: 10.1016/j.cmi.2020.12.001.
- (8) Datta, S. D., Talwar, A., and Lee, J. T. (2020) A Proposed Framework and Timeline of the Spectrum of Disease Due to SARS-CoV-2 Infection: Illness Beyond Acute Infection and Public Health Implications. *JAMA* 324 (22), 2251–2252.
- (9) Ludvigsson, J. F. (2020) Case Report and Systematic Review Suggest that Children may Experience Similar Long-Term Effects to Adults After Clinical COVID-19. *Acta Paediatr.*, DOI: 10.1111/apa.15673.
- (10) Townsend, L., Dyer, A. H., Jones, K., Dunne, J., Mooney, A., Gaffney, F., O’Connor, L., Leavy, D., O’Brien, K., Dowds, J., et al. (2020) Persistent Fatigue Following SARS-CoV-2 Infection is Common and Independent of Severity of Initial Infection. *PLoS One* 15 (11), e0240784.
- (11) Lu, Y., Li, X., Geng, D., Mei, N., Wu, P. Y., Huang, C. C., Jia, T., Zhao, Y., Wang, D., Xiao, A., and Yin, B. (2020) Cerebral Micro-Structural Changes in COVID-19 Patients - An MRI-based 3-month Follow-up Study. *EclinicalMedicine* 25, 100484.
- (12) van den Borst, B., Peters, J. B., Brink, M., Schoon, Y., Bleeker-Rovers, C. P., Schers, H., van Hees, H. W. H., van Helvoort, H., van den Boogaard, M., and van der Hoeven, H. (2020) Comprehensive Health Assessment Three Months After Recovery from Acute COVID-19. *Clin. Infect. Dis.*, DOI: 10.1093/cid/ciaa1750.
- (13) Carfi, A., Bernabei, R., and Landi, F. (2020) Persistent Symptoms in Patients After Acute COVID-19. *JAMA* 324 (6), 603–605.
- (14) Walsh-Messinger, J., Manis, H., Vrabec, A., Sizemore, J., Bishof, K., Debidda, M., Malaspina, D., and Greenspan, N. (2020) The Kids Are Not Alright: A Preliminary Report of Post-COVID Syndrome in University Students. *medRxiv*, DOI: 10.1101/2020.11.24.20238261.
- (15) Mandal, S., Barnett, J., Brill, S. E., Brown, J. S., Denny, E. K., Hare, S. S., Heightman, M., Hillman, T. E., Jacob, J., and Jarvis, H. C. (2020) ‘Long-COVID’: A Cross-Sectional Study of Persisting Symptoms, Biomarker and Imaging Abnormalities Following Hospitalisation for COVID-19. *Thorax*, DOI: 10.1136/thoraxjnl-2020-215818.
- (16) Petersen, M. S., Kristiansen, M. F., Hanusson, K. D., Danielsen, M. E., á Steig, B., Gaini, S., Strom, M., and Weihe, P. (2020) Long COVID in the Faroe Islands - A Longitudinal Study Among Non-Hospitalized Patients. *Clin. Infect. Dis.*, DOI: 10.1093/cid/ciaa1792.
- (17) Townsend, L., Dowds, J., O’Brien, K., Sheill, G., Dyer, A. H., O’Kelly, B., Hynes, J. P., Mooney, A., Dunne, J., and Ni Cheallaigh, C. (2021) Persistent Poor Health Post-COVID-19 Is Not Associated with Respiratory Complications or Initial Disease Severity. *Ann. Am. Thorac. Soc.*, DOI: 10.1513/AnnalsATS.202009-1175OC.
- (18) Taboada, M., Carinena, A., Moreno, E., Rodriguez, N., Dominguez, M. J., Casal, A., Riveiro, V., Diaz-Vieito, M., Valdes, L., Alvarez, J., and Seoane-Pillado, T. (2020) Post-COVID-19 Functional Status six-months After Hospitalization. *J. Infect.*, DOI: 10.1016/j.jinf.2020.12.022.
- (19) Baig, A. M. (2020) Deleterious Outcomes in Long-Hauler COVID-19: The Effects of SARS-CoV-2 on the CNS in Chronic COVID Syndrome. *ACS Chem. Neurosci.* 11, 4017.
- (20) Dani, M., Dirksen, A., Taraborrelli, P., Torocastro, M., Panagopoulos, D., Sutton, R., and Lim, P. B. (2021) Autonomic Dysfunction in ‘Long COVID’: Rationale, Physiology and Management Strategies. *Clin. Med.* 21, e63.
- (21) Chu, H., Chan, J. F.-W., Yuen, T. T.-T., Shuai, H., Yuan, S., Wang, Y., Hu, B., Yip, C. C.-Y., Tsang, J. O.-L., Huang, X., et al. (2020) Comparative Tropism, Replication Kinetics, and Cell Damage Profiling of SARS-CoV-2 and SARS-CoV with Implications for Clinical Manifestations, Transmissibility, and Laboratory Studies of COVID-19: An Observational Study. *Lancet Microbe* 1 (1), e14–e23.
- (22) Sun, S. H., Chen, Q., Gu, H. J., Yang, G., Wang, Y. X., Huang, X. Y., Liu, S. S., Zhang, N. N., Li, X. F., Xiong, R., et al. (2020) A Mouse Model of SARS-CoV-2 Infection and Pathogenesis. *Cell Host Microbe* 28 (1), 124–133.
- (23) Zhang, B. Z., Chu, H., Han, S., Shuai, H., Deng, J., Hu, Y. F., Gong, H. R., Lee, A. C., Zou, Z., Yau, T., et al. (2020) SARS-CoV-2 Infects Human Neural Progenitor Cells and Brain Organoids. *Cell Res.* 30 (10), 928–931.
- (24) Rogers, J. P., Chesney, E., Oliver, D., Pollak, T. A., McGuire, P., Fusar-Poli, P., Zandi, M. S., Lewis, G., and David, A. S. (2020) Psychiatric and Neuropsychiatric Presentations Associated with Severe Coronavirus Infections: A Systematic Review and Meta-Analysis with Comparison to the COVID-19 Pandemic. *The Lancet. Psychiatry* 7 (7), 611–627.
- (25) Pezzini, A., and Padovani, A. (2020) Lifting the Mask on Neurological Manifestations of COVID-19. *Nat. Rev. Neurol.* 16 (11), 636–644.
- (26) Khan, S., and Gomes, J. (2020) Neuropathogenesis of SARS-CoV-2 Infection. *eLife* 9, e59136.
- (27) Chen, X., Laurent, S., Onur, O. A., Kleineberg, N. N., Fink, G. R., Schweitzer, F., and Warnke, C. (2020) A Systematic Review of Neurological Symptoms and Complications of COVID-19. *J. Neurol.*, DOI: 10.1007/s00415-020-10067-3.
- (28) Puelles, V. G., Lutgehetmann, M., Lindenmeyer, M. T., Sperhake, J. P., Wong, M. N., Allweiss, L., Chilla, S., Heinemann, A., Wanner, N., Liu, S., et al. (2020) Multiorgan and Renal Tropism of SARS-CoV-2. *N. Engl. J. Med.* 383 (6), 590–592.
- (29) Wichmann, D., Sperhake, J. P., Lutgehetmann, M., Steurer, S., Edler, C., Heinemann, A., Heinrich, F., Mushumba, H., Kniep, I., Schroder, A. S., et al. (2020) Autopsy Findings and Venous Thromboembolism in Patients With COVID-19: A Prospective Cohort Study. *Ann. Intern. Med.* 173 (4), 268–277.
- (30) Hanley, B., Naresh, K. N., Roufousse, C., Nicholson, A. G., Weir, J., Cooke, G. S., Thursz, M., Manousou, P., Corbett, R., Goldin, R., et al. (2020) Histopathological Findings and Viral Tropism in UK Patients with Severe Fatal COVID-19: A Post-Mortem Study. *Lancet Microbe* 1 (6), e245–e253.
- (31) Skok, K., Stelzl, E., Trauner, M., Kessler, H. H., and Lax, S. F. (2020) Post-Mortem Viral Dynamics and Tropism in COVID-19 Patients in Correlation with Organ Damage. *Virchows Arch.*, DOI: 10.1007/s00428-020-02903-8.
- (32) Kantonen, J., Mahzabin, S., Mayranpaa, M. I., Tynnenen, O., Paetau, A., Andersson, N., Sajantila, A., Vapalahti, O., Carpen, O., and Kekalainen, E. (2020) Neuropathologic Features of Four Autopsied COVID-19 Patients. *Brain Pathol.* 30, 1012.
- (33) Schaller, T., Hirschbuhl, K., Burkhardt, K., Braun, G., Trepel, M., Markl, B., and Claus, R. (2020) Postmortem Examination of Patients With COVID-19. *JAMA* 323 (24), 2518–2520.

- (34) von Weyhern, C. H., Kaufmann, I., Neff, F., and Kremer, M. (2020) Early Evidence of Pronounced Brain Involvement in Fatal COVID-19 Outcomes. *Lancet* 395 (10241), e109.
- (35) Solomon, I. H., Normandin, E., Bhattacharyya, S., Mukerji, S. S., Keller, K., Ali, A. S., Adams, G., Hornick, J. L., Padera, R. F., Jr, and Sabeti, P. (2020) Neuropathological Features of Covid-19. *N. Engl. J. Med.* 383 (10), 989–992.
- (36) Matschke, J., Lütgehetmann, M., Hagel, C., Spherhake, J. P., Schröder, A. S., Edler, C., Mushumba, H., Fitzek, A., Allweiss, L., Dandri, M., et al. (2020) Neuropathology of Patients with COVID-19 in Germany: A Post-Mortem Case Series. *Lancet Neurol.* 19 (11), 919–929.
- (37) Meinhardt, J., Radke, J., Dittmayer, C., Franz, J., Thomas, C., Mothes, R., Laue, M., Schneider, J., Brunink, S., and Greuel, S. (2021) Olfactory Transmucosal SARS-CoV-2 Invasion as a Port of Central Nervous System Entry in Individuals with COVID-19. *Nat. Neurosci.* 24, 168.
- (38) Al-Dalalah, O., Thakur, K. T., Nordvig, A. S., Prust, M. L., Roth, W., Lignelli, A., Uhlemann, A. C., Miller, E. H., Kunnath-Velayudhan, S., Del Portillo, A., et al. (2020) Neuronophagia and Microglial Nodules in a SARS-CoV-2 Patient with Cerebellar Hemorrhage. *Acta Neuropathol. Commun.* 8 (1), 147.
- (39) Deigendesch, N., Sironi, L., Kutza, M., Wischniewski, S., Fuchs, V., Hench, J., Frank, A., Nienhold, R., Mertz, K. D., Cathomas, G., et al. (2020) Correlates of Critical Illness-Related Encephalopathy Predominate Postmortem COVID-19 Neuropathology. *Acta Neuropathol.* 140 (4), 583–586.
- (40) Fabbri, V. P., Foschini, M. P., Lazzarotto, T., Gabrielli, L., Cenacchi, G., Gallo, C., Aspide, R., Frascaroli, G., Cortelli, P., Riefolo, M., et al. (2021) Brain Ischemic Injury in COVID-19-Infected Patients: A Series of 10 Post-Mortem Cases. *Brain Pathol.* 31, e12901.
- (41) Mukerji, S. S., and Solomon, I. H. (2021) What can we Learn from Brain Autopsy in COVID-19? *Neurosci. Lett.* 742, 135528.
- (42) Schurink, B., Roos, E., Radonic, T., Barbe, E., Bouman, C. S. C., de Boer, H. H., de Bree, G. J., Bulle, E. B., Aronica, E. M., Florquin, S., et al. (2020) Viral Presence and Immunopathology in Patients with Lethal COVID-19: A Prospective Autopsy Cohort Study. *Lancet Microbe* 1 (7), e290–e299.
- (43) Benganem, S., Mazeraud, A., Azabou, E., Chhor, V., Shinotsuka, C. R., Claassen, J., Rohaut, B., and Sharshar, T. (2020) Brainstem Dysfunction in Critically ill Patients. *Crit. Care* 24 (1), 5.
- (44) Solomon, T. (2021) Neurological infection with SARS-CoV-2 - the story so far. *Nat. Rev. Neurol.*, DOI: 10.1038/s41582-020-00453-w.
- (45) Zhou, P., Yang, X. L., Wang, X. G., Hu, B., Zhang, L., Zhang, W., Si, H. R., Zhu, Y., Li, B., Huang, C. L., et al. (2020) A Pneumonia Outbreak Associated with a New Coronavirus of Probable Bat Origin. *Nature* 579 (7798), 270–273.
- (46) Letko, M., Marzi, A., and Munster, V. (2020) Functional Assessment of Cell Entry and Receptor Usage for SARS-CoV-2 and Other Lineage B Betacoronaviruses. *Nat. Microbiol.* 5 (4), 562–569.
- (47) Lin, Z., Chen, Y., Zhang, W., Chen, A. F., Lin, S., and Morris, M. (2008) RNA Interference Shows Interactions Between Mouse Brainstem Angiotensin AT1 Receptors and Angiotensin-Converting Enzyme 2. *Exp Physiol* 93 (5), 676–84.
- (48) Gowrisankar, Y. V., and Clark, M. A. (2016) Angiotensin II Regulation of Angiotensin-Converting Enzymes in Spontaneously Hypertensive Rat Primary Astrocyte Cultures. *J. Neurochem.* 138 (1), 74–85.
- (49) Doobay, M. F., Talman, L. S., Obr, T. D., Tian, X., Davisson, R. L., and Lazartigues, E. (2007) Differential Expression of Neuronal ACE2 in Transgenic Mice with Overexpression of the Brain Renin-Angiotensin System. *Am. J. Physiol Regul Integr Comp Physiol* 292 (1), R373–81.
- (50) Lukiw, W. J., Pogue, A., and Hill, J. M. (2020) SARS-CoV-2 Infectivity and Neurological Targets in the Brain. *Cell. Mol. Neurobiol.*, DOI: 10.1007/s10571-020-00947-7.
- (51) Daly, J. L., Simonetti, B., Klein, K., Chen, K. E., Williamson, M. K., Anton-Plagaro, C., Shoemark, D. K., Simon-Gracia, L., Bauer, M., Hollandi, R., et al. (2020) Neuropilin-1 is a Host Factor for SARS-CoV-2 Infection. *Science* 370 (6518), 861–865.
- (52) Cantuti-Castelvetri, L., Ojha, R., Pedro, L. D., Djannatian, M., Franz, J., Kuivainen, S., van der Meer, F., Kallio, K., Kaya, T., Anastasina, M., et al. (2020) Neuropilin-1 Facilitates SARS-CoV-2 Cell Entry and Infectivity. *Science* 370 (6518), 856–860.
- (53) Corson, S. L., Kim, M., Mistretta, C. M., and Bradley, R. M. (2013) Gustatory Solitary Tract Development: A Role for Neuropilins. *Neuroscience* 252, 35–44.
- (54) Chilton, J. K., and Guthrie, S. (2003) Cranial Expression of Class 3 Secreted Semaphorins and Their Neuropilin Receptors. *Dev. Dyn.* 228 (4), 726–33.
- (55) Netland, J., Meyerholz, D. K., Moore, S., Cassell, M., and Perlman, S. (2008) Severe Acute Respiratory Syndrome Coronavirus Infection Causes Neuronal Death in the Absence of Encephalitis in Mice Transgenic for Human ACE2. *J. Virol.* 82 (15), 7264–75.
- (56) Li, K., Wohlford-Lenane, C., Perlman, S., Zhao, J., Jewell, A. K., Reznikov, L. R., Gibson-Corley, K. N., Meyerholz, D. K., and McCray, P. B., Jr. (2016) Middle East Respiratory Syndrome Coronavirus Causes Multiple Organ Damage and Lethal Disease in Mice Transgenic for Human Dipeptidyl Peptidase 4. *J. Infect. Dis.* 213 (5), 712–22.
- (57) McCray, P. B., Jr, Pewe, L., Wohlford-Lenane, C., Hickey, M., Manzel, L., Shi, L., Netland, J., Jia, H. P., Halabi, C., Sigmund, C. D., et al. (2007) Lethal Infection of K18-hACE2 Mice Infected with Severe Acute Respiratory Syndrome Coronavirus. *J. Virol.* 81 (2), 813–21.
- (58) Tao, X., Garron, T., Agrawal, A. S., Algaissi, A., Peng, B. H., Wakamiya, M., Chan, T. S., Lu, L., Du, L., Jiang, S., et al. (2016) Characterization and Demonstration of the Value of a Lethal Mouse Model of Middle East Respiratory Syndrome Coronavirus Infection and Disease. *J. Virol.* 90 (1), 57–67.
- (59) Ngai, J. C., Ko, F. W., Ng, S. S., To, K. W., Tong, M., and Hui, D. S. (2010) The Long-Term Impact of Severe Acute Respiratory Syndrome on Pulmonary Function, Exercise Capacity and Health Status. *Respirology* 15 (3), 543–50.
- (60) Lam, M. H., Wing, Y. K., Yu, M. W., Leung, C. M., Ma, R. C., Kong, A. P., So, W. Y., Fong, S. Y., and Lam, S. P. (2009) Mental Morbidities and Chronic Fatigue in Severe Acute Respiratory Syndrome Survivors: Long-Term Follow-up. *Arch. Intern. Med.* 169 (22), 2142–7.
- (61) Das, K. M., Lee, E. Y., Singh, R., Enani, M. A., Al Dossari, K., Van Gorkom, K., Larsson, S. G., and Langer, R. D. (2017) Follow-up Chest Radiographic Findings in Patients with MERS-CoV After Recovery. *Indian J. Radiol Imaging* 27 (3), 342–349.
- (62) Nouri-Vaskeh, M., Sharifi, A., Khalili, N., Zand, R., and Sharifi, A. (2020) Dyspneic and Non-Dyspneic (Silent) Hypoxemia in COVID-19: Possible Neurological Mechanism. *Clin Neurol Neurosurg* 198, 106217.
- (63) Zubair, A. S., McAlpine, L. S., Gardin, T., Farhadian, S., Kuruvilla, D. E., and Spudich, S. (2020) Neuropathogenesis and Neurologic Manifestations of the Coronaviruses in the Age of Coronavirus Disease 2019: A Review. *JAMA Neurol* 77 (8), 1018–1027.
- (64) Ogier, M., Andeol, G., Sagui, E., and Dal Bo, G. (2020) How to Detect and Track Chronic Neurologic Sequelae of COVID-19? Use of Auditory Brainstem Responses and Neuroimaging for Long-Term Patient Follow-up. *Brain Behav Immun Health* 5, 100081.
- (65) Li, Z., Liu, T., Yang, N., Han, D., Mi, X., Li, Y., Liu, K., Vuylsteke, A., Xiang, H., and Guo, X. (2020) Neurological Manifestations of Patients with COVID-19: Potential Routes of SARS-CoV-2 Neuroinvasion from the Periphery to the Brain. *Front Med.* 14 (5), 533–541.
- (66) Das, G., Mukherjee, N., and Ghosh, S. (2020) Neurological Insights of COVID-19 Pandemic. *ACS Chem. Neurosci.* 11 (9), 1206–1209.
- (67) Bradley, B. T., Maioli, H., Johnston, R., Chaudhry, I., Fink, S. L., Xu, H., Najafian, B., Deutsch, G., Lacy, J. M., Williams, T., et al. (2020) Histopathology and Ultrastructural Findings of Fatal COVID-19 Infections in Washington State: A Case Series. *Lancet* 396 (10247), 320–332.
- (68) Bulfamante, G., Chiumello, D., Canevini, M. P., Priori, A., Mazzanti, M., Centanni, S., and Felisati, G. (2020) First Ultrastructural

Autoptic Findings of SARS-Cov-2 in Olfactory Pathways and Brainstem. *Minerva Anesthesiol.* 86 (6), 678–679.

(69) Kirschenbaum, D., Imbach, L. L., Ulrich, S., Rushing, E. J., Keller, E., Reimann, R. R., Frauenknecht, K. B. M., Lichtblau, M., Witt, M., Hummel, T., et al. (2020) Inflammatory Olfactory Neuropathy in Two Patients with COVID-19. *Lancet* 396 (10245), 166.

(70) Li, Y. C., Bai, W. Z., and Hashikawa, T. (2020) The Neuroinvasive Potential of SARS-CoV2 may Play a Role in the Respiratory Failure of COVID-19 Patients. *J. Med. Virol.* 92 (6), 552–555.

(71) Gandhi, S., Srivastava, A. K., Ray, U., and Tripathi, P. P. (2020) Is the Collapse of the Respiratory Center in the Brain Responsible for Respiratory Breakdown in COVID-19 Patients? *ACS Chem. Neurosci.* 11 (10), 1379–1381.

(72) Chigr, F., Merzouki, M., and Najimi, M. (2020) Autonomic Brain Centers and Pathophysiology of COVID-19. *ACS Chem. Neurosci.* 11 (11), 1520–1522.

(73) Dey, J., Alam, M. T., Chandra, S., Gupta, J., Ray, U., Srivastava, A. K., and Tripathi, P. P. (2021) Neuroinvasion of SARS-CoV-2 may Play a Role in the Breakdown of Respiratory Center of the Brain. *J. Med. Virol.* 93, 1296.

(74) Yachou, Y., El Idrissi, A., Belapasov, V., and Ait Benali, S. (2020) Neuroinvasion, Neurotropic, and Neuroinflammatory Events of SARS-CoV-2: Understanding the Neurological Manifestations in COVID-19 Patients. *Neurol Sci.* 41 (10), 2657–2669.

(75) Baig, A. M. (2020) Computing the Effects of SARS-CoV-2 on Respiration Regulatory Mechanisms in COVID-19. *ACS Chem. Neurosci.* 11 (16), 2416–2421.

(76) Case, L. C., and Tessier-Lavigne, M. (2005) Regeneration of the Adult Central Nervous System. *Curr. Biol.* 15 (18), R749–53.

(77) Huebner, E. A., and Strittmatter, S. M. (2009) Axon Regeneration in the Peripheral and Central Nervous Systems. *Results Probl. Cell Differ.* 48, 339–351.

(78) Zochodne, D. W. (2012) The Challenges and Beauty of Peripheral Nerve Regrowth. *J. Peripher. Nerv. Syst.* 17 (1), 1–18.

(79) Arnold, D. T., Hamilton, F. W., Milne, A., Morley, A., Viner, J., Attwood, M., Noel, A., Gunning, S., Hatrick, J., and Hamilton, S. (2020) Patient Outcomes After Hospitalisation with COVID-19 and Implications for Follow-up; Results from a Prospective UK Cohort. *medRxiv*, DOI: 10.1101/2020.08.12.20173526.

(80) Shah, A. S., Wong, A. W., Hague, C. J., Murphy, D. T., Johnston, J. C., Ryerson, C. J., and Carlsten, C. (2020) A Prospective Study of 12-Week Respiratory Outcomes in COVID-19-Related Hospitalisations. *Thorax*, DOI: 10.1136/thoraxjnl-2020-216308.

(81) Miyazato, Y., Morioka, S., Tsuzuki, S., Akashi, M., Osanai, Y., Tanaka, K., Terada, M., Suzuki, M., Kutsuna, S., Saito, S., et al. (2020) Prolonged and Late-Onset Symptoms of Coronavirus Disease 2019. *Open Forum Infect. Dis.* 7 (11), ofaa507.

(82) Salmon-Ceron, D., Slama, D., De Broucker, T., Karmochkine, M., Pavie, J., Sorbets, E., Etienne, N., Batisse, D., Spiridon, G., and Baut, V. L. (2020) Clinical, Virological and Imaging Profile in Patients with Persistent or Resurgent Forms of COVID-19: A Cross-Sectional Study. *J. Infect.*, DOI: 10.1016/j.jinf.2020.12.002.

(83) Benarroch, E. E. (2018) Brainstem Integration of Arousal, Sleep, Cardiovascular, and Respiratory Control. *Neurology* 91 (21), 958–966.

(84) Moreira, T. S., Takakura, A. C., Damasceno, R. S., Falquetto, B., Totola, L. T., Sobrinho, C. R., Ragioto, D. T., and Zolezi, F. P. (2011) Central Chemoreceptors and Neural Mechanisms of Cardiorespiratory Control. *Braz. J. Med. Biol. Res.* 44 (9), 883–9.

(85) Smith, J. C., Ellenberger, H. H., Ballanyi, K., Richter, D. W., and Feldman, J. L. (1991) Pre-Botzinger Complex: A Brainstem Region that may Generate Respiratory Rhythm in Mammals. *Science* 254 (5032), 726–9.

(86) Stornetta, R. L. (2008) Identification of Neurotransmitters and Co-Localization of Transmitters in Brainstem Respiratory Neurons. *Respir. Physiol. Neurobiol.* 164 (1–2), 18–27.

(87) Nicholls, J. G., and Paton, J. F. (2009) Brainstem: Neural Networks Vital for Life. *Philos. Trans. R. Soc., B* 364 (1529), 2447–51.

(88) Mandel, D. A., and Schreihofer, A. M. (2006) Central Respiratory Modulation of Barosensitive Neurons in Rat Caudal Ventrolateral Medulla. *J. Physiol.* 572 (3), 881–896.

(89) Zhao, Y. M., Shang, Y. M., Song, W. B., Li, Q. Q., Xie, H., Xu, Q. F., Jia, J. L., Li, L. M., Mao, H. L., Zhou, X. M., et al. (2020) Follow-up Study of the Pulmonary Function and Related Physiological Characteristics of COVID-19 Survivors Three Months After Recovery. *EClinicalMedicine* 25, 100463.

(90) Travagli, R. A., Hermann, G. E., Browning, K. N., and Rogers, R. C. (2006) Brainstem Circuits Regulating Gastric Function. *Annu. Rev. Physiol.* 68, 279–305.

(91) Browning, K. N., and Travagli, R. A. (2014) Central Nervous System Control of Gastrointestinal Motility and Secretion and Modulation of Gastrointestinal Functions. *Compr Physiol* 4 (4), 1339–68.

(92) Horn, C. C. (2008) Why is the Neurobiology of Nausea and Vomiting so Important? *Appetite* 50 (2–3), 430–4.

(93) Andrews, P. L. R., Cai, W., Rudd, J. A., and Sanger, G. J. (2020) COVID-19, Nausea, and Vomiting. *J. Gastroenterol. Hepatol.*, DOI: 10.1111/jgh.15261.

(94) Obiefuna, S., and Donohoe, C. (2020) Neuroanatomy, Nucleus Gustatory. In *StatPearls*, StatPearls Publishing, Treasure Island, FL.

(95) Walker, E. P., and Tadi, P. (2020) Neuroanatomy, Nucleus Raphe. In *StatPearls*, StatPearls Publishing, Treasure Island, FL.

(96) Itoi, K., and Sugimoto, N. (2010) The Brainstem Noradrenergic Systems in Stress, Anxiety and Depression. *J. Neuroendocrinol.* 22 (5), 355–61.

(97) Loughlin, S. E., and Fallon, J. H. (1984) Substantia Nigra and Ventral Tegmental Area Projections to Cortex: Topography and Collateralization. *Neuroscience* 11 (2), 425–35.

(98) Haber, S. N. (2003) The Primate Basal Ganglia: Parallel and Integrative Networks. *J. Chem. Neuroanat.* 26 (4), 317–30.

(99) Venkatraman, A., Edlow, B. L., and Immordino-Yang, M. H. (2017) The Brainstem in Emotion: A Review. *Front. Neuroanat.* 11, 15.

(100) Paredes, S., Cantillo, S., Candido, K. D., and Knezevic, N. N. (2019) An Association of Serotonin with Pain Disorders and Its Modulation by Estrogens. *Int. J. Mol. Sci.* 20 (22), 5729.

(101) Becker, S., and Schweinhardt, P. (2012) Dysfunctional Neurotransmitter Systems in Fibromyalgia, Their Role in Central Stress Circuitry and Pharmacological Actions on These Systems. *Pain Res. Treat.* 2012, 741746.

(102) Yong, S. J., Tong, T., Chew, J., and Lim, W. L. (2020) Antidepressive Mechanisms of Probiotics and Their Therapeutic Potential. *Front. Neurosci.* 13, 1361.

(103) Burgold, T., Voituren, N., Caganova, M., Tripathi, P. P., Menuet, C., Tusi, B. K., Spreafico, F., Beventgut, M., Gestreau, C., Buontempo, S., et al. (2012) The H3K27 Demethylase JMJD3 is Required for Maintenance of the Embryonic Respiratory Neuronal Network, Neonatal Breathing, and Survival. *Cell Rep.* 2 (5), 1244–58.

(104) Eder, H. G., Legat, J. A., and Gruber, W. (2000) Traumatic Brain Stem Lesions in Children. *Childs Nerv Syst* 16 (1), 21–4.

(105) Kinney, H. C., Richerson, G. B., Dymecki, S. M., Darnall, R. A., and Nattie, E. E. (2009) The Brainstem and Serotonin in the Sudden Infant Death Syndrome. *Annu. Rev. Pathol.: Mech. Dis.* 4, 517–50.

(106) Kinney, H. C., and Haynes, R. L. (2019) The Serotonin Brainstem Hypothesis for the Sudden Infant Death Syndrome. *J. Neuropathol. Exp. Neurol.* 78 (9), 765–779.

(107) Dhanwate, A. D. (2014) Brainstem death: A Comprehensive Review in Indian Perspective. *Indian J. Crit. Care Med.* 18 (9), 596–605.

(108) Mills, E. P., Di Pietro, F., Alshelhi, Z., Peck, C. C., Murray, G. M., Vickers, E. R., and Henderson, L. A. (2018) Brainstem Pain-Control Circuitry Connectivity in Chronic Neuropathic Pain. *J. Neurosci.* 38 (2), 465–473.

(109) Wilcox, S. L., Gustin, S. M., Macey, P. M., Peck, C. C., Murray, G. M., and Henderson, L. A. (2015) Anatomical Changes Within the Medullary Dorsal Horn in Chronic Temporomandibular Disorder Pain. *NeuroImage* 117, 258–66.

(110) Stroman, P. W., Khan, H. S., Bosma, R. L., Cotoi, A. I., Leung, R., Cadotte, D. W., and Fehlings, M. G. (2016) Changes in Pain

Processing in the Spinal Cord and Brainstem after Spinal Cord Injury Characterized by Functional Magnetic Resonance Imaging. *J. Neurotrauma* 33 (15), 1450–60.

(111) Marciszewski, K. K., Meylakh, N., Di Pietro, F., Mills, E. P., Macefield, V. G., Macey, P. M., and Henderson, L. A. (2018) Changes in Brainstem Pain Modulation Circuitry Function over the Migraine Cycle. *J. Neurosci.* 38 (49), 10479–10488.

(112) Chong, C. D., Plasencia, J. D., Frakes, D. H., and Schwedt, T. J. (2017) Structural Alterations of the Brainstem in Migraine. *Neuroimage Clin* 13, 223–227.

(113) Marciszewski, K. K., Meylakh, N., Di Pietro, F., Macefield, V. G., Macey, P. M., and Henderson, L. A. (2018) Altered Brainstem Anatomy in Migraine. *Cephalalgia* 38 (3), 476–486.

(114) Aurora, S. K., and Brin, M. F. (2017) Chronic Migraine: An Update on Physiology, Imaging, and the Mechanism of Action of Two Available Pharmacologic Therapies. *Headache* 57 (1), 109–125.

(115) Callard, F., and Perego, E. (2021) How and Why Patients Made Long Covid. *Social Sci. Med.* 268, 113426.

(116) Perrin, R., Riste, L., Hann, M., Walther, A., Mukherjee, A., and Heald, A. (2020) Into the Looking Glass: Post-Viral Syndrome Post COVID-19. *Med. Hypotheses* 144, 110055.

(117) Barnden, L. R., Shan, Z. Y., Staines, D. R., Marshall-Gradisnik, S., Finegan, K., Ireland, T., and Bhuta, S. (2018) Hyperintense Sensorimotor T1 Spin Echo MRI is Associated with Brainstem Abnormality in Chronic Fatigue Syndrome. *Neuroimage Clin* 20, 102–109.

(118) Barnden, L. R., Crouch, B., Kwiatek, R., Burnet, R., Mernone, A., Chryssidis, S., Scroop, G., and Del Fante, P. (2011) A brain MRI study of Chronic Fatigue Syndrome: Evidence of Brainstem Dysfunction and Altered Homeostasis. *NMR Biomed.* 24 (10), 1302–12.

(119) Barnden, L. R., Kwiatek, R., Crouch, B., Burnet, R., and Del Fante, P. (2016) Autonomic Correlations with MRI are Abnormal in the Brainstem Vasomotor Centre in Chronic Fatigue Syndrome. *Neuroimage Clin* 11, 530–537.

(120) Barnden, L. R., Shan, Z. Y., Staines, D. R., Marshall-Gradisnik, S., Finegan, K., Ireland, T., and Bhuta, S. (2019) Intra Brainstem Connectivity is Impaired in Chronic Fatigue Syndrome. *Neuroimage Clin* 24, 102045.

(121) VanElzakker, M. B., Brumfield, S. A., and Lara Mejia, P. S. (2019) Neuroinflammation and Cytokines in Myalgic Encephalomyelitis/Chronic Fatigue Syndrome (ME/CFS): A Critical Review of Research Methods. *Front Neurol* 9, 1033.