



CASE REPORT

Conservative treatment of immature teeth with apical periodontitis using triple antibiotic paste disinfection



Hsin-Ju Wang^a, Yea-Huey Melody Chen^b, Kuan-Liang Chen^{b*}

^a Department of Endodontics, Chang Gung Memorial Hospital—Kaohsiung Medical Center, Kaohsiung, Taiwan, ROC

^b Department of Endodontics, Chi Mei Medical Center, Tainan, Taiwan, ROC

Received 25 January 2011; Final revision received 1 March 2011

Available online 9 April 2013

KEYWORDS

apexogenesis;
immature teeth;
mineral trioxide
aggregate;
sodium hypochlorite;
triple antibiotic paste

Abstract The purpose of this report is to present conservative treatment for two immature premolars with apical periodontitis. A triple antibiotic paste was used to disinfect the root canal systems for revascularization. In both cases, residual vital pulp tissue was noted in the root canal system after the opening of each premolar. The canals in both cases were irrigated with copious sodium hypochlorite solution and medicated with a paste consisting of ciprofloxacin, metronidazole, and minocycline. The teeth were sealed with mineral trioxide aggregate and restored with composite resin. There were satisfactory outcomes after 18 months. The patients were asymptomatic, with radiographic evidence of complete resolution of radiolucency, continual thickening of dentinal walls, apical closure, and increased root length.

Copyright © 2013, Association for Dental Sciences of the Republic of China. Published by Elsevier Taiwan LLC. This is an open access article under the CC BY-NC-ND license (<http://creativecommons.org/licenses/by-nc-nd/4.0/>).

Introduction

Treatment of immature teeth with apical periodontitis poses numerous challenges to dentists. Traditional

apexification uses long-term calcium hydroxide dressing to promote the formation of a calcified barrier.¹ This technique requires multiple appointments over a period of months. A study by Andreasen et al showed that long-term use of calcium hydroxide can weaken dentin.² Recently, mineral trioxide aggregate (MTA) has been used in apexification procedures to create an artificial apical barrier.³ The MTA apexification technique is not only more predictable with a high success rate, but also reduces the number of appointments necessary. Although an open apex may be

* Corresponding author. Department of Endodontics, Chi Mei Medical Center, 901 Chung Hwa Road, Yong Kang City, Tainan 710, Taiwan, ROC.

E-mail address: k2050562@ms33.hinet.net (K.-L. Chen).

closed by traditional apexification or artificial apical barriers, the apexification technique does not promote thickening of the root wall or continual development of the root length.

Recent case presentations have shown that immature teeth clinically diagnosed as nonvital pulp with periradicular periodontitis or abscess can undergo continual maturation of the root and apex.^{4–6} In 2001, Iwaya et al⁴ first described a new treatment procedure for the management of the open apex called revascularization, which disinfected the root canal with sodium hypochlorite (NaOCl) irrigation and two antimicrobial agents (metronidazole and ciprofloxacin). The revascularization technique assumed that the formation of a blood clot within a disinfected root canal space provides a matrix that traps cells capable of initiating new tissue formation. In 2004, Banchs and Trope⁵ published a case presentation where disinfection of the canal was carried out by using NaOCl irrigation followed by a combination of three antibiotics (ciprofloxacin, metronidazole, and minocycline), as described by Hoshino et al.⁷ In 2006, Chueh and Huang⁶ reported four cases of immature teeth with apical periodontitis or abscess that were treated with a conservative approach, without instrumentation and with just copious NaOCl irrigation and calcium hydroxide intra-canal medication. All these four teeth showed continual root development and formation of the root apex.

The aim of this presentation is to report the clinical outcome of two cases of conservative treatment of immature teeth with apical periodontitis. The possible mechanism underlying this clinical observation is also discussed.

Case reports

Case 1

An 11-year-old boy was referred by his general dentist for root canal treatment of the mandibular right second premolar. His general health history was noncontributory. The intra-oral examination revealed swelling on the buccal vestibule of tooth 29 with palpation and percussion

sensitivity. Tooth 29 had been opened and sealed with temporary cement by the patient's general dentist 3 days prior to this examination. The adjacent teeth were caries free and asymptomatic. The periodontal examination presented normal probing depths and physiological mobility. Radiographic film showed an immature open apex with a periradicular rarefaction approximately $5 \times 5 \text{ mm}^2$ in size (Fig. 1A). The diagnosis of tooth 29 was previously initiated therapy leading to acute apical abscess. After the rubber dam isolation and upon accessing the tooth without anesthesia, hemorrhage from the canal was observed. A number 30 gutta-percha cone (Meta Biomed Co., Chungcheongbuk, Korea) was gently inserted into the canal and the patient reported sensitivity, potentially indicating the survival of residual vital pulp tissue (Fig. 1B). The pulp chamber was irrigated with 10 mL of 3% NaOCl, without instrumentation. The canal was dried with paper points. A mixture of ciprofloxacin, metronidazole, and minocycline paste, as described by Hoshino et al,⁷ was mixed to a creamy consistency. The paste was then placed into the canal with an endodontic plugger to a depth of 10 mm. The access cavity was sealed with 4-mm thickness of intermediate restorative materials (IRM; Dentsply Caulk, Milford, DE, USA).

The patient returned 21 days after the last treatment without clinical symptoms. The tooth was then re-opened and the canal irrigated with 10 mL of 3% NaOCl. The canal appeared clean and was without signs of inflammatory exudates. An endodontic explorer was introduced into the canal until apical tissue was detected. The explorer was then used to irritate the tissue gently to create some bleeding into the canal. The bleeding was stopped at a level of 3 mm apical to the cemento-enamel junction (CEJ) and left for 10 minutes. After the blood clotted at that level, the 3 mm thickness of MTA (White Pro-Root MTA, Dentsply Maillefer, Ballaigues, Switzerland) was carefully placed over the blood clot, followed by a wet cotton pellet and IRM (Fig. 1C). The patient returned and was asymptomatic 3 days later. The IRM and cotton pellet were removed and replaced with bonded composite resin restoration (Filtek Z250, 3M ESPE, St Paul, MN, USA) (Fig. 1D). Crown discoloration of tooth 29 was noted (Fig. 2).

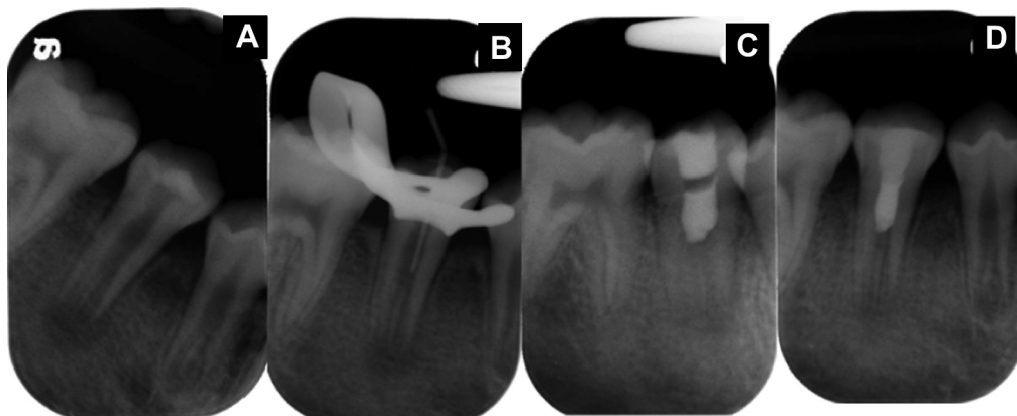


Figure 1 (A) Radiograph showing a radiolucent lesion at the periapical area of tooth 29 with a wide open apex. (B) Radiograph demonstrating a gutta-percha cone being introduced into the canal without local anesthesia, which stopped when the patient felt sensitivity. (C) Radiograph presenting the mineral trioxide aggregate placement. (D) Radiograph presenting composite resin restoration.

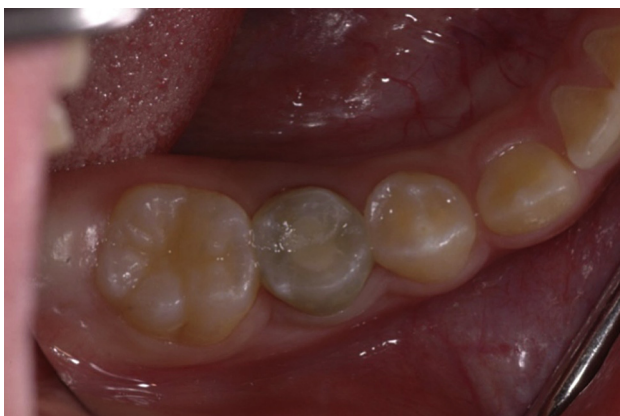

Figure 2 Clinical photograph showing that buccal vestibule swelling at tooth 29 had subsided and there was discoloration 21 days after triple antibiotic paste placement.

At 6-month recall, the patient was asymptomatic. The radiograph showed complete resolution of the radiolucency (Fig. 3A). At 1-year (Fig. 3B) and 17-month (Fig. 3C) follow-up examinations, the patient remained asymptomatic. The radiographs demonstrated evidence of continual development of the tooth apex.

Case 2

A 14-year-old girl was referred by her general dentist for evaluation and root canal treatment of the mandibular right second premolar. Her medical history was unremarkable. The intra-oral examination exhibited a sinus tract on the buccal gingiva of tooth 29 (Fig. 4A), which assured the attrition facet of the central cusp and percussion sensitivity. The adjacent teeth were caries free and asymptomatic. The periodontal examination presented 5 mm of probing depth over the mesiobuccal surface of tooth 29. Radiographic film showed an immature open apex with a periradicular rarefaction approximately $15 \times 7 \text{ mm}^2$ on the mesial root surface (Fig. 4B), with a gutta-percha point

tracing the sinus tract to tooth 29 (Fig. 4C). Pulp vitality test gives unreliable results from immature teeth, therefore a cavity test was performed upon access. With rubber dam isolation and upon accessing the tooth without anesthesia, hemorrhage from the canal was observed. A number 30 gutta-percha cone was gently inserted into the canal and the patient reported sensitivity, potentially indicating the survival of residual vital pulp tissue (Fig. 4D). The clinical diagnosis was partial pulp necrosis with chronic periapical abscess. The hemorrhaging coronal portion of the canal was irrigated with 10 mL of 3% NaOCl, without instrumentation. The canal was dried with paper points. A mixture of ciprofloxacin, metronidazole, and minocycline paste was prepared and then placed into the canal with an endodontic plugger to a depth of 14 mm. The access cavity was sealed with 4 mm thickness of IRM.

The patient returned 25 days later (Fig. 4E). The tooth was re-opened and the canal irrigated with 10 mL of 3% NaOCl. The canal appeared clean with no exudates. An endodontic explorer was introduced into the canal until vital tissue was detected and the blood clot was created 3 mm apical to the CEJ after 10 minutes using the same method described in Case 1. MTA 3-mm thick was carefully placed over the blood clot, followed by a wet cotton pellet and IRM (Fig. 4F). The patient returned 7 days later and was asymptomatic. The IRM and cotton pellet were replaced with bonded composite resin restoration (Fig. 4G).

At 6-month recall, the patient was asymptomatic. The radiograph showed complete resolution of the radiolucency (Fig. 5A). At 1-year (Fig. 5B) and 18-month (Fig. 5C) follow-up examinations, the patient remained asymptomatic, and continual development of the apex of the tooth was shown radiographically.

Discussion

Our two clinical cases underwent the revascularization protocol as described by Banchs and Trope.⁵ Both cases had been conventionally considered indications for apexification treatment. Instead of using endodontic files to

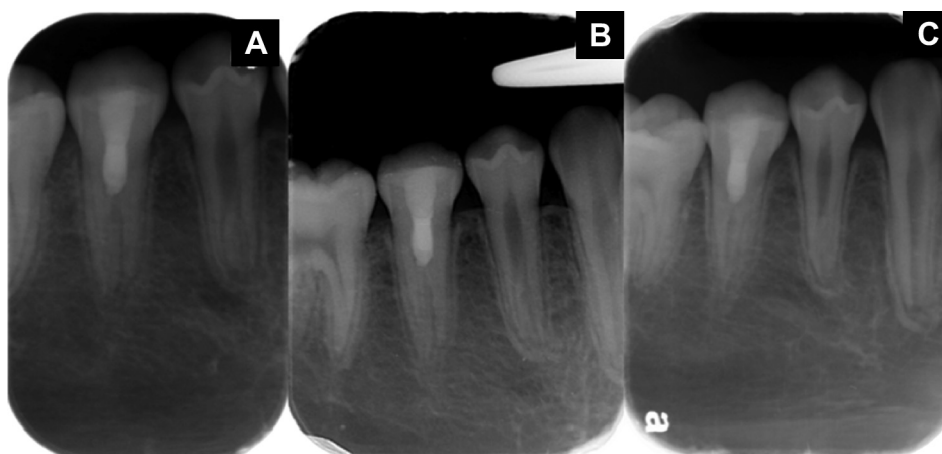

Figure 3 (A) Six-month follow-up radiograph showing complete resolution of radiolucency. (B) One-year follow-up radiograph revealing an increase in the thickness of the root canal wall and continual development of the apex. (C) Seventeen-month follow-up radiograph depicting continual root development.

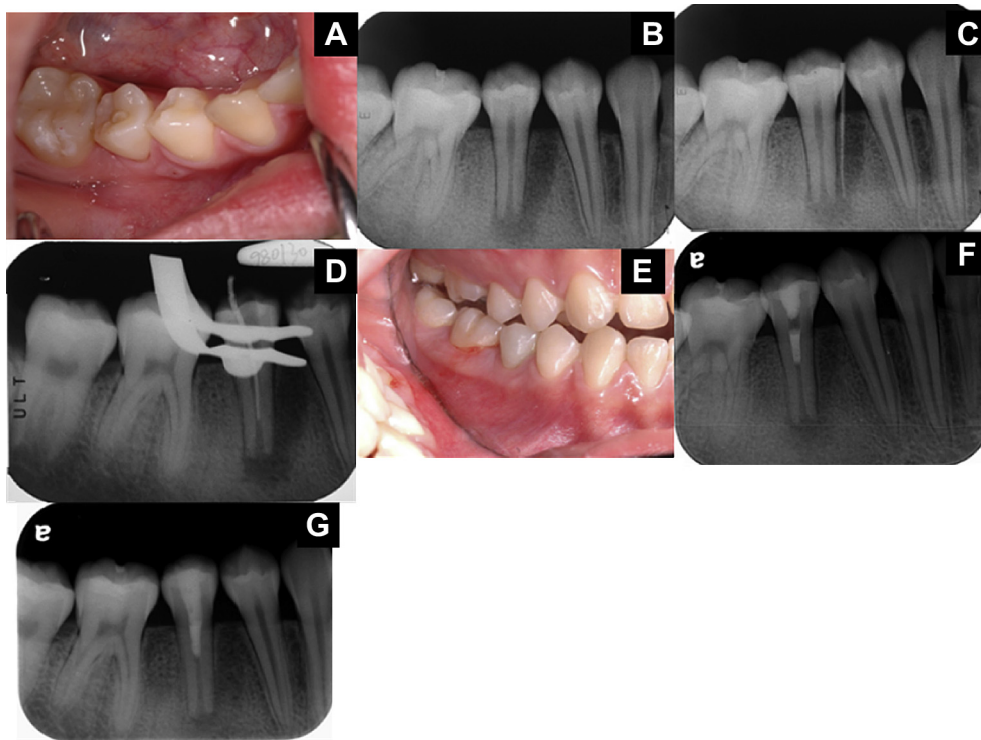


Figure 4 (A) Photograph showing a sinus tract on the alveolar mucosa between teeth 28 and 29. The attrition facet of the central cusp was evident. (B) Radiograph showing periradicular radiolucency of tooth 29 with a wide open apex. (C) Radiograph showing the sinus tract tracing to the periradicular radiolucency of tooth 29. (D) Radiograph demonstrating a gutta-percha cone, which was introduced into the canal without local anesthesia and stopped when the patient felt sensitivity. (E) Clinical photograph 25 days after triple antibiotic paste placement, showing that the sinus tract had disappeared and crown discoloration of tooth 29. (F) Radiograph presenting the mineral trioxide aggregate placement. (G) Radiograph presenting coronal sealing with composite resin restoration.

debride infected pulps or canals, they were irrigated with 3% NaOCl and medicated with triple antibiotic paste. The conservative approach was to preserve the vital pulp tissue. It is possible that apexogenesis can occur with surviving pulp tissue despite the presence of periradicular disease or abscess. In the mature teeth, vital pulp tissues may remain regardless of a periradicular lesion developing.⁸ For a developing tooth, the rich blood supply through the wide open apex may be more potent in defending infection and promoting healing. Moreover, the dental papilla at the apex may contain more stem cells than a mature tooth.⁹ Therefore, a developing tooth has greater potential to rebuild the lost pulp tissue and continue root maturation.

A human avulsion case series study has successfully revascularized immature permanent teeth after replantation.¹⁰ This may be because, although the pulp is devitalized after avulsion, it will stay free of bacteria for some time. The uninfected pulp acts as a scaffold for the in-growth of new tissue from the periradicular area. In addition, the crowns of these teeth are usually intact. As it takes bacteria a long time to advance into the pulp space, the new tissue will fill the canal space. Applying these three concepts for treating a necrotic and infected immature permanent tooth with apical periodontitis is generalized as: (1) the infected canals need to be disinfected; (2) the presence of a scaffold for tissue in-growth is required; and

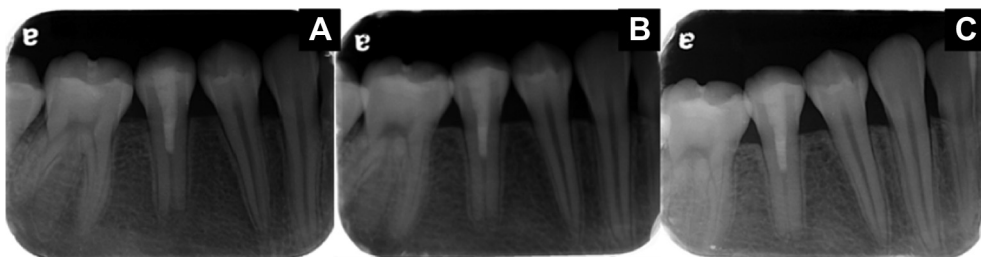


Figure 5 (A) Six-month follow-up radiograph showing complete resolution of radiolucency. (B) One-year follow-up radiograph showing a slight increase in the thickness of the root canal wall and continual development of the apex. (C) Eighteen-month follow-up radiograph showing continual root development.

(3) intact coronal seal to prevent bacteria leakage into the canal.

The disinfection features of immature teeth with apical periodontitis in the case reports^{4–6} are: minimal or no instrumentation; irrigation with 2.5–5.25% NaOCl solution; and intra-canal medication with antimicrobial agents comprising equal parts of metronidazole, minocycline, and ciprofloxacin in a paste form⁵ or with calcium hydroxide dressing.⁶ In the *in vitro* study by Hoshino et al⁷ and the *in vivo* study by Windly et al,¹¹ the effect of antibiotic combination against the bacteria of infected dentine, infected pulps and periapical lesions was better than treatment with each antibiotic alone. In addition, in the *in situ* study by Sato et al,¹² the antibiotic combination was effective in killing bacteria in the deep layers of root canal dentine. Banchs and Trope⁵ indicated that the high pH of calcium hydroxide will necrose tissue in immediate contact, destroying tissues that are potentially differentiating into new pulps. In Chueh and Huang's study,⁶ the use of calcium hydroxide as intracanal medication resulted in apical maturation with increased root length but significantly narrowed canal space. One question that has been puzzling clinicians is what type of tissue is actually generated in the pulp space after antibiotic or calcium hydroxide therapy. It is still unknown whether the thickened root is formed by pulp tissue from the remaining vital pulp and dental papilla at the periradicular region¹³ or by periodontal ligament tissue that has grown into the root canal from the apical opening and deposited the cementum onto the inner surface of the root dentin.

It is unfortunate that there is a lack of histological findings on human studies. In the study in rhesus monkeys by Nevins et al,¹⁴ the cementum tissue formed at the apex and in the canal after total pulp tissue removal in immature teeth that were treated either with calcium hydroxide or collagen gel. Wang et al¹⁵ used the triple antibiotic paste to disinfect immature dog teeth that were infected with plaque. It was found that there was cementum and bone tissue formation at the apex and in the canal and it was concluded that the mechanism was not tissue regeneration but wound repair. However, one case¹⁵ proved partial survival of pulp tissue and odontoblast lining against one side of the dentin wall, which might be due to infection owing to supragingival plaque insertion into the pulp chamber causing severe tissue damage. In our cases, the residual vital pulp tissue detected might contribute to the root development. Continual apical development might come from cells in the surviving pulp–dentin complex or regenerated tissues originating from stem/progenitor cells in the apical papilla.¹³

Bose et al¹⁶ compared the radiographically-assessed outcome of root formation between the triple antibiotic paste and calcium hydroxide treatment. It was found that the former produced significantly greater differences in root wall thickness than the latter. There was no significant difference, however, between both groups whose root length had increased significantly more than apexification. The position at which calcium hydroxide was placed also influenced the outcome; placing calcium hydroxide in the coronal half of the root canal system had better results than placing it beyond the coronal half. This was also reported by Chueh and Huang.⁶ They found that calcium hydroxide placement deep in the canals might have

prevented the deposition of hard-tissue formation in the coronal half of the canals. In addition, studies have testified that long-term calcium hydroxide treatment can in fact weaken the tooth and predispose it to fracture.²

The disadvantage of the antibiotic paste treatment is that it may cause bacterial resistance and allergy. The paste contains both bactericidal (metronidazole and ciprofloxacin) and bacteriostatic (minocycline) antibiotics. There is currently no study on the effect of the bacterial resistance of antibiotic paste in canals. Minocycline causes tooth discoloration, like Ledermix,¹⁷ more severely in the chamber than below the CEJ. In our cases, crown discoloration was noted after triple antibiotic paste dressing (Figs. 2 and 4E). To prevent crown discoloration, Reynolds¹⁸ described a modified novel technique using flowable composite to seal the dentinal tubules of the chamber, and to prevent any contact between the triple antibiotic paste and the dentinal walls of the crown. Iwaya et al⁴ used only a metronidazole and ciprofloxacin combination for canal disinfection. Further investigation is needed to replace minocycline with other antibiotics in order to get the same disinfection effect.

A blood clot was induced as a scaffold for tissue ingrowth in the canal after disinfection for both cases presented. Thibodeau et al¹⁹ ascertained that roots with blood clots after disinfection had better treatment outcomes in a dog model than those without blood clots. Besides acting as a scaffold, the blood clot might also contain platelet-derived growth factors that were important for revascularization. In the case series study by Jung et al,²⁰ there was no difference between cases with and without induced intracanal bleeding. It is still controversial whether blood clots should be induced or not.

A bacteria-tight coronal seal needs to be created to inhibit bacterial invasion. MTA has excellent marginal adaptation and sealing ability.²¹ A double seal of MTA placed below the CEJ followed by a seal of bonded resin coronal was reported by Banchs and Trope.⁵ Lawley et al²² also attributed a significantly greater resistance to root fracture to a 4-mm thickness of MTA followed by an intracanal composite resin.

In conclusion, this report demonstrates a successful conservative technique that can be used to treat immature teeth with apical periodontitis and the long-term prognosis of these cases was investigated. This conservative technique involved no instrumentation, 3% NaOCl irrigation, and a combination of three antibiotics (ciprofloxacin, metronidazole and minocycline) as intracanal medication, resulting in the resolution of periapical pathology and a thickened, mature root. This treatment modality should be preferable to the traditional apexification treatment.

References

1. Rafter M. Apexification: a review. *Dent Traumatol* 2005;21: 1–8.
2. Andreasen JO, Farik B, Munksgaard EC. Long-term calcium hydroxide as a root canal dressing may increase the risk of root fracture. *Dent Traumatol* 2002;18:134–7.
3. Witherspoon DE, Small JC, Regan JD, Nunn M. Retrospective analysis of open apex teeth obturated with mineral trioxide aggregate. *J Endod* 2008;34:1171–6.

4. Iwaya SI, Ikawa M, Kubota M. Revascularization of an immature permanent tooth with apical periodontitis and sinus tract. *Dent Traumatol* 2001;17:185–7.
5. Banchs F, Trope M. Revascularization of immature permanent teeth with apical periodontitis: new treatment protocol? *J Endod* 2004;30:196–200.
6. Chueh LH, Huang GT. Immature teeth with periradicular periodontitis or abscess undergoing apexogenesis: a paradigm shift. *J Endod* 2006;32:1205–13.
7. Hoshino E, Kurihara-Ando N, Sato I, et al. In-vitro antibacterial susceptibility of bacteria taken from infected root dentine to a mixture of ciprofloxacin, metronidazole and minocycline. *Int Endod J* 1996;29:125–30.
8. Lin L, Shovlin F, Skribner J, Langeland K. Pulp biopsies from the teeth associated with periapical radiolucency. *J Endod* 1984;10:436–48.
9. Gronthos S, Brahim J, Li W, et al. Stem cell properties of human dental pulp stem cells. *J Dent Res* 2002;81:531–5.
10. Kling M, Cvek M, Mejare I. Rate and predictability of pulp revascularization in therapeutically reimplanted permanent incisors. *Endod Dent Traumatol* 1986;2:83–9.
11. Windley 3rd W, Teixeira F, Levin L, Sigurdsson A, Trope M. Disinfection of immature teeth with a triple antibiotic paste. *J Endod* 2005;31:439–43.
12. Sato I, Ando-Kurihara N, Kota K, Iwaku M, Hoshino E. Sterilization of infected root-canal dentine by topical application of a mixture of ciprofloxacin, metronidazole and minocycline in situ. *Int Endod J* 1996;29:118–24.
13. Sonoyama W, Liu Y, Yamaza T, et al. Characterization of the apical papilla and its residing stem cells from human immature permanent teeth: a pilot study. *J Endod* 2008;34:166–71.
14. Nevins A, Finkelstein F, Laporta R, Borden BG. Induction of hard tissue into pulpless open-apex teeth using collagen-calcium phosphate gel. *J Endod* 1978;4:76–81.
15. Wang X, Thibodeau B, Trope M, Lin L, Huang GT. Histologic characterization of regenerated tissues in canal space after the revitalization/revascularization procedure of immature dog teeth with apical periodontitis. *J Endod* 2010;36:56–63.
16. Bose R, Nummikoski P, Hargreaves K. A retrospective evaluation of radiographic outcomes in immature teeth with necrotic root canal systems treated with regenerative endodontic procedures. *J Endod* 2009;35:1343–9.
17. Kim ST, Abbott PV, McGinley P. The effects of Ledermix paste on discolouration of immature teeth. *Int Endod J* 2000;33:233–7.
18. Reynolds K, Johnson JD, Cohenca N. Pulp revascularization of necrotic bilateral bicuspid using a modified novel technique to eliminate potential coronal discolouration: a case report. *Int Endod J* 2009;42:84–92.
19. Thibodeau B, Teixeira F, Yamauchi M, Caplan DJ, Trope M. Pulp revascularization of immature dog teeth with apical periodontitis. *J Endod* 2007;33:680–9.
20. Jung IY, Lee SJ, Hargreaves KM. Biologically based treatment of immature permanent teeth with pulpal necrosis: a case series. *J Endod* 2008;34:876–87.
21. Torabinejad M, Wilder Smith P, Pitt Ford TR. Comparative investigation of marginal adaptation of mineral trioxide aggregate and other commonly used root-end filling materials. *J Endod* 1995;21:295–9.
22. Lawley GR, Schindler WG, Walker III WA, Kolodrubetl D. Evaluation of ultrasonically placed MTA and fracture resistance intracanal composite resin in a model of apexification. *J Endod* 2004;30:167–72.